



ELSEVIER

Contents lists available at [ScienceDirect](https://www.sciencedirect.com)

Trauma Case Reports

journal homepage: www.elsevier.com/locate/tcr

Case Report

Delayed traumatic purulent pericarditis with cardiac tamponade - A rare case report

Te-Kai Liao^{*}, Hiong-Ping Hii, Chao-Kun Chen, Li-Chin Cheng

Division of Traumatology, Department of Surgery, Tainan Chi-Mei Medical Center, No.901, Zhonghua Rd., Yongkang Dist., Tainan City 710, Taiwan

ARTICLE INFO

Keywords:

Pericardial tamponade
Purulent pericarditis
Thoracic trauma
Delayed traumatic purulent pericarditis

ABSTRACT

Thoracic trauma often results in immediate or delayed hemorrhage. There are few cases of purulent pericarditis with pericardial tamponade reported in the literature. If a devastating complication develops several weeks following blunt thoracic trauma, the causal relationship with the thoracic trauma event is less evident. As such, accurate diagnosis and subsequent effective treatment implementation is likely to be delayed. Herein, we present the case of a 46-year-old male patient with delayed purulent pericarditis that led to cardiac tamponade 2 weeks after the initial trauma.

Introduction

Cardiac tamponade occurs in less than 0.1 % of cases after blunt chest trauma, the majority of cases are related to hemopericardium [1]. Delayed traumatic purulent pericarditis with cardiac tamponade is rare and has not been reported in previous studies. Possible pathogenic mechanisms include hematogenous spread, infection of the adjacent thoracic cavity, and minor injury to organs from the mediastinal cavity [2]. Herein, we present and discuss the case of a 46-year-old male patient with delayed purulent pericarditis that led to cardiac tamponade 2 weeks after the initial collision.

Case presentation

A 46-year-old male motorcyclist was brought to our emergency department following a road traffic collision. On arrival, the patient was alert and oriented. Physical examination revealed erythematous changes over the trunk, from the chest to the abdomen, and severe abnormalities of the extremities. Once the patient was stabilized, whole body computed tomography (CT) was performed. CT showed bilateral lung contusions with mild hemothorax, fractures of the right third to fifth ribs, and liver laceration with a minor active bleed (Fig. 1). Empiric trans-arterial embolization of the right hepatic artery was subsequently successfully with Gelfoam.

The patient was admitted to the intensive care unit (ICU) Sinus tachycardia with ventricular premature complex (VPC) was noted, and laboratory examination showed elevated troponin-I (820.3 pg/mL). Subsequently, an echocardiogram was arranged; however, no cardiac wall abnormality or pericardial effusion was noted. A 10 French pigtail chest catheter was placed on the fourth day after admission, and a subsequent echocardiogram revealed progression of left pleural effusion. No pleural effusion was detected over the right costophrenic angle, and drainage fluid was a moderate to dark red color. Chest radiography (CXR) was subsequently rechecked over several days. There was a significant improvement in the hemithorax white-out and fluid amount. As such, the pigtail catheter size

^{*} Corresponding author at: 7F.-1, No.192, Daqiao 2nd St., Yongkang Dist., Tainan City 710008, Taiwan.
E-mail address: poorguypaper@gmail.com (T.-K. Liao).

<https://doi.org/10.1016/j.tcr.2022.100726>

Accepted 1 November 2022

Available online 2 November 2022

2352-6440/© 2022 The Authors. Published by Elsevier Ltd. This is an open access article under the CC BY-NC-ND license (<http://creativecommons.org/licenses/by-nc-nd/4.0/>).

was not revised. After 10 days of intensive care, the patient was transferred to a regular hospital ward in stable condition, and the chest pigtail catheter was removed.

The patient however complained of shortness of breath on the third day after being transferred. CXR showed recurrent massive left pleural effusion. An echo-guided pigtail insertion was subsequently performed, and minimal turbid fluid was drained. Culture of the drainage fluid was later confirmed positive for *Staphylococcus aureus* (*S. aureus*). The patient's symptoms temporarily improved, though 2 days later, he experienced severe chest pain with worsening shortness of breath. Electrocardiography showed frequent VPC, and cardiomegaly was observed on CXR. CT disclosed a severe purulent pericardial effusion at the right heart border and suspected purulent pericarditis with cardiac tamponade. A cardiovascular surgeon was consulted for emergency surgery. Upon pericardiectomy, compression of the right atrium and right ventricle by a massive yellow purulent exudate was found with cardiac tamponade. Both pericardiectomy and debridement were subsequently performed and around 500 mL of purulent exudate was removed (Fig. 2). Additionally, a right atrium/superior vena cava (RA/SVC) junction tear was found and repaired by the surgeon. As *S. aureus* was grown upon culture of both the purulent exudate and blood, the penicillin beta-lactam antibiotic, *oxacillin* and aminoglycoside, gentamycin were administered for infection control. The patient developed dyspnea with desaturation 3 weeks following pericardiectomy. Follow-up CT revealed bilateral lung pleural effusion and empyema. Decortication surgery was performed, and multiple bilateral loculated effusions and exudates were removed. Following intravenous administration of antibiotics, the patient recovered and was discharged within one month.

Discussion

Thoracic trauma comprises 20–25 % of all traumas worldwide and is the third most common cause of death in patients with polytrauma after abdominal injury and head trauma [3,4]. It can be broadly divided into blunt or penetrating trauma. The most common cause of blunt chest trauma is motor vehicle collision, which accounts for up to 80 % of all injuries. Blunt chest trauma can cause various cardiac injuries, including minor contusions or rupture of the heart and pericardium. These injuries often result in hemopericardium.

In previous studies, delayed hemopericardium with cardiac tamponade after nonpenetrating chest trauma has been described [5]. Delayed hemopericardium may result from displacement of a thrombus that had temporarily closed the cardiac wound [6]. However, delayed purulent pericarditis complicated by tamponade has not been previously described in any study, to the best of our knowledge. Several pathogenic mechanisms can lead to invasion of the pericardial space to cause purulent pericarditis. These include hematogenous spread, infection of the adjacent thoracic cavity, and minor injury to organs in the mediastinal cavity. In our case, both the blood, pleural and pericardial fluid contained *S. aureus*, which is most often involved in hematogenous spread [7]. Trauma-related RA/SVC tears are the leading cause of bacterial colonization. Other risks include immunosuppression, cardiothoracic surgery, and preexisting catheters in the pericardial cavity [2]. We postulated that the RA/SVC tears were sealed by a thrombus during the first 10 days in ICU. After returning to the ward, intermittent coughing and unanticipated exertion may have displaced the thrombus, resulting in subsequent bleeding and rapid bacterial growth leading to cardiac tamponade. Other origins, such as contiguous spread from the intrathoracic site or minor perforation of the esophagus, were also possible. In our case, the left pleural pigtail catheter may have introduced *S. aureus* from the skin into the thoracic space and subsequently the pericardium. However, it was difficult to confirm the exact cause.

Patients with pericarditis present with sharp pleuritic chest pain, which is usually located in the retrosternal region and may radiate into the neck, jaw, or arms, similar to myocardial ischemia. Unlike myocardial ischemia, chest pain due to pericarditis is exacerbated in

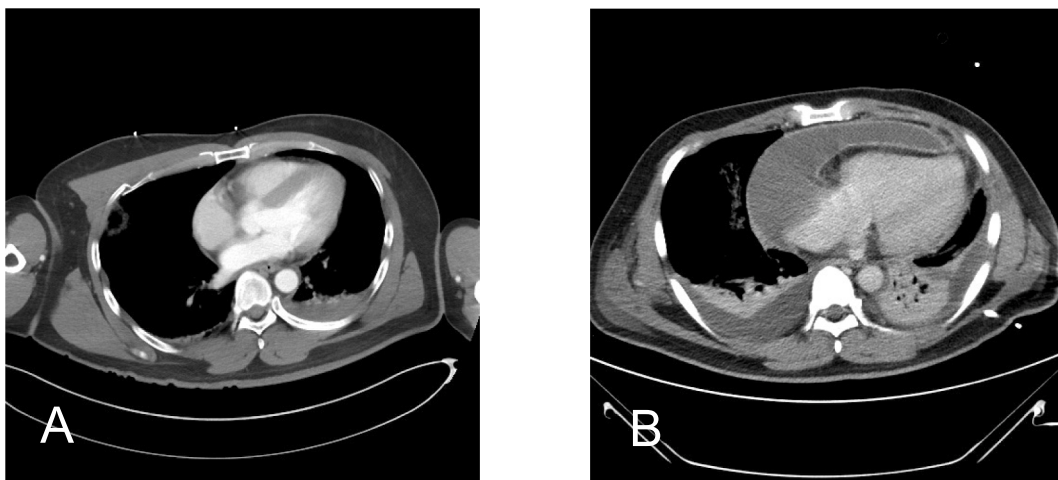


Fig. 1. Axial slices of CT. A) Initial ER CT; no fluid located at the pericardium. B) Severe purulent pericardial effusion at the right heart border, suggestive of purulent pericarditis with cardiac tamponade.

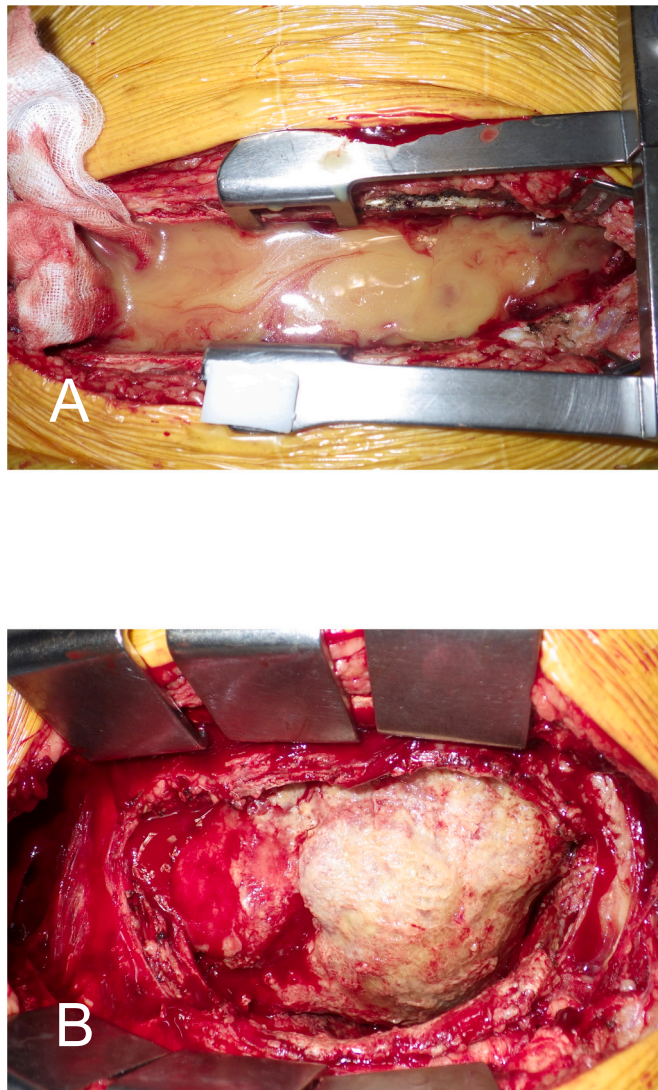


Fig. 2. A) Intraoperative image of purulent pericardial fluid. B) Inflammation and adhesion of the pericardium cavity.

the supine position, coughing, and with inspiration [8]. Echocardiography is the preferred diagnostic tool that shows both the location and amount of pericardial fluid. In most patients with cardiac tamponade, typical echocardiography shows diastolic collapse of the right atrium, right ventricle, or left heart [9]. CT is usually not required when echocardiography is available. In our case, both echo- and ultrasound-guided tube placement was performed 2 days before surgery. However, no obvious pericardial effusion was found. As such, until the severity of symptoms increased, emergent CT was used to identify lesions.

The gold-standard treatment for purulent pericarditis should include drainage of the pericardial space. This should be combined with systemic antibiotic therapy that is initially broad-spectrum empirical, and then adjusted according to the results of microbiological study [7]. Open surgical intervention is preferred over pericardiocentesis when the effusion is thick and loculated.

Conclusion

Delayed traumatic pericarditis with cardiac tamponade is serious, and can occur if a patient has a history of chest trauma even when there are no symptoms. The pathogenic mechanisms include hematogenous spread, infection of the adjacent thoracic cavity, and minor injury to organs in the mediastinal cavity. Catheter related pleural infection is a potential cause. The mortality rate in patients who are promptly diagnosed and appropriately treated is around 40 %, generally due to cardiac tamponade, septic shock, or constriction. Mortality increases with delayed diagnosis and is higher in those with *S. aureus* infection and in malnourished patients [10].

Declaration of competing interest

The authors declare that they have no known competing financial interests or personal relationships that have influenced the work reported in this paper.

References

- [1] R.L. Maenza, D. Seaberg, F. D'Amico, A meta-analysis of blunt cardiac trauma: ending myocardial confusion, *Am. J. Emerg. Med.* 14 (3) (1996 May) 237–241.
- [2] R.H. Rubin, R.C. Moellering Jr., Clinical, microbiologic and therapeutic aspects of purulent pericarditis, *Am. J. Med.* 59 (1) (1975 Jul) 68–78.
- [3] R. Demirhan, B. Onan, K. Oz, S. Halezeroglu, Comprehensive analysis of 4205 patients with chest trauma: a 10-year experience, *Interact. Cardiovasc. Thorac. Surg.* 9 (3) (2009 Sep) 450–453.
- [4] F.E. Lecky, O. Bouamra, M. Woodford, R. Alexandrescu, S.J. O'Brien, Epidemiology of polytrauma, in: H.-C. Pape, A.B. Peitzman, C.W. Schwab, P.V. Giannoudis (Eds.), *Damage Control Management in the Polytrauma Patient*, Springer, New York, 2010, pp. 13–24.4.
- [5] T. Tsugu, Y. Nagatomo, T. Tanigawa, J. Endo, Y. Itabashi, M. Murata, H. Mitamura, Delayed hemopericardium due to non-penetrating chest trauma: a report of new case and literature review 46 (1) (2019 Jan) 159–162 (2001).
- [6] M.O. Aaland, R.T. Sherman, Delayed pericardial tamponade in penetrating chest trauma: case report, *J. Trauma* 31 (11) (1991 Nov) 1563–1565.
- [7] L. Ferreira dos Santos, D. Moreira, P. Ribeiro, B. Rodrigues, et al., Pericardite purulenta: um diagnóstico raro [Purulent pericarditis: a rare diagnosis], *Rev. Port. Cardiol.* 32 (9) (2013 Sep) 721–727.
- [8] V. Ariyarajah, D.H. Spodick, Acute pericarditis: diagnostic cues and common electrocardiographic manifestations, *Cardiol. Rev.* 15 (1) (2007 Jan-Feb) 24–30.
- [9] S. Roomi, S. Haq, W. Ullah, M.S. Jafar, M. Sherazi, Cardiac tamponade due to inferior vena cava filter removal: a case report and review of literature, *Cureus* 12 (2) (2020 Feb 14), e6996.
- [10] J. Mercé, J. Sagristà-Sauleda, G. Permanyer-Miralda, A. Evangelista, J. Soler-Soler, Correlation between clinical and doppler echocardiographic findings in patients with moderate and large pericardial effusion: implications for the diagnosis of cardiac tamponade, *Am. Heart J.* 138 (4 Pt 1) (1999 Oct) 759–764.