

The prevalence and types of coronary artery anomalies in Northern Ireland

S B Pillai, M M Khan, A Diamond, P P McKeown

Accepted 1 March 2000

SUMMARY

Coronary artery anomalies are uncommon, with a reported prevalence ranging from 0.2% to 1.6%. It is important that those who undertake coronary angiographic procedures are aware of the spectrum of these anomalies. Interventional percutaneous coronary revascularisation procedures are widely used in the management of patients with symptomatic coronary atherosclerosis. The presence of a coronary artery anomaly may make these procedures technically challenging. We have reviewed the Cardiac catheterisation database at the Royal Victoria Hospital, Belfast, and report the prevalence and types of these anomalies.

INTRODUCTION

The prevalence of coronary artery anomalies in the general population varies from 0.2% to 1.6%.¹⁻³ Although coronary artery anomalies are rare, they may result in symptoms, with the clinical spectrum ranging from chest pain to sudden death. Of interest, Click *et al* reviewed angiographic data from the Coronary Artery Surgery Study and reported that anomalous circumflex coronary arteries had a significantly greater degree of stenosis than that found in non-anomalous arteries in age – and gender-matched patients.¹

Coronary angiography remains the gold standard in the diagnosis of coronary artery anomalies. The recognition of these anomalies is of particular significance when a patient requires percutaneous therapeutic coronary intervention or cardiac surgery.

The purpose of this study was to establish the prevalence and anatomical patterns of coronary artery anomalies in the adult population of Northern Ireland.

METHODS

This study was carried out at the Regional Medical Cardiology Centre, Royal Victoria Hospital, Belfast. Demographic details of all adult patients undergoing coronary angiography at this centre are recorded on a dedicated Cardiology database. Angiographic procedures are performed by Consultant Cardiologists, including several

Visiting Cardiologists, and doctors-in-training (under the supervision of the Consultant staff). After the angiogram has been performed the physician, who has undertaken the procedure, should record the diagnostic findings, including the presence of congenital coronary anomalies, on a separate diagnostic form. This information is then entered on the same database. We analysed the data between the period 1 January 1990 to 15 July 1999. Patients with known congenital heart disease were excluded. 18 189 diagnostic catheterisations involving 14 424 patients were performed. Complete diagnostic coding of coronary angiographic findings was available in

Regional Medical Cardiology Centre, Royal Victoria Hospital, Grosvenor Road, Belfast BT12 6BA, Northern Ireland

Shevanthi Bastiam Pillai, MD, Specialist Registrar.

Mazhar M Khan, FRCP, Consultant Cardiology.

Aisling Diamond, MRCPI, Senior House Officer.

Cardiovascular Research Group, The Queen's University of Belfast, Institute of Clinical Science, Grosvenor Road, Belfast BT12 6BJ, Northern Ireland.

Pascal P McKeown, MD, Consultant/Senior Lecturer in Cardiology.

Correspondence to Dr McKeown, Regional Medical Cardiology Centre, Royal Victoria Hospital, Grosvenor Road, Belfast BT12 6BA, Northern Ireland.

11 411 patients (79.0%). The diagnostic coding information was incomplete in the other patients, due to a failure of some members of the medical staff to complete fully the diagnostic form.

Two approaches were used – the angiograms from those patients recorded as having a congenital coronary anomaly were retrieved and reviewed by two independent observers (n= 50) or details of the coronary anomalies were obtained from the medical notes (n= 9). In two patients it was not possible to validate the presence of a coronary anomaly as both the angiogram and the medical notes had been misplaced.

The coronary artery anomalies were classified according to a scheme adapted from those suggested by Chu and Cheitlin² and Angelini.⁴ Congenital coronary anomalies were classified as: (a) ectopic coronary artery origin, (b) absence of a coronary artery, or (c) abnormal distal connection. Angelini has defined a coronary anomaly as any congenital deviation that is seen in less than 1% of otherwise normal individuals.⁴ Absence of the left main trunk (side by side origin of the left anterior descending and circumflex) and separate origin of a conus branch were therefore not included in our analysis, as these have been reported in >1% of otherwise normal hearts.⁴ Minor variations in the position of a coronary artery origin (such as 'high take-off') in the right or left coronary sinuses were also not included. However, those patients with an extremely unusual coronary artery origin in the respective coronary sinus, which could not be selectively entered or which required a prolonged search, were included.

RESULTS

We confirmed the presence of sixty congenital coronary anomalies in fifty-nine patients, giving an estimated prevalence of 0.52%. Thirty-four were male and twenty-five female. The age range was 19 to 82 years. The details of these coronary artery anomalies are summarised in the Table.

Of these fifty-nine patients, forty-eight had an ectopic coronary artery origin, four had absence of a coronary artery (circumflex artery in three patients and right coronary artery in one patient), one had both an ectopic coronary artery origin (left anterior descending coronary artery arising from right coronary sinus) and absent circumflex, and six had an abnormal distal connection. Of the patients with an ectopic coronary artery origin,

TABLE

<i>Congenital Coronary Artery Anomalies</i>	
<i>Ectopic Coronary Artery Origin</i>	
Anomalous CX from RCS	27
Anomalous CX from RCA	7
Anomalous RCA from LCS	5
Anomalous LMCA from RCS	2
Anomalous LAD from RCS	1*
Single right Coronary Artery	3
Single left Coronary Artery	1
Posterior location of LMCA in LCS	2
Posterior location of RCA in RCS	1#
<i>Absent Coronary Artery</i>	
Absent CX	4*
Absent RCA	1
<i>Abnormal Distal Connection</i>	
LAD to PA Fistula	4
LMCA to PA Fistula	1
CX to Coronary Sinus	1
TOTAL	60*

* Note: one patient had both an abnormal origin of the left anterior descending coronary artery from the right coronary sinus and an absent circumflex artery.

Note: right coronary artery not selectively entered.

Abbreviations: CX=circumflex, LAD=left anterior descending, LCS=left coronary sinus, LMCA=left main coronary artery, NCS=non-coronary sinus, PA=pulmonary artery, RCA=right coronary artery, RCS=right coronary sinus.

the commonest anomaly was an anomalous circumflex artery arising from either the right coronary sinus (twenty-seven patients) or the right coronary artery (seven patients) [Figure 1]. Of the thirty-four patients with anomalous circumflex arteries, four had a dominant circumflex. Four patients had a single coronary artery, which supplied all three branches; three had a single right [Figure 2] and one a single left coronary artery. One patient had an absent right coronary artery, with the circumflex artery continuing beyond the crux to supply the territory normally supplied by the right coronary artery [Figure 3]. Two patients had an extreme posterior location of the left coronary artery in the left coronary sinus and in one patient the right coronary artery was not selectively entered,

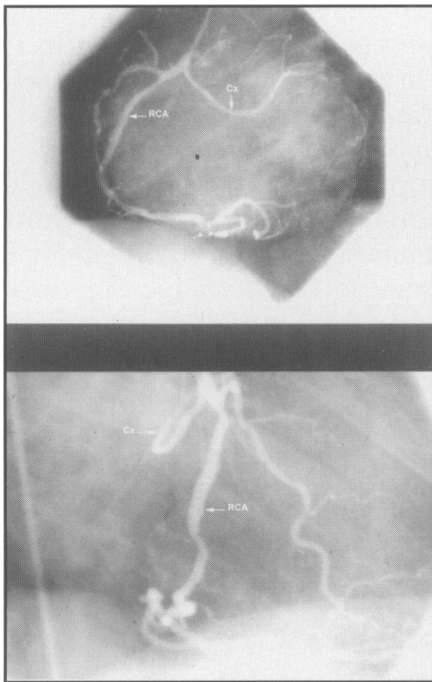


Fig 1. Anomalous origin of circumflex artery from right coronary artery (a) Left Anterior Oblique projection. (b) Right Anterior Oblique projection shows characteristic posterior (retro-aortic) course of the anomalous circumflex artery. Cx=circumflex, RCA=right coronary artery.

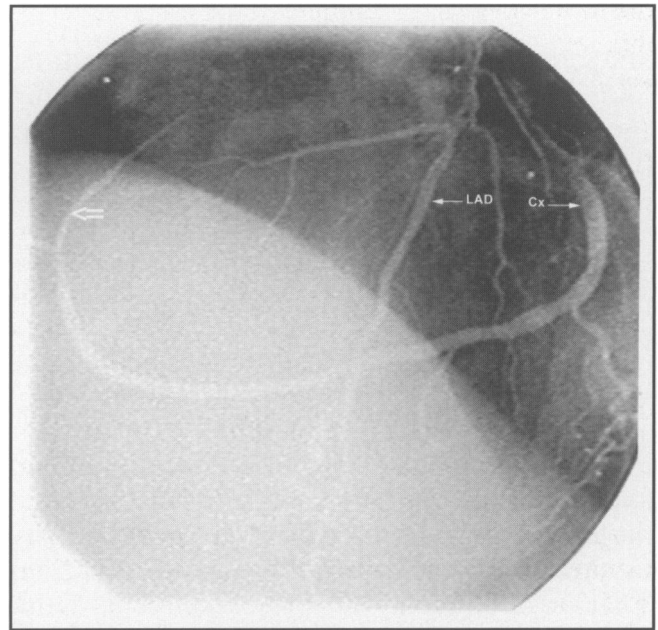


Fig 3. Absent right coronary artery. Left Anterior Oblique projection. The large arrow shows the continuation of the circumflex artery into the territory normally supplied by the right coronary artery. Cx=circumflex, LAD=left anterior descending.

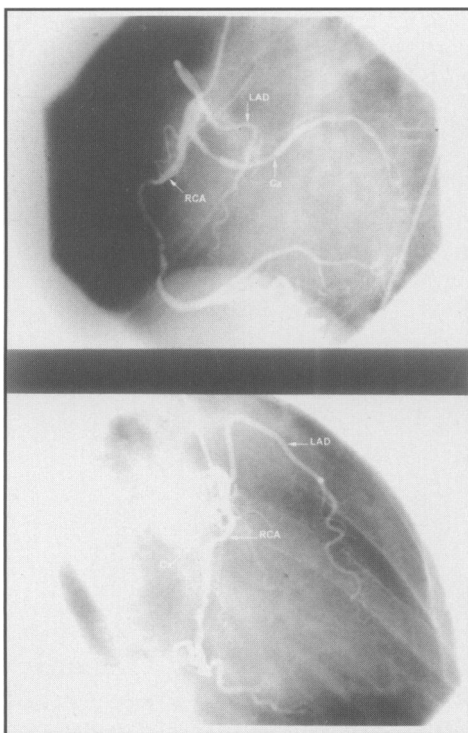


Fig 2. Single right coronary. (a) Left Anterior Oblique projection. (b) Right Anterior Oblique projection. Cx=circumflex, LAD=left anterior descending, RCA=right coronary artery.

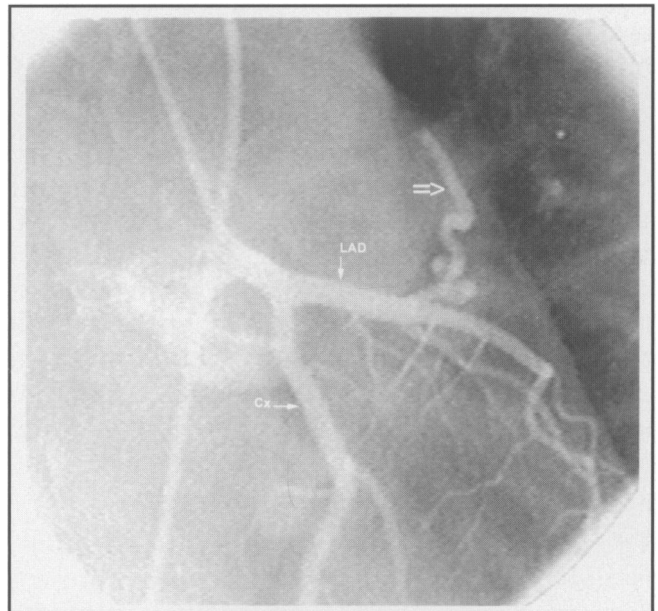

Fig 4. Left anterior descending coronary artery to pulmonary artery fistula. Right Anterior Oblique projection. The large arrow shows an abnormal vessel arising from the left anterior descending coronary artery. On the dynamic images it was clear that this vessel communicated with the pulmonary artery. Cx=circumflex, LAD=left anterior descending.

although on aortography it appeared to have a posterior origin.

Six patients had an abnormal distal connection; four of these were left anterior descending coronary artery to pulmonary artery fistulae [Figure 4].

DISCUSSION

Coronary artery anomalies are rare in adults. Most coronary artery anomalies are not haemodynamically significant and are found incidentally during coronary angiography. One should suspect the presence of a coronary artery anomaly if a myocardial region does not appear to be supplied by any visualised vessel or a vessel appears to cross the aorta and pulmonary artery at the level of the aortic root on left ventriculography or proximal aortic root injection in the right anterior oblique (RAO) projection. This latter appearance is seen with most anomalies of ectopic coronary artery origin from the contralateral sinus or artery.

Coronary angiography remains the gold standard in the diagnosis of coronary artery anomalies, as it is the only method of reliably documenting the course and distribution of the coronary arteries. Angiographic visualisation of the entire coronary circulation is of particular importance in preventing coronary trauma and ensuring optimal revascularisation in patients undergoing coronary artery bypass grafting.

Recent advances in interventional cardiology have resulted in a dramatic increase in the use of percutaneous procedures, often on an urgent basis, for the treatment of both unstable angina and myocardial infarction. The treatment of culprit lesions in coronary artery anomalies is a technical challenge to the cardiologist as early recognition of the anomalous artery is essential in order to minimize time to revascularisation and the procedure (angioplasty and/or stenting of the anomalous artery) itself may be difficult.

The early diagnosis of abnormal distal connections is also important as such patients often present with chest pain. Inappropriate treatment with potent vasodilators may result in a coronary steal phenomenon, thereby exacerbating symptoms, particularly in patients with a left anterior descending coronary artery to pulmonary artery fistula.

In our study we found an prevalence of 0.52% of coronary artery anomalies at angiography. We

acknowledge that our angiographic data are incomplete (diagnostic coding available in 79% of patients, and diagnostic validation was not feasible in two patients). However, we believe that our findings are a good reflection of the true angiographic prevalence of these anomalies. Anomalous circumflex arising from the right coronary sinus or the right coronary artery was the commonest coronary artery anomaly in our study. It appears that the range of coronary artery anomalies in the Northern Ireland population is similar to that reported in other angiographic series.^{1,2}

ACKNOWLEDGEMENTS

We wish to acknowledge the help and support of all the medical staff undertaking invasive procedures at the Regional Medical Cardiology Centre, Royal Victoria Hospital, Belfast, and the assistance of Margaret Bustard, Senior Systems Analyst, in the provision of data collection and database interrogation.

REFERENCES

1. Click R L, Holmes D R, Vlietstra R E, Kosinski A S, Kronmal R A. Anomalous coronary arteries: location, degree of atherosclerosis and effect on survival – a report from the Coronary Artery Surgery Study. *J Am Coll Cardiol* 1989; **13**: 531-7.
2. Chu E, Cheitlin M D. Diagnostic considerations in patients with suspected coronary artery anomalies. *Am Heart J* 1993; **126**: 1427-38.
3. Kardos A, Babai L, Rudas L, *et al*. Epidemiology of congenital coronary artery anomalies: a coronary arteriography study on a central European population. *Cathet Cardiovasc Diagn* 1997; **42**: 270-5.
4. Angelini P. Normal and anomalous coronary arteries: definitions and classification. *Am Heart J* 1989; **117**: 418-34.