

Received: 2019.06.16
Accepted: 2019.11.07
Published: 2020.01.12

Chromosome 1q Terminal Deletion and Congenital Glaucoma: A Case Report

Authors' Contribution:
Study Design A
Data Collection B
Statistical Analysis C
Data Interpretation D
Manuscript Preparation E
Literature Search F
Funds Collection G

BCEF 1 **Rakan AlSaad**
ABDE 1,2 **Jeylan ElMansoury**
DG 1,2 **Selwa A.F. AlHazzaa**
ACEG 1,2 **Qais S. Dirar**

1 College of Medicine, Alfaisal University, Riyadh, Saudi Arabia
2 Department of Ophthalmology, King Faisal Specialist Hospital and Research Center, Riyadh, Saudi Arabia

Corresponding Author: Qais S. Dirar, e-mail: qdirar@gmail.com
Conflict of interest: None declared

Patient: Female, 8-year-old
Final Diagnosis: Chromosome 1 q31 and q42.1 deletion with congenital glaucoma
Symptoms: Vision loss
Medication: —
Clinical Procedure: —
Specialty: Ophthalmology





Objective: Rare co-existence of disease or pathology
Background: This paper aims to highlight the presence of primary congenital glaucoma (PCG) in a patient with chromosome 1 q31 and q42.1 deletion of the distal long arm. The characteristic combination of phenotypic features in this deletion include dysmorphic features, psychomotor retardation and neurological signs; however, PCG has never been recognized as part of these features before.

Case Report: This is a case of an 8-year-old female with chromosome 1 q31 and q42.1 deletion with congenital glaucoma since birth. She was found to have bilateral buphthalmos and large cloudy corneas and was also unable to follow or fixate in any directional gaze with either eye. Family history was negative for congenital glaucoma and both parents are healthy and non-consanguineous. Karyotyping showed chromosome 1 microdeletion, 46, XX, del (1) (q31q42.1) on high resolution G-banding. Further genetic testing showed no mutations in the *CYP11B1* gene.

Conclusions: In summary, we describe a rare presentation of congenital bilateral glaucoma in the context of chromosome 1 q31 and q42.1 deletion. This clinical manifestation is uncommon when compared with that of other subsets of chromosome 1 deletions. Thus, we emphasize the need to explore factors contributing to the development of PCG in patients with chromosomal 1 deletion.

MeSH Keywords: Chromosome Deletion • Congenital Abnormalities • Glaucoma

Full-text PDF: <https://www.amjcaserep.com/abstract/index/idArt/918128>

 1675   2  17



Background

Chromosome 1 deletion of the distal long arm is rarely reported but it causes a characteristic combination of multiple phenotypic abnormalities including dysmorphic features, psychomotor retardation and neurologic signs [1]. Clinical features usually include craniofacial dysmorphism (microcephaly, up slanting palpebral fissures, epicanthal folds, deep seated eyes, short broad nose, micrognathia, short neck, low set ears), growth and mental retardation (speech delay), central nervous system anomalies (hypoplasia and agenesis of corpus callosum, hypotonia, seizures and epilepsy), gastrointestinal (dysphagia) and occasional genitourinary (vesicoureteral reflux) and/or cardiac (atrial and ventricular septal defects, tetralogy of Fallot) malformations [2]. Ophthalmologic findings are not part of the clinical features of this chromosome deletion.

Here, we present a case of chromosome 1 q31 and q42.1 deletion with congenital glaucoma. This case shares similar clinical features with the previously mentioned chromosome 1 deletion of the distal long arm entity, albeit with the addition of congenital glaucoma bilaterally. The available limited literature is lacking regarding the role of glaucoma in cases of chromosome 1 deletions of the distal long arm. To the best of our knowledge, this is the first case of bilateral congenital glaucoma in the context of chromosome 1 q31 and q42.1 deletion.

Case Report

This is a case of an 8-year-old female, referred to the Ophthalmology Department at King Faisal Specialist Hospital and Research Center (KFSH&RC) in Saudi Arabia, as a case of congenital glaucoma since birth, that was associated with microcephaly, unilateral cleft lip and palate, tetralogy of Fallot, and vesicoureteral reflux.

She was a product of spontaneous vaginal delivery, with a birthweight of 2.15 kg, length 42.5 cm and head circumference of 29.5 cm. Karyotyping showed chromosome 1 microdeletion, 46, XX, del (1) (q31q42.1) on high resolution G-banding, namely the Giemsa Trypsin Wright (GTW) technique [3]. A total of 20 metaphases were examined, 5 metaphases analyzed, and 2 metaphases karyotyped. And there are about 285 genes contained in both deleted segments as per the NCBI Genome Data Viewer [4].

Family history was negative for congenital glaucoma, both parents are healthy and non-consanguineous. All 3 of her siblings were free of disease except 1 sister who had history of vesicoureteral reflux surgery.

This patient was born flat and cyanotic with multiple congenital anomalies and was admitted to the neonatal intensive care unit (NICU) for further management. She was vitally stable for her age; heart rate: 150 beats per minute, blood pressure: 85/50 mmHg, temperature: 36.6°C. She had multiple dysmorphic facial features which include microcephaly, proptosis, cloudy corneas, short broad nose, unilateral cleft lip and palate, short neck and low set ears (Figure 1A). Chest examination was unremarkable and cardiovascular examination revealed a systolic ejection murmur. Neurologically, she had hypotonia with decreased reflexes and her extremities revealed clinodactyly with dysplastic nails. She was also started on phototherapy as her metabolic panel showed high indirect bilirubin of 10.98 mg/dL. The rest of her laboratory results were within the normal range. Head ultrasound (US) showed normal anterior fontanelle with a grossly unremarkable head, and a follow up brain magnetic resonance imaging (MRI) was unremarkable.

At the age of 8 days, Pediatric Ophthalmology was consulted for evaluation. She was found to have congenital glaucoma with bilateral buphthalmos and large cloudy corneas (Figure 1B). She was also unable to follow or fixate in any directional gaze with either eye. Her corneas had a diameter of 13.5 mm in the right eye (OD) and 14 mm in the left eye (OS). The intraocular pressure (IOP) was 35 mmHg OD and 37 mmHg OS.

Bilateral glaucoma surgery was recommended to preserve the vision in both eyes. However, cardiology clearance was needed due to the patient's cardiac anomaly. Thus, we started her on a topical carbonic anhydrase inhibitor and a beta blocker.

Eight months later, the patient received cardiology clearance for the surgery but her IOP was persistently elevated despite the use of drops. Vision remained poor and she was still unable to follow or fixate.

Deep sclerectomy or cyclophotocoagulation were suggested as a palliative procedure to alleviate the pain associated with the high IOP, and the patient was referred to another hospital to undergo the procedures as they were not provided at KFSH&RC.

The patient was lost to follow-up for 4 years as she was being followed in more than one hospital. She returned to KFSH&RC with severe buphthalmos having underwent right bilateral tarsorrhaphy and left lateral tarsorrhaphy (Figure 1B). She could not follow or fixate with the right eye, which became atrophic. The left eye remained buphthalmic with severe exposure keratitis for which she is receiving lubricants and antibiotics. The anterior and posterior segments could not be appreciated because of the corneal opacity. Parents refused any further surgeries offered to them.

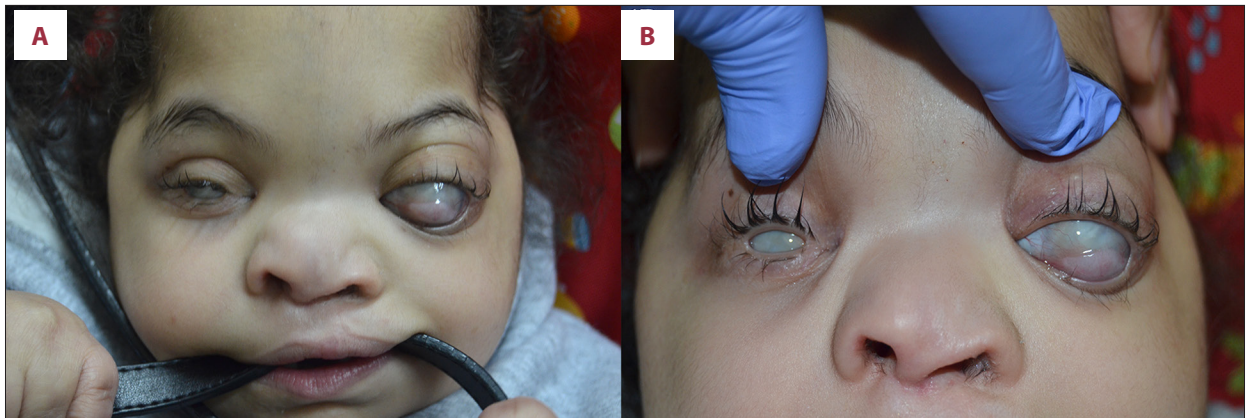

Figure 1. Facial features. (A) Presence of microcephaly, short broad nose, corrected unilateral cleft lip and palate and short neck. (B) Eyes showing bilateral buphthalmos and total corneal opacification. Right eye status post right medial and lateral tarsorrhaphy and phthisis bulbi. Left eye lateral tarsorrhaphy and anterior staphyloma.

A year later, on follow-up the patient's mother reported that glaucoma surgeries were done in a different hospital despite the patient's late age, and with no outcome. She presented with OD phthisis bulbi, OS anterior staphyloma, and increased bilateral buphthalmos (Figure 1B). The patient was offered to undergo an enucleation, but the parents refused. A B-scan ultrasonography was done and showed OD total retinal detachment without endophthalmitis and OS buphthalmos with exposure keratopathy.

Discussion

Chromosome 1q deletion is rarely reported in the medical literature and its phenotypic features include severe mental retardation, growth delay, cerebral anomalies, and early onset of seizures and epilepsy. It is often accompanied with arched eyebrows, a broad nose, epicanthal folds, micrognathia, short neck, low-set ears as well as cardiac, gastrointestinal and genitourinary defects [5]. Although ophthalmologic findings do not seem to be part of this deletion, our patient happened to have a bilateral congenital glaucoma, which could probably be associated with the combination of both *loci* deletions (1q31, 1q42.1) occurring simultaneously (Figure 2).

In our case, the patient was diagnosed by the Ophthalmology Department at KFSH&RC on the 8th day of life as a case of bilateral congenital glaucoma. The family history was unremarkable for any ophthalmologic findings and the parents were non-consanguineous. On clinical examination, congenital glaucoma causing buphthalmos was identified and she was not able to follow or fixate in any directional gaze in either eye. Finally, head US and brain MRI showed no abnormalities contrary to the usual presence of central nervous system anomalies in chromosome 1q deletions [5]. Considering the persistent inability to follow or fixate gaze in both eyes up to this point in

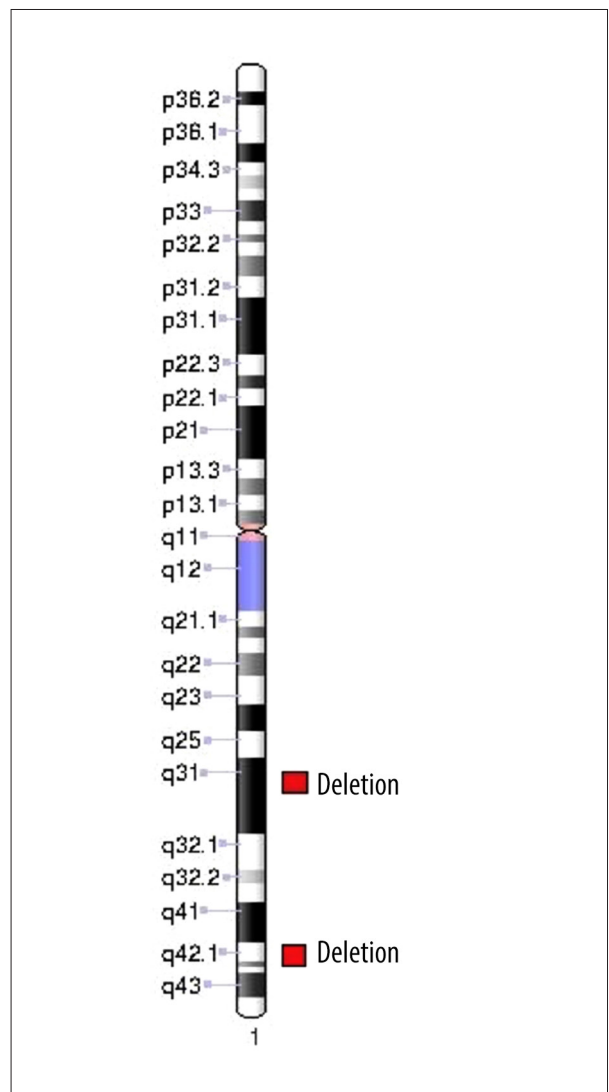


Figure 2. Schematic diagram of chromosome 1 q31 and q42.1 deletion location [17].

time suggests vision deterioration. The presence of primary congenital glaucoma (PCG) and the absence of central nervous system anomalies does not match with the typical chromosome 1q deletion phenotypes depicted in the literature.

PCG is defined as glaucoma occurring within the first 3 years of life as a result of isolated trabeculodysgenesis. It is relatively common in Saudi Arabia due to the high prevalence of consanguinity among Saudi families [6]. In particular, the *CYP1B1* gene was found to be associated with bilateral PCG in consanguineous Saudi Arabian families [7]. Despite the prevalence of PCG due to the *CYP1B1* gene mutation, the patient had no mutations after sequencing the full coding exons and the exon-intron boundaries of the *CYP1B1* gene. A similar finding was reported in a Saudi girl, who had PCG with a negative *CYP1B1* gene mutation, however, she had a deletion in a different chromosome as well as duplications [8]. Decreased levels of antithrombin III along with PCG was previously reported in the literature in the context of interstitial chromosome 1q deletion but this is not present in our patient [9].

One variant of chromosome 1 abnormalities, the trisomy 1q syndromes, particularly 1q41-qter duplications share some non-ophthalmologic clinical features with our case. Although previously reported cases of 1q41 duplication demonstrated that they share major phenotypic manifestations (developmental delay, low set ears, macrocephaly, heart murmurs), it was also suggested that phenotype variation in said duplications might be due to subatomic size differences in the segments involved. Additionally, it was reported that proximal chromosome 1q deletions had more severe malformations, reduced life expectancy and more mental retardation, while distal chromosome 1q duplications had better outcomes for the same variables [10]. Another case of 1q41-qter duplication reported infantile congenital glaucoma associated with partial monosomy 9p and it was the second of its kind in the literature. However, partial monosomy 9p on its own causing congenital glaucoma has not been reported in the literature and no direct link with partial monosomy 9p has been elucidated yet. This could suggest there being a level of interplay between 1q41-qter and partial monosomy 9p in the development of congenital glaucoma, which could be extrapolated to an interplay between chromosome 1 q31 and q42.1 in our case [11].

It is worth noting that clinical manifestations of the chromosome 1q deletion in our case (q31, q42.1), resemble those of a chromosome 1p36 deletion, which is one of the most common chromosome deletion syndromes [12]. Chromosome 1p36 deletion is generally characterized by a large anterior fontanel, low set ears, mental retardation, developmental delay, seizures, hypotonia, eye/vision problems, hearing impairment and 5th finger clinodactyly [13]. The most common eye/vision problems were strabismus and refractive errors, while glaucoma features have never been reported in this syndrome before [14,15]. Whereas the most common type of hearing impairment was sensorineural hearing loss [14,16]. The case does not have any form of visual impairment or seizures, which occur in approximately half of patients [14].

Conclusions

In summary, we describe a rare presentation of congenital bilateral glaucoma in the context of chromosome 1 q31 and q42.1 deletion. This clinical manifestation is uncommon when compared with that of other subsets of chromosome 1 deletions. Despite being part of a geographic location with high rates of PCG due to *CYP1B1* gene mutation [4], the case tested negative for *CYP1B1* mutation. Thus, we emphasize the need to explore factors contributing to the development of PCG in patients with chromosomal 1 deletion who test negative for *CYP1B1* mutations.

Acknowledgment

We thank Ms. Doaa Alshammari, Ophthalmic Photographer, Ophthalmology Department, King Faisal Specialist Hospital and Research Center.

Department and Institution where work was done

Department of Ophthalmology, King Faisal Specialist Hospital and Research Center, Riyadh, Saudi Arabia

Conflicts of interest

None.

References:

1. Arai E, Nishimura S, Tamura K et al: Chromosome 1q terminal deletion resulting from *de novo* translocation with an acrocentric chromosome. *Jpn J Hum Genet*, 1994; 39(4): 433–37
2. Van Linthout C, Emonard V, Gatot JS et al: Prenatal diagnosis of a terminal chromosome 1 (q42-q44) deletion: Original case report and review of the literature. *Facts Views Vis Obgyn*, 2016; 8(2): 101–3
3. Moore CM, Best RG: Chromosome preparation and banding. *Encyclopedia of Life Sciences* [Internet]. 2001 April [cited 2019 Sep 16]. Available from: <https://onlinelibrary.wiley.com/doi/full/10.1038/npg.els.0001444>
4. NCBI's Genome Browser – Genome Data Viewer; c2019 [cited 2019 Sep 16]. Available from: <https://www.ncbi.nlm.nih.gov/genome/gdv/>
5. Wagner N, Guengoer E, Mau-Holzmann U et al: Prenatal diagnosis of a fetus with terminal deletion of chromosome 1 (q43) in first-trimester screening: Is there a characteristic antenatal 1q deletion phenotype? A case report and review of the literature. *Fetal Diagn Ther*, 2011; 29(3): 253–56
6. Badeeb OM, Micheal S, Koenekoop RK et al: CYP1B1 mutations in patients with primary congenital glaucoma from Saudi Arabia. *BMC Med Genet*, 2014; 15(1): 109
7. Bejjani BA, Stockton DW, Lewis RA et al: Multiple CYP1B1 mutations and incomplete penetrance in an inbred population segregating primary congenital glaucoma suggest frequent *de novo* events and a dominant modifier locus. *Hum Mol Genet*, 2000; 9(3): 367–74
8. Abu-Amero KK, Kondkar AA, Khan AO: Molecular karyotyping of a dysmorphic girl from Saudi Arabia with CYP1B1-negative primary congenital glaucoma. *Ophthalmic Genet*, 2016; 37(1): 98–101
9. Okamoto N, Hatsukawa Y, Shiraishi J et al: Chromosome 1q deletion and congenital glaucoma. *Pediatr Int*, 2005; 47(4): 477–79
10. Kulikowski LD, Bellucco FT, Nogueira SI et al: Pure duplication 1q41-qter: Further delineation of trisomy 1q syndromes. *Am J Med Genet A*, 2008; 146A(20): 2663–67
11. Verbraak FD, Pogány K, Pilon JW et al: Congenital glaucoma in a child with partial 1q duplication and 9p deletion. *Ophthalmic Paediatr Genet*, 1992; 13(3): 165–70
12. 1p36 deletion syndrome; c2018 [cited 2018 Dec 20] Available from: https://www.orpha.net/consor/cgi-bin/OC_Exp.php?Lng=GB&Expert=1606
13. Shapira SK, McCaskill C, Northrup H et al: Chromosome 1p36 deletions: The clinical phenotype and molecular characterization of a common newly delineated syndrome. *Am J Hum Genet*, 1997; 61(3): 642–50
14. Heilstedt, HA, Ballif BC, Howard LA et al: Physical map of 1p36, placement of breakpoints in monosomy 1p36, and clinical characterization of the syndrome. *Am J Hum Genet*, 2003; 72(5): 1200–12
15. Gajecka M, Mackay KL, Shaffer LG: Monosomy 1p36 deletion syndrome. *Am J Med Genet C Semin Med Genet*, 2007; 145C(4): 346–56
16. Battaglia A, Hoyme HE, Dallapiccola B et al: Further delineation of deletion 1p36 syndrome in 60 patients: A recognizable phenotype and common cause of developmental delay and mental retardation. *Pediatrics*, 2008; 121(2): 404–10
17. Genome Decoration Page; c2019 [cited 2019 Jan 30]. Available from: <https://www.ncbi.nlm.nih.gov/genome/tools/gdp/>