

Case Report

A Rare Case of Supinator Intramuscular Myxoma with Encasement of the Posterior Interosseous Nerve

Chiao Yee Lim , Suryasmi Duski , and Ping Ching Chye

Department of Orthopaedic Surgery, Kuala Lumpur Hospital, 50586 Kuala Lumpur, Malaysia

Correspondence should be addressed to Chiao Yee Lim; chiaoyee@hotmail.com

Received 11 May 2019; Revised 11 July 2019; Accepted 18 July 2019; Published 14 August 2019

Academic Editor: Johannes Mayr

Copyright © 2019 Chiao Yee Lim et al. This is an open access article distributed under the Creative Commons Attribution License, which permits unrestricted use, distribution, and reproduction in any medium, provided the original work is properly cited.

Intramuscular myxomas are rare, benign mesenchymal tumors. Tumor location in the forearm is very rare among all the intramuscular myxomas. To the best of our knowledge, there were two cases of supinator intramuscular myxoma reported in the literature, and we intend to report the third case of supinator myxoma with encasement of the posterior interosseous nerve (PIN). A 67-year-old lady presented with history of left proximal forearm swelling for the past 5 years. Magnetic resonance imaging showed a lobulated multiseptated lesion seen within left supinator muscle, which was hyperintense on T2-weighted images (T2WI) and hypointense on T1-weighted images (T1WI), with peripheral enhancement post contrast. The tissue diagnosis of myxoma was confirmed via an open biopsy. She underwent en bloc resection of the tumor. The PIN was encased by the tumor; it was preserved and carefully released from the tumor. The nerve sheath served as an excision margin. In conclusion, we present a rare case of an intramuscular myxoma in the supinator muscle. In view of the location, extra attention should be paid during excision surgery to locate the PIN and to avoid damaging the surrounding structures.

1. Introduction

Intramuscular myxomas are rare, benign mesenchymal tumors in the musculoskeletal system, in which the primitive mesenchymal cells lose their capacity to produce collagen but instead have excess hyaluronic acid and immature collagen production [1]. Tumor location in the forearm is very rare among all the intramuscular myxomas. To the best of our knowledge, there were two cases of supinator intramuscular myxoma reported in the English literature [2, 3], and we intend to report the third case of supinator myxoma with encasement of the posterior interosseous nerve (PIN).

2. Case Report

A 67-year-old lady, with underlying type 2 diabetes mellitus, presented with the history of left proximal forearm swelling which had progressively increased in size for the past 5 years. There was no pain and no numbness or weakness of her left wrist or fingers. She denied any past history of trauma, infection, fever, or constitutional symp-

oms. Physical examination revealed an ill-defined swelling at the radial border of the left proximal forearm. It was nontender, was not attached to overlying skin but fixed to the underlying structures, had a smooth surface, and was firm to hard in consistency.

Plain radius and ulna radiographs did not show any scalloping, osteolysis, pathological fracture, or soft tissue calcification. Magnetic resonance imaging (MRI) showed a lobulated multiseptated lesion seen within left supinator muscle, which showed hyperintense signal on T2-weighted images (T2WI) and hypointense on T1-weighted images (T1WI), with peripheral enhancement post contrast (Figures 1(a)–1(e)). The PIN was reported as being encased/impinged by the tumor. An open biopsy was performed, and histopathological examination confirmed the diagnosis of myxoma.

She was counselled for tumor excision with possible risk of postoperative loss of PIN function informed. The patient was fully aware about the possibility of PIN injury and consented for the surgery. The patient underwent en bloc resection of her left supinator intramuscular myxoma under general anesthesia. A curvilinear longitudinal skin incision

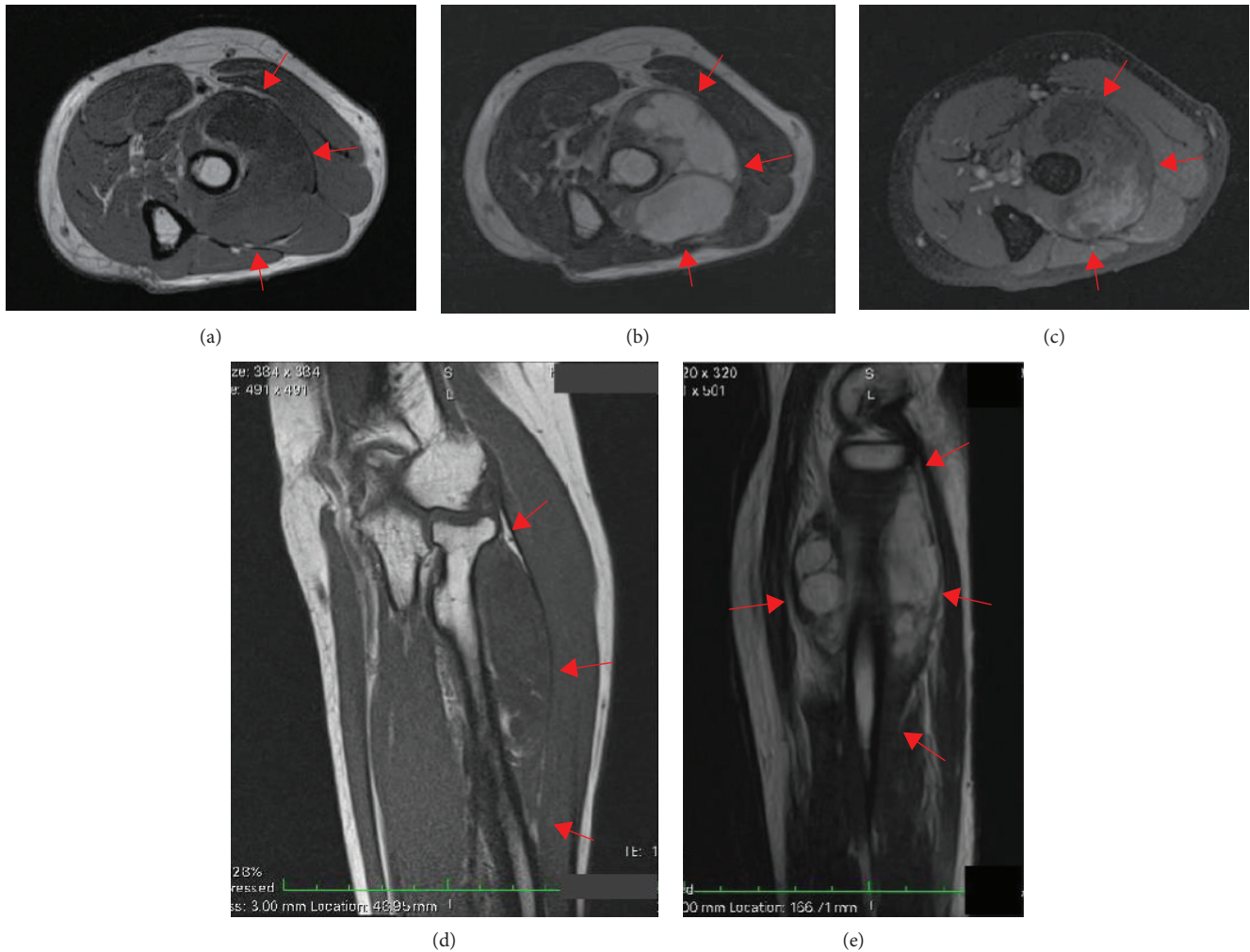


FIGURE 1: Magnetic resonance imaging (MRI) showed a lobulated multiseptated lesion seen within left supinator muscle as delineated by the red arrows, which showed a hyperintense signal on T2-weighted images (T2WI) (b, e) and hypointense on T1-weighted images (T1WI) (a, d), with peripheral enhancement post contrast (c).

was made overlying the tumor mass. A surgical plane was attained between the extensor carpi radialis brevis and extensor digitorum communis to reach the tumor mass. The tumor was noted to be a well-encapsulated cystic, solid, well-defined supinator intramuscular mass which encroached the proximal radius. The PIN was encased by the tumor (Figure 2). The PIN was carefully released from the tumor under loupe magnification. The excised tumor measured at $5.5 \times 4.5 \times 2.5 \text{ cm}^3$. Clinical examination postoperatively showed no wrist or finger drop. Her recovery was uneventful. Final histopathological examination of the excised tumor confirmed the diagnosis of intramuscular myxoma with hypocellular and loosely arranged spindle to stellate cells set within a copious myxoid stroma. The cells appeared bland looking and displayed coarse chromatin, inconspicuous nucleoli, and scanty cytoplasm. No mitotic activity was observed. At the time of this report, the patient is currently well at 6 months post surgery; we will continue to follow up on her with 6-monthly appointment.

3. Discussion

Intramuscular myxoma was first delineated as a definite clinicopathologic lesion by Enzinger in 1965 [4]. The incidence of intramuscular myxoma varies between 0.10 and 0.13 per 100,000 [2, 5]. The majority of lesions present in the fourth to sixth decade of life with slight female predominance [2, 5]. It typically involves large muscle groups in the thigh, gluteal region, shoulder, and upper arm [6]. Intramuscular myxoma occurs as a solitary entity, less frequently in association with fibrous dysplasia of the bone (Mazabraud's syndrome), or as a part of the McCune-Albright syndrome (polyostotic fibrous dysplasia, café-au-lait spots, and endocrine hyperfunction) [7]. In these syndromes, multiple myxomas are encountered more often [7].

On T2-weighted MRI, a perilesional fat rind and increased signal intensity in the adjacent muscle tissue may be observed in intramuscular myxoma [6]. On T1-weighted MRI, the tumor has a low signal intensity [6].

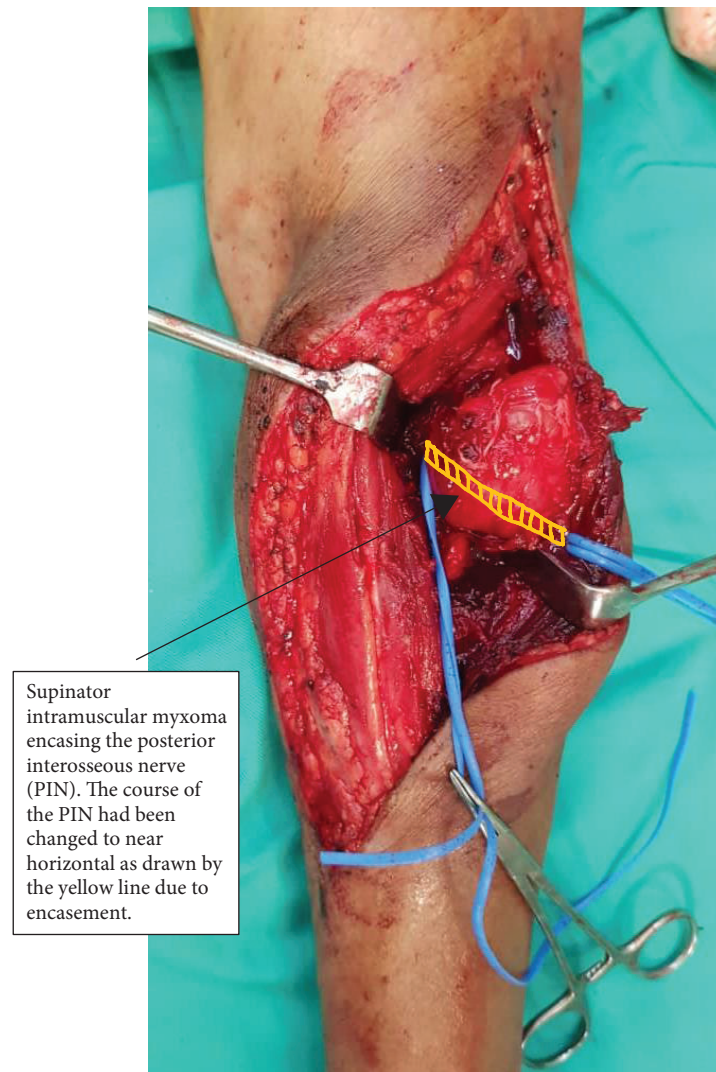


FIGURE 2: Intraoperative photograph showed the left supinator intramuscular myxoma encasing the posterior interosseous nerve (PIN). The course of the PIN had been changed to near horizontal as drawn by the yellow line due to encasement.

On contrast-enhanced MRIs, myxomas usually demonstrate a mild to moderate contrast enhancement. Cystic areas may be observed in >50% of all lesion with a thin peripheral and septal enhancement pattern [6, 8–11]. However, intramuscular myxoma has nonspecific clinical symptoms and radiologic findings that may be confused with other soft tissue tumors; microscopic examination is required to confirm the diagnosis.

To the best of our knowledge, this is the third case of supinator intramuscular myxoma reported in the English literature. The first case was reported by Kursumovic et al. [2]; the patient presented with PIN palsy after bowel surgery associated with intramuscular myxoma of the supinator muscle. Their patient underwent tumor excision 3 months after the symptom onset, and intraoperatively, the PIN was found alongside of the tumor and was compressed and flattened against the distal rim of the supinator muscle [2]. Nonaka et al. reported the second case of intramuscular myxoma in the supinator muscle with transient postoperative

PIN palsy due to soft tissue retraction during the excision surgery [3]. Their patient had complete PIN function recovery at 3 months after the surgery [3].

Our patient had a relatively large supinator intramuscular tumor (the excised mass measured at $5.5 \times 4.5 \times 2.5 \text{ cm}^3$) which encased the PIN. The preoperative biopsy had confirmed the benign nature of the tumor; thus, during the surgery, the PIN was preserved and carefully released from the tumor. The nerve sheath served as an excision margin.

In conclusion, we described a rare case of an intramuscular myxoma in the supinator muscle. The treatment of the tumor is en bloc excision. However, in view of the location, extra attention should be paid to locate the PIN and to avoid damaging the surrounding structures. Recurrence after intramuscular myxoma excision is uncommon [12]; thus, we should avoid damaging any important neurovascular structures by overzealous attempt to remove all tumor tissues.

Conflicts of Interest

The authors declare that there is no conflict of interest regarding the publication of this paper.

References

- [1] V. Yaligod and S. M. Ajoy, "Intramuscular myxoma – a rare tumor," *Journal of Orthopaedic Case Reports*, vol. 3, no. 4, pp. 41–44, 2014.
- [2] A. Kursumovic, G. Mattiassich, and S. Rath, "Delayed diagnosed posterior interosseous nerve palsy due to intramuscular myxoma," *BMJ Case Reports*, vol. 2013, no. 1, article bcr2012008332, 2013.
- [3] T. Nonaka, M. Sonohata, S. Takeshita, Y. Oba, Y. Fujii, and M. Mawatari, "Intramuscular myxoma in the supinator muscle with transient postoperative posterior interosseous nerve palsy: a case report," *The Open Orthopaedics Journal*, vol. 12, no. 1, pp. 353–357, 2018.
- [4] F. M. Enzinger, "Intramuscular myxoma: a review and follow-up study of 34 cases," *American Journal of Clinical Pathology*, vol. 43, no. 2, pp. 104–113, 1965.
- [5] N. Ozbek, M. Danaci, B. Okumus, B. Gursel, S. Cakir, and N. K. F. Dabak, "Recurrent intramuscular myxoma: review of the literature, diagnosis and treatment options," *Turkish Journal of Cancer*, vol. 36, pp. 75–78, 2006.
- [6] Y. Baltu, Ş. M. Arikan, U. C. Dölen, H. Uzun, B. İ. Alkan, and O. Aydin, "Intramuscular myxoma: clinical and surgical observation notes on eleven cases," *International Orthopaedics*, vol. 41, no. 4, pp. 837–843, 2017.
- [7] N. A. Darlis, A. V. Korompilias, A. S. Skopelitou, K. A. Petropoulou, and P. N. Soucacos, "Soft tissue mass in the proximal forearm of a 17-year-old girl," *Clinical Orthopaedics and Related Research*, vol. 437, pp. 265–270, 2005.
- [8] M. D. Murphey, G. A. McRae, J. C. Fanburg-Smith, H. T. Temple, A. M. Levine, and A. J. Aboulaflia, "Imaging of soft-tissue myxoma with emphasis on CT and MR and comparison of radiologic and pathologic findings," *Radiology*, vol. 225, no. 1, pp. 215–224, 2002.
- [9] L. W. Bancroft, M. J. Kransdorf, D. M. Menke, M. I. O'Connor, and W. C. Foster, "Intramuscular myxoma," *American Journal of Roentgenology*, vol. 178, no. 5, pp. 1255–1259, 2002.
- [10] A. Luna, S. Martinez, and E. Bossen, "Magnetic resonance imaging of intramuscular myxoma with histological comparison and a review of the literature," *Skeletal Radiology*, vol. 34, no. 1, pp. 19–28, 2005.
- [11] J. M. Petscavage-Thomas, E. A. Walker, C. I. Logie, L. E. Clarke, D. M. Duryea, and M. D. Murphey, "Soft-tissue myxomatous lesions: review of salient imaging features with pathologic comparison," *Radiographics*, vol. 34, no. 4, pp. 964–980, 2014.
- [12] G. P. Nielsen, J. X. O'Connell, and A. E. Rosenberg, "Intramuscular myxoma: a clinicopathologic study of 51 cases with emphasis on hypercellular and hypervascular variants," *The American Journal of Surgical Pathology*, vol. 22, no. 10, pp. 1222–1227, 1998.