

CORONARY ARTERY DISEASE

Editor's Choice

Origin of the Right Coronary Artery from the Opposite Sinus of Valsalva in Adults: Characterization by Intravascular Ultrasonography at Baseline and After Stent Angioplasty

Paolo Angelini,^{1,2*} MD, Carlo Uribe,² MD, Jorge Monge,² MD, Jonathan M. Tobis,³ MD, MacArthur A. Elayda,⁴ MD, PhD, and James T. Willerson,¹ MD

Objectives: We attempted to characterize the anatomy, function, clinical consequences, and treatment of right-sided anomalous coronary artery origin from the opposite side (R-ACAOS). **Background:** Anomalous aortic origin of a coronary artery is a source of great uncertainty in cardiology. A recent study by our group found that ACAOS had a high prevalence (0.48%) in a general population of adolescents. **Methods:** Sixty-seven consecutive patients were diagnosed with R-ACAOS according to a new definition: ectopic right coronary artery (RCA) with an intramural proximal course. We used intravascular ultrasonograms of the RCA to quantify congenital stenosis (in patients with potentially serious clinical presentations), and we correlated these measurements with clinical manifestations. **Results:** All patients had some proximal intramural stenosis (mean 50%, range 16–83% of the cross-sectional area). Forty-two patients (62%) underwent stent-percutaneous coronary intervention (PCI) of R-ACAOS because of significant symptoms, positive stress tests, and/or significant stenosis. Stent-PCI was successful in all cases and correlated with improved symptoms at >1-year follow-up in 30 patients (71%) who were available for clinical follow-up. No ACAOS-related deaths occurred. The in-stent restenosis rate was 4/30 (13%) at a mean follow-up time of 5.0 years. **Conclusions:** This preliminary, but large and unprecedented observational study shows that cases angiographically identified as R-ACAOS universally feature an intramural aortic course but only occasionally severe stenosis on resting IVUS imaging. Our data suggest that stent-PCI with IVUS monitoring ameliorates patients' presenting symptoms. © 2015 Wiley Periodicals, Inc.

Key words: coronary vessel anomalies; coronary imaging; coronary pathophysiology; catheter-based coronary interventions: stents

Additional Supporting Information may be found in the online version of this article.

¹Department of Cardiology, Texas Heart Institute, Houston, Texas

²Center for Coronary Artery Anomalies, Texas Heart Institute, Houston, Texas

³Department of Cardiology, David Geffen School of Medicine, University of California–Los Angeles, Los Angeles, California

⁴Department of Biostatistics and Epidemiology, Texas Heart Institute, Houston, Texas

Conflict of interest: Nothing to report.

The editor's choice video can be viewed online at http://onlinelibrary.wiley.com/journal/10.1002/ISSN1522_726X/homepage/cci_editor_s_choice_papers_and_videos.htm.

*Correspondence to: Paolo Angelini, MD; 6624 Fannin, Suite 2780, Houston, TX. E-mail: PAngelini@leachmancardiology.com

Received 11 March 2015; Revision accepted 21 May 2015

DOI: 10.1002/ccd.26069

Published online 14 July 2015 in Wiley Online Library (wileyonlinelibrary.com)

© 2015 The Authors. Catheterization and Cardiovascular Interventions. Published by Wiley Periodicals, Inc. This is an open access article under the terms of the Creative Commons Attribution-Non-Commercial License, which permits use, distribution and reproduction in any medium, provided the original work is properly cited and is not used for commercial purposes.

INTRODUCTION

Coronary artery anomalies (CAAs) exist in a relatively large portion of the general population, including 0.1–5.64% of catheterization laboratory patients. When the definition of CAA is narrowed to only “clinically important” anomalies [1–7] the prevalence is about 0.5–1% among catheterization laboratory patients. We recently proposed labeling a specific subtype of CAA as “anomalous coronary arteries originating from the opposite sinus” (ACAOS) [8], when an intramural proximal course can be documented, rather than any ectopic artery independent from its course (e.g., prepulmonic, retroaortic, intraseptal; SI-Fig. 1 and SI-Fig. 2) [3]. Several recent studies have recognized ACAOS as essentially the only type of CAA associated with intrinsic coronary stenosis that causes symptoms in adults, such as chest pain, syncope, and, less commonly, sudden cardiac arrest (SCA) or death (SCD) in the young [1–15]. Both the right and left coronary arteries (RCA and LCA) can have ACAOS (R-ACAOS and L-ACAOS) [6,7,16–18]. In our experience, ACAOSs angiographic prevalence is about 1.07% in cardiac catheterization laboratory patients [3], but it was about 0.7% in a large sample of schoolchildren who underwent screening by coronary magnetic resonance angiography for high-risk cardiovascular conditions (hr-CVC) to prevent SCD in the young [1]; we found ACAOS to be the most frequent hr-CVC, comprising 40% of all hr-CVCs, while the total prevalence of hr-CVC was 1.6% [19].

Although the intramural location of the proximal ectopic coronary artery has long been observed by pathologists [11–15], its stenotic effect has not been systematically measured by histologic cross-section, nor can it be identified angiographically. Interestingly, the notion of an intramural course inspired a popular surgical approach that involved “unroofing” the intramural segment to treat stenosis, even in the absence of objective evidence of stenosis [20–22].

Only anecdotal reports have described measuring R-ACAOS stenosis severity during the evaluation of ACAOS vessels [10,23–25]. No large study has yet evaluated the results of stent angioplasty in symptomatic patients with R-ACAOS. We hypothesized that by defining R-ACAOS as involving an intramural stenotic course, we could capture an entity with a specific and consistent pathophysiologic mechanism in ACAOS. Specifically, this study of R-ACAOS had two principal aims: first, to characterize ectopic vessels by intravascular ultrasonography (IVUS) and correlate stenosis severity with symptoms; second, to determine whether stent angioplasty could reduce symptoms in patients selected by clinical and IVUS criteria.

MATERIALS AND METHODS

Patients

We retrospectively reviewed data from all patients treated by our own group with the use of IVUS ($n = 67$, a small fraction of the total number of clinical cases of R-ACAOS seen at THI during 2000–2014). The study of IVUS and stents in R-ACAOS was approved by our institutional review board, which waived the requirement for specific informed consent for this study, because the target patients were equivalent to routine coronary artery disease patients with significant coronary ostial stenosis, symptoms, a positive stress test, or some combination of these factors.

Statistical Analysis

Categorical variables were expressed as frequencies and percentages, and continuous variables were expressed as mean \pm SD. Group differences in continuous pretreatment and post-treatment variables were evaluated with the paired *t* test or the non-parametric Wilcoxon’s signed rank test. Group differences in categorical variables were evaluated with the Fisher exact test. Pearson correlation was performed to evaluate the relationship between the cross-sectional diameter and percent area of stenosis (%AS). All analyses were performed with STATA SE 12 (StataCorp, College Station, TX). Probability values were two-sided; $P < 0.05$ was considered statistically significant.

Presentations

All R-ACAOS patients had a structured history and physical examination (Table I). Atypical chest pain was defined as having a variable onset and location and not being reproducible with exertion. A global, symptoms-based “Center for Coronary Artery Anomalies Functional Class” (CCAA-FC) scoring system and classification scheme was developed in an attempt to summarize the global impact of symptoms in patients with R-ACAOS (Table II). Treadmill nuclear testing was routinely pursued.

Catheterization/IVUS Data

Because of ectopic and tangential origin in R-ACAOS, selective catheterization with standard catheters is usually difficult. Soon after starting this project, we began using a novel, custom-made 6 Fr guiding catheter (manufactured by Cordis, Miami Lakes, FL; SI-Fig. 3) that features an anterior tilt at the distal 1 cm tip, enabling expeditious and consistent selective catheterization of the tangential ostium while providing enhanced support for subselectively advancing guide

wires, balloons, IVUS probes, and stents [16]. We used this catheter in 90% of cases.

The angiographic diagnosis of R-ACAOS required (1) ostial location within the left sinus of Valsalva, to the left of the anterior aortic commissure, and (2) proximal coursing in front of the anterior commissure of the aortic valve (preaortic; SI-Fig. 4).

An IVUS probe, either a 40 MHz rotational Atlantic (Boston Scientific, Natick, MA; distal profile 3.2 Fr) or a 20-MHz solid-state design (Volcano Corporation, Rancho Cordoba, CA; distal profile 3.5 Fr), was then advanced subselectively over a soft-tip coronary 0.014" guide-wire. Heparin anticoagulation was used as is customary for coronary interventions. Initially, IVUS imaging was obtained with the standard mechanical pull-back method (30 images/sec, at 0.5 mm/sec), starting more than 3 cm distal to the coronary ostium (Fig. 1; Video 1). Whenever possible, we used an IVUS device that could simultaneously display ultrasonographic and ECG signals (a feature no longer available in any

IVUS device) to show the timing of observed phasic changes in cross-sectional area (CSA). Percentage stenosis of the anomalous proximal segment was then calculated by the formula $(RA - SA)/RA \times 100$, where RA is reference area and SA is stenosis area. Eventually, while the IVUS probe was stationary at the site of maximal stenosis, imaging was also obtained, both at baseline (in all patients) and after cardiac output, heart rate, and blood pressure were increased (about 2.5 times above control) by infusing saline (500 mL over 15 min), atropine (0.5 mg), and dobutamine (10–40 $\mu\text{g}/\text{kg}/\text{min}$); this "SAD test" was performed in 18 cases. The maximal and minimal diameters at the most stenotic level were measured during systole and diastole, respectively. Generally, stent angioplasty of the proximal vessel was tentatively recommended to patients with a history of significant symptoms, potentially important CSA stenosis (>50–55% at baseline or >60–65% during the SAD test), a severely compressed short-axis diameter (see MFCC in Table III), or current involvement in strenuous athletics. Optical coherence tomography (OCT) was attempted in a few of the more recent cases (Fig. 2; SI-Fig. 5, Videos 2, 3). Only 4 of 8 such studies produced diagnostic-quality images[16] (the other 4 had inadequate guiding catheter seating or clearing of blood from the explored coronary segment). In a few of the initial cases, we took pressure wire measurements (fractional flow reserve) or performed acetylcholine testing (to rule out unusual spasticity).

When it was agreed that stenting was indicated, we aimed at covering the entire intramural segment with a single stent, guided by IVUS imaging (to attain a circular intramural CSA within the aortic media that would match the RCA's distal reference diameter). At the aortic end, the proximal stent was deployed about 2 mm proximal to the site of loss of a circular cross-section in the IVUS images. Clopidogrel 75 mg/day and aspirin 81 mg/day were prescribed for 1 year after the procedure (stents are usually evaluated for restenosis 1 year after intervention). The pre-intervention loading dose of clopidogrel changed over the years from 300 to 600 mg. Planned follow-up, to be completed at least 1 year after IVUS study or stenting,

TABLE I. Presenting Symptoms

Category	No. (%) of patients
Asymptomatic	8 (12%)
Chest pain	58 (87%)
Atypical	14 (24%)
Mild	3 (4%)
Moderate	8 (12%)
Severe	3 (4%)
Typical (CCS)	44 (76%)
I	5 (7%)
II	8 (12%)
III	21 (31%)
IV	10 (15%)
Shortness of breath (NYHA)	36 (54%)
I	15 (22%)
II	17 (25%)
III	4 (6%)
IV	0 (0)
Neurologic ischemic symptoms	24 (36%)
Dizziness	8 (12%)
Syncope	15 (22%)
Syncope causing collapse	1 (1%)

CCS, Canadian Cardiovascular Society; NYHA, New York Heart Association.

TABLE II. Global Severity of Symptom Burden in R-ACAOS, Quantified as Center for Coronary Artery Anomalies Functional Class (CCAA-FC)

Points for each category (0–3)	Chest pain		Shortness of breath	Neurologic symptoms
	Atypical	Typical		
0	None	I	I	None
1	Mild	II	II	Dizziness
2	Moderate	III	III	Brief syncope
3	Severe	IV	IV	Syncope with collapse

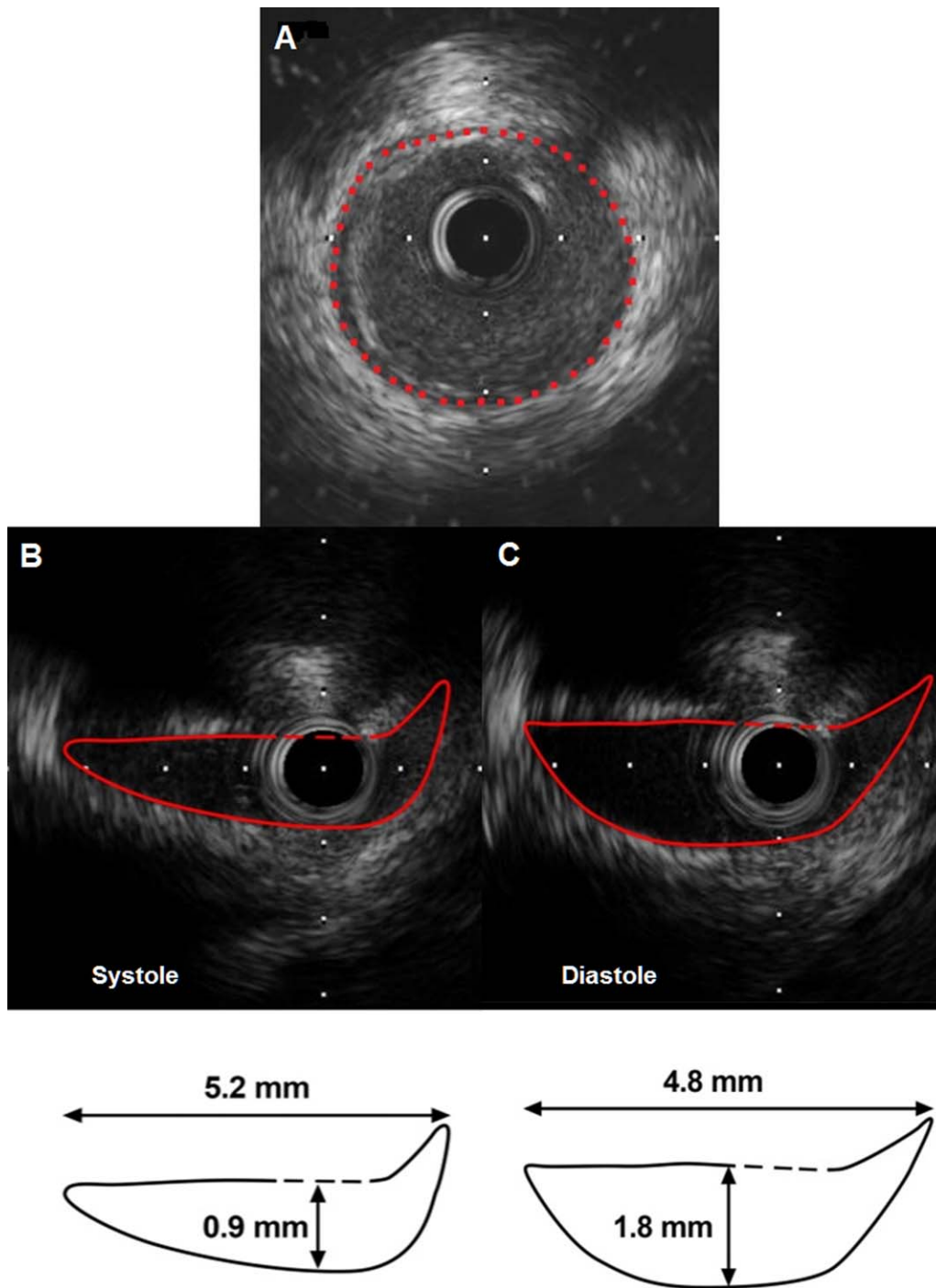


Fig. 1. Intravascular ultrasonograms in R-ACAOS. Distal reference cross-sectional area (CSA) is shown (A). After a solution of saline and blood (4:1 ratio in volume) was infused, images were obtained during systole (B) and diastole (C). The area and diameters are shown in the lower cartoons. Severity of stenosis is reported as a percentage, computed as the minimal CSA at the point of worst stenosis relative to the distal CSA; in this case, it was about 70%. [Color figure can be viewed in the online issue, which is available at wileyonlinelibrary.com.]

consisted of clinical evaluation and stress testing. Angiography and IVUS were repeated only if clinically indicated. Mortality was confirmed by searching

patients' Social Security numbers in State of Texas and national vital statistics records (last done during December 2014).

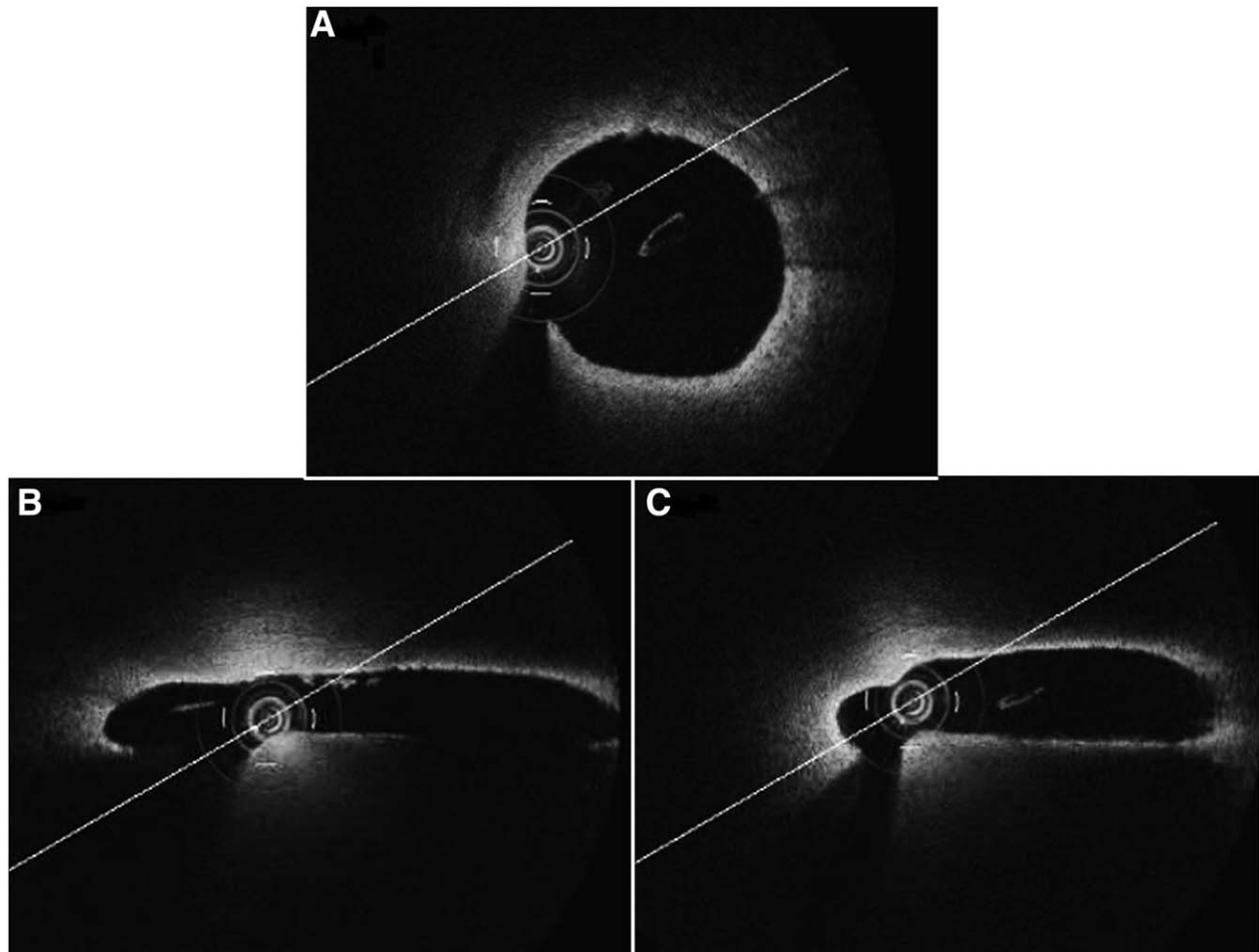


Fig. 2. Optical coherence tomography (OCT) images. With this modality, the inner lumen can be crisply imaged, but only if the operator can advance the guiding catheter selectively enough to eliminate most of the luminal blood, thereby enabling infrared laser imaging. (A) The reference distal cross-sectional area (CSA) is shown (diameters 3.8×4.0 mm; CSA 15.42 mm^2) for contrast with the proximal systolic (B) (diameters, 8.7×5.3 mm; CSA, 4.6 mm^2 ; 70% stenosis) and diastolic images (C) (diameters, 6.2×10.3 mm; CSA, 6.4 mm^2 ; 58% stenosis).

RESULTS

Clinical Presentation

Of the 67 patients (67% male; mean age 48 ± 12 years, range 12–73 years) seen at initial presentation (Table I), 58 (87%) reported chest pain, characterized as atypical in 14 (24%) and typical angina in 44 (76%). Thirty-six patients (54%) had shortness of breath. Twenty-four patients (36%) reported symptoms of transient cerebral ischemia. One patient had cardiac arrest and acute myocardial infarction complicating elective coronary artery bypass grafting done because of a positive nuclear stress test, without preoperative IVUS. Eight patients (13%) were asymptomatic but were involved in strenuous exercise programs from which they had been initially disqualified because of

R-ACAOS. Most medically treated patients used metoprolol (25–100 mg/day).

Imaging (Preliminary to IVUS)

The initial diagnosis of R-ACAOS was made with coronary computerized tomographic angiography in 24 patients (36%), 5 of whom underwent cardiac catheterization with IVUS to confirm the diagnosis. In the other 43 patients (64%), R-ACAOS was diagnosed by cardiac catheterization.

Stress Testing

No resting ECG features appeared to be distinctive of ACAOS. No significant arrhythmias were observed.

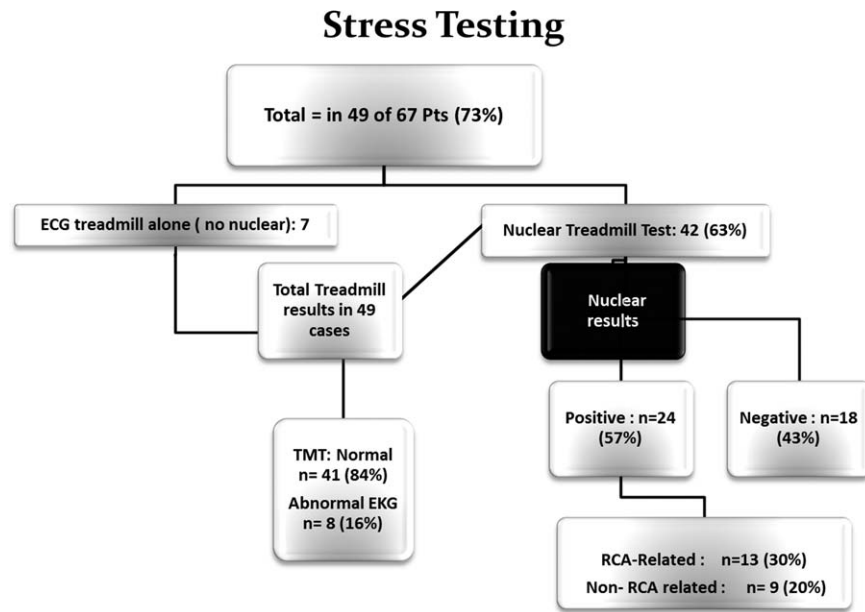


Fig. 3. Stress testing clinical evaluation studies for severity of ischemia. Note that, out of 67 patients, electrocardiographic treadmill test results were available for 49 patients and nuclear treadmill stress test results for 42 patients. ECG, electrocardiography; TMT, treadmill test; RCA, right coronary artery.

TABLE III. Scoring System for Morphofunctional Combined Class (MFCC)

Points for each category	Chest pain		Shortness of breath	Neurologic symptoms	%AS
	Atypical	Typical			
0	None	I	I	None	0–25%
1	Mild	II	II	Dizziness	26–50%
2	Moderate	III	III	Short-lasting syncope	51–75%
3	Severe	IV	IV	Syncope with trauma	76–100%

MFCC score for each patient is obtained by adding the appropriate points in each category, and grouping the patients in classes accordingly: A (0), B (1–3), C (4–6), D (7–9), and E (10–12). The severity of typical chest pain and shortness of breath are classified by using the Canadian Cardiovascular Society angina classification and the New York Heart Association Functional Classification, respectively. %AS, percent area of stenosis; see text.

Data from 49 patients (73%; Fig. 3) who underwent exercise tests were available for review (see results in Supporting Information Fig. 3).

Coronary Angiography

The RCA was dominant in 53 patients (79%), codominant in 4 (6%), and nondominant in 3 (5%). Five patients (7%) who had undergone previous coronary artery bypass grafting to treat R-ACAOS remained symptomatic and had nonfunctioning, atretic internal mammary artery grafts or (in 1 patient) thrombosed vein grafts. Fifteen patients (22%) had accompanying distal atherosclerotic coronary artery disease, for which, previously, four patients had undergone stent angioplasty and one had undergone coronary artery bypass grafting. In all patients, the proximal RCA

appeared to exit the aorta tangentially (improperly also called “at acute angle”), and in 14 patients (21%), the RCA ostium originated above the left sinotubular junction (by >5 mm). Two patients had direct origin of the RCA from the proximal left main trunk.

Intravascular Ultrasonography

In all patients, a coronary guidewire was passed successfully into the distal RCA. In only 1 case, the IVUS probe could not be advanced. The proximal RCA had an intramural course inside the aortic wall, and the worst stenosis was just distal to the ostium in all patients. In no patient (of any age) did IVUS reveal atherosclerotic plaques in the intramural proximal RCA. According to IVUS measurements (Table IV), the mean minimal diameter of the proximal intramural

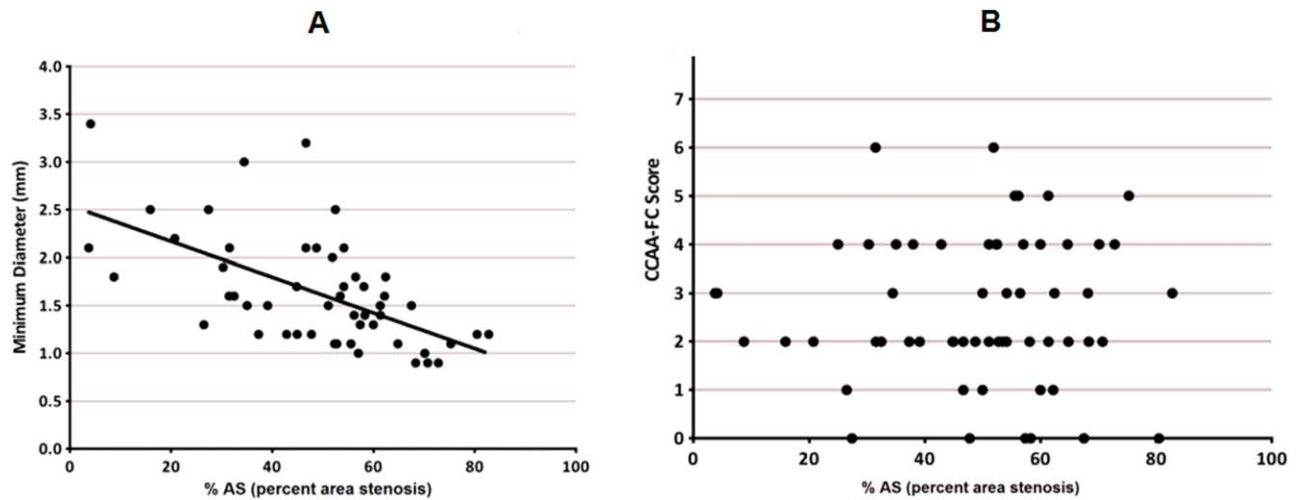


Fig. 4. (A) Correlation between short cross-sectional diameter and area (CSA) of stenosis. This figure shows a statistically significant moderate negative correlation ($r = -0.59$) between minimum diameter (mm) and percent area of stenosis (%AS). (B) Relationship between stenosis severity and symptoms, indicated by percent area of stenosis (%AS) and Center for Coronary Artery Anomalies functional class (CCAA-

FC) score, respectively. A Pearson correlation coefficient was computed to assess the relationship between the FC score and %AS. There was no statistically significant linear correlation between the two variables ($r = 0.01807$); see text, page 12.[Color figure can be viewed in the online issue, which is available at wileyonlinelibrary.com.]

ellipsoid-cross-section segment was 1.59 mm (range 0.9–4.8 mm). The reference distal vessel had a circular CSA with a mean diameter of 3.9 mm (range 2.4–6.0 mm). During systole, the mean CSA of the most stenotic intramural segment was 6.0 mm² (range 1.6–16.2 mm²), and the mean CSA of the reference distal vessel was 12.4 mm² (range 4.5–28.0 mm²). The resulting mean %AS was 50 ± 16% (with a wide range 16–83%). In the majority of our patients (mainly selected because they were more symptomatic than those excluded from intervention), the minimal cross-diameters clustered around 1.3 mm (84% of patients had a minimal diameter <1.8 mm; range 0.9–1.8 mm) (Fig. 4A and B).

Quantification of Severity: the Morphofunctional Combined Class

In order to quantify synthetically each patient’s symptomatic state and evidence of stenosis, we retrospectively adopted a morphofunctional combined classification (MFCC score, see Table III) that combines scores for the severity of each symptom and severity of IVUS stenosis. The mean score was 3.53 in the full cohort, 2.84 in the medical-treatment group, and 4.50 in the stent-treatment group ($P < 0.001$).

Treatment

Of the 67 patients (SI-Figs. 6-8), 42 (63%) underwent stent angioplasty of the intramural RCA, 3 (4%)

TABLE IV. Quantitative Measurements From Intravascular Ultrasonography

	Mean ± SD	Range
Reference distal segment of RCA		
Cross-sectional area (mm ²)	12.1 ± 4.2	4.5–28.0
Diameter (mm)	3.9 ± 0.7	2.4–6.0
Intramural segment of RCA (worst stenosis)		
Cross-sectional area (mm ²)	6.0 ± 2.4	1.6–16.2
Minimal diameter (mm)	1.6 ± 0.7	0.9–4.8
Maximal diameter (mm)	4.4 ± 1.3	2.4–8.6
Minimal/maximal diameter index (mm)	0.40 ± 0.17	0.14–0.99
Degree of stenosis (%AS)	49 ± 18	4–83

%AS, percent area of stenosis; RCA, right coronary artery.

had primary surgical correction of the anomalous RCA, and 22 (33%) were treated medically. Several stent models were initially used, including bare-metal stents in three cases (7%); later, only drug-eluting stents were used: 26 (62%) Cypher stents (Cordis), 7 (17%) Promus (Boston Scientific), and 6 (14%) Taxus (Boston Scientific). After primary stenting, the CSA of the intramural segment increased from 4.8 mm² (2.6–7.6 mm²) to 10.8 mm² (5.2–19.8 mm²), reducing the average %AS from 58% (37–83%) to 8% (0–41%). Stenting was successful in all patients in whom it was attempted, eliminating lateral compression of the proximal RCA and its phasic pulsatility.

Follow-Up

Forty-one patients (61% of total; SI-Fig. 7 and SI-Fig. 8), treated medically or by stent angioplasty,

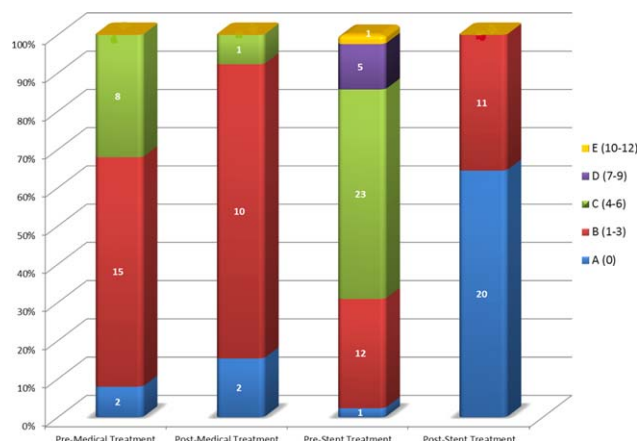


Fig. 5. Percentages of patients per treatment group, by the combined severity-FC score. Comparative distribution of pre- and post-treatment MFCC scores in patients treated medically versus with stent angioplasty. The MFCCs were much higher at baseline and after treatment in the stent group than in the medical-treatment group.

completed more than 1 year of follow-up (mean 5.0 ± 2.9 years; range 1.1–12.1 years). An 84-year-old patient (not treated with stenting) died of progressive concomitant coronary atherosclerotic disease (unrelated to R-ACAOS) 8 years after IVUS. Another patient died of chronic renal failure.

Among the 42 patients who underwent stent angioplasty, no deaths occurred due to R-ACAOS pathology. The mean MFCC score in the medical group decreased from 2.84 to 1.50 ($P = 0.06$); in 31 (74%) of the 42 stent-treated patients (mean follow-up: 5.0 years), MFCC decreased from 4.50 to 0.60 ($P < 0.001$, Fig. 5). Fourteen patients (33%) in the stent group had an MFCC score of 6 or higher before stenting, whereas none scored higher than three afterwards. Twenty-three patients in the stent group underwent follow-up stress testing by nuclear myocardial perfusion scan; only two had perfusion defects in stented areas. Of the 10 patients in the stent group who underwent clinically indicated follow-up coronary angiography (2 had a positive stress test; other 8 were possibly symptomatic), 4 had restenosis at the intramural stent by in-stent scar formation, with resulting %ASs of 50, 63, 80, and 100% on IVUS (2 of these patients had bare-metal stents).

Of the four patients with restenosis, 1 had origin of the RCA from a common trunk with the LCA, at the left sinus, and was initially treated with a Taxus stent. After 5 months, she had diffuse in-stent restenosis that was treated by balloon angioplasty. At 3 years, she required redo stenting for 40% restenosis and severe symptoms; a Cypher stent was used. At 6 years, she had stent thrombosis without clinical infarct (possibly due to stent kinking during phasic systolic bending). A

surgical mammary artery graft to the RCA yielded favorable clinical and angiographic results at 4 months' follow-up. The other three restenosis patients underwent in-stent balloon angioplasty, resulting in a 0 to 20% %AS. No clinically significant restenosis was noted at follow-up. Nine years after stenting, one other patient developed incidental severe myocarditis that partially resolved; this patient's stent was still patent (as shown by angiography and IVUS).

DISCUSSION

In R-ACAOS, which is more prevalent than L-ACAOS [3,19], symptoms are variable, SCD is rare [2,23,26] and treatment indications are inconsistent. The recent realization that ACAOS is not as rare (about 1.5 million persons in the United States [19]), as previously assumed has encouraged investigators to research factors that could be used to subclassify certain types of CAA that could be hr-CVC for SCD or for symptoms. Many authors have recently suggested that not all cases of R-ACAOS necessitate intervention [16,23,26]. Typically, unabated angina, dyspnea, or a positive stress test has been considered adequate reason for intervention, especially in people with active lifestyles, but there is no objective published evidence that any particular intervention for R-ACAOS of any severity improves long-term outcome [23,26]. Our group and others have reported that stent angioplasty of R-ACAOS vessels is technically feasible [21,24,25]. Coronary catheter angiography, computed tomographic angiography, and echocardiography cannot assess degree of proximal stenosis (or intramurality), whereas IVUS assessment of the luminal geometry of the initial portion of the ectopic vessels could be critically important for effectively subclassifying ACAOS [8–22,24,25].

Although the lack of close correlation between functional class and %AS (as suggested by Fig. 4B) may seem disappointing, it also may indicate that a more complex mechanism of episodic ischemia is at work, in which baseline stenosis is intermittently modulated by factors that are difficult to identify and measure clinically, such as aortic compliance, or flail-membrane behavior of the slit-like ostial anatomy (a Venturi effect could be involved, as suggested by OCT). Additionally, our experience brings to the forefront frequently unrecognized adult presentations of ACAOS (commonly considered a problem only in the young, and only related to SCD that occurs during exercise). The present study advances our knowledge because it used IVUS for in vivo cross-sectional imaging of the anomalous artery, revealing and measuring stenosis at rest, while suggesting possible worsening during exertion. Such imaging is more accurate than angiography

because it is tomographic, *in vivo*, and 10 times more precise in temporal and geometric discrimination. Our IVUS studies consistently revealed an intramural course in cases of pre-aortic ectopic RCA (see SI-Fig. 9 and animation in Video 4) [2,8]. Furthermore, we noticed variable degrees of phasic cross-luminal changes [8,16].

Recently, R-ACAOS was redefined [8] as having three characteristics: (1) an ectopic location of the RCA ostium (i.e., not in the right sinus of Valsalva, its normal location [3]); (2) an intramural proximal course, passing inside the aortic tunica media (from the ectopic ostial site toward the normal right sinus); and (3) some degree of stenosis of the intramural artery. In most adult patients who received a stent because of significant stenosis (by MFCC classification), symptoms improved from moderate to mild or none, tentatively confirming our pathophysiological hypothesis. Stenting the R-ACAOS proximal segment was technically delicate and demanding, but it was successful in all patients in whom it was attempted, and postprocedural complications and restenosis at more than 1-year follow-up were trivial.

Study Limitations

This study of R-ACAOS was relatively small, and not a prospective, randomized trial; rather, it was a single-center, observational, preliminary study without a defined endpoint, a fair comparison group, or 100% long-term follow-up. The study was chiefly intended to elucidate the pathophysiological mechanisms of ACAOS, introduce a prognostication method for individual carriers, and examine the effectiveness of stent angioplasty (which eliminates stenosis).

Our findings do not clearly correlate severity of clinical presentation with baseline %AS as measured by IVUS. The cross-sectional diameters of the IVUS probes (about 1.3 mm) may be too large to permit the assessment of the more severe intramural slits under baseline and exercise conditions. The IVUS catheter may prop open a lumen that otherwise would be collapsed. Using OCT (currently done with a 0.9 mm diameter catheter) could produce more accurate results, but this application of OCT has several unresolved technical issues (especially interference from blood at the ostium by nonselective position of the guiding catheter and the removal of the ECG feature from current IVUS devices).

Current technology does not allow adequate analysis by the SAD test of the likely exercise-related changes in CSA (hyperactive state and tachycardia-related motion artifacts), so our findings and conclusions are preliminary in this regard. The present pilot study does

not provide definitive answers to other important questions: What intervening factors make a patient with ACAOS symptomatic or likely to die? Exercise is frequent precipitating factor, but is it essential? What treatment modality is best, and for which patients?

CONCLUSION

The use of IVUS seems necessary to evaluate the anatomic severity of stenosis, the likely cause of clinical manifestations in R-ACAOS. Our preliminary, hypothesis-generating findings support the notion that in adults with noncritical R-ACAOS (by symptoms, stenosis, and prognosis), observation and medical management alone may be adequate, especially for palliating symptoms. The recent introduction of a custom-made guiding catheter designed specifically to coaxially access the ectopic, tangential RCA and to provide adequate backup support has improved the ease of IVUS imaging and stent delivery. On the basis of our pilot data, it seems reasonable to propose a multicenter study, performed by centers of excellence in the field of these not-so-rare anomalies, involving prospective and consistent operative algorithms.

REFERENCES

1. Angelini P. Coronary artery anomalies—Current clinical issues: Definitions, classification, incidence, clinical relevance, and treatment guidelines. *Texas Heart Inst J* 2002;29:271–278.
2. Angelini P. Coronary artery anomalies: An entity in search of an identity. *Circulation* 2007;115:1296–1305.
3. Angelini P, Villason S, Chan AV. 1999. Normal and anomalous coronary artery in humans. In: Angelini P, Fairchild VD, editors. *Coronary Artery Anomalies: A Comprehensive Approach*. Lippincott Williams & Wilkins, 1999. pp 27–126.
4. Erez E, Tam VK, Doublin NA, Stakes J. Anomalous coronary artery with aortic origin and course between the great arteries: Improved diagnosis, anatomic findings, and surgical treatment. *Ann Thorac Surg* 2006; 82:973–977.
5. Jacobs ML, Mavroudis C. Anomalies of the coronary arteries: Nomenclature and classification. *Cardiol Young* 2010;20 Suppl 3:15–19.
6. Lim JC, Beale A, Ramcharitar S. Anomalous origination of a coronary artery from the opposite sinus. *Nat Rev Cardiol* 2011; 8:706–719.
7. Penalver JM, Mosca RS, Weitz D, Phoon CK. Anomalous aortic origin of coronary arteries from the opposite sinus: A critical appraisal of risk. *BMC Cardiovasc Disord* 2012;12:83
8. Angelini P, Flamm SD. Newer concepts for imaging anomalous aortic origin of the coronary arteries in adults. *Catheter Cardiovasc Interv* 2007;69:942–954.
9. Basso C, Maron BJ, Corrado D, Thiene G. Clinical profile of congenital coronary artery anomalies with origin from the wrong aortic sinus leading to sudden death in young competitive athletes. *J Am Coll Cardiol* 2000;35:1493–1501.
10. Cheitlin MD, De Castro CM, McAllister HA. Sudden death as a complication of anomalous left coronary origin from the anterior

- sinus of Valsalva, A not-so-minor congenital anomaly. *Circulation* 1974;50:780–787.
11. Frescura C, Basso C, Thiene G, Corrado D, Pennelli T, Angelini A, Daliento L. Anomalous origin of coronary arteries and risk of sudden death: A study based on an autopsy population of congenital heart disease. *Hum Pathol* 1998;29:689–695.
 12. Kragel AH, Roberts WC. Anomalous origin of either the right or left main coronary artery from the aorta with subsequent coursing between aorta and pulmonary trunk: Analysis of 32 necropsy cases. *Am J Cardiol* 1988;62:771–777.
 13. Roberts WC, Siegel RJ, Zipes DP. Origin of the right coronary artery from the left sinus of Valsalva and its functional consequences: Analysis of 10 necropsy patients. *Am J Cardiol* 1982;49:863–868.
 14. Taylor AJ, Byers JP, Cheitlin MD, Virmani R. Anomalous right or left coronary artery from the contralateral coronary sinus: "High-risk" abnormalities in the initial coronary artery course and heterogeneous clinical outcomes. *Am Heart J* 1997;133:428–435.
 15. Taylor AJ, Rogan KM, Virmani R. Sudden cardiac death associated with isolated congenital coronary artery anomalies. *J Am Coll Cardiol* 1992;20:640–647.
 16. Angelini P, Monge J. 2013. Coronary artery anomalies. In: Moscucci M, editor. *Grossman & Baim's Cardiac Catheterization, Angiography, and Intervention*, 8th ed. Lippincott Williams & Wilkins; pp 335–353.
 17. Lee HJ, Hong YJ, Kim HY, Lee J, Hur J, Choi BW, Chang HJ, Nam JE, Choe KO, Kim YJ. Anomalous origin of the right coronary artery from the left coronary sinus with an interarterial course: Subtypes and clinical importance. *Radiology* 2012;262:101–108.
 18. Miller JA, Anavekar NS, El Yaman MM, Burkhart HM, Miller AJ, Julsrud PR. Computed tomographic angiography identification of intramural segments in anomalous coronary arteries with interarterial course. *Int J Cardiovasc Imaging* 2012;28:1525–1532.
 19. Angelini P, Cheong B, Uribe C, Ali SW, Elayda M, Willerson JT. Results of systematic MRI-based pre-participation screening of school children: The sample size issue. *JACC* 2015;A315:1242–016.
 20. Garcia-Rinaldi R, Sosa J, Olmeda S, Cruz H, Carballido J, Quintana C. Surgical treatment of right coronary arteries with anomalous origin and slit ostium. *Ann Thorac Surg* 2004;77:1525–1529.
 21. Hariharan R, Kacere RD, Angelini P. Can stent-angioplasty be a valid alternative to surgery when revascularization is indicated for anomalous origination of a coronary artery from the opposite sinus? *Texas Heart Inst J* 2002;29:308–313.
 22. Moodie DS, Gill C, Loop FD, Sheldon WC. Anomalous left main coronary artery originating from the right sinus of Valsalva: Pathophysiology, angiographic definition, and surgical approaches. *J Thorac Cardiovasc Surg* 1980;80:198–205.
 23. Brothers J, Gaynor JW, Paridon S, Lorber R, Jacobs M. Anomalous aortic origin of a coronary artery with an interarterial course: Understanding current management strategies in children and young adults. *Pediatr Cardiol* 2009;30:911–921.
 24. Lim MJ, Forsberg MJ, Lee R, Kern MJ. Hemodynamic abnormalities across an anomalous left main coronary artery assessment: Evidence for a dynamic ostial obstruction. *Catheter Cardiovasc Interv* 2004;63:294–298.
 25. Tsujita K, Maehara A, Mintz GS, Franklin-Bond T, Mehran R, Stone GW, Leon MB, Moses JW. *In vivo* intravascular ultrasonic assessment of anomalous right coronary artery arising from left coronary sinus. *Am J Cardiol* 2009;103:747–751.
 26. Krasuski RA, Magyar D, Hart S, Kalahasti V, Lorber R, Hobbs R, Pettersson G, Blackstone E. Long-term outcome and impact of surgery on adults with coronary arteries originating from the opposite coronary cusp. *Circulation* 2011;123:154–162.