

Technical Note

Underlay hourglass-shaped autologous pericranium duraplasty in “key-hole” retrosigmoid approach surgery: Technical report

Luciano Mastronardi, Guglielmo Cacciotti, Franco Caputi, Raffaelino Roperto, Maria Pia Tonelli, Ettore Carpineta, Takanori Fukushima¹

Department of Neurosurgery, San Filippo Neri Hospital, Roma, Italy, ¹Department of Neurosurgery, Carolina Neuroscience Institute, Raleigh, North Carolina, USA

E-mail: *Luciano Mastronardi - mastro@tin.it; Guglielmo Cacciotti - gugio@hotmail.com; Franco Caputi - frcaputi@gmail.com;
Raffaelino Roperto - r.roperto@katamail.com; Maria Pia Tonelli - mptonelli@hotmail.it; Ettore Carpineta - ettore.carpineta@gmail.com;
Takanori Fukushima - lori@carolinaneuroscience.com
*Corresponding author

Received: 24 February 15 Accepted: 30 October 15 Published: 10 March 16

Abstract

Background: Cerebrospinal fluid (CSF) leakages represent a major complication of skull base surgery. Watertight dural suture is challenging, and different ways to reinforce it have been proposed. Since 6 months, we use locally harvested autologous pericranium graft for dural repair in retrosigmoid approach.

Methods: Retrospectively, we analyzed 27 patients operated on with “key-hole” retrosigmoid approach from May 2014. In all, autologous pericranium was harvested and inserted as an underlay “hourglass-shaped” plug under the dura plane and stitched to dura. Surgical patch and sealant were used for augmentation. Complications considered were new neurological symptoms, surgical site infections, meningitis, CSF-leaks, and pseudomeningocele.

Results: Indications included tumor (16 cases), microvascular decompression (10 cases), and hemorrhagic cerebellar arteriovenous malformation (1 case). Surgical site infections, meningitis, and CSF leaks have never been observed. One neurofibromatosis type 2 patient operated on for large acoustic neuroma developed an asymptomatic pseudomeningocele, disappeared on 3-month magnetic resonance imaging follow-up.

Conclusions: In our series, autologous pericranium inserted and stitched as an underlay hourglass-shaped plug, augmented with surgical patch pieces and dural sealant seemed to be safe and effective for dural repair in “key-hole” retrosigmoid approach. With this technique, we obtained low complication rate, similar to the best current results of available literature.

Key Words: Autologous pericranium patch, cerebrospinal fluid-related complications, duraplasty, retrosigmoid approach

Access this article online

Website:

www.surgicalneurologyint.com

DOI:

10.4103/2152-7806.178521

Quick Response Code:

INTRODUCTION

Postoperative cerebrospinal fluid (CSF) leakage is a challenging and potentially hazardous problem following many complex cranial procedures. This is, especially true for surgical approaches to posterior cranial fossa, in which a watertight dural reconstruction is not always feasible, and CSF pulsation waves are greater than other

This is an open access article distributed under the terms of the Creative Commons Attribution-NonCommercial-ShareAlike 3.0 License, which allows others to remix, tweak, and build upon the work non-commercially, as long as the author is credited and the new creations are licensed under the identical terms.

For reprints contact: reprints@medknow.com

How to cite this article: Mastronardi L, Cacciotti G, Caputi F, Roperto R, Tonelli MP, Carpineta E, et al. Underlay hourglass-shaped autologous pericranium duraplasty in “key-hole” retrosigmoid approach surgery: Technical report. *Surg Neurol Int* 2016;7:25.

<http://surgicalneurologyint.com/Underlay-hourglass-shaped-autologous-pericranium-duraplasty-in-“key-hole”-retrosigmoid-approach-surgery:-Technical-report/>

cranial areas.^[5,7,8] Copeland *et al.*^[3] reported that obesity, translabyrinthine approach, and longer operative times seem to increase significantly the risk of a CSF leak following vestibular schwannoma surgery.

CSF fistulas into the soft tissues at the base of the skull can cause wound breakdown and/or pseudomeningocele, which often become very painful and debilitating. In addition, drainage of spinal fluid from the skin increases the risk for surgical site infections and meningitis.^[5] In a recent article on a series of 357 acoustic neuromas, Nonaka *et al.*^[8] reported a CSF leak in 7.6% of cases, wound infection in 2.2%, and meningitis in 1.7%. On the other hand, in a large systematic review of literature, Xia *et al.*^[10] reported CSF leak complications in 1.6% (0.7–2.5%) of patients operated on for trigeminal neuralgia with microvascular decompression by retrosigmoid approach.

Autologous tissues for posterior cranial fossa dural closure have been mentioned in several articles.^[4,6,7] We report the use of autologous pericranium harvested during the opening step of retrosigmoid approach, inserted and stitched as an underlay hourglass-shaped plug, followed by application of a layer of absorbable hemostats and of surgical patch and by dural sealant augmentation. In our series, this technique appeared to be a safe and effective way to repair the dural opening at the end of posterior fossa surgeries.

MATERIALS AND METHODS

Patient population

From May to October 2014, 27 consecutive patients were enrolled in the study. Indications for posterior fossa surgery have been cerebellopontine angle tumors in 16 cases (12 acoustic neuromas and 4 meningiomas), microvascular decompression for trigeminal neuralgia in 9 and for hemifacial spasm in 1, and bleeding left cerebellar arteriovenous malformation (AVM) associated with a left posterior inferior cerebellar artery aneurysm in 1 case. The age ranged from 20 to 77 years; 15 patients were female and 12 male.

Intraoperative procedures

“Key-hole” retrosigmoid approach

Except for the patient operated on for a hemorrhagic lateral cerebellar AVM, in which a supine position with 45° rotation of the head was used, in all patients a lateral Fukushima position was adopted.^[9] Continuous lumbar drain was placed only in cases operated on for larger tumors (maximum diameter > 2.5 cm) and left in place for 3–4 days, for facilitating cerebellar detention during surgery and postoperative wound closure (draining around 10 cc/h, starting the day after surgery).

After a slightly curved 4–5 cm skin incision behind the ear, in all cases a free pericranial flap (about 3 cm × 3 cm)

for dural closure was harvested [Figure 1]. During the remainder of the procedure, the graft patch was soaked and stored in Gentamycin-enriched saline solution.

Retromastoid lateral occipital bone was exposed including superior and inferior nuchal lines,^[9] and a craniectomy of about 3 cm × 3 cm was performed in all cases, exposing sigmoid and transverse sinuses and the angle between them. The dura was opened in a semicircular shape, covering part of cerebellar hemisphere, and the arachnoid membrane of lateral cerebellopontine cistern was opened for cerebellar detension.

Dural closure

At the end of the intracranial step and after meticulous hemostasis, the tack-up dural sutures applied during the dural opening phase were cut, and the autologous pericranium graft was inserted through the defect as an underlay hourglass-shaped plug. For obtaining this, the graft harvested had to be slightly larger than the dural defect, in order to have its edges under the dural plane. It was fixed under operative microscope magnification with separated stitches (with an “inside-to-outside” direction) to the dura mater, using a 3-0 running silk [Figure 2]. After that, the inserted patch was augmented with one layer of absorbable hemostats (Fibrillary Surgicel, Ethicon, J and J, Somerville, New Jersey, USA), with small pieces of surgical patch (TachoSil®, Takeda, Japan), and with a dural sealant (DuraSeal, Covidien LLC, Mansfield, Massachusetts or Tisseel, Baxter, Deerfield, Illinois, USA).

In all cases, the autologous bone removed or fitted titanium net was placed on the bony defect with dedicated miniscrews (Lorenz, Biomet Microfixation, Jacksonville, Florida, USA).

RESULTS

In this series, we never observed new neurological symptoms related to the described procedure of dural closure, surgical site infections, meningitis, and CSF leaks. The complication rate was 4%. One neurofibromatosis type 2-patient operated on for a right large acoustic neuroma developed an asymptomatic small pseudomeningocele on the 48-h-postoperative computed tomography scan; the CSF sac disappeared at the 3-month magnetic resonance imaging follow-up.

DISCUSSION

Techniques for posterior cranial fossa dural reconstruction and closure include many solutions. Synthetic dural patches applied with continuous or separate stitches, incorporation of autologous tissues (pericranium or fascia lata), augmentation with “muscle plugs” for small defects in the suture line and/or with gelatin sponge, absorbable hemostats, dural sealants. Temporary CSF diversion can

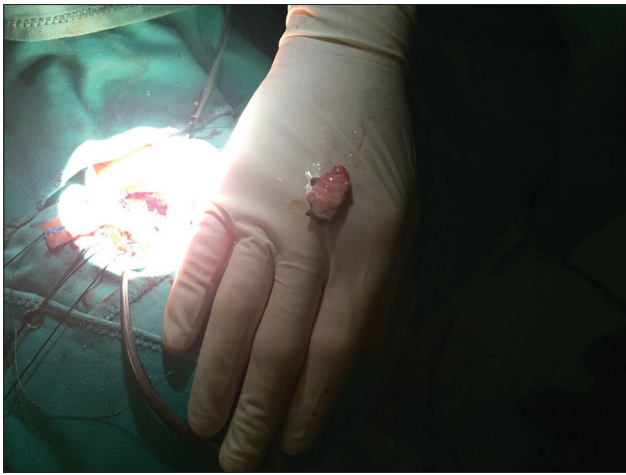


Figure 1: Autologous harvested pericranium

be employed via a lumbar drain or external ventricular drain to reduce the pressure gradient across the dural closure until it “seals.”^[7]

Even with these techniques, however, it is impossible to ensure a watertight dural closure for several reasons, including the holes in the dura created by surgical needle during suturing. “Onlay” applicable synthetic dural grafts should be avoided because of the high hydrodynamic pressure of CSF in this district.^[7]

Chauvet *et al.*^[1] have developed an experimental device capable of testing dural closure watertightness. With this study, they demonstrated that interrupted stitch suturing proved to have the same efficacy of running simple closure. On the contrary, the 2 sealants/glues (Bioglue[®], Cryolife, USA and Duraseal[®], Covidien, Ireland) and the 2 haemostatics (Tachosil[®], Takeda, Japan and Tissucol[®], Baxter, USA) show different watertightness capacities.^[1] All sealants increased the watertightness of sutures significantly; however, one sealant (Duraseal[®]) and one hemostatic (Tachosil[®]) seemed to show better results.^[1]

The nonaerosolized application of a thin layer of dural sealant (Duraseal[®]) to the dry dural surface, followed by a titanium mesh secured to the calvarium with microscrews, has been used by Lam and Kasper^[7] to cover the craniectomy. Anyway, in some selected cases, it was possible to replace the autologous bone flap.

The so-called surgical patch (TachoSil[®], Takeda, Japan) combines the bioactive mechanism of action of fibrinogen and thrombin, with the mechanical support of a collagen patch. It is made from collagen, i.e. naturally reabsorbed, and is approved for hemostasis and for sealing of tissues. On contact with blood or other fluids, the coagulation factors react to form a fibrin clot that sticks the surgical patch to the tissue surface, producing an air- and liquid-tight seal in few minutes, providing protection against postoperative re-bleedings and leaks.^[1,2]

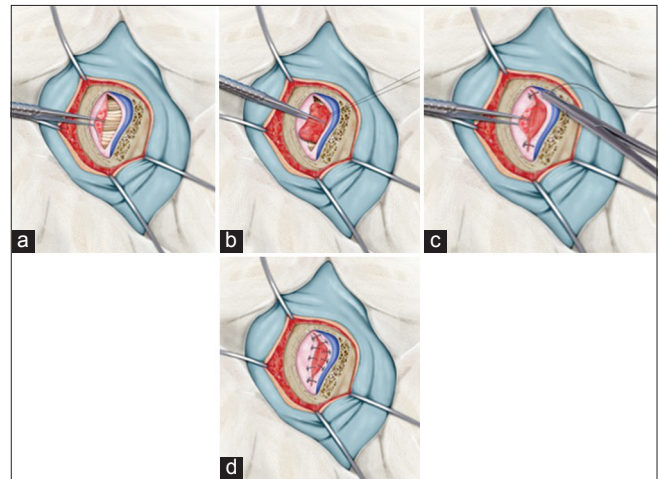


Figure 2: Intraoperative picture of a typical “key-Hole” retrosigmoid closure (a). Step by step procedure. The local harvested pericranium is inserted under the dural plane (b) with “inside-to-outside” direction (c) and is stitched (d)

Even if variety of dural substitutes is currently available, many data suggest that autologous materials are preferable compared to nonautologous substitutes.^[4,6,7,9] Czorny^[4] used a pericranial graft taken in the interparietal area on up of the occipital craniotomy in order to obtain a tight dural closure, preventing pseudomeningocele, without tension gaining space, permitting a better tolerance of possible postoperative cerebellar edema. Kosnik^[6] proposed the technique of harvesting the ligamentum nuchae for closure of dura after posterior fossa surgery: With this technique, the author avoided postoperative CSF leakage in more than 200 procedures. A vascularized pericranium reflected or an autologous pericranium graft with dural sealant augmentation proved to be an effective way to repair the durotomy in posterior cranial fossa surgeries.^[7]

The technical tip we propose for dural closure after retrosigmoid approach is to insert a layer of autologous pericranium harvested during the opening step as an underlay hourglass-shaped plug, larger than the defect, under the dural plane, and to stitch it with an “inside-to-outside” direction to the dura mater [Figure 2]. The suture was and augmented by absorbable hemostats, surgical patch pieces, and dural sealant layers. This method seemed to be simple, safe, and effective for repairing the dural opening at the end of key-hole retrosigmoid approaches for cerebellopontine pathologies. Prospective studies on larger series are warranted.

Financial support and sponsorship

Nil.

Conflicts of interest

There are no conflicts of interest.

REFERENCES

1. Chauvet D, Tran V, Mutlu G, George B, Allain JM. Study of dural suture watertightness: An *in vitro* comparison of different sealants. *Acta Neurochir (Wien)* 2011;153:2465-72.
2. Colombo GL, Bettoni D, Di Matteo S, Grumi C, Molon C, Spinelli D, et al. Economic and outcomes consequences of TachoSil®: A systematic review. *Vasc Health Risk Manag* 2014;10:569-75.
3. Copeland WR, Mallory GW, Neff BA, Driscoll CL, Link MJ. Are there modifiable risk factors to prevent a cerebrospinal fluid leak following vestibular schwannoma surgery? *J Neurosurg* 2015;122:312-6.
4. Czorny A. Postoperative dural tightness. Value of suturing of the pericranium in surgery of the posterior cranial fossa. *Neurochirurgie* 1992;38:188-90.
5. Dubey A, Sung WS, Shaya M, Patwardhan R, Willis B, Smith D, et al. Complications of posterior cranial fossa surgery – An institutional experience of 500 patients. *Surg Neurol* 2009;72:369-75.
6. Kosnik EJ. Use of ligamentum nuchae graft for dural closure in posterior fossa surgery. Technical note. *J Neurosurg* 1998;89:155-6.
7. Lam FC, Kasper E. Augmented autologous pericranium duraplasty in 100 posterior fossa surgeries – A retrospective case series. *Neurosurgery* 2012;71 2 Suppl Operative:ons302-7.
8. Nonaka Y, Fukushima T, Watanabe K, Friedman AH, Sampson JH, McElveen JT Jr, et al. Contemporary surgical management of vestibular schwannomas: Analysis of complications and lessons learned over the past decade. *Neurosurgery* 2013;72 2 Suppl Operative:ons103-15.
9. Sameshima T, Mastronardi L, Friedman AH, Fukushima T, editors. *Microanatomy and Dissection of Temporal Bone for Surgery of Acoustic Neuroma and Petroclival Meningioma*. 2nd ed. Durham, NC: AF Neurovideo, Inc.; 2007.
10. Xia L, Zhong J, Zhu J, Wang YN, Dou NN, Liu MX, et al. Effectiveness and safety of microvascular decompression surgery for treatment of trigeminal neuralgia: A systematic review. *J Craniofac Surg* 2014;25:1413-7.