

**OPEN ACCESS**

Full open access to this and thousands of other papers at <http://www.la-press.com>.

## A Case of Fitz-Hugh-Curtis Syndrome Complicated by Appendicitis Conservatively Treated with Antibiotics

Itsuro Kazama<sup>1</sup> and Toshiyuki Nakajima<sup>2</sup>

<sup>1</sup>Department of Physiology I, Tohoku University Graduate School of Medicine, Seiryō-cho, Aoba-ku, Sendai, Miyagi, Japan. <sup>2</sup>Internal Medicine, Iwakiri Hospital, Miyagino-ku, Sendai, Miyagi, Japan.  
Corresponding author email: [kazaitso@med.tohoku.ac.jp](mailto:kazaitso@med.tohoku.ac.jp)

**Abstract:** A 27-year-old woman developed a low grade fever and increased vaginal discharge that persisted for 2 weeks. Intermittent abdominal pain in the right upper quadrant had been experienced over the previous few days. Due to her clinical manifestations and typical abdominal computed tomography (CT) findings, including hepatic capsular enhancement and hepatomegaly, a diagnosis of Fitz-Hugh-Curtis syndrome was made. The early empirical use of antibiotics, azithromycin and levofloxacin, partially improved her symptoms. However, the low grade fever persisted and additional abdominal pain developed in the right lower quadrant. Based on the radiological evidence of an enlarged appendix with wall thickening, a diagnosis of appendicitis was additionally made, which was thought to occur secondarily to the genital tract infection. Following the administration of antibiotics ceftriaxone and cefditoren pivoxil, her symptoms were completely resolved without the need for any surgical intervention. Here, we report the first case of Fitz-Hugh-Curtis syndrome complicated by appendicitis, which was conservatively managed with antibiotic treatment alone. In this case, the overgrowth of pathogens within the genital tract and their direct penetration into the appendix was thought to be responsible for the development of appendicitis.

**Keywords:** Fitz-Hugh-Curtis syndrome, appendicitis, complication, antibiotic treatment, overgrowth of the pathogen

*Clinical Medicine Insights: Case Reports* 2013:6 35–40

doi: [10.4137/CCRep.S11522](https://doi.org/10.4137/CCRep.S11522)

This article is available from <http://www.la-press.com>.

© the author(s), publisher and licensee Libertas Academica Ltd.

This is an open access article. Unrestricted non-commercial use is permitted provided the original work is properly cited.



## Introduction

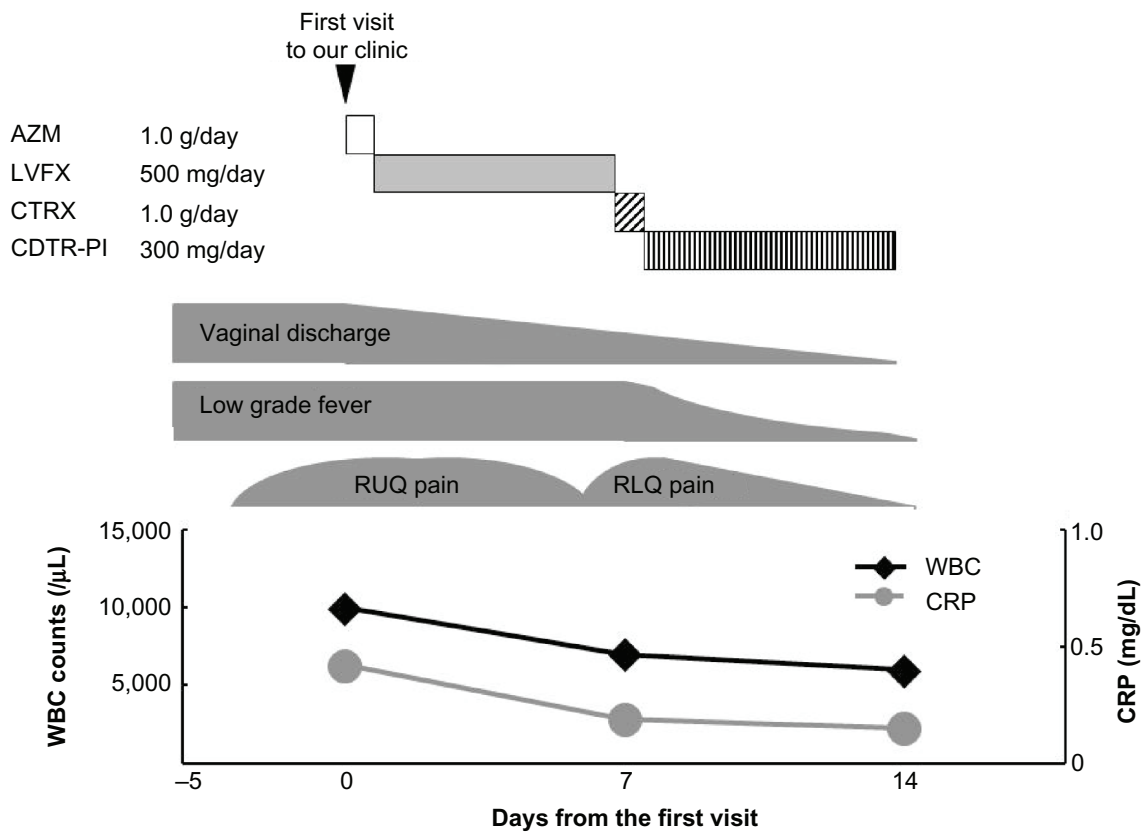
Fitz-Hugh-Curtis syndrome is perihepatitis that develops secondarily to genital tract infections.<sup>1</sup> The syndrome is characterized by inflammation of the liver and adjacent peritoneal surfaces, and occurs in as high as 14% of cases with pelvic inflammatory disease (PID).<sup>2,3</sup> In the 1970's, the syndrome was thought primarily attributable to *Neisseria gonorrhoeae* infection.<sup>4</sup> However, later studies using modern assessments revealed the principal involvement of *Chlamydia trachomatis* infection in the pathogenesis.<sup>5</sup> Although these organisms are regarded as the two major pathogens responsible for the syndrome,<sup>6,7</sup> the mechanism by which they specifically cause inflammation in the liver is not fully understood.<sup>8,9</sup> According to some reports, the organisms can disseminate to the liver hematogenously<sup>10</sup> or lymphatically.<sup>5</sup> However, most studies support the hypothesis that the organisms spread intraperitoneally from genital tracts to the liver capsule.<sup>3,11</sup> Since the organisms are preferentially absorbed by the liver capsule,<sup>12</sup> they are not supposed to cause inflammation in the other intra-abdominal organs.<sup>5</sup> Anatomically, however, because organs such as the appendix and cecum are closely located to the ends of the fallopian tubes, they could be affected depending on the severity of infection within the genital tract.<sup>13</sup> Here, we describe a patient with Fitz-Hugh-Curtis syndrome complicated by appendicitis that was conservatively managed with antibiotic treatment alone. The overgrowth of the pathogens within the genital tract and their direct penetration into the appendix was thought to be responsible for the development of appendicitis.

## Case Report

A 27-year-old woman came to our outpatient clinic because of a low grade fever and increased vaginal discharge that developed 2 weeks prior to her visit (Fig. 1). Over the previous few days, she had also noticed intermittent abdominal pain in the right upper quadrant. Her menstrual periods were usually regular in interval and she rarely suffered from menorrhagia. She had a single sex partner and her sexual history was otherwise unremarkable. She had no apparent past medical history of sexually transmitted diseases. On physical examination, the patient appeared exhausted. Her body temperature was

37.3 °C, blood pressure was 110/73 mmHg, and pulse rate was 86 beats/min. She weighed 60 kg and was 163 cm tall. Her eyes were slightly inflamed and the oropharynx was swollen and red. She had right upper abdominal tenderness without rebound pain or guarding, but costovertebral angle tenderness was absent on both sides. Her bowel sounds were normal, and the liver and spleen were not palpable. Laboratory data showed an increased peripheral white blood cell count (10,000/ $\mu$ L) and a slightly elevated C-reactive protein level (0.42 mg/dL). Liver enzymes, such as alanine aminotransferase (ALT) and aspartate aminotransferase (AST), were both slightly elevated (ALT 58 IU/l, AST 44 IU/l), although other routine laboratory investigations, including blood glucose level, electrolytes, and renal function tests, were normal. Although ultrasound investigation of the uterus and adnexa was unremarkable, an abdominal computed tomography (CT) scan showed hepatomegaly with a hepatic capsular enhancement in the arterial phase (Fig. 2), indicating perihepatitis. However, it did not show any findings of other intra-abdominal infections, such as cholecystitis, appendicitis, or pyelonephritis. Based on her clinical manifestations and typical CT findings (Fig. 2),<sup>14</sup> a diagnosis of Fitz-Hugh-Curtis syndrome was made. Since *C. trachomatis* is the pathogen most often responsible for the syndrome,<sup>7</sup> a single dose oral administration of azithromycin (1.0 g) was empirically initiated immediately after the diagnosis, followed by oral administration of levofloxacin (500 mg/day) for the next 7 days (Fig. 1). Although the cervical bacterial culture and serologic tests for *C. trachomatis* later proved negative, treatment with the antibiotics decreased her vaginal discharge and ameliorated the right upper abdominal pain, together with improvement of the systemic inflammatory findings (Fig. 1).

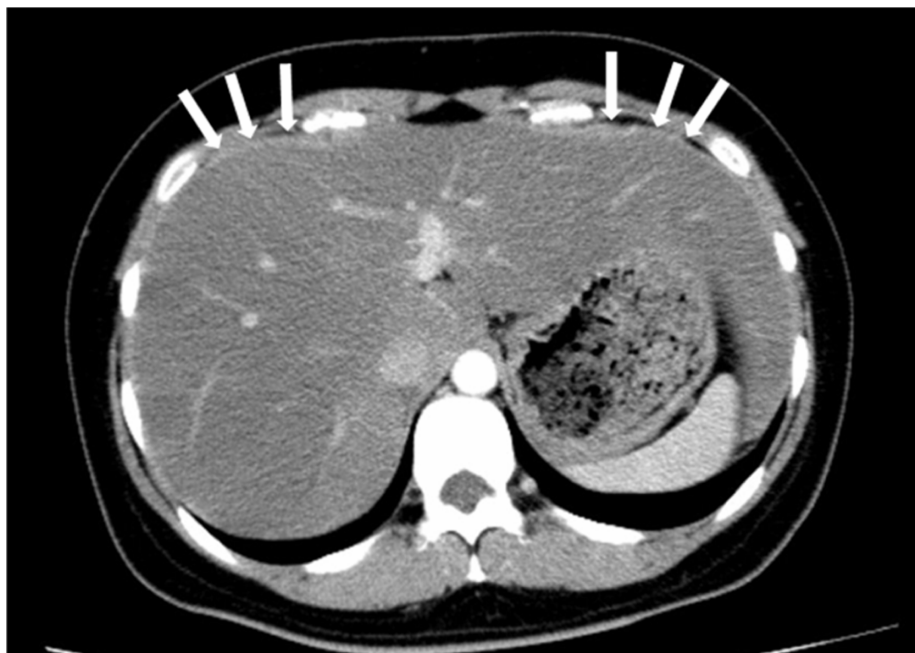The low grade fever, however, persisted and abdominal pain additionally developed in the right lower quadrant. Since an abdominal CT scan demonstrated an enlarged appendix with wall thickening (Fig. 3), she was additionally diagnosed as appendicitis. Because there were no signs of systemic or peritoneal inflammation, and because the CT scan did not indicate the presence of serious complications, such as purulent ascites, she was not surgically treated. Alternatively, we conservatively managed the patient with intravenous administration of ceftriaxone



**Figure 1.** Clinical course and the changes in white blood cell count in the peripheral blood (WBC), C-reactive protein level (CRP).

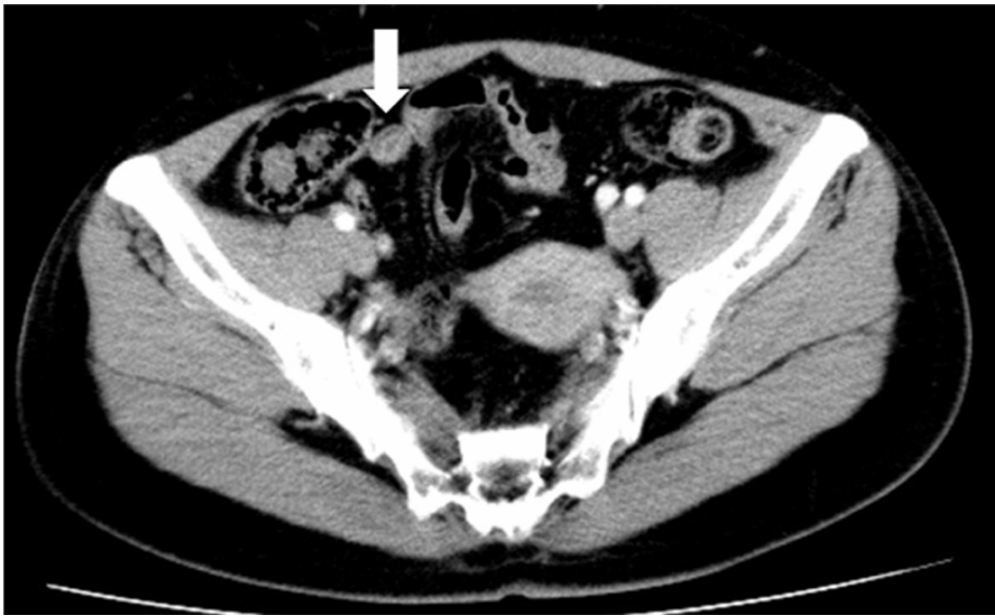**Notes:** Although treatment with azithromycin (AZM) followed by levofloxacin (LVFX) decreased the vaginal discharge and improved the systemic inflammatory findings, the low grade fever persisted as did the right lower abdominal pain. However, treatment with ceftriaxone (CTR), followed by cefditoren pivoxil (CDTR-PI) completely resolved the symptoms, and there were no further signs of recurrence.

**Abbreviations:** AZM, azithromycin; LVFX, levofloxacin; CTRX, ceftriaxone; CDTR-PI, cefditoren pivoxil; RUQ, right upper quadrant; RLQ, right lower quadrant; WBC, white blood cell count in the peripheral blood; CRP, C-reactive protein.



**Figure 2.** Computed tomography (CT) scan image on initial presentation.

**Note:** A computed tomography (CT) image showing hepatomegaly with a hepatic capsular enhancement in the arterial phase (white arrows).



**Figure 3.** CT scan image after 7 days of levofloxacin treatment.  
**Note:** A CT image showing an enlarged appendix with wall thickening (white arrow).

(1.0 g/day), followed by oral administration of cefditoren pivoxil (300 mg/day) (Fig. 1). After an additional 7 days of treatment with these antibiotics (total 14 days), her symptoms, such as a low grade fever and right lower abdominal pain, had completely disappeared. Afterwards, no recurrence of the symptoms or signs was noted, indicating complete remission of the disease.

## Discussion

In the present case, the cervical culture results were negative for both *C. trachomatis* and *N. gonorrhoeae*, although they are the two major pathogens responsible for Fitz-Hugh-Curtis syndrome.<sup>6,7</sup> According to previous studies, diverse microorganisms, including anaerobic bacteria and facultative gram negative rods, also cause pelvic inflammatory disease (PID).<sup>15</sup> Recently, Woo et al further demonstrated that the organisms other than *C. trachomatis* and *N. gonorrhoeae*, such as *Trichomonas vaginalis*, *Ureaplasma urealyticum* and *Mycoplasma hominis*, can cause Fitz-Hugh-Curtis syndrome.<sup>16</sup> In our case, however, since the patient's symptoms were consistent with those typically caused by *C. trachomatis* or *N. gonorrhoeae*,<sup>17</sup> and since the symptoms responded well to the antibiotic treatment, either or both of the organisms were thought to be responsible for the development of Fitz-Hugh-Curtis syndrome.<sup>18</sup> In this

context, the negative culture results in our patient may be due to the partial treatment effect by the antibiotics, which were empirically started before sampling the specimen for the culture.

In our case, the diagnosis of appendicitis was additionally made based on the radiological evidence of an enlarged appendix with wall thickening (Fig. 3), which had not been noted in the first abdominal CT scan. Appendicitis is usually caused by the intraluminal overgrowth of enterobacteria, such as *Escherichia coli*, *Peptostreptococcus* and *Bacteroides fragilis*.<sup>19,20</sup> However, according to previous reports, the disease can also be caused by exogenous infections with *C. trachomatis* and *N. gonorrhoeae*.<sup>13,21</sup> In the development of perihepatitis in Fitz-Hugh-Curtis syndrome, these organisms are known to travel intraperitoneally from the genital tract via the paracolic gutters to the liver capsule.<sup>3,11</sup> Since the organisms are more preferentially absorbed by the liver capsule than any other intra-abdominal structures,<sup>12</sup> perihepatitis is considered to be the most frequent intra-abdominal complication of genital tract infections.<sup>2,3</sup> In contrast, however, the organisms do not usually affect other intra-abdominal organs,<sup>22</sup> although they are located more closely to the genital tract than the liver is. In our case, despite the lack of radiological evidence characteristic to PID, the patient had been suffering from a genital tract infection for the



previous 2 weeks, which was sufficient time for the organisms to overgrow within the tract. Since overgrown bacteria can cause inflammation locally in the surrounding organs and increase the fragility of their peritoneal walls,<sup>23</sup> it is not surprising that they could penetrate into the adjacent appendix and thus caused appendicitis. Previously, Marbet et al reported two cases of severe peritonitis caused by *C. trachomatis* in the absence of Fitz-Hugh-Curtis syndrome.<sup>24</sup> The cases demonstrated our hypothesis that the organisms can directly extend into the peritoneal cavity from the genital tracts.

Previous studies have demonstrated through in vitro experiments that infections with *C. trachomatis* and *N. gonorrhoeae* stimulate the activity of lymphocytes.<sup>25,26</sup> Therefore, the involvement of an increased immunological reaction has often been proposed in the pathogenesis of Fitz-Hugh-Curtis syndrome.<sup>27</sup> In our case, such increased immunity was also likely to contribute to the pathogenesis of appendicitis, since lymphoid follicular hyperplasia in the appendix can be the main cause of luminal obstruction,<sup>28</sup> which might have developed later during treatment with levofloxacin. According to some basic studies, the activity of lymphocytes is closely associated with delayed rectifier K<sup>+</sup>-channels (Kv1.3) expressed in their plasma membranes.<sup>29,30</sup> Recently, we have demonstrated in two patients that non-steroidal anti-inflammatory drugs (NSAIDs), which inhibit the Kv1.3-channels in lymphocytes,<sup>31</sup> actually suppressed the hyper-immune response triggered by the virus.<sup>32</sup> In the present case, although the patient had complicated with appendicitis, she could be successfully treated with antibiotics alone. However, considering such an immunological involvement in the pathogenesis, the use of selective Kv1.3-channel blockers or NSAIDs could enhance the therapeutic efficacy of the antibiotics, particularly in cases with greater than usual systemic inflammation.

## Conclusion

In summary, this is the first report of a patient with Fitz-Hugh-Curtis syndrome complicated by appendicitis. It was conservatively managed with antibiotic treatment alone. Overgrowth of the pathogens within the genital tracts and direct penetration into the appendix was thought to be responsible for the development of appendicitis.

## Acknowledgements

We thank the staff at Iwakiri Hospital for their assistance.

## Funding

The authors disclose no funding sources.

## Competing Interests

The authors declare no conflicts of interest.

## Author Contributions

IK was involved in the clinical care of the patient, as well as the conception of the report, the literature review, and manuscript preparation and editing. TN was also involved in the clinical care of the patient. All authors proof-read, reviewed and approved of the final manuscript.

## Disclosures and Ethics

As a requirement of publication, authors have provided to the publisher signed confirmation of compliance with legal and ethical obligations including but not limited to the following: authorship and contributorship, conflicts of interest, privacy and confidentiality and (where applicable) protection of human and animal research subjects. The authors have read and confirmed their agreement with the ICMJE authorship and conflict of interest criteria. The authors have also confirmed that this article is unique and not under consideration or published in any other publications, and that they have permission from rights holders to reproduce any copyrighted material. Any disclosures are made in this section. The external blind peer reviewers report no conflicts of interest.

## References

1. Dalaker K, Gjonnaess H, Kvile G, Urnes A, Anestad G, Bergan T. Chlamydia trachomatis as a cause of acute perihepatitis associated with pelvic inflammatory disease. *Br J Vener Dis*. Feb 1981;57(1):41–3.
2. Semchyshyn S. Fitz-Hugh and Curtis syndrome. *J Reprod Med*. Jan 1979; 22(1):45–8.
3. Onsrud M. Perihepatitis in pelvic inflammatory disease—association with intrauterine contraception. *Acta Obstet Gynecol Scand*. 1980;59(1):69–71.
4. Litt IF, Cohen MI. Perihepatitis associated with salpingitis in adolescents. *JAMA*. Sep 15, 1978;240(12):1253–4.
5. Lopez-Zeno JA, Keith LG, Berger GS. The Fitz-Hugh-Curtis syndrome revisited. Changing perspectives after half a century. *J Reprod Med*. Aug 1985;30(8):567–82.
6. Stanley MM. Gonococcal peritonitis of the upper part of abdomen in young women; (phrenic reaction, or subcostal syndrome of Stajano; Fitz-Hugh-Curtis syndrome); report of cases of three patients treated successfully with penicillin and a summary of the literature. *Arch Intern Med (Chic)*. Jul 1946;78:1–13.



7. Wang SP, Eschenbach DA, Holmes KK, Wager G, Grayston JT. Chlamydia trachomatis infection in Fitz-Hugh-Curtis syndrome. *Am J Obstet Gynecol.* Dec 1, 1980;138(7 Pt 2):1034–8.
8. Kornfeld SJ, Worthington MG. Culture-proved Fitz-Hugh-Curtis syndrome. *Am J Obstet Gynecol.* Jan 1981;139(1):106–7.
9. Wolner-Hanssen P, Svensson L, Westrom L, Mardh PA. Isolation of Chlamydia trachomatis from the liver capsule in Fitz-Hugh-Curtis syndrome. *N Engl J Med.* Jan 14, 1982;306(2):113.
10. Banerjee B, Rennison A, Boyes BE. Sonographic features in a case of Fitz-Hugh-Curtis syndrome masquerading as malignancy. *Br J Radiol.* Apr 1992;65(772):342–4.
11. Vickers FN, Maloney PJ. Gonococcal Perihepatitis. Report of Three Cases with Comments on Diagnosis and Treatment. *Arch Intern Med.* Jul 1964;114:120–3.
12. Holm-Nielsen P. Right upper quadrant pain in salpingitis and other abdominal diseases explained by absorption of exudates from the peritoneal cavity through the diaphragm. *Acta Chir Scand.* 1953;104(6):435–46.
13. Mardh PA, Wolner-Hanssen P. Periappendicitis and chlamydial salpingitis. *Surg Gynecol Obstet.* Apr 1985;160(4):304–6.
14. Nishie A, Yoshimitsu K, Irie H, et al. Fitz-Hugh-Curtis syndrome. Radiologic manifestation. *J Comput Assist Tomogr.* Sep–Oct 2003;27(5):786–91.
15. Eschenbach DA, Buchanan TM, Pollock HM, et al. Polymicrobial etiology of acute pelvic inflammatory disease. *N Engl J Med.* Jul 24, 1975;293(4):166–71.
16. Woo SY, Kim JI, Cheung DY, et al. Clinical outcome of Fitz-Hugh-Curtis syndrome mimicking acute biliary disease. *World J Gastroenterol.* Dec 7, 2008;14(45):6975–80.
17. Zeger W, Holt K. Gynecologic infections. *Emerg Med Clin North Am.* Aug 2003;21(3):631–48.
18. van Bergen JE, Spaargaren J, Gotz HM, et al. Population prevalence of Chlamydia trachomatis and Neisseria gonorrhoeae in The Netherlands. Should asymptomatic persons be tested during population-based Chlamydia screening also for gonorrhoea or only if chlamydial infection is found? *BMC Infect Dis.* 2006;6:42.
19. Lau WY, Teoh-Chan CH, Fan ST, Yam WC, Lau KF, Wong SH. The bacteriology and septic complication of patients with appendicitis. *Ann Surg.* Nov 1984;200(5):576–81.
20. Bennion RS, Baron EJ, Thompson JE Jr, et al. The bacteriology of gangrenous and perforated appendicitis—revisited. *Ann Surg.* Feb 1990;211(2):165–71.
21. Joshi RM, Alkhalegy AA. Acute gonococcal Fitz-Hugh-Curtis syndrome: a case report. *Int J STD AIDS.* Mar 2012;23(3):e39–40.
22. Detels R, Green AM, Klausner JD, et al. The incidence and correlates of symptomatic and asymptomatic Chlamydia trachomatis and Neisseria gonorrhoeae infections in selected populations in five countries. *Sex Transm Dis.* Jun 2011;38(6):503–9.
23. Kazama I, Muto S, Inoue M, et al. Accelerated recovery from Candida peritonitis of enteric origin by early surgical drainage in a peritoneal dialysis patient. *Clin Exp Nephrol.* Dec 2011;15(6):957–61.
24. Marbet UA, Stalder GA, Vogtlin J, et al. Diffuse peritonitis and chronic ascites due to infection with Chlamydia trachomatis in patients without liver disease: new presentation of the Fitz-Hugh-Curtis syndrome. *Br Med J (Clin Res Ed).* Jul 5, 1986;293(6538):5–6.
25. Hallberg T, Wolner-Hanssen P, Mardh PA. Pelvic inflammatory disease in patients infected with Chlamydia trachomatis: in vitro cell mediated immune response to chlamydial antigens. *Genitourin Med.* Aug 1985;61(4):247–51.
26. Simpson SD, Ho Y, Rice PA, Wetzler LM. T lymphocyte response to Neisseria gonorrhoeae porin in individuals with mucosal gonococcal infections. *J Infect Dis.* Sep 1999;180(3):762–73.
27. Money DM, Hawes SE, Eschenbach DA, et al. Antibodies to the chlamydial 60 kd heat-shock protein are associated with laparoscopically confirmed perihepatitis. *Am J Obstet Gynecol.* Apr 1997;176(4):870–7.
28. Arnbjornsson E, Bengmark S. Obstruction of the appendix lumen in relation to pathogenesis of acute appendicitis. *Acta Chir Scand.* 1983;149(8):789–91.
29. Chandy KG, Wulff H, Beeton C, Pennington M, Gutman GA, Cahalan MD. K+ channels as targets for specific immunomodulation. *Trends Pharmacol Sci.* May 2004;25(5):280–9.
30. Kazama I, Maruyama Y, Murata Y, Sano M. Voltage-dependent biphasic effects of chloroquine on delayed rectifier K(+)-channel currents in murine thymocytes. *J Physiol Sci.* May 2012;62(3):267–74.
31. Kazama I, Maruyama Y, Murata Y. Suppressive effects of nonsteroidal anti-inflammatory drugs diclofenac sodium, salicylate and indomethacin on delayed rectifier K+ channel currents in murine thymocytes. *Immunopharmacol Immunotoxicol.* Mar 12, 2012.
32. Kazama I, Sasagawa N, Nakajima T. Complete remission of human parvovirus b19 associated symptoms by loxoprofen in patients with atopic predispositions. *Case Report Med.* 2012;2012:703281.