

Cryolipolysis Conformable-Surface Applicator for Nonsurgical Fat Reduction in Lateral Thighs

Aesthetic Surgery Journal
2015, Vol 35(1) 66–71
© 2015 The American Society for
Aesthetic Plastic Surgery, Inc.
Reprints and permission:
journals.permissions@oup.com
DOI: 10.1093/asj/sju024
www.aestheticsurgeryjournal.com
OXFORD
UNIVERSITY PRESS

W. Grant Stevens, MD, FACS; and Eric P. Bachelor, MD, FACS

Abstract

Background: Vacuum applicators have been effective for cryolipolysis of the abdomen, flanks, inner thighs, back, chest, and arms. However, the lateral thighs have not been easily treated because fat from this area cannot be easily drawn into a vacuum cup.

Objectives: The authors investigated the safety and efficacy of a prototype applicator for treatment of “nonpinchable” fat in the lateral thighs.

Methods: In this prospective, nonrandomized, interventional cohort, multicenter study, a 120-minute unilateral treatment with a prototype conformable-surface applicator was performed on 1 lateral thigh of 40 patients, with the contralateral thigh serving as the control. During follow-up visits at 2 and 4 months, fat reduction was assessed by ultrasound imaging and clinical photography, and patient satisfaction surveys were completed.

Results: Ultrasound data indicated a 2.6-mm mean normalized reduction in fat thickness—a statistically significant reduction vs the untreated control thigh ($P = 7.8E-8$). According to patient survey responses, 89% of patients would recommend the procedure to a friend; 86% were satisfied with cryolipolysis for the lateral thighs; 86% noticed visible fat reduction; and 97% were likely to undergo a second treatment. A panel of 3 independent blinded physicians correctly identified baseline and posttreatment clinical photographs in 87% of cases. There were no serious adverse events or unanticipated adverse device effects.

Conclusions: The cryolipolysis conformable-surface applicator was safe and efficacious for treatment of lateral thigh fat. Clinical photographs and ultrasound results showed significant reduction in fat thickness, and noticeable reduction in undesirable “saddlebag” bulges.

Level of Evidence: 3



Accepted for publication June 12, 2014.

Cryolipolysis has been safe and effective for nonsurgical reduction of subcutaneous fat. It has received FDA clearance for treatment of the flanks (2010, K080521) and abdomen (2012, K120023), and has been used off-label to reduce fat in the back, arms, inner thighs, and chest.¹⁻⁶ Areas with “pinchable” subcutaneous fat are often treated with commercially available cryolipolysis applicators, which use vacuum suction to pull the targeted tissue between parallel cooling plates. However, areas with fibrous fat such as the lateral thighs present a challenge because this type of fat cannot be easily drawn by vacuum suction.

The history and development of cryolipolysis has been well described in review articles.^{7,8} Clinical observations have demonstrated the sensitivity of adipose tissue to cold. The initial description was published in 1902; firm nodules under the chins of children were observed in response to

acute cold injury.⁹ Subsequently, reports of cold-induced panniculitis in young children, teenagers, and adults were published.¹⁰⁻¹³ A case of “popsicle panniculitis” in an infant was reported in 1970; the patient developed a red indurated nodule and subsequent fat loss in the cheek after

Dr Stevens is a Clinical Professor in the Department of Surgery, the Director of the Aesthetics Division of the University of Southern California (USC) Division of Plastic and Reconstructive Surgery, and the Director of the Marina del Rey–USC Aesthetic Surgery Fellowship, Los Angeles, California. Dr Bachelor is a plastic surgeon in private practice in Pleasanton, California.

Corresponding Author:

Dr W. Grant Stevens, 4644 Lincoln Blvd, Suite 552, Marina del Rey, CA 90292, USA.
E-mail: DrStevens@hotmail.com

sucking on a popsicle.¹⁴ Based on these clinical observations, Manstein et al¹⁵ recognized the potential for cold therapy to selectively target undesirable adipose tissue and thus invented cryolipolysis. Their proof-of-concept porcine study, published in 2008, showed significant fat reduction after noninvasive application of cold, without injury to the skin or significant change in serum lipids or liver function.¹⁵ These results were confirmed in a subsequent porcine study.¹⁶ Findings from clinical studies have since demonstrated the safety and efficacy of cryolipolysis in humans.¹⁷⁻¹⁹

Fibrous fat in areas such as the lateral thighs traditionally has been treated by effective but invasive liposuction techniques. Non-surgical techniques were also used, but the authors found radiofrequency heating to have variable efficacy and high intensity focused ultrasound to have poor patient tolerability. A nonvacuum conformable-surface cryolipolysis applicator, developed to address this unmet need, provides an opportunity to clinically study cryolipolysis of previously untreatable “saddlebag” fat.

We investigated the safety and efficacy of a prototype conformable-surface cryolipolysis applicator (CoolSmooth Applicator, CoolSculpting System, Zeltiq Aesthetics, Pleasanton, CA) for reduction of fat in the lateral thighs. Data from this study were incorporated into a regulatory submission that resulted in FDA clearance for cryolipolysis of the thighs (2014, K133212).

METHODS

This prospective, nonrandomized, interventional cohort, multicenter clinical study received approval from the RCRC/Salus Independent Review Board, and was conducted from January 8, 2013 (study initiation) through April 14, 2014 (final patient exit). Eligible participants were men and women age 18 to 65 years who had clearly visible fat on their lateral thighs and a body mass index (BMI) ≤ 30 kg/m². Exclusion criteria included surgical procedures in the area of treatment, non-surgical fat reduction procedures in the area of treatment within the past 6 months, known history of cryoglobulinemia, cold urticaria, and paroxysmal cold hemoglobinuria. The study population comprised 40 subjects all of whom provided written informed consent prior to treatment. All subjects were instructed to avoid major diet or lifestyle changes throughout the study in order to maintain their weight within 5 lb of the baseline value.

Thigh areas to be treated were assessed and marked while the subject was standing. At each of the 2 clinical sites, the same clinician administered treatment and performed assessments at all follow-up visits. No preoperative analgesia or sedation was administered.

Subjects were placed in a lateral recumbent position on Velcro straps. The surface applicator was then securely attached to the patient by the straps (Figure 1). Each subject received 120 minutes of treatment via the prototype applicator to 1 thigh (eg, unilaterally), and the contralateral

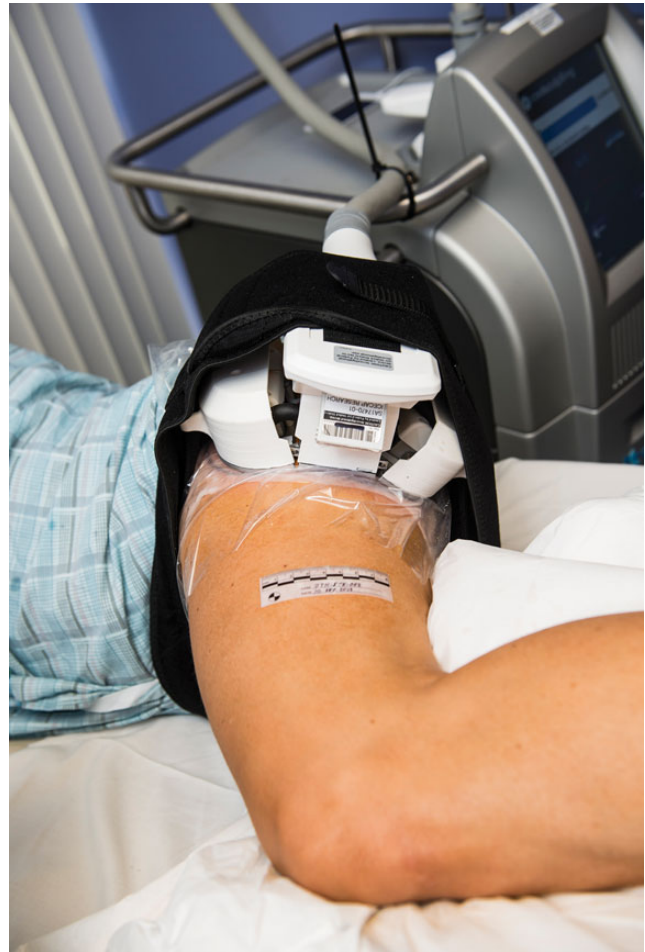

Figure 1. Each patient was placed in the lateral recumbent position, and the conformable-surface applicator was secured over the lateral thigh throughout the 120-minute unilateral cryolipolysis treatment.

thigh served as the control. Treatment was delivered at the default Cooling Intensity Factor setting, at the same temperature as commercial cryolipolysis vacuum applicators. Each study subject was unilaterally treated on one thigh selected by the investigator to have the more distinct bulge. Subjects were able to resume normal activities immediately after treatment but were encouraged to call the study coordinator if unexpected side effects occurred, such as severe, prolonged bruising or swelling lasting more than 1 month or redness lasting more than 2 weeks. There was no specific protocol for posttreatment care, such as the application of compression garments.

Clinical assessments, photographs, and ultrasound images were obtained before treatment (baseline) and at the 8- and 16-week follow-up visits. Patient surveys were administered by the study coordinator, and were completed anonymously by all subjects during each follow-up visit. The survey appears in Appendix A, which may be viewed at www.aestheticsurgeryjournal.com/supplemental.

Subjects were photographed with their feet separated at a fixed distance (11 inches) with a foot positioning guide. To ensure consistency, a standardized photography setup (Nikon D300, Nikon 60-mm lens, DynaLite strobes) was utilized for all photographs. At study completion, photographs were reviewed by 3 blinded independent physicians. Each patient's pretreatment and posttreatment photograph pairs were presented randomly, and reviewers were asked to determine which image was the pretreatment view.

Ultrasound images were acquired with a 7.5-MHz high-resolution linear transducer (SonoSite TITAN, Bothell, WA) and were utilized to measure change in fat thickness. Images of treated and untreated thighs were obtained to permit normalization of fat layer reduction measurements. For each patient, a transparent template was created to align the ultrasound measurement sites with anatomic landmarks, such as moles and scars. These templates enabled the ultrasound

operator to consistently locate the measurement sites at baseline and all follow-up visits. A series of evenly spaced ultrasound images was acquired for all treated and control thighs.

RESULTS

Among the 2 study sites, a total of 40 subjects were enrolled and completed treatment. Three subjects did not return for the 16-week follow-up. Although men were eligible for study inclusion, lateral thigh saddlebags are much more common in women; consequently, all 37 subjects who completed the study were female. Fitzpatrick skin type ranged from I to V. The mean age was 43.2 years (range, 22-65 years), mean weight was 150.3 lb (range, 116.0-199.7 lb), and mean BMI was 25.3 kg/m² (range, 20.7-30.4 kg/m²).

Figures 2 and 3 show baseline and 16-week posttreatment results in 2 representative subjects. Visible reduction

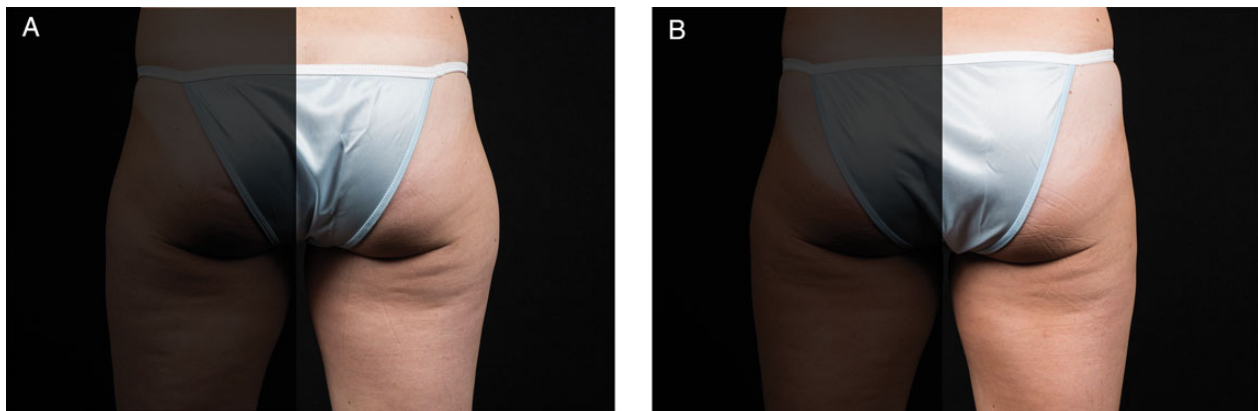


Figure 2. This 44-year-old woman underwent unilateral cryolipolysis of her right thigh to reduce subcutaneous fat. (A) Pretreatment and (B) 16 weeks posttreatment. She gained 2.7 lb since baseline. (Procedure performed by Dr Eric Bachelor, Innovation Research Center.)

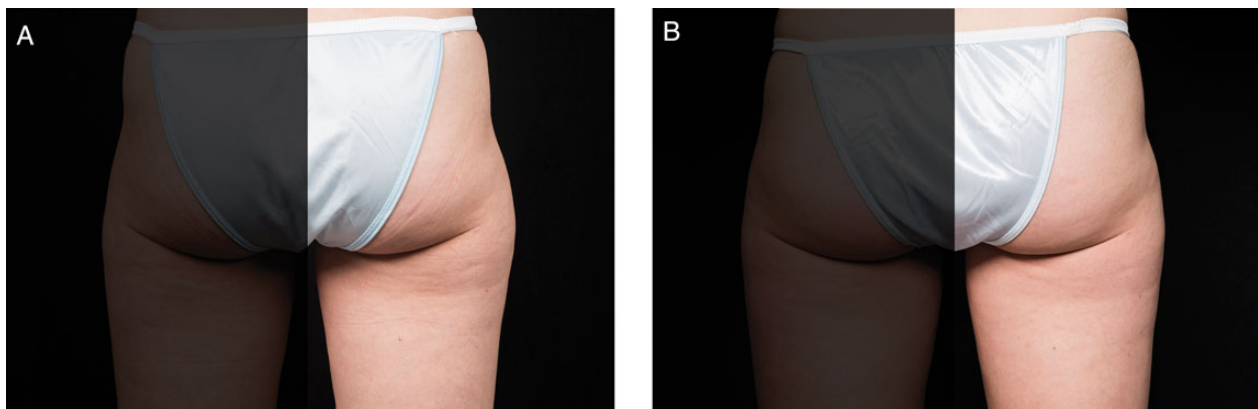


Figure 3. This 33-year-old woman underwent unilateral cryolipolysis of her right thigh to reduce subcutaneous fat. (A) Pretreatment and (B) 16 weeks posttreatment. She gained 1.0 lb since baseline. (Procedure performed by Dr Grant Stevens, Marina Plastic Surgery.)

of the lateral thigh contour is evident between pre- and posttreatment photographs. Figure 4 is an overlay of pre- and posttreatment photographs, demonstrating visible lateral thigh contour reduction from pre- to posttreatment. The 3 blinded independent physicians correctly identified the baseline images in 87% of cases.

Ultrasound images were analyzed to calculate fat layer reduction for treated and untreated thighs. To account for weight fluctuations, fat layer reduction was normalized for the treated thigh against the contralateral control thigh by subtracting any fat layer change measured from the control side. For the 37 subjects that completed the study, ultrasound measurements showed a mean normalized fat layer reduction of 2.6 mm (95% confidence interval [CI]: 1.8 to 3.4; standard error: 0.39 mm; range: +1.5 mm to -10.0 mm). Overall, the mean reduction in fat layer thickness was significantly greater for the treated thighs ($P = 7.86E-8$).

At posttreatment visits, data from the follow-up questionnaire were tabulated for all subjects. At 16 weeks, 86% of subjects noted that the treatment met or exceeded their expectations, 89% would recommend lateral thigh cryolipolysis

to a friend, 97% were likely to undergo a second procedure, and 76% reported that the procedure was comfortable.

At the conclusion of the study, 7 of the 40 subjects received optional equalization treatment to the control thigh. Thirty subjects declined equalization treatment, and 3 were lost to follow-up.

All side effects were transient and typical of cryolipolysis, such as erythema, mild swelling, and numbness. There were 2 reports of device- or procedure-related adverse events: 1 patient experienced prolonged numbness that spontaneously resolved 63 days after the procedure, and another experienced discomfort during the equalization procedure. No serious adverse events were reported.

DISCUSSION

Cryolipolysis vacuum applicators have been utilized in numerous clinical studies. The controlled, noninvasive cooling of subcutaneous fat associated with these devices has been shown to be safe in studies of peripheral nerve function, serum lipid levels, and liver function tests.^{20,21}

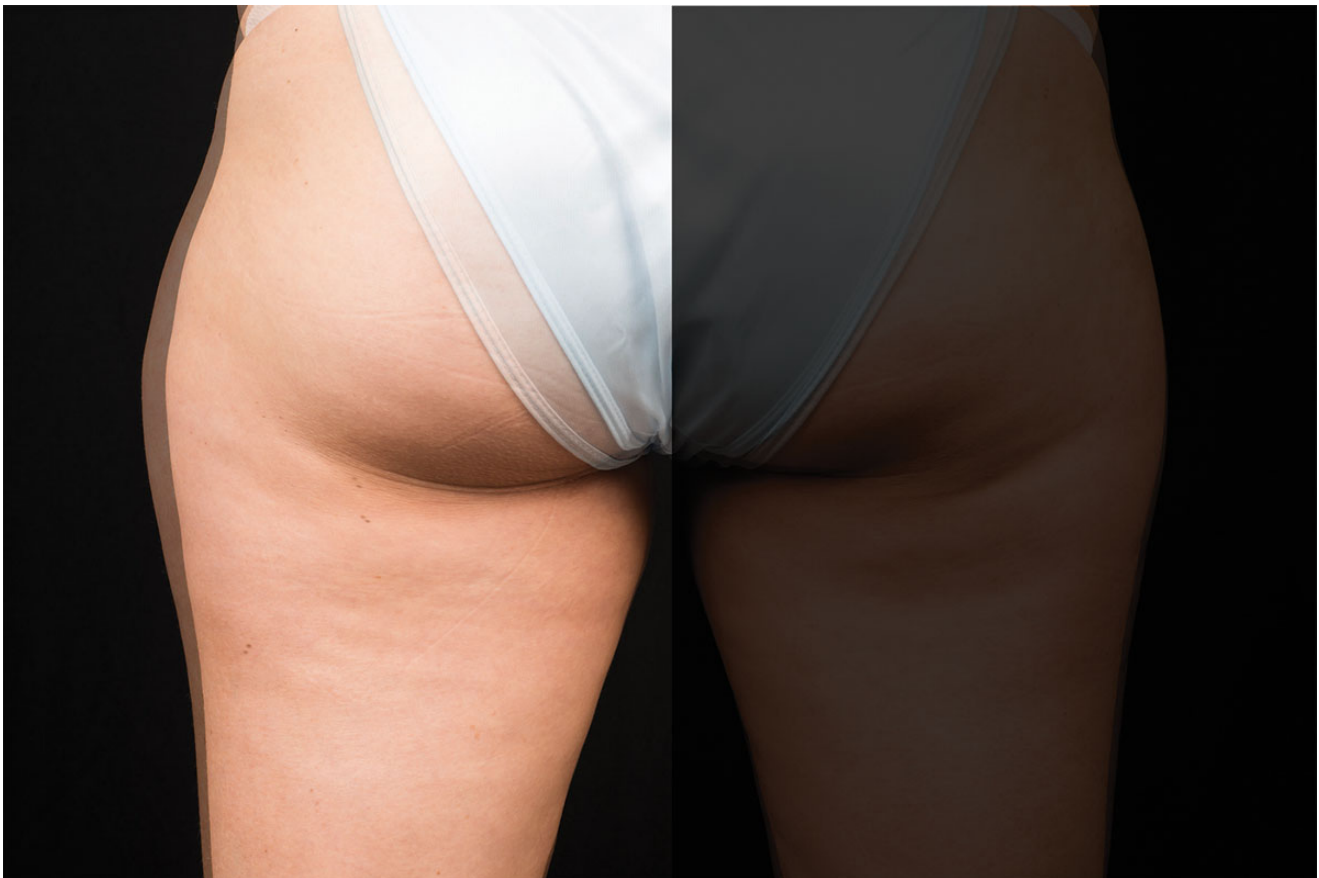

Figure 4. This 41-year-old woman underwent unilateral cryolipolysis of her left thigh to reduce subcutaneous fat. The photographic overlay of baseline and 8-week images shows visible reduction in lateral thigh curvature. The patient gained 5.0 lbs since baseline. (Procedure performed by Dr Grant Stevens, Marina Plastic Surgery.)

Initial clinical studies demonstrated efficacy, safety, and patient satisfaction for cryolipolysis of the abdomen and flanks.¹⁷⁻¹⁹ Subsequent studies have demonstrated the safety and effectiveness off-label treatment of areas including the inner thighs^{4,5} and chest.⁶ Garibyan et al²² conducted a study of unilateral flank treatment to objectively quantify the efficacy of cryolipolysis. Measurements obtained from Vectra 3-dimensional (3D) imaging demonstrated that the average fat volume loss 2 months after a single treatment was 40 cc. Although 3D imaging has been effective for assessing volume reduction from cryolipolysis, 2-dimensional ultrasound measurement was utilized in the present study because depth measurements were sufficient to quantify fat layer reduction.

Numerous retrospective studies of cryolipolysis with vacuum applicators have involved large patient populations and many areas of the body, including the flanks, abdomen, back, arms, knees, banana rolls, and inner thighs. Dierickx et al¹ examined safety, tolerability, and patient satisfaction in 518 patients treated in France and Belgium. Stevens et al² presented initial data on clinical safety, efficacy, patient satisfaction, and commercial viability for 528 patients in California. Sasaki et al³ obtained in vivo temperature measurements during cryolipolysis in 112 patients, and evaluated efficacy by ultrasound, caliper, and scores on the Global Aesthetic Improvement Scale. Despite the favorable findings of these studies, fat from certain areas of the body, such as the lateral thighs and upper abdomen, could not be easily drawn into a vacuum cup and thus was not treatable until a conformable-surface applicator became available.

The nonvacuum conformable-surface cryolipolysis applicator employed in our study demonstrated safety, efficacy, and patient satisfaction for treatment of the lateral thigh. Ultrasound measurements of fat reduction in our analysis are comparable to those in a study of inner-thigh fat reduction with a vacuum applicator.²³ Both methods were associated with the same mean fat reduction (2.6 mm). Although the fat layer reduction observed in our study is modest compared with that of liposuction, our patients were pleased overall with the noticeable reduction in lateral thigh curvature achieved nonsurgically.

A limitation of this study is the fact that only 1 treatment cycle was performed. Although our data show a measurable reduction in lateral thigh fat, patients with larger deposits of saddlebag fat may benefit from multiple treatments to achieve a more aesthetically pleasing outcome. As with treatments involving commercially available applicators, we expect that multiple applicator placements to ensure treatment of the entire area of concern, along with additional visits to reassess and perhaps retreat, will result in greater efficacy and patient satisfaction with the conformable-surface applicator.

Patient survey results showed that a topic of interest is the tolerability of cryolipolysis treatment of the lateral thigh. Although 86% of our subjects reported that the

procedure met or exceeded their expectations, only 76% noted that the experience was comfortable. Nine of 37 subjects (24%) reported discomfort from lying on their side on the treatment table for 120 minutes. Per the study protocol, patients were consistently placed in the lateral recumbent position; however, in subsequent commercial treatments, the prone, supine, and Fowler's (sitting up) positions have been employed. We have also treated both lateral thighs simultaneously with DualSculpting in prone and supine positions, (Zeltiq, Pleasanton, CA), with positive feedback from patients regarding comfort. Comfort can be improved by exploring alternate positions for treatment, because some patients may be unwilling to lie in a lateral recumbent position for 120 minutes unless the treatment table is padded heavily.

Because the target tissue cannot be pulled away from the body and sandwiched between 2 cooling plates (as with vacuum cryolipolysis applicators), treatment time with the surface cryolipolysis applicator was 120 minutes as opposed to 60 minutes, the typical time with vacuum applicators; this ensured appropriate cooling of the lateral thigh fat. No change in treatment temperature was needed with this adjustment.

We have initiated a new clinical study to explore alternate treatment parameters that could be applied to safely and effectively treat lateral thighs in significantly less time.

CONCLUSIONS

Utilization of the cryolipolysis conformable-surface applicator results in safe and efficacious reduction of lateral thigh fat. Photographs and ultrasound data showed significant reduction in fat thickness and noticeable reduction of undesirable saddlebag bulges. Patient satisfaction was high, and most patients were likely to recommend cryolipolysis treatment of the lateral thigh to others. These findings contributed to the April 2014 FDA clearance of cryolipolysis for reduction of fat in the thighs.

Disclosures

Dr Stevens is an investigator for Sientra & Silimed (Santa Barbara, CA), Cohera Medical (Pittsburgh, PA) and Mentor CPG (Santa Barbara, CA); medical luminary for BTL (Framingham, MA), Merz (Greensboro, NC), and Syneron-Candela (Irvine, CA); speaker for Allergan Academy (Irvine, CA) and Cynosure (Westford, MA); consultant for TauTona (Menlo Park CA); medical luminary and speaker for Cutera (Brisbane, CA) and Solta (Hayward, CA); medical luminary, investigator, and speaker for Zeltiq (Pleasanton, CA). Dr Bachelor is an investigator and speaker for Zeltiq; investigator for Allergan Medical; and consultant for Ideal Implant (Dallas, TX).

Funding

This study was sponsored by Zeltiq Aesthetics, manufacturers of the CoolSculpting System. The sponsor provided consumable

study supplies, loan of the study applicator and control unit, ultrasound and photography support, and subject and study-site compensation for treatment and follow-up visits.

Previous Presentation

Presented as a slide/podium at The Aesthetic Meeting, San Francisco, California, April 28, 2014.

REFERENCES

- Dierickx CC, Mazer JM, Sand M, Koenig S, Arigon V. Safety, tolerance, and patient satisfaction with noninvasive cryolipolysis. *Dermatol Surg*. 2013;39(8):1209-1216.
- Stevens WG, Pietrzak LK, Spring MA. Broad overview of a clinical and commercial experience with CoolSculpting. *Aesthet Surg J*. 2013;33(6):835-846.
- Sasaki GH, Abelev N, Tevez-Ortiz A. Noninvasive selective cryolipolysis and reperfusion recovery for localized natural fat reduction and contouring. *Aesthet Surg J*. 2014;34(3):420-431.
- Boey GE, Wasilenchuk JL. Non-invasive fat reduction in the inner thigh using a prototype cryolipolysis applicator. *Lasers Surg Med*. 2013;45(S25):20.
- Zelickson B, Wallander I. Safety and efficacy of cryolipolysis for inner thigh fat reduction. *Lasers Surg Med*. 2013;45(4):282.
- Munavalli G. Cryolipolysis treatment of male pseudogynecomastia. *Lasers Surg Med*. 2013;45(S25):16.
- Jalian HR, Avram MM. Cryolipolysis: a historical perspective and current clinical practice. *Semin Cutan Med Surg*. 2013;32(1):31-34.
- Avram MM, Harry RS. Cryolipolysis for subcutaneous fat layer reduction. *Lasers Surg Med*. 2009;41(10):703-708.
- Hochsinger C. Über eine akute kongelative Zellgewebsverhärtung in der Submentalregion bei Kindern. *Mtschr Kinderheilk*. 1902;1:323-327.
- Haxthausen H. Adiponecrosis e frigore. *Br J Dermatol*. 1941;53:83-89.
- Collins HA, Stahlman M, Scott HW Jr. The occurrence of subcutaneous fat necrosis in an infant following induced hypothermia used as an adjuvant in cardiac surgery. *Ann Surg*. 1953;138:880-885.
- Rotman H. Cold panniculitis in children. Adiponecrosis E frigore of Haxthausen. *Arch Dermatol*. 1966;94:720-721.
- Solomon LM, Beerman H. Cold panniculitis. *Arch Dermatol*. 1963;88:897-900.
- Epstein EH Jr, Oren ME. Popsicle panniculitis. *N Engl J Med*. 1970;82:966-967.
- Manstein D, Laubach H, Watanabe K, Farinelli W, Zurakowski D, Anderson RR. Selective cryolysis: A novel method of non-invasive fat removal. *Lasers Surg Med*. 2008;40:595-604.
- Zelickson B, Egbert BM, Preciado J, et al. Cryolipolysis for noninvasive fat cell destruction: initial results from a pig model. *Dermatol Surg*. 2009;35(10):1462-1470.
- Dover J, Burns J, Coleman S, et al. A prospective clinical study of noninvasive cryolipolysis for subcutaneous fat layer reduction — interim report of available patient data. *Lasers Surg Med*. 2009;41(S21):43.
- Burns JA, Allison J, Bachelor E, Dover J, Coleman S, et al. Analysis of side effects of non-invasive cryolipolysis for subcutaneous fat layer reduction — interim report from controlled clinical trials. *Lasers Surg Med*. 2010;42(S22):21.
- Dover J, Kaminer M, Teahan M, Barrett L. Patient satisfaction at 2 and 6 months after a single non-invasive cryolipolysis treatment for subcutaneous fat layer reduction. *Lasers Surg Med*. 2011;43(S23):968.
- Coleman SR, Sachdeva K, Egbert BM, Preciado J, Allison J. Clinical efficacy of non-invasive cryolipolysis and its effects on peripheral nerves. *Aesthetic Plast Surg*. 2009;33:482-488.
- Klein KB, Zelickson B, Riopelle JG, et al. Non-invasive cryolipolysis for subcutaneous fat reduction does not affect serum lipid levels or liver function tests. *Lasers Surg Med*. 2009;41(10):785-790.
- Garibyan L, Sipprell WH 3rd, Jalian HR, Sakamoto FH, Avram M, Anderson RR. Three-dimensional volumetric quantification of fat loss following cryolipolysis. *Lasers Surg Med*. 2014;46(2):75-80.
- Zelickson BD, Burns AJ, Kilmer SL. Cryolipolysis for safe and effective inner thigh fat reduction. *Lasers Surg Med*. 2015; in press.