

The role of internal fixation in the treatment of femoral head necrosis with ipsilateral hip fracture

Xinguo Zhang, MD^a, Sikai Liu, MD^{b,*}

Abstract

Whether internal fixation or hip arthroplasty is the most appropriate initial treatment for patients with ipsilateral hip fracture and osteonecrosis of the femoral head remains unknown. In this study, the prognoses of patients who underwent internal fixation or hip arthroplasty were analyzed and compared to explore the role of internal fixation in treating such patients.

We retrospectively reviewed 69 patients diagnosed with osteonecrosis of the femoral head and ipsilateral hip fracture from 1999 to 2018. They were divided into the hip arthroplasty or internal fixation group. The visual analog scale and Harris score were used. The incidence of complications and the conversion to arthroplasty were also investigated to further explore the role of internal fixation.

Male patients (male/female: 25/31 vs 20/38, $P = .015$), younger patients (average age: 46.80 ± 13.14 vs 61.07 ± 15.61 , $P < .001$), and patients with femoral neck fractures (fracture type, femoral neck/trochanter: 21/31 vs 12/38, $P = .003$) were more likely to receive 1-stage hip arthroplasty. Of 38 patients undergoing internal fixation, fracture nonunion was identified in 9, and progression of osteonecrosis was identified in 16. Meanwhile, conversion to secondary hip arthroplasty occurred in 13 patients. Four independent risk factors for conversion to secondary hip arthroplasty were identified: age of ≤ 60 years (odds ratio [OR] = 9.786, 95% confidence interval [CI] = 2.735–35.015), male sex (OR = 6.790, 95% CI = 1.718–26.831), collapse of the femoral head before injury (OR = 7.170, 95% CI = 2.004–25.651), and femoral neck fracture (OR = 8.072, 95% CI = 2.153–30.261). A new scoring system was constructed for predicting conversion to hip arthroplasty in patients undergoing internal fixation treatment. A cutoff of ≤ 2 points indicated low risk for conversion, 3 to 4 points indicated moderate risk, and ≥ 5 points indicated high risk.

Patients who underwent internal fixation had worse prognoses than those who underwent 1-stage hip arthroplasty. However, in this study, hip arthroplasty conversion did not occur in most patients who received internal fixation. Using the new scoring system to identify patients who may require conversion to replacement may help make appropriate patient management and clinical decisions.

Abbreviations: ARCO = Association Research Circulation Osseous, JIC = Japanese investigation committee, ONFH = osteonecrosis of femoral head, VAS = visual analog scale.

Keywords: femoral head necrosis, hip arthroplasty, hip fracture, internal fixation

1. Introduction

In some circumstances, ipsilateral hip fracture and osteonecrosis of the femoral head (ONFH) may occur in the same patient.^[1–3] This presentation complicates surgeons' treatment strategy selection process. For instance, if an isolated femoral neck fracture (FNF) is identified in a young patient, internal fixation (IF) should be performed.^[4,5] However, the outcome may be unsatisfactory when the fracture is combined with existing ONFH.^[3] ONFH may progress rapidly after initial surgery.^[2,3] The patient may ultimately require hip arthroplasty (HA). How to treat a patient with ipsilateral ONFH and intertrochanteric fracture is still controversial.^[6]

Generally, HA can achieve satisfactory clinical and functional postoperative outcomes.^[7] However, HA is not the only choice for these patients. One study showed that most patients with Association Research Circulation Osseous (ARCO) stage I and stage II could be cured by surgical or nonsurgical methods.^[8,9] Therefore, IF treatment still plays an important role in managing these special patients.

However, to date, no study has been conducted on the role of IF in treating femoral head necrosis with ipsilateral hip fracture. The indications and curative effects remain unknown. In this study, we investigated patients with ipsilateral hip fracture and ONFH who received IF. We mainly focused on the clinical

Written informed consent was obtained from participants whose radiological data have been published in the journal.

The authors have no funding and conflicts of interest to disclose.

The datasets generated during and/or analyzed during the current study are available from the corresponding author on reasonable request.

This study was approved by the Institutional Review Board of the Third Hospital of Hebei Medical University and was conducted in accordance with the Declaration of Helsinki. As this was a retrospective study and all patient information was deidentified before analysis, informed consent was only required for patients whose radiological images would be published.

All the authors declare that they have no conflict of interest with any organization that sponsored the research.

^a Department of orthopedic, Shenzhen Hospital of Guangzhou University of Chinese Medicine, Shenzhen, People's Republic of China, ^b Department of Osteonecrosis and Hip Surgery, The Third Hospital of Hebei Medical University, Shijiazhuang, Hebei, People's Republic of China.

*Correspondence: Sikai Liu, Department of Osteonecrosis and Hip Surgery, the Third Hospital of Hebei Medical University, No. 139 Ziqiang Road, Shijiazhuang, Hebei Province, People's Republic of China (e-mail: liusikai.sky@hebmh.edu.cn).

Copyright © 2022 the Author(s). Published by Wolters Kluwer Health, Inc. This is an open-access article distributed under the terms of the Creative Commons Attribution-Non Commercial License 4.0 (CCBY-NC), where it is permissible to download, share, remix, transform, and buildup the work provided it is properly cited. The work cannot be used commercially without permission from the journal.

How to cite this article: Zhang X, Liu S. The role of internal fixation in the treatment of femoral head necrosis with ipsilateral hip fracture. *Medicine* 2022;101:32(e29921).

Received: 2 April 2022 / Received in final form: 13 June 2022 / Accepted: 13 June 2022

<http://dx.doi.org/10.1097/MD.00000000000029921>

outcomes of these patients and risk factors associated with IF failure.

2. Patients and Methods

2.1. Participants

Patients diagnosed with ONFH and ipsilateral hip fracture at our hospital from January 1999 to December 2018 were retrospectively included in this study. The exclusion criteria were as follows: age <18 years, secondary osteonecrosis caused by other diseases, pathological fracture due to malignant tumor, sepsis, conservative treatment of hip fracture, and lack of medical records or radiological data. If a patient experienced bilateral ONFH and hip fracture, he or she was considered 2 independent individuals. To improve the comparability of the results, we included both patients undergoing IF and those undergoing HA. Note that the main objective of this study was to evaluate the features of patients undergoing IF rather than to explore the efficacy of HA. As a result, patients undergoing HA were not investigated in detail and were considered a control group. Given that this was an observational study, the initial treatment was determined by the treating surgeon and the patient. The study was approved by the Institutional Review Board of the Third Hospital of Hebei Medical University and was conducted in accordance with the tenets of the Declaration of Helsinki and regulations of the Health Insurance Portability and Accountability Act. As this was a retrospective study and all patient information was deidentified before analysis, informed consent was not required except for from patients whose radiological images would be published.

2.2. Data collection and outcome evaluation

The patient characteristics, such as the demographic information, ONFH etiology and stage, and fracture type, were obtained from medical records and radiological images. The ONFH stage was evaluated by the ARCO classification system.^[8]

The follow-up period was at least 2 years. Pain and hip function evaluations were performed at 4 time points: before hip fracture, 6 weeks after initial surgical treatment, 1 year after initial surgical treatment, and at the final follow-up. The visual analog scale (VAS)^[10] was used to evaluate the pain status, and the Harris score^[11] was used to evaluate hip function. If a patient was converted to HA treatment, the VAS and Harris scores before the secondary HA were recorded.

In patients undergoing IF, 2 types of complications were analyzed: fracture nonunion and ONFH progression. Fracture nonunion was defined as the presence of a fracture line for >1 year or the presence of a fracture line for >6 months with significant bone absorption of the proximal femur. ONFH progression was defined as an increase in the ARCO stage or significant progression of traumatic arthritis secondary to ONFH. If a patient underwent IF initially and subsequently underwent HA, the reason for this conversion and the time between these 2 surgeries were also recorded. Two subjective questions were asked of patients undergoing IF at the final follow-up: "Are you satisfied with the initial IF treatment?" and "Regardless of economic reasons, are you willing to receive HA currently?" The answers were divided into 3 levels (excellent/strong, moderate, and poor) based on the subjective judgment of each patient.

2.3. Statistical analysis

Excel 2016 for Windows (Microsoft Corporation, Seattle WA) and SPSS Version 19.0 statistical software for Windows (IBM,

Armonk, NY) were used for statistical analyses. Continuous variables are expressed as the mean \pm standard deviation. Categorical variables are expressed as frequencies. The Mann-Whitney *U* test was performed for comparisons between continuous variables. The chi-square test was performed for comparisons between categorical variables.

A multivariate logistic regression model was built to identify the potential risk factors for conversion to HA in patients undergoing IF treatment. We did not choose the Cox regression model because many factors, including economic reasons, influenced conversion, and the time between the initial IF and 2-stage HA might have been affected by these factors. A stepwise regression method was used. After constructing the initial regression model, a receiver operating characteristic (ROC) curve was drawn for continuous variables. Then, a cutoff point was made by the Youden index, and the continuous variable was converted into a categorical variable. Next, logistic regression analysis was applied to establish the diagnostic model, including the converted categorical variables above. The odds ratio (OR), 95% confidence interval (95% CI), and β -coefficient were calculated. According to the β -coefficient, clinical significance, and convenience of calculation, a scoring system was built to help predict the conversion to HA in patients undergoing IF treatment. The highest possible score in this system was set as 10 points. The ROC was drawn for this scoring system, and the area under the curve was calculated to estimate its prediction accuracy. Some cutoff points were also given for estimating the risk for conversion to HA. These cutoff points were selected from the coordinate points of the ROC. The conversion risk was considered low if the risk was <30% and high if the risk was >70%. A *P* value of <.05 was considered statistically significant.

3. Results

3.1. Treatment methods

A total of 69 patients were included in this study. All the fractures were unilateral, regardless of the status of primary femoral head necrosis. Thirty-one patients received 1-stage HA treatment, and 38 received IF treatment. Based on their initial procedures, the patients were divided into the HA group and the IF group. The comparison of baseline characteristics between the 2 groups is shown in Table 1. The average age, sex, smoking status, and fracture type differed between the 2 groups. Patients undergoing 1-stage HA were younger (46.80 ± 13.14 vs 61.07 ± 15.61 , $P < .001$), more likely to be male (25/31 vs 20/38, $P = .015$), and comprised a higher proportion of FNF (21/31 vs 12/38, $P = .003$). No other differences were found in the baseline characteristics.

3.2. Comparison of pain and hip function

The Harris and VAS scores differed between the 2 groups at each follow-up, except for the preoperative VAS scores (3.47 ± 1.78 vs 3.56 ± 1.47 , $P = .391$). The Harris score before injury in patients undergoing HA was significantly higher than in patients undergoing IF (71.34 ± 13.17 vs 66.18 ± 12.62 , $P = .001$). The postoperative VAS score decreased gradually, while the Harris score increased, in patients undergoing HA. At the final follow-up, the average VAS and Harris scores were 0.52 ± 0.50 and 95.82 ± 2.65 , respectively, and these patients reported that they were pain-free with good hip function. Unfortunately, the postoperative Harris scores were lower after IF than before injury. During the follow-up period, the changes in Harris scores were not obvious. The VAS scores were all higher than those before injury at 6 weeks postoperatively. The comparison of pain and hip function between the 2 groups is shown in Table 2.

Table 1
Baseline characteristics of patients.

Characteristic	Patients undergoing HA (n = 31)	Patients undergoing IF (n = 38)	P value
Age (yr)	46.80 ± 13.14	61.07 ± 15.61	<.001
Sex			
Male	25	20	.015
Female	6	18	
Smoking			
No	16	30	.017
Yes	15	8	
Alcohol			
No	19	23	.984
Yes	12	15	
Corticosteroid			
No	26	30	.603
Yes	5	8	
ONFH side			
Unilateral	12	16	.775
Bilateral	19	22	
ONFH etiology			
Corticosteroid	5	8	.823
Ethanol	5	6	
Idiopathic	18	21	
Posttraumatic	2	3	
Other	1	0	
JIC stage			
Type A	1	1	.971
Type B	3	4	
Type C1	5	4	
Type C2	11	14	
Collapsed	11	15	
Fracture type			
Femoral neck	21	12	.003
Trochanters	10	26	
Follow-up time (yr)	6.58 ± 2.64	6.31 ± 2.81	.401

HA = hip arthroplasty, IF = internal fixation, JIC = Japanese Investigation Committee, ONFH = osteonecrosis of the femoral head.

3.3. Complications and conversion to HA after IF

Among the 38 patients who initially received IF, fracture nonunion was identified in 9, and progression of osteonecrosis was identified in 16 (Table 3). The majority of the patients (25/38) had an excellent to moderate degree of satisfaction with IF treatment.

Table 2
Evaluation of pain and hip function.

Time	Patients undergoing HA (n = 31)	Patients undergoing IF (n = 38)	P value
Before hip fracture			
Visual analog scale	3.47 ± 1.78	3.56 ± 1.47	.391
Harris score	71.34 ± 13.17	66.18 ± 12.62	.001
6 wk postoperative			
Visual analog scale	2.23 ± 1.03	2.97 ± 1.23	<.001
Harris score	78.82 ± 8.49	58.91 ± 9.29	<.001
1 yr postoperative			
Visual analog scale	1.49 ± 1.14	3.84 ± 1.23	<.001
Harris score	91.07 ± 5.13	57.60 ± 10.19	<.001
Last follow-up			
Visual analog scale	0.52 ± 0.50	3.84 ± 1.23	<.001
Harris score	95.82 ± 2.65	56.14 ± 9.83	<.001

If a patient had undergone IF converted to hip arthroplasty postoperatively, he or she was excluded from the cohort when the arthroplasty was performed.
HA = hip arthroplasty, IF = internal fixation.

Table 3
Disease and life status after initial IF of hip fracture in patients who underwent IF.

Characteristic	Patients converted to HA (n = 13)	Patients not converted to HA (n = 25)	P value
Fracture nonunion			
No	7	22	.019
Yes	6	3	
Progress of ONFH following hip fracture			
No	3	19	.002
Yes	10	6	
Satisfactory degree to IF			
Excellent	1	11	.003
Moderate	3	10	
Poor	9	4	
Willingness of conversion to HA			
Strong	NA	2	
Moderate	NA	5	
Poor	NA	18	
Time from IF to HA (yr)	1.28 ± 0.57	NA	
<1	6	NA	
1–2	5	NA	
>2	2	NA	
Reason for conversion to HA			
Fracture nonunion	6	NA	
Progress of ONFH	6	NA	
Other	1	NA	

HA = hip arthroplasty, IF = internal fixation, NA = not available, ONFH = osteonecrosis of the femoral head.

A total of 13 patients subsequently received second-stage HA. Most of the second-stage hip arthroplasties were performed within 2 years after the initial IF. The average time from initial IF to second HA was 1.28 ± 0.57 years. Six patients received HA due to FNF nonunion, 6 due to osteonecrosis progression and 1 due to other reasons.

Of the 25 patients who did not undergo HA, 2 indicated a strong willingness to receive second-stage HA. Despite the poor Harris score, the other 23 patients shared moderate to low willingness to receive a second surgery.

Besides, the effects of fracture features and Japanese Investigation Committee (JIC) stage on the treatment methods selection and prognosis of patients were also analyzed (Table 4). Compared with the patients undergoing HA, a higher proportion of intertrochanteric fractures (68.42% vs 32.26%) were identified in patients undergoing IF. However, the proportion of nondisplaced FNF (15.79% vs 22.58%), younger aged displaced FNF (10.53% vs 25.81%), and older aged displaced FNF (5.26% vs 19.35%) were lower in patients undergoing IF than that in patients undergoing HA. In comparison between the 2 subgroups (patients undergoing IF who were converted to HA and patients undergoing IF who were not converted to HA), differences were noticed as well. Patients with nondisplaced FNF (38.46% vs 4.00%) and younger-aged patients with displaced FNF (30.77% vs 0.00%) were more likely to convert to HA. Stratified by JIC stage, no differences of proportion were found between patients undergoing HA and IF. However, the proportions of JIC stage were different in 2 subgroups of patients undergoing IF. The proportion of collapsed ONFH was higher in patients who were converted to HA (76.92% vs 20.00%).

3.4. Risk factors and scoring system

A total of 4 independent risk (protective) factors for conversion to HA in patients undergoing IF treatment were initially

Table 4**The effects of fracture features and JIC stage on the selection of treatment methods and patient prognosis.**

	Patients undergoing HA (n = 31)	Patients undergoing IF			P value
		Converted to HA (n = 13)	Not converted to HA (n = 25)	Total (n = 38)	
Fracture features					
Nondisplaced FNF	7 (22.58%)	5 (38.46%)	1 (4.00%)	6 (15.79%)	<.001*
Displaced FNF, <65 yr	8 (25.81%)	4 (30.77%)	0 (0.00%)	4 (10.53%)	
Displaced FNF, ≥65 yr	6 (19.35%)	0 (0.00%)	2 (8.00%)	2 (5.26%)	
Intertrochanteric fractures	10 (32.26%)	4 (30.77%)	22 (88.00%)	26 (68.42%)	
JIC classification					
Type A	1 (3.23%)	0 (0.00%)	1 (4.00%)	1 (2.63%)	.010*
Type B	3 (9.68%)	0 (0.00%)	4 (16.00%)	4 (10.53%)	
Type C1	5 (16.13%)	1 (7.69%)	3 (12.00%)	4 (10.53%)	
Type C2	11 (35.48%)	2 (15.38%)	12 (48.00%)	14 (36.84%)	
Collapsed	11 (35.48%)	10 (76.92%)	5 (20.00%)	15 (39.47%)	

FNF = femoral neck fracture, HA = hip arthroplasty, IF = internal fixation, JIC = Japanese Investigation Committee.

*Comparison between the 2 subgroups (patients undergoing internal fixation converted to hip arthroplasty and patients for whom internal fixation was not converted to hip arthroplasty).

Table 5**Risk factors for conversion to hip arthroplasty in patients undergoing internal fixation.**

Risk (protective) factor	β-coefficient	OR	95% CI for OR	P value
Age, yr				
>60	Ref.			
≤60	2.281	9.786	2.735–35.015	<.001
Sex				
Female	Ref.			
Male	1.915	6.790	1.718–26.831	.006
Collapse of femoral head before injury				
No	Ref.			
Yes	1.970	7.170	2.004–25.651	.002
Fracture type				
Femoral trochanter	Ref.			
Femoral neck	2.088	8.072	2.153–30.261	.002

CI = confidence interval, OR = odds ratio, Ref. = reference.

identified. Among them, age was a continuous variable. The other factors were all categorical variables. Then, the cutoff point for age was identified, which was 60 years. After constructing a new regression model including categorical age, the OR, 95% CI for OR, and β-coefficient were recalculated and are shown in Table 5.

A scoring system for predicting whether a patient will require conversion to HA was developed and is shown in Table 6. This

scoring system included 4 factors, each assigned 2 or 3 points. The final score of a patient was the sum of scores originating from each factor. The area under the curve of this scoring system was 0.880. A cutoff of ≤2 points indicated low risk for conversion, 3 to 4 points indicated moderate risk, and ≥5 points indicated high risk.

4. Discussion

In this study, nearly half of the patients received IF. Young patients, male patients, and patients with FNF were more likely to choose HA instead of IF (Table 1). This may be because male patients and young patients are more active and have a higher demand for hip function.^[12,13] Meanwhile, FNF may largely compromise the blood supply of the femoral head, causing fracture nonunion and rapid progression of ONFH.^[14–17] Hence, patients with FNF were also more likely to receive HA (as demonstrated in Fig. 1). In contrast, in elderly patients, the main treatment goal might be relieving hip pain rather than achieving excellent joint function. Therefore, in these patients, IF was more acceptable in some special situations.^[14]

Previous studies have shown that when IF failed, except revision fixation of the fractures, HA would be indicated in case of femoral head necrosis. In 2008, Hsu et al reported the surgical outcomes of hemiarthroplasty in patients with failed IF and fractures of greater trochanter. The SF-36 questionnaire improved from 41.9 to 82.7 and 15 of 16 patients achieved solid union of greater trochanter.^[18] Later, a study evaluated 16 patients who

Table 6**Scoring system for prediction of conversion to hip arthroplasty in patients undergoing internal fixation treatment.**

Factor	Score
Age, yr	
≤60	3
>60	0
Sex	
Male	2
Female	0
Collapse of femoral head before injury	
Yes	2
No	0
Fracture type	
Femoral neck	3
Femoral trochanter	0

The total score was ≤2 points for low risk (estimated risk ≤30%), 3–4 points for moderate risk (30% < estimated risk <70%) and ≥5 points for high risk (estimated risk ≥70%). The area under the curve of this scoring system was 0.880.

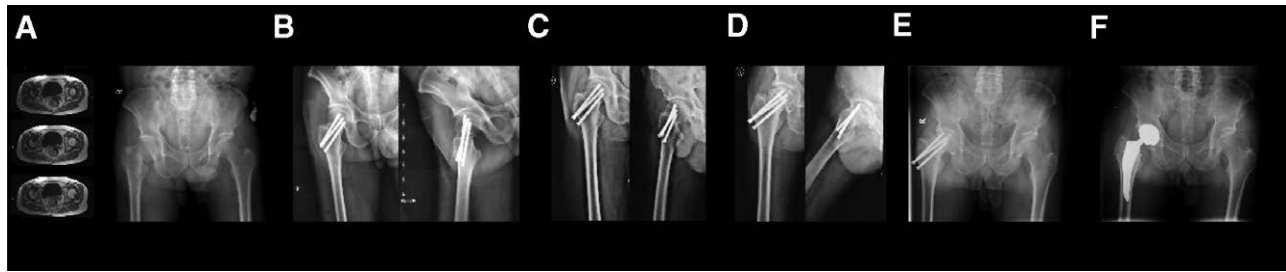


Figure 1. A patient who had internal fixation finally turned to total hip arthroplasty because of the progression of the femoral head necrosis. (A) A 58-year-old male patient was diagnosed with right femoral head necrosis. Three months after the initial diagnosis of osteonecrosis, the patient experienced a right femoral neck fracture due to a fall. (B) The radiograph immediately after the surgery showed that the patient underwent close reduction and internal fixation with 3 screws. (C) Six months after the internal fixation surgery, the radiograph showed that the fracture was union. (D) Two years after the internal fixation surgery, the radiograph showed right femoral head necrosis progression. Compared with the radiograph immediately after the surgery, a significant collapse of the patient's right femoral head was identified. (E) Three years after the internal fixation surgery, the patient's right femoral head collapse continuously progressed, affecting his daily life. (F) The patient ultimately underwent a right 2-stage hip arthroplasty.

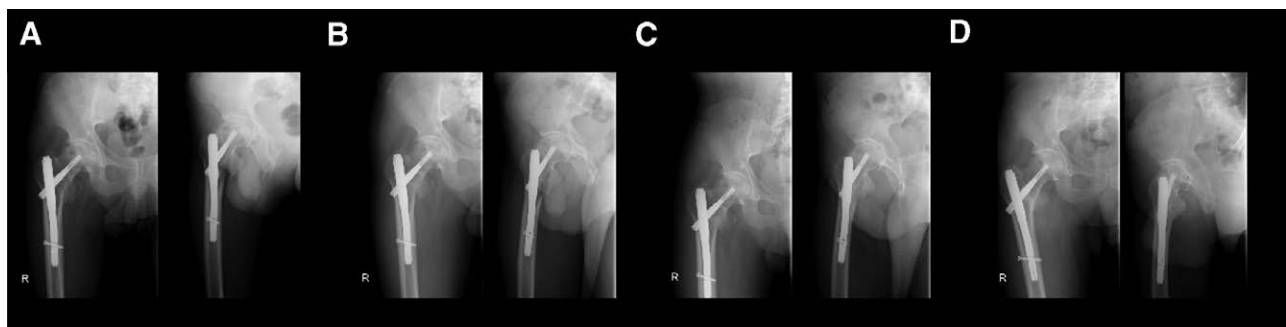


Figure 2. A patient who had PFNA ignored the progression of the femoral head necrosis because of the good function. (A) A 54-year-old male patient was diagnosed with right femoral head necrosis. Two years after the initial diagnosis of osteonecrosis, the patient experienced a right femoral trochanteric fracture due to an accident. The patient underwent internal fixation treatment with a proximal femoral nail to fix the trochanteric fracture. The radiograph immediately after the surgery showed necrosis of the femoral head and trochanteric fracture. (B) Three months after the internal fixation surgery of the trochanteric fracture, the radiograph showed that the trochanteric fracture was partially union. No significant progression of femoral head necrosis was identified. (C) Eight months after the internal fixation surgery of the trochanteric fracture, the radiograph showed that the trochanteric fracture was union. No significant progression of femoral head necrosis was identified. (D) Three years after the initial surgery, despite the collapse of the femoral head, the patient was pain-free without significant movement restriction. Therefore, the patient did not undergo hip arthroplasty. When asking "Are you satisfied with the initial internal fixation treatment?," the patient said "I am fine now and I am so old that I don't need a hip arthroplasty."

suffered from IF failure and converted to HA. The result showed that the Harris Hip Score improved from 17.8 to 87.7 points postoperatively and the pain was relieved remarkably.^[19] More studies have been made and the fact that the conversion to HA would lead to an improvement.^[20,21]

Hip function was significantly worse in patients who underwent IF. After IF, the average Harris score was lower than that before hip fracture and remained at a low level for the whole follow-up period (Table 2). Interestingly, we found that most patients could (or had to) accept this poor hip function. Most patients had excellent to moderate satisfaction with IF treatment, and the goal of some patients was only to regain basic hip function, especially among elderly patients. Therefore, only 34.21% (13/38) of patients subsequently underwent HA. This demonstrates that in a considerable number of patients, IF is a suitable treatment method. Although IF might not perfectly restore joint function, this low-cost, low-risk approach could meet patients' basic needs (as demonstrated in Fig. 2).

However, when the initial IF treatment failed, HA was necessary within a very short period (commonly within 2 years in this study; Table 3). This not only increases the medical cost and patient injury but also complicates the second-stage salvage surgery.^[22] Consequently, the accurate selection of patients is crucial. To fill this gap, we investigated the potential risk factors for conversion to HA in patients undergoing IF (Table 5). A scoring system (Table 6) was developed to help clinical surgeons rapidly evaluate the conversion risk of an IF patient. There were

4 risk factors in this scoring system. A score of ≤ 2 points indicated low risk for conversion, 3 to 4 points indicated moderate risk, and ≥ 5 points indicated high risk. We strongly recommend that patients receive 1-stage HA if they score of ≥ 5 points (conversion risk $>70\%$). Note that due to the sample selection, this scoring system should only be used for patients who originally intended to receive IF treatment rather than for patients already intending to undergo 1-stage HA.

This study has some limitations. First, as a retrospective single-center study with relatively small sample size, some potential confounding factors might not have been eliminated. Second, the baseline patient characteristics between the 2 groups (HA vs IF) differed. Consequently, the ability to compare prognoses between these 2 groups was limited. Finally, the scoring system in this study has not been verified in a prospective study with large sample size.

5. Conclusion

Our findings do not refute that HA may be the optimal choice for osteonecrosis and ipsilateral hip fracture patients. The prognosis of such patients undergoing IF was significantly worse than that of patients undergoing 1-stage HA. However, we noticed that most patients who received IF had not subsequently received HA by the mid-term follow-up. Understanding the risk factors for IF failure and identifying patients who later require HA might facilitate appropriate patient management and clinical decisions.

Author contributions

Both SK Liu and XGZhang made substantial contributions to the conception of this study. They both collected and analyzed the data from the electronic medical record inquiry system. XG Zhang was the major contributor in writing the manuscript text and SK Liu made his effort in preparing the figures and tables. After all SK Liu revised it. They have reviewed and approved the manuscript.

References

- [1] Kim YM, Kim HJ. Pathological fracture of the femoral neck as the first manifestation of osteonecrosis of the femoral head. *J Orthop Sci.* 2000;5:605–9.
- [2] Lee JS, Suh KT. A pathological fracture of the femoral neck associated with osteonecrosis of the femoral head and a stress fracture of the contralateral femoral neck. *J Arthroplasty.* 2005;20:807–10.
- [3] Shah KA, Desai MM. Subcapital Neck of femur fracture in a case of osteonecrosis of femoral head—rare presentation. *J Orthop Case Rep.* 2019;9:87–90.
- [4] Duffin M, Pilson HT. Technologies for young femoral neck fracture fixation. *J Orthop Trauma.* 2019;33(Suppl 1):S20–6.
- [5] Florschutz AV, Langford JR, Haidukewych GJ, et al. Femoral neck fractures: current management. *J Orthop Trauma.* 2015;29:121–9.
- [6] Fukuoka N, Oe K, Sakurai A, et al. Subcapital fracture with avascular necrosis of the whole femoral head after fixation of an intertrochanteric fracture: a case report. *J Orthop Case Rep.* 2020;10:42–4.
- [7] Hart A, Janz V, Trousdale RT, et al. Long-term survivorship of total hip arthroplasty with highly cross-linked polyethylene for osteonecrosis. *J Bone Joint Surg Am.* 2019;101:1563–8.
- [8] Yoon BH, Mont MA, Koo KH, et al. The 2019 revised version of association research circulation osseous staging system of osteonecrosis of the femoral head. *J Arthroplasty.* 2020;35:933–40.
- [9] Zhao D, Zhang F, Wang B, et al. Guidelines for clinical diagnosis and treatment of osteonecrosis of the femoral head in adults (2019 version). *J Orthop Translat.* 2020;21:100–10.
- [10] Aubrun F, Langeron O, Quesnel C, et al. Relationships between measurement of pain using visual analog score and morphine requirements during postoperative intravenous morphine titration. *Anesthesiology.* 2003;98:1415–21.
- [11] Ziran N, Soles GLS, Matta JM. Outcomes after surgical treatment of acetabular fractures: a review. *Patient Saf Surg.* 2019;13:16.
- [12] Yoo JI, Cha Y, Kwak J, et al. Review on basicervical femoral neck fracture: definition, treatments, and failures. *Hip Pelvis.* 2020;32:170–81.
- [13] Guyen O. Hemiarthroplasty or total hip arthroplasty in recent femoral neck fractures? *Orthop Traumatol Surg Res.* 2019;105:S95–S101.
- [14] Xu DF, Bi FG, Ma CY, et al. A systematic review of undisplaced femoral neck fracture treatments for patients over 65 years of age, with a focus on union rates and avascular necrosis. *J Orthop Surg Res.* 2017;12:28.
- [15] Slobogean GP, Sprague SA, Scott T, et al. Complications following young femoral neck fractures. *Injury.* 2015;46:484–91.
- [16] Ehlinger M, Moser T, Adam P, et al. Early prediction of femoral head avascular necrosis following neck fracture. *Orthop Traumatol Surg Res.* 2011;97:79–88.
- [17] Bachiller FG, Caballer AP, Portal LF. Avascular necrosis of the femoral head after femoral neck fracture. *Clin Orthop Relat Res.* 2002;399:87–109.
- [18] Hsu CJ, Chou WY, Chiou CP, et al. Hemi-arthroplasty with supplemental fixation of greater trochanter to treat failed hip screws of femoral intertrochanteric fracture. *Arch Orthop Trauma Surg.* 2008;128:841–5.
- [19] Abouelela AA. Salvage of failed trochanteric fracture fixation using the revitan curved cementless modular hip arthroplasty. *J Arthroplasty.* 2012;27:1382–8.
- [20] Bonneville P, Saragaglia D, Ehlinger M, et al. Trochanteric locking nail versus arthroplasty in unstable intertrochanteric fracture in patients aged over 75 years. *Orthop Traumatol Surg Res.* 2011;97(Suppl 6):S95–100.
- [21] Favreau H, Ehlinger M, Adam P, et al. Total hip arthroplasty with exclusive use of dual-mobility cup after failure of internal fixation in trochanteric fracture. *Orthop Traumatol Surg Res.* 2020;106:645–9.
- [22] Tetsunaga T, Fujiwara K, Endo H, et al. Total hip arthroplasty after failed treatment of proximal femur fracture. *Arch Orthop Trauma Surg.* 2017;137:417–24.