

Immunohistochemistry: A diagnostic aid in differentiating primary epithelial ovarian tumors and tumors metastatic to the ovary

Divya Kriplani, Mandakini M. Patel

Abstract

Introduction: Among cancers of the female genital tract, the incidence of ovarian cancer ranks below only carcinoma of the cervix and the endometrium. Recent years have witnessed significant development in the use of immunohistochemistry in diagnostic ovarian pathology. **Materials and Methods:** We received 95 specimens and biopsies of primary ovarian neoplasms and neoplasms metastatic to the ovary in a period of 2 years. Of these 30 cases were of the primary surface epithelial neoplasms and seven of metastatic tumors. **Discussion:** The most common tumors metastasizing to the ovary originate from the gastrointestinal tract followed by the endometrium. We used a panel of six markers including cytokeratin-7 (CK7), CK20, carcinoembryonic antigen (CEA), cancer antigen 125 (CA125), estrogen receptor (ER) and Wilms' tumor 1 (WT1) to help classify various surface epithelial tumors as well as to differentiate them from tumors metastatic to the ovary. **Conclusion:** CK7 is the most helpful marker to differentiate primary ovarian carcinoma from metastatic colorectal carcinoma of the ovary. Nearly, 96% of ovarian adenocarcinomas were positive for CK7 in contrast to metastatic colorectal, which showed only 25% positivity. We also found that CK7, CK20 and CEA are useful markers to differentiate primary serous tumors from primary mucinous tumors; however, these are less helpful in differentiating ovarian mucinous adenocarcinomas from colorectal adenocarcinomas metastasizing to the ovaries. WT1 helps in typing primary surface epithelial tumors of the ovary and is also significant in determining whether a serous carcinoma within the ovary is primary or metastatic.

Key words: Colorectal carcinoma, endometrial carcinoma, epithelial ovarian neoplasms, immunohistochemistry

Introduction

Ovarian cancers account for total 3%^[1] of all cancers in women and 30% of all cancers of the female genital system.^[2] Among cancers of the female genital tract, the incidence of ovarian cancer ranks below only carcinoma of the cervix and the endometrium. Recent years have witnessed significant development in the use of immunohistochemistry (IHC) in diagnostic ovarian pathology.^[3] Each of the three main categories of ovarian tumors has distinctive immunohistochemical features and stains can be used to suggest or confirm a diagnosis. IHC is often useful to differentiate between primary ovarian adenocarcinoma and metastatic adenocarcinomas specially those of colorectal origin. It is also useful in diagnosing other ovarian metastatic tumors, especially in the absence of a known primary elsewhere. Various markers may also be of value in peritoneal biopsy or fluid specimens when faced with an adenocarcinoma of unknown primary.

Department of Pathology, Government Medical College, Surat, Gujarat, India

Correspondence to: Dr. Divya Kriplani,
E-mail: divya_krips@yahoo.co.in

Access this article online	
Quick Response Code: 	Website: www.sajc.org
	DOI: 10.4103/2278-330X.119888

Materials and Methods

Tissue specimens

A total of 37 cases of primary epithelial and metastatic ovarian neoplasms were collected from pathology files of our institution. Specimens were obtained from patients undergoing surgery for ovarian tumors between 2009 and 2011. Hematoxylin and Eosin (H and E) slides were reviewed in each tumor case and all tumors were classified according to the World Health Organization criteria. The number of cases in each histologic subtype was as follows [Table 1]. The study was approved by the review board and ethics committee. Patient consent was taken by the operating surgeon.

IHC

Tissue was fixed using 10% buffered formalin solution. Five-micrometer sections of formalin fixed paraffin-embedded specimens were cut and immunohistochemical staining was performed using the

Table 1: Total cases included in the study

Neoplasm	Number of cases
Serous ovarian neoplasm	22 (20 adenocarcinoma and 2 borderline)
Mucinous ovarian neoplasm	5 (4 adenocarcinoma and 1 borderline)
Clear cell carcinoma	1
Transitional cell carcinoma	1
Brenner tumor	1
Metastatic colorectal adenocarcinoma	4
Metastatic endometrial adenocarcinoma	3

peroxidase anti-peroxidase method. Fresh citric buffer solution of pH 6 was used for all markers except estrogen receptor (ER) and Wilms' tumor 1 (WT1) (pH 2.5). Antigen retrieval was carried out using a microwave oven. Next a peroxide block was used to prevent background non-specific staining due to endogenous peroxidases. This was followed by the addition of the primary and secondary antibodies and subsequently the addition of the chromogen, 3,3-Diaminobenzidine. Slides were counterstained using H and E, stain. We used a panel of six markers including cytokeratin7 (CK7), CK20, carcinoembryonic antigen (CEA), cancer antigen 125 (CA125), ER and WT1 to differentiate between primary and metastatic ovarian tumors [Table 2].

Immunohistochemical results were evaluated in a semi-quantitative manner and scored according to the percentages of positively staining cells. Cases were divided into the following groups: (-) No staining and only few scattered positive cells (<5%) was considered to be negative; 1 + 5-25% of cells stained; 2 + 25-50% of cells stained; 3 + 50-75% of cells stained; 4 + 75-100% of cells stained.

Only tumor cells stained in the appropriate cytoplasmic/membrane/nuclear position were scored. Focal staining was interpreted as positivity in $\leq 50\%$ of the cells (1+, 2+) and diffuse staining was interpreted as positivity in $>50\%$ of the cells (3+, 4+). For statistical analysis cases with any degree of positive staining (focal or diffuse) were considered positive. Appropriate controls were included.

Results

The mean age of presentation for primary surface epithelial tumors was 49 years (32-70) and for metastatic tumors was 55 years (26-71). Pain was the most common presenting symptom (70.3%) in patients, followed by a lump in abdomen (27%) and abdominal distention (16.2%). Postmenopausal bleeding was seen in 1 case (20%) of primary mucinous carcinoma and two cases (66%) of metastatic endometrial carcinomas.

Bilateralism was seen in 68% of primary ovarian serous carcinomas while, only 4 out of 7 (57.1%) metastatic carcinomas were bilateral.

Histomorphologically, the most common pattern was papillary followed by glandular, solid, nests, trabeculae and micropapillary. Psammoma bodies were seen in 45% of serous carcinomas while 60% primary mucinous carcinomas showed focal calcifications.

Nearly, 50% of primary serous tumors showed the presence of omental metastases at the time of initial surgery, indicating that these tumors are likely to present at a late/advanced stage in the Indian setup.

Among the metastatic colon carcinomas, 3 out of 4 (75%) showed intraluminal necrosis, 2 out of 4 (50%) showed the presence of vascular invasion and 1 (25%) showed capsular invasion. One case showed the presence of calcifications and focal osseous metaplasia.

The metastatic endometrial carcinomas also showed the above features along with extra ovarian spread to cervix and fallopian tubes.

IHC profile in primary surface epithelial tumors of ovary

CK7 was diffusely positive in 18 of the 20 serous adenocarcinomas [Figure 1] and two serous borderline tumors and focal positive in two serous adenocarcinomas. CK20 and CEA were negative in all 22 tumors and 17 tumors reacted with CA125 showing a membranous pattern of staining. ER and WT1 showed a nuclear pattern of staining. ER and WT1 were positive in 8 and 18 tumors respectively. Out of five mucinous tumors, four showed positivity for CK7 and CK20. Positivity for CK7 was diffuse, whereas that for CK20 was focal. Three tumors were positive for CEA and one for CA125. All were negative for ER and WT1. The clear cell carcinoma showed diffuse positivity with CK7, focal positivity with CK20 and CEA and was negative for CA125, ER and WT1. The transitional cell carcinoma was diffusely positive for CK7, CA125 [Figure 2] and WT1 and negative for CK20, CEA and ER. Positivity for WT1 was faint.

In Brenner tumor, CK7 was positive within the epithelial cells present in nests [Figure 3]. Stromal cells were negative. The tumor was negative for CK20, CEA and WT1. Stains for CA125 and ER were not performed in this case.

IHC profile in metastatic ovarian adenocarcinoma

Three of four metastatic colorectal adenocarcinomas were negative for CK7 and CA125. Three showed diffuse and strong positivity for CEA [Figure 4]. All were positive for CK20 [Figure 5] and none reacted with ER and WT1. CK7, CK20 and CEA all showed a cytoplasmic pattern of staining.

All serous ovarian and endometrial adenocarcinomas were positive for CK7 and none showed reactivity with CK20, CEA and WT1. CA125 positivity was seen in two endometrial adenocarcinomas and ER was positive in one.

Table 2: Antibodies used in the study

Antibody	Clone	Company	RTU*/dilution	Control	Pattern of staining
CK7	OV-TL 12/30	Dako	RTU	Kidney	Cytoplasmic
CK20	K _s 20.8	Dako	RTU	Colon	Cytoplasmic
CEA	CEA88	Biogenex	1:50	Colon	Cytoplasmic/luminal
CA125	M11	Dako	RTU	Ovary	Cytoplasmic/membrane
ER	1D5	Dako	RTU	Breast	Nuclear

*RTU=Ready to use, CEA=Carcinoembryonic antigen, ER=Estrogen receptor

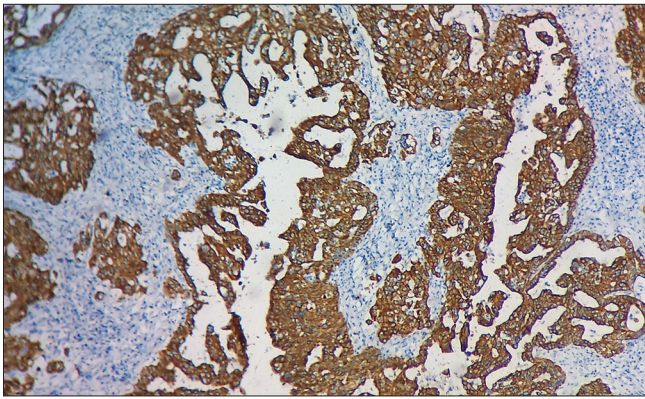


Figure 1: Diffuse, strong cyokeratin 7 cytoplasmic positivity in serous papillary cystadenocarcinoma x10

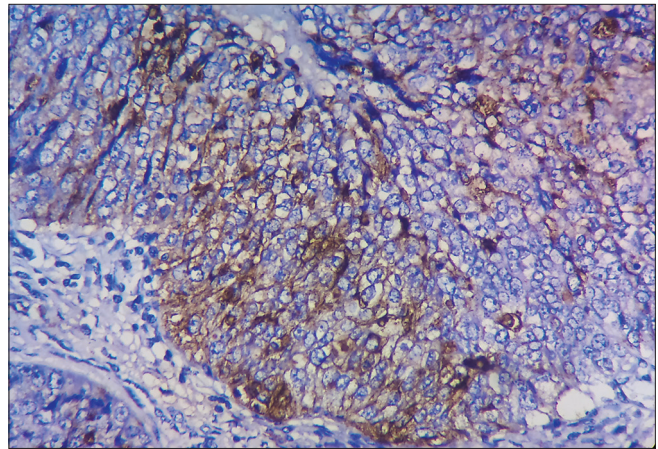


Figure 2: Transitional cell carcinoma of the ovary showing membranous pattern of staining with cancer antigen 125 x40

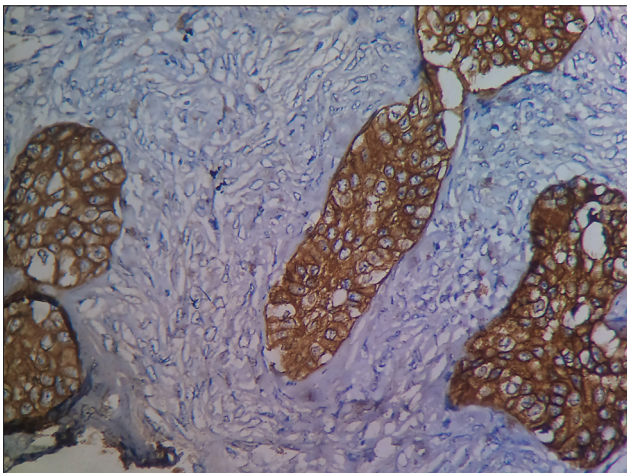


Figure 3: Cytokeratin 7 shows cytoplasmic positivity in epithelial cell nests in Brenner tumor. Stromal cells are negative x40

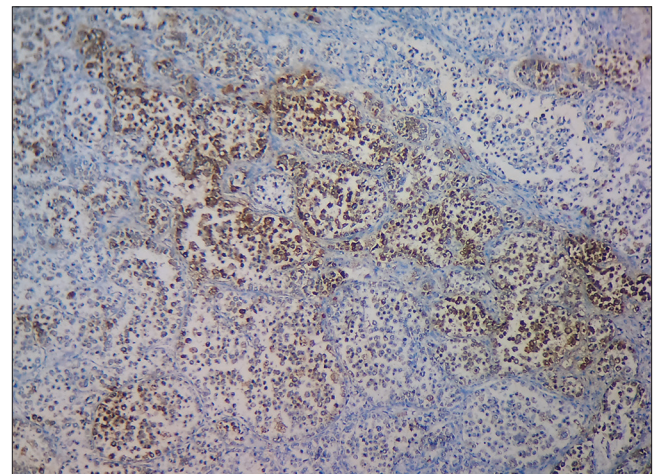


Figure 4: Carcinoembryonic antigen cytoplasmic positivity seen in metastatic colorectal adenocarcinoma x10

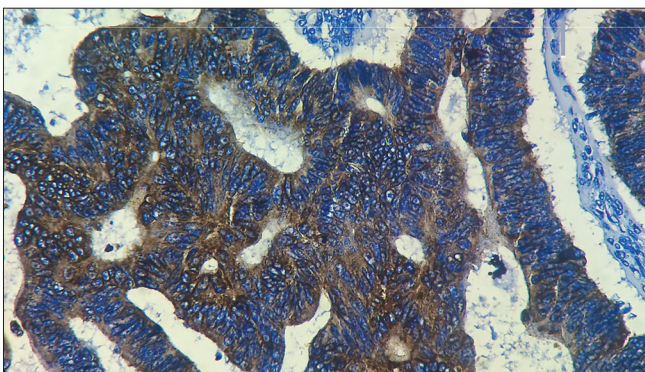


Figure 5: Strong and diffuse cytoplasmic positivity with cytokeratin 20 seen in metastatic colorectal adenocarcinoma x40

Discussion

The ovary is characterized by the occurrence of a wide range of neoplasia with an almost bewildering array of morphological features perhaps more so than any other organ. Although, majority of ovarian neoplasms can readily be categorized by standard morphological examination using routine H and E stained sections, significant problems in diagnosis may occur due to neoplasms of similar or even diverse histogenic origins mimicking each other to a

greater or lesser extent.^[4] In such cases use of IHC plays a significant role in the classification of these tumors.

Koonings *et al.*^[5] and Robbins pathologic basis of disease^[1] also state that the incidence of benign ovarian neoplasms range from 70% to 80% and that of malignant ovarian tumors ranges from 20% to 30%. Our study included 95 cases of which 42% were benign and 58% malignant. The reason for this discrepancy may be that diagnostic facilities have improved greatly over recent years. Sonography is readily available and inexpensive resulting in early detection of malignant masses and their removal. Diet patterns have changed in favor of the western countries where incidence of malignant tumors is higher as compared to the Asian population. Also, this study was carried out in a tertiary institute, which receives patients from a large number of peripheral centers and other surrounding hospitals to be operated. We also receive slides and blocks of difficult cases from other nearby institutes for review and performing IHC; thus, all these independent factors coming together may be a possible reason for the presence of a higher rate of malignant ovarian tumors diagnosed and studied at our center.

Ovaries are commonly involved by tumors originating in the gastrointestinal tract. Though, some histological features may aid in distinguishing between an ovarian primary and metastatic neoplasm it may not always be possible to do so. This distinction is important as the choice of treatment may depend on the origin of the primary. We used a panel of six markers, which included CK7, CK20, CEA, CA125, ER and WT1 to identify the primary location of ovarian neoplasms.

CK7 shows diffuse and strong staining in all serous ovarian tumors.^[6-8] It is positive in 80-100% of mucinous ovarian tumors^[6-10] and other ovarian epithelial tumors also show positivity for CK7. Among the metastatic tumors, metastatic colorectal carcinomas are mostly negative for CK7 while some studies including the present one have reported a positivity of 20-30%.^[11-13] In case of metastatic endometrial adenocarcinomas 90-100% positivity is seen.^[6,14,15] We have found antibody to CK7 to be the most helpful marker in distinguishing between primary ovarian carcinomas and colorectal adenocarcinoma metastatic to the ovary. Moreover, 96% of ovarian adenocarcinomas were positive for CK7 in contrast to metastatic colorectal, which showed only 25% positivity. The reason for this one tumor being positive maybe that right sided and high-grade colonic adenocarcinomas can show CK7 positivity.^[16]

CK20 has been found to be negative in all ovarian^[6,7] serous adenocarcinomas. Goldstein *et al.*^[17] however, reported 9 of 41 cases (22%) to be positive for CK20. Various studies^[6,7,10,11,17] have showed the CK20 positivity in mucinous ovarian neoplasms to range from 40% to 83%.^[6,17] and colorectal adenocarcinomas have been found to show 80-100% positivity^[9,10,14,15] and endometrial serous adenocarcinomas have been found to be negative for CK20.^[6,14]

CEA has been found to be negative in all serous adenocarcinomas.^[7,17] Mucinous ovarian and colorectal adenocarcinoma both show varying percentage of positivity. Colorectal carcinomas^[7,9,18] show more positivity than mucinous ovarian adenocarcinomas.^[9,17,19]

CK20 and CEA are also of value to differentiate serous ovarian from colorectal adenocarcinomas. Serous tumors are generally negative for these two, vice versa being true for colorectal adenocarcinomas. However, a proportion of mucinous adenocarcinomas are positive for CK20 and CEA (positivity is focal as compared to the diffuse pattern in colonic adenocarcinomas); thus, these markers are of less value in differentiating a mucinous adenocarcinoma

from colorectal metastasis. The main finding of our study was that CK7+/CK20-/CEA- primary ovarian carcinomas can readily be distinguished from CK7-/CK20+/CEA+ colorectal metastasis [Table 3]. This applies to all ovarian adenocarcinomas except mucinous type.

Goldstein *et al.*^[17] and Loy *et al.*^[19] have reported a luminal and cytoplasmic pattern of staining in the tumor cells with CA125 in 34 of 41 (83%) and 11 of 12 (92%) of the serous tumors respectively. The present study showed positivity in 13 of 22 (77%) tumors. They also report 17-20% positivity in mucinous tumors. 10-20%^[9,14] of metastatic colorectal carcinomas have been found to show positive results with CA125, whereas metastatic endometrial carcinomas showed 94% positivity in the study by Loy *et al.*^[19] who had studied 35 tumors.

Nearly, 30-40% of serous tumors^[20,21] stain positive for ER. We found one study that employed ER in the differentiation between primary and metastatic ovarian tumors. Dionigi *et al.*^[10] showed that none of the 16 mucinous ovarian tumors and 25 metastatic colorectal adenocarcinomas stained with ER and our results are consistent with these findings.

These findings conclude that CA125 and ER may aid CK7 and CK20 in differentiating primary from metastatic colorectal carcinomas as they are mostly negative in colorectal adenocarcinomas.

Almost all endometrial adenocarcinomas are CK7+/CK20- as is the case in primary ovarian carcinomas. Endometrial adenocarcinomas also express CA125 and ER at a rate almost equal to primary ovarian carcinomas; thus, these markers are not helpful in their differentiation. However, this pattern suggests a common origin of both these tumors from mullerian epithelium.^[6]

Various studies have found WT1 positivity in serous ovarian tumors to range from 77% to 97%^[22,23] with majority tumors showing diffuse and strong nuclear expression. We found two studies comparing WT1 positivity in serous ovarian and endometrial adenocarcinomas. Positivity in metastatic endometrial adenocarcinomas was 0-20%^[23,24] and the tumor cells showed weak staining when positive.

In our study, 82% primary serous adenocarcinomas and none of the metastatic endometrial adenocarcinomas showed positivity with WT1. This supports the fact that WT1 is of significance in differentiating between these two tumors. It helps in finding the primary site of origin of serous adenocarcinoma.

Table 3: Comparative CK7 and CK20 immunohistochemical profiles in different histological types of primary and metastatic ovarian carcinomas

Histological type	Number of cases	CK7+/CK20-	CK7+/CK20+	CK7-/CK20+	CK7-/CK20-
Serous adenocarcinoma	22	22	-	-	-
Mucinous adenocarcinoma	5	1	3	1	-
Metastatic colorectal adenocarcinoma	4	-	1	3	-
Metastatic endometrial adenocarcinoma	3	3	-	-	-

Mucinous tumors,^[17,22,25] clear cell carcinomas^[22,25] and Brenner tumors^[22] have been chiefly found to be negative for WT1 while transitional cell carcinomas^[22] have been found to show positivity. This confirms that WT1 helps in typing primary surface epithelial ovarian tumors, serous and transitional cell carcinomas being positive while other subtypes such as mucinous, clear cell and Brenner tumors are negative.

Conclusion

IHC helps in confirming as well as supporting a diagnosis and when IHC is used a panel of markers should always be employed. The panel should include markers, which are expected to be positive and negative in the various tumors in the differential diagnosis. Use of a single antibody may be misleading. We have found antibody to CK7 to be the most helpful marker in distinguishing between primary ovarian carcinomas and colorectal adenocarcinoma metastatic to the ovary. Primary carcinomas are extensively positive for CK7. CK20 and CEA are also of value to differentiate serous ovarian from colorectal adenocarcinomas. Serous tumors are generally negative for these two, vice versa being true for colorectal adenocarcinomas. However, a proportion of mucinous adenocarcinomas are positive for CK20 and CEA; thus, these markers are of less value to differentiate a mucinous adenocarcinoma from colorectal metastasis.

Almost all endometrial adenocarcinomas are CK7+/CK20- as is the case in primary ovarian carcinomas. Endometrial adenocarcinomas also express CA125 and ER at a rate almost equal to primary ovarian carcinomas; thus, these markers are not helpful in their differentiation. However, this pattern suggests a common origin of both these tumors from müllerian epithelium.

WT1 helps in typing of the primary surface epithelial tumors, serous and transitional cell carcinomas being positive while other subtypes are negative. It is also significant in differentiating between a primary serous ovarian adenocarcinoma (WT1 positive) and a metastatic endometrial serous adenocarcinoma (WT1 negative).

References

- Ellenson LH, Pirog EC. The female genital tract-ovaries. In: Kumar V, Abbas AK, Fausto N, Aster JC, editors. Robbins and Cotran Pathological Basis of Disease. 8th ed. Elsevier; 2010. p. 1039-52.
- Tavassoli FA, Devilee P, editors. World Health Organisation classification of tumors. Pathology and Genetics of tumors of the breast and female genital organs. IARC Press: Lyon 2003.
- Mittal K, Soslow R, McCluggage WG. Application of immunohistochemistry to gynecologic pathology. Arch Pathol Lab Med 2008;132:402-23.
- McCluggage WG, Young RH. Immunohistochemistry as a diagnostic aid in the evaluation of ovarian tumors. Semin Diagn Pathol 2005;22:3-32.
- Koonings PP, Campbell K, Mishell DR Jr, Grimes DA. Relative frequency of primary ovarian neoplasms: A 10-year review. Obstet Gynecol 1989;74:921-6.
- Wauters CC, Smedts F, Gerrits LG, Bosman FT, Ramaekers FC. Keratins 7 and 20 as diagnostic markers of carcinomas metastatic to the ovary. Hum Pathol 1995;26:852-5.
- Berezowski K, Stastny JF, Kornstein MJ. Cytokeratins 7 and 20 and carcinoembryonic antigen in ovarian and colonic carcinoma. Mod Pathol 1996;9:426-9.
- Ueda G, Sawada M, Ogawa H, Tanizawa O, Tsujimoto M. Immunohistochemical study of cytokeratin 7 for the differential diagnosis of adenocarcinomas in the ovary. Gynecol Oncol 1993;51:219-23.
- Legendijk JH, Mullink H, Van Diest PJ, Meijer GA, Meijer CJ. Tracing the origin of adenocarcinomas with unknown primary using immunohistochemistry: Differential diagnosis between colonic and ovarian carcinomas as primary sites. Hum Pathol 1998;29:491-7.
- Dionigi A, Facco C, Tibiletti MG, Bernasconi B, Riva C, Capella C. Ovarian metastases from colorectal carcinoma. Clinicopathologic profile, immunophenotype, and karyotype analysis. Am J Clin Pathol 2000;114:111-22.
- Vang R, Gown AM, Wu LS, Barry TS, Wheeler DT, Yemelyanova A, et al. Immunohistochemical expression of CDX2 in primary ovarian mucinous tumors and metastatic mucinous carcinomas involving the ovary: Comparison with CK20 and correlation with coordinate expression of CK7. Mod Pathol 2006;19:1421-8.
- Logani S, Oliva E, Arnell PM, Amin MB, Young RH. Use of novel immunohistochemical markers expressed in colonic adenocarcinoma to distinguish primary ovarian tumors from metastatic colorectal carcinoma. Mod Pathol 2005;18:19-25.
- Larson L-I, editor. Immunocytochemistry Theory and Practice. Boca Raton, FL: CRC Press; 1988.
- Chu P, Wu E, Weiss LM. Cytokeratin 7 and cytokeratin 20 expression in epithelial neoplasms: A survey of 435 cases. Mod Pathol 2000;13:962-72.
- Wang NP, Zee S, Zarbo RJ, Bacchi CE, Gown AM. Coordinate expression of Cytokeratins 7 and 20 defines unique subsets of carcinomas. Appl Immunohistochem 1995;3:99-107.
- Baker PM, Oliva E. Immunohistochemistry as a tool in the differential diagnosis of ovarian tumors: An update. Int J Gynecol Pathol 2005;24:39-55.
- Goldstein NS, Bassi D, Uzieblo A. WT1 is an integral component of an antibody panel to distinguish pancreaticobiliary and some ovarian epithelial neoplasms. Am J Clin Pathol 2001;116:246-52.
- Rekhi B, George S, Madur B, Chinoy RF, Dikshit R, Maheshwari A. Clinicopathological features and the value of differential cytokeratin 7 and 20 expression in resolving diagnostic dilemmas of ovarian involvement by colorectal adenocarcinoma and vice-versa. Diagn Pathol 2008;3:39.
- Loy TS, Quesenberry JT, Sharp SC. Distribution of CA 125 in adenocarcinomas. An immunohistochemical study of 481 cases. Am J Clin Pathol 1992;98:175-9.
- Burges A, Brüning A, Dannenmann C, Blankenstein T, Jeschke U, Shabani N, et al. Prognostic significance of estrogen receptor alpha and beta expression in human serous carcinomas of the ovary. Arch Gynecol Obstet 2010;281:511-7.
- Karaferic A, Jovanovic D, Jelic S. Expression of HER2/neu, estrogen and progesterone receptors, CA 125 and CA19-9 on cancer cell membrane in patients with serous and mucinous carcinoma of the ovary. J BUON 2009;14:635-9.
- Cathro HP, Stoler MH. The utility of calretinin, inhibin, and WT1 immunohistochemical staining in the differential diagnosis of ovarian tumors. Hum Pathol 2005;36:195-201.
- Goldstein NS, Uzieblo A. WT1 immunoreactivity in uterine papillary serous carcinomas is different from ovarian serous carcinomas. Am J Clin Pathol 2002;117:541-5.
- Al-Hussaini M, Stockman A, Foster H, McCluggage WG. WT-1 assists in distinguishing ovarian from uterine serous carcinoma and in distinguishing between serous and endometrioid ovarian carcinoma. Histopathology 2004;44:109-15.
- Hylander B, Repasky E, Shrikant P, Intengan M, Beck A, Driscoll D, et al. Expression of Wilms tumor gene (WT1) in epithelial ovarian cancer. Gynecol Oncol 2006;101:12-7.

How to cite this article: Kriplani D, Patel MM. Immunohistochemistry: A diagnostic aid in differentiating primary epithelial ovarian tumors and tumors metastatic to the ovary. South Asian J Cancer 2013;2:254-8.
Source of Support: Nil. **Conflict of Interest:** None declared.