

## Calcifying pseudoneoplasm of the neuraxis within the sellar region: illustrative case

Daniel D. Cummins, BS,<sup>1</sup> Ramin A. Morshed, MD,<sup>2</sup> Tarik Tihan, MD, PhD,<sup>3</sup> and Sandeep Kunwar, MD<sup>2</sup>

<sup>1</sup>School of Medicine and Departments of <sup>2</sup>Neurological Surgery and <sup>3</sup>Pathology, University of California, San Francisco, San Francisco, California

**BACKGROUND** There are numerous atypical lesions of the sellar and suprasellar region that are often mistaken for pituitary adenomas. It is important to consider rare mimics of more common pathologies in this region.

**OBSERVATIONS** The authors detail the case of a 37-year-old woman with hypopituitarism who was found to have an atypical sellar mass with slow growth on interval imaging. The lesion was debulked via a microscopic endonasal transsphenoidal approach and found to be a calcifying pseudoneoplasm of the neuraxis (CAPNON).

**LESSONS** CAPNON is a rare disease entity that may affect the sellar region. CAPNON should be on the differential diagnosis for sellar masses that are associated with T1 and T2 hypointensity on magnetic resonance imaging with minimal enhancement. Although CAPNON is not at risk for malignant progression, these benign lesions can continue to grow after a subtotal resection and require follow-up.

<https://thejns.org/doi/abs/10.3171/CASE2286>

**KEYWORDS** sellar; pituitary; calcifying pseudoneoplasm of the neuraxis; CAPNON

More than 90% of sellar lesions that present for transsphenoidal resection are pituitary adenomas,<sup>1,2</sup> with other common lesions including Rathke cleft cysts, craniopharyngiomas, and meningiomas.<sup>1-3</sup> However, numerous additional rare neoplastic, cystic, infectious, and inflammatory lesions have been identified within the sellar and suprasellar region (SSR).<sup>1-4</sup> Therefore, a wide differential diagnosis is often needed when considering the etiology of a sellar mass. Clinical outcomes with SSR lesions significantly correlate with final histopathological diagnosis.<sup>4</sup> Transsphenoidal resection of SSR lesions for definitive histopathological diagnosis may therefore play a crucial role in cases with weak diagnostic certainty based on clinical, laboratory, and radiographic work-up. This case demonstrates a rare sellar lesion: a calcifying pseudoneoplasm of the neuraxis (CAPNON).

### Illustrative Case

#### Preoperative Presentation

A 37-year-old female presented to our institution with a sellar mass with suprasellar extension. The patient had experienced amenorrhea and galactorrhea from age 14, originally attributed to

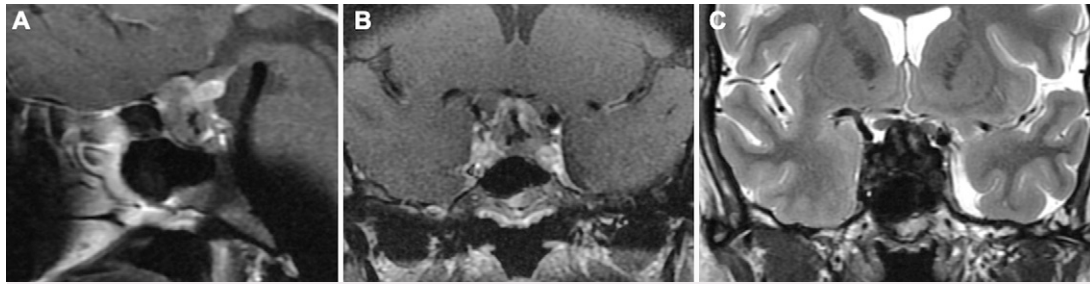
polycystic ovary syndrome. She subsequently developed hypothyroidism at age 18 that was controlled on levothyroxine. Other significant medical history included successful gastric sleeve surgery for obesity. At age 34, the patient was diagnosed with hypopituitarism with hypogonadotropic hypogonadism, central hypothyroidism, and low serum insulin-like growth factor-1; other endocrine function laboratory test results, including prolactin, were within normal range. She reported intermittent headaches at this time but no visual symptoms and was otherwise asymptomatic. Cranial magnetic resonance imaging (MRI) demonstrated a multilobular 1.3 × 1.6 × 1.6-cm sellar mass with suprasellar extension contacting the optic chiasm. The patient was diagnosed with a presumed pituitary adenoma and observed, with normal ophthalmological examination results and controlled endocrine disease until age 37. At this time, interval MRI (Fig. 1) demonstrated growth to 2.0 × 1.4 × 1.8 cm, with irregular patchy enhancement and an area of central hypointensity on T1 and T2. Given the growth of the lesion and the patient's hypopituitarism and need for a diagnosis, the patient was recommended an endonasal transsphenoidal resection.

**ABBREVIATIONS** CAPNON = calcifying pseudoneoplasm of the neuraxis; MRI = magnetic resonance imaging; SSR = sellar and suprasellar region; STR = subtotal resection.

**INCLUDE WHEN CITING** Published April 18, 2022; DOI: 10.3171/CASE2286.

**SUBMITTED** February 17, 2022. **ACCEPTED** February 25, 2022.

© 2022 The authors, CC BY-NC-ND 4.0 (<http://creativecommons.org/licenses/by-nc-nd/4.0/>).



**FIG. 1.** A sellar mass with suprasellar extension measuring  $2.0 \times 1.4 \times 1.8$  cm was observed on MRI before transsphenoidal resection. **A:** Diffuse patchy enhancement within the lesion and a central area of hypointensity was seen on sagittal T1-weighted MRI. **B:** The same findings shown on coronal T1-weighted MRI; contact with the optic chiasm was also observed, although the patient did not have vision changes. **C:** The region of central hypointensity was present on coronal T2-weighted MRI.

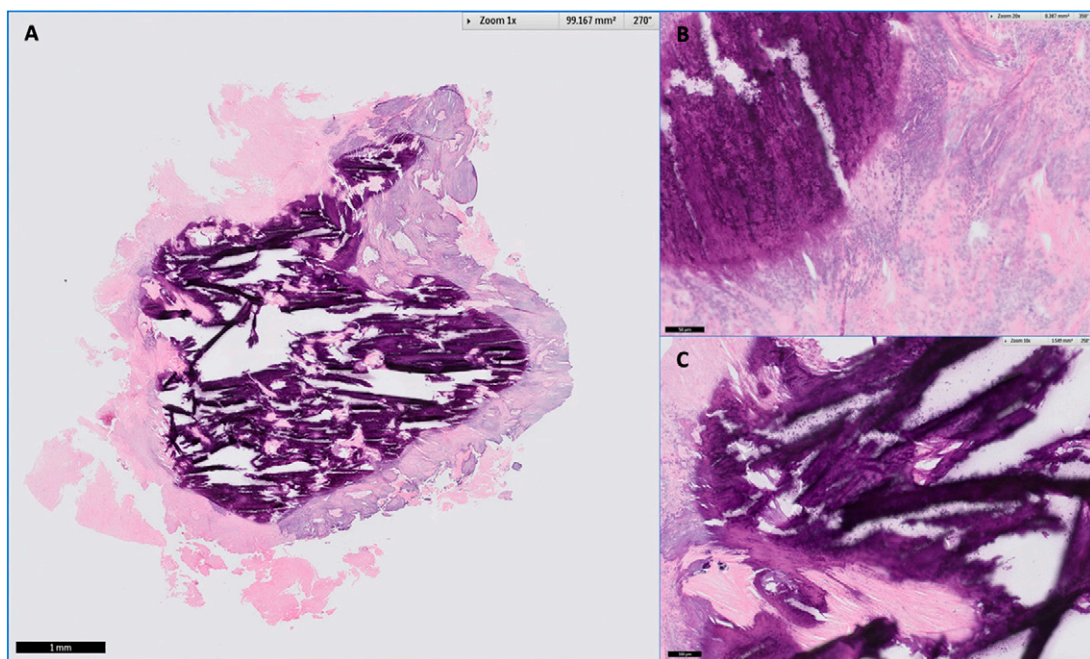
### Surgery

The patient subsequently underwent a microscopic endonasal transsphenoidal approach for attempted resection of the mass. After the sellar dura was exposed, a firm, fibrous, and calcified mass was encountered. The dura was found to be significantly adherent to the underlying lesion, and no normal gland was observed. A biopsy of the mass was obtained and sent for pathology, with intraoperative frozen sections demonstrating a fibrous mass. No observable plane could be developed along the floor or along the cavernous sinus walls on either side, despite multiple attempts. Therefore, the lesion was internally debulked in a piecemeal fashion using a combination of an ultrasonic surgical aspirator, dissection instruments, and a micropituitary rongeur. After significant debulking, a rind of fibrous tissues that was adherent to the cavernous

sinus walls and diaphragma sella was left in place. The patient did well postoperatively, was neurologically intact, and was discharged home on postoperative day 1.

### Pathology

Histological examination of the surgical material revealed findings typically described for lesions classified as a CAPNON.<sup>5,6</sup> Briefly, the mass lesion was composed predominantly of calcifications embedded in an amorphous matrix (Fig. 2). There were only small foci of viable spindle cells with meningotheelial features. The overwhelming majority of the cells demonstrated dystrophic calcification. There were no pituitary cells or foreign body giant cell reactions. There was a thick fibrous tissue on the periphery of the extensively calcified center.



**FIG. 2.** CAPNON within the sellar region. **A:** Whole-mount preparation of the lesion showing extensively calcified nidus and the surrounding fibrous rim (scale bar = 1 mm, zoom  $\times 1$ ). **B:** Higher magnification showing markedly dystrophic cells rimming the large, calcified areas (scale bar = 50 microns, zoom  $\times 20$ ). **C:** Medium-power magnification showing the calcifications with an internal laminar arrangement and the surrounding dystrophic cells outlined by a thick fibrous capsule (scale bar = 100  $\mu$ m, zoom  $\times 10$ ).

## Discussion

### Observations

As their name suggests, CAPNONS can affect any location in the central nervous system.<sup>5,7</sup> CAPNONS have been identified anywhere from the sacral,<sup>8</sup> lumbar,<sup>9</sup> thoracic,<sup>10</sup> and cervical spine<sup>9</sup> to within the cranium in the posterior fossa<sup>11</sup> or anterior fossa<sup>12</sup> and throughout the skull base.<sup>13,14</sup> Reports of CAPNON affecting the sellar region are scarce and have previously not been confined to the SSR alone.<sup>15</sup> Given the rarity of CAPNONS, these lesions are unsurprisingly misdiagnosed with great frequency. Skull base CAPNONS are most often mistaken for meningiomas, given their radiographic and gross tissue similarities.<sup>14</sup> A number of groups have consistently found CAPNONS to be primarily T1 and T2 hypointense on MRI, consistent with extensive calcification,<sup>5,7,16</sup> as was seen in this case. Diffuse hyperintensity on computed tomography also indicates CAPNON calcification, and the lesion will typically have minimal enhancement with contrast.<sup>16</sup> Although vasogenic edema with CAPNONS was not present in this case and is often absent,<sup>5</sup> edema has been reported in a number of cases.<sup>6,16,17</sup> The radiographic features of CAPNONS may be nonspecific, but atypical radiographic findings for the location of interest may suggest the diagnosis.

The largest report on CAPNONS detailed findings for 37 patients from a single center. One important result from this work was a high documented rate (93%) of dural attachment,<sup>16</sup> as was experienced operatively in this case. In a challenging surgical location such as the SSR, dura-based attachment, extensive calcification, and adherence to neighboring critical neurovascular structures may prevent a safe gross total resection without risking injury. CAPNONS are notably a benign lesion, possibly of reactive or inflammatory etiology, and do not carry a risk of malignant progression.<sup>7,16</sup> However, cases with subtotal resection (STR) are at risk of interval progression that may require repeat surgery to alleviate symptoms due to mass effect. Progression after STR ranged from 14 to 125 months from the time of surgery in a recent review.<sup>7</sup>

### Lessons

CAPNON is a rare disease entity that may affect the sellar region and may mimic other more common tumors in this region, including pituitary adenomas and meningiomas. This case illustrates the broad differential diagnosis that is needed when assessing atypical lesions of the SSR and is a reason why tissue diagnosis is often required for patient management. CAPNON should be included in the differential diagnosis for sellar masses that are associated with T1 and T2 hypointensity on MRI with minimal enhancement. Although CAPNON is not at risk for malignant progression and does not require adjuvant chemotherapy or radiation therapy, these benign lesions can continue to grow after STR and require postoperative imaging follow-up.

## References

1. Freda PU, Wardlaw SL, Post KD. Unusual causes of sellar/parasellar masses in a large transsphenoidal surgical series. *J Clin Endocrinol Metab.* 1996;81(10):3455–3459.
2. Valassi E, Biller BM, Klibanski A, Swearingen B. Clinical features of nonpituitary sellar lesions in a large surgical series. *Clin Endocrinol (Oxf).* 2010;73(6):798–807.
3. Thakkar K, Ramteke-Jadhav S, Kasaliwal R, et al. Sellar surprises: a single-centre experience of unusual sellar masses. *Endocr Connect.* 2020;9(2):111–121.
4. Petrakakis I, Pirayesh A, Krauss JK, Raab P, Hartmann C, Nakamura M. The sellar and suprasellar region: a “hideaway” of rare

- lesions. Clinical aspects, imaging findings, surgical outcome and comparative analysis. *Clin Neurol Neurosurg.* 2016;149:154–165.
5. Aiken AH, Akgun H, Tihan T, Barbaro N, Glastonbury C. Calcifying pseudoneoplasms of the neuraxis: CT, MR imaging, and histologic features. *AJNR Am J Neuroradiol.* 2009;30(6):1256–1260.
6. Safaee MM, Jonzson S, López GY, et al. Perilesional edema associated with an intracranial calcifying pseudoneoplasm of the neuraxis in a child: case report and review of imaging features. *J Neurosurg Pediatr.* 2018;22(5):528–531.
7. Yang K, Reddy K, Chebib I, Hammond R, Lu JQ. Calcifying pseudoneoplasm of the neuraxis: from pathogenesis to diagnostic and therapeutic considerations. *World Neurosurg.* 2021;148:165–176.
8. Wu HG, Yue L, Luo CJ, Wei ZH, Wang S, Zheng ND. Calcifying pseudoneoplasm of the neuraxis arising from the sacral canal: case report and review of the literature. *World Neurosurg.* 2017;98:875.e9–875.e12.
9. García Duque S, Medina Lopez D, Ortiz de Méndivil A, Diamantopoulos Fernández J. Calcifying pseudoneoplasms of the neuraxis: report on four cases and review of the literature. *Clin Neurol Neurosurg.* 2016;143:116–120.
10. Muccio CF, Cerase A, Leone A, et al. Calcifying pseudoneoplasm of the neuraxis. two case reports and review of CT and MR findings. *Neuroradiol J.* 2012;25(4):453–459.
11. Benson JC, Trejo-Lopez J, Boland-Froemming J, Pollock B, Hunt CH, Wald JT. Calcified pseudoneoplasm of the neuraxis. *AJNR Am J Neuroradiol.* 2021;42(10):1751–1754.
12. Blood TC, Rodriguez FJ, Nolan N, Ramanathan M Jr, Desai SC. Anterior cranial fossa calcifying pseudoneoplasm of the neuroaxis—diagnosis using a transblepharoplasty approach. *J Neurol Surg Rep.* 2018;79(3):e75–e78.
13. Yan L, Dileep Menon P, Heim-Hall J, Hackman S. Calcifying pseudoneoplasm of the neuraxis involving the posterior skull base: a case report and literature review. *Int J Surg Pathol.* 2021;29(7):733–739.
14. Yang K, Reddy K, Ellenbogen Y, Wang BH, Bojanowski MW, Lu JQ. Skull base calcifying pseudoneoplasms of the neuraxis: two case reports and a systematic review of the literature. *Can J Neurol Sci.* 2020;47(3):389–397.
15. Bertoni F, Unni KK, Dahlin DC, Beabout JW, Onofrio BM. Calcifying pseudoneoplasms of the neural axis. *J Neurosurg.* 1990;72(1):42–48.
16. Ho ML, Eschbacher KL, Paolini MA, Raghunathan A. New insights into calcifying pseudoneoplasm of the neuraxis (CAPNON): a 20-year radiological-pathological study of 37 cases. *Histopathology.* 2020;76(7):1055–1069.
17. Barber SM, Low JCM, Johns P, Rich P, MacDonald B, Jones TL. Calcifying pseudoneoplasm of the neuraxis: a case illustrating natural history over 17 years of radiologic surveillance. *World Neurosurg.* 2018;115:309–319.

### Disclosures

The authors report no conflict of interest concerning the materials or methods used in this study or the findings specified in this paper.

### Author Contributions

Conception and design: Morshed, Kunwar. Acquisition of data: Morshed, Tihan. Analysis and interpretation of data: all authors. Drafting the article: Morshed, Cummins. Critically revising the article: Morshed, Cummins. Reviewed submitted version of manuscript: all authors. Approved the final version of the manuscript on behalf of all authors: Morshed. Administrative/technical/material support: Tihan. Study supervision: Morshed, Kunwar.

### Correspondence

Ramin A. Morshed: University of California, San Francisco, San Francisco, CA. [ramin.morshed@ucsf.edu](mailto:ramin.morshed@ucsf.edu).