

## Variable clinical profile of foveal hypoplasia in albinism

Kshitiz Kumar, Subhendu K Boral, Deepak Agarwal,  
Angshuman Goswami, Tushar K Sinha,  
Debashish Bhattacharya

**Key words:** Albinism, dome-shaped macula, foveal hypoplasia

Clinical profiles of three patients are enumerated in Table 1.


Fundus examination of both eyes showed albinotic retina with grossly hypopigmented retinal pigment epithelium (RPE) with the visualization of choroidal vasculature and an absent foveal reflex in all three cases. Ultra-widefield fundus imaging and angiography were captured centrally and peripherally using the Optos 200Tx (Optos, Dunfermline, UK) in 3<sup>rd</sup> patient showing the lack of pigment in RPE, failure of retinal vasculature to “wreath” the fovea, small vessels crossing the macular area and forming direct anastomoses with superior and inferior vessels, and prominent silhouette of medium and large choroidal vessels in contrast to the sclera [Fig. 1a-f]. Spectral domain optical coherence tomography (SD-OCT) using the SPECTRALIS (Heidelberg Engineering, Heidelberg, Germany) of both eyes confirmed grade 4 foveal hypoplasia characterized by the absence of the foveal pit at the expected location of anatomic fovea, incursion of inner plexiform layers and inner nuclear layers traversing the foveola as continuous bands, the absence of widened outer nuclear layer (ONL) and lack of outer segment (OS) lengthening (suggestive of cone specialization) and overall thickening of retina in all three cases.

On enhanced depth imaging (EDI)-OCT, the entire macular region comprising retina and the choroid—RPE complex was flat in case 1 [Fig. 2a and b], had smooth-rising anterior convex bulge of choroid-RPE complex suggestive of “dome-shaped” macula on vertical cross-section in case 2 [Fig. 3a and b], and had anterior convex bulge forming marked “dome-shaped” macula (DSM) on both horizontal and vertical cross-sectional scans in case 3 [Fig. 4a and b]. The above findings were consistent with ocular albinism (OA) except for DSM. Patients were advised for low vision aid trial and to use photochromic glasses. The patients were asked to have regular follow-up along with dermatology opinion.

Oculocutaneous albinism (OCA) represents a range of inherited, congenital disorders of hypomelanosis, typically involving the skin, hair, and eyes with an estimated prevalence of 1 in 17,000 cases. Ocular findings across different types of OCA are same and include various degrees of nystagmus, iris heterochromia, hypopigmentation of RPE, foveal hypoplasia, subnormal vision in the range of 20/60 to 20/400, refractive errors, and sometimes a degree of color vision impairment.<sup>[1]</sup> The absence or poor definition of the foveal pit at the center of the macula is normally called foveal hypoplasia which accounts for poor visual acuity (VA) and nystagmus.<sup>[2]</sup> Thomas *et al.* described the grades of foveal hypoplasia. They were distinguished as grade 1: shallow foveal pit, the presence of ONL widening, presence of OS lengthening with median VA=0.2; grade 2: grade 1 but absence of foveal pit, grade 3: grade 2 but absence of OS lengthening; grade 4: grade 3 but absence of ONL widening with progressively poorer VA with a median VA of 0.44, 0.60, and 0.78 logMAR, respectively.<sup>[3]</sup>

However, in this case series, in the first two cases best-corrected visual acuity (BCVA) was 0.60 (Snellen scale 6/24) with grade 4 hypoplasia, whereas in the third case, BCVA was 0.50 logMAR (Snellen scale 6/18) despite the same grade of hypoplasia. Also, the degree of myopia did not correlate with the grade of foveal hypoplasia.

Abnormal convex, anterior protrusion of macula including the retina, RPE, and choroid was described as DSM by Gaucher *et al.*<sup>[4]</sup> EDI-OCT-based study has established DSM resulting from the localized thickening of the sclera in myopic patients.<sup>[5]</sup>

Access this article online	
Quick Response Code:	Website: www.ijo.in
	DOI: 10.4103/ijo.IJO_905_19

Department of Vitreo-Retina, Disha Eye Hospital, Kolkata, West Bengal, India

**Correspondence to:** Dr.Kshitiz Kumar, Department of Vitreo-Retina, Disha Eye Hospital, Barrackpore, Kolkata - 700 120, West Bengal, India. E-mail: kshitiz\_k@rediffmail.com

Received: 20-Jun-2019

Revision: 10-Sep-2019

Accepted: 23-Oct-2019

Published: 16-Mar-2020

This is an open access journal, and articles are distributed under the terms of the Creative Commons Attribution-NonCommercial-ShareAlike 4.0 License, which allows others to remix, tweak, and build upon the work non-commercially, as long as appropriate credit is given and the new creations are licensed under the identical terms.

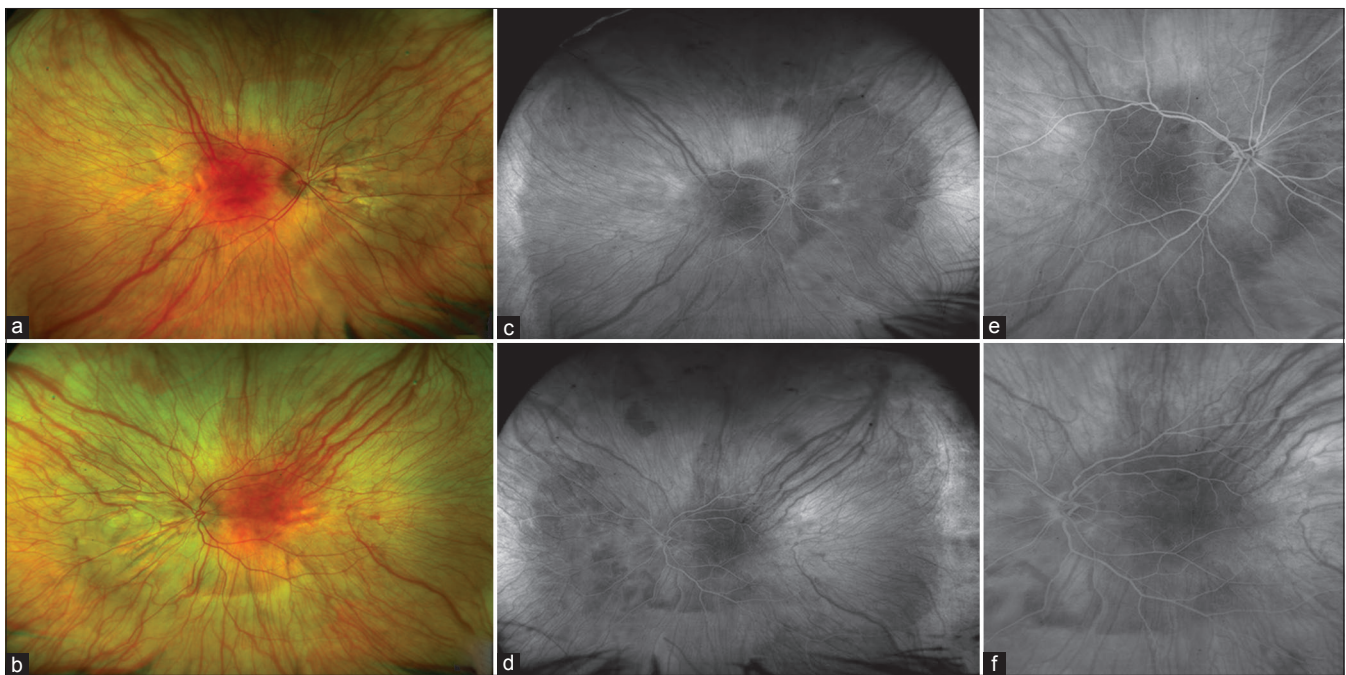
**For reprints contact:** reprints@medknow.com

**Cite this article as:** Kumar K, Boral SK, Agarwal D, Goswami A, Sinha TK, Bhattacharya D. Variable clinical profile of foveal hypoplasia in albinism. Indian J Ophthalmol 2020;68:649-51.

**Table 1: Demography & clinical characteristics of patients**

	Case 1	Case 2	Case 3
Age (years)	7	6	40
Gender	M	M	F
Photophobia	+	+	+
Nystagmus	+	+	+
Refraction and BCVA	plano/-2.00DS*10°6/36 OD, plano/-2.5DS*180 6/24 OS, N6 OU	-3.50DS/-1.50DS*110°6/24 OD, -2.75DS/-2.00DC*15°6/24 OS, N6 OU	-8.00ds/-2.00DS*10°6/18 OD, -8.50DS/-2.50DC*175°6/18 OS; +2.00DS N6 OU
Light colored irides	+	+	+
Iris transillumination	+	+	+
Cutaneous albinism	Not present	Present	Present
Grade of foveal hypoplasia	Grade 4	Grade 4	Grade 4

Anterior segment and clinical Features of three patients. BCVA: Best-corrected visual acuity



**Figure 1:** Ultra widefield (UWF) color fundus photograph of the right (a) and left eye (b) showing the lack of pigment in the retinal pigment epithelium and visible large choroidal vessels. UWF fluorescein angiography (FA) photographs of the right (c) and left eye (d) showing a prominent silhouette of medium and large choroidal vessels up to periphery. Magnified FA photograph of the posterior pole of the right eye (e) and left eye (f) showing an absence of foveal avascular zone (FAZ) with retinal vessels crossing macula and forming an anastomosis. All the images are of case 3

Recent studies have established the prevalence of DSM in high myopia populations across various ethnic groups worldwide with a frequency of 10.7–20.1%.<sup>[6]</sup> OA with DSM is a rare association that has been reported only once in the literature.<sup>[7]</sup>

In this case series, we didn't observe DSM in the first patient who had simple myopic astigmatism only. In the second patient with moderate myopia, DSM was present along vertical cross-section only and not markedly elevated. Whereas, in the third patient with high myopia, DSM was prominent with the global involvement of macula. These findings are consistent with the above literature on DSM in increasing grades of myopia.

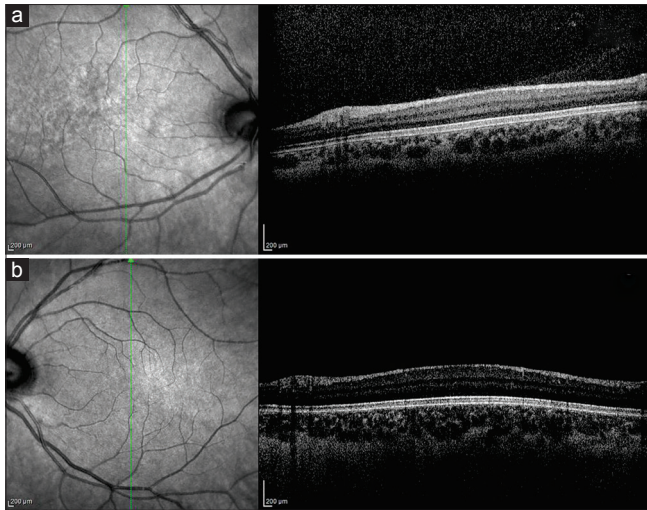
Different grades of DSM with foveal hypoplasia in OA and OCA in this case series make it an interesting observation. However, the clinical implication of DSM with foveal hypoplasia in albinism needs to be analyzed in a larger cohort of patients. Through this case series, we highlight different grades of underlying sclerochoroidal morphology of foveal hypoplasia in proportion with the amount of refractive error in albinism.

#### Financial support and sponsorship

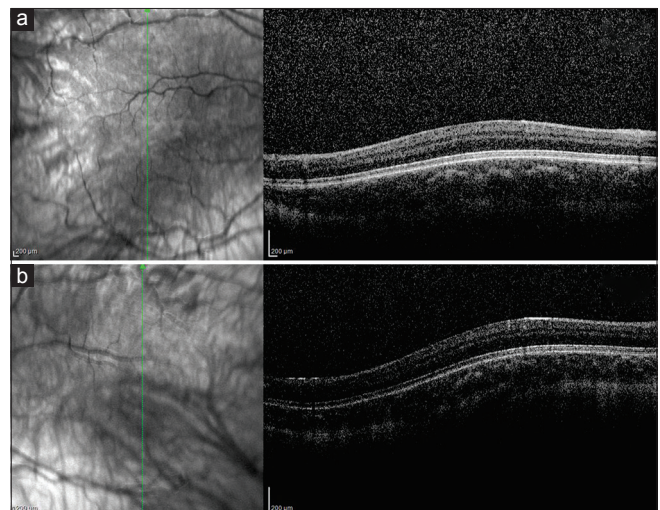
Nil.

#### Conflicts of interest

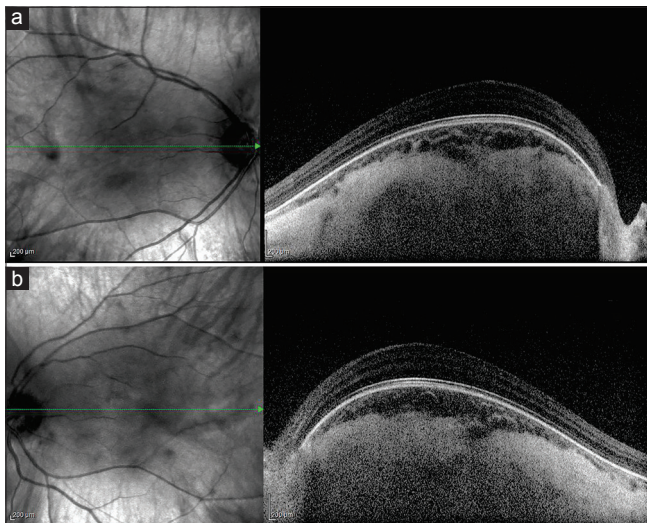
There are no conflicts of interest.



**Figure 2:** Spectral domain-optical coherence tomography (SD-OCT) with enhanced depth imaging (EDI) images of case 1 of right (a) and left (b) eye showing grade 4 foveal hypoplasia on a vertical cross-section



**Figure 3:** SD-OCT with EDI images of case 2 of right (a) and left (b) eye showing grade 4 foveal hypoplasia with the slight dome-shaped contour of macula on a vertical cross-section



**Figure 4:** SD-OCT with EDI images of case 3 of right (a) and left (b) eye showing grade 4 foveal hypoplasia with thickened sclera leading to the marked dome-shaped macula on a horizontal cross-section

## References

1. Grønskov K, Ek J, Brøndum-Nielsen K. Oculocutaneous albinism. *Orphanet J Rare Dis* 2007;2:43.
2. Vincent A, Kemmanu V, Shetty R, Anandula V, Madhavarao B, Shetty B. Variable expressivity of ocular associations of foveal hypoplasia in a family. *Eye (Lond)*2009;23:1735-9.
3. Thomas MG, Kumar A, Mohammad S, Proudlock FA, Engle EC, Andrews C, *et al*. Structural grading of foveal hypoplasia using spectral-domain optical coherence tomography a predictor of visual acuity? *Ophthalmology* 2011;118:1653-60.
4. Gaucher D, Erginay A, Leclaire-Collet A, Haouchine B, Puech M, Cohen SY, *et al*. Dome-shaped macula in eyes with myopic posterior staphyloma. *Am J Ophthalmol* 2008;145:909-14.
5. Imamura Y, Iida T, Maruko I, Zweifel SA, Spaide RF. Enhanced depth imaging optical coherence tomography of the sclera in dome-shaped macula. *Am J Ophthalmol* 2011;151:297-302.
6. García-Ben A, Kamal-Salah R, García-Basterra I, Gonzalez Gómez A, Morillo Sanchez MJ, García-Campos JM. Two- and three-dimensional topographic analysis of pathologically myopic eyes with dome-shaped macula and inferior staphyloma by spectral domain optical coherence tomography. *Graefes Arch Clin Exp Ophthalmol*2017;255:903-12.
7. Kumar V, Molla K, Chandra P, Kumar A. Dome-shaped macula in oculocutaneous albinism. *BMJ Case Rep* 2016;2016.doi: 10.1136/bcr-2016-215368.