

# Acute Primary Repair of the Anterior Cruciate Ligament With Anterolateral Ligament Augmentation



Edoardo Monaco, M.D., Daniele Mazza, M.D., Matthew Daggett, M.D., Fabio Marzilli, M.D., Alessandro Annibaldi, M.D., Alessandro Carrozzo, M.D., and Andrea Ferretti, M.D.

**Abstract:** Acute injuries of the anterior cruciate ligament are often associated with concurrent injuries to the structures of the anterolateral complex, specifically the anterolateral ligament. Some injury patterns of the anterior cruciate ligament involve tearing of the majority of the ligament from the femoral origin, leaving a large, viable ligament remnant. In these patients, a repair of the anterior cruciate ligament back to the femoral origin can be undertaken. Subsequently, percutaneous repair of the anterolateral ligament can be performed through anatomical, percutaneous suture tape augmentation. The combined technique of anterior cruciate ligament repair with anterolateral ligament reinforcement is presented.

**A**nterior cruciate ligament (ACL) rupture is one of the most frequent orthopaedic and sports medicine injuries in the active population and often results in knee instability and functional impairment that eventually contribute to the development of post-traumatic arthritis.<sup>1,2</sup> Recently, clinical and radiologic studies have demonstrated that the lesion of the anterolateral ligament (ALL) and capsule of the knee are associated with ACL tears in almost 90% of cases and that this represents the most important risk factor for grade 3 pivot shift (PS) in acute ACL-injured knees.<sup>3-5</sup> For this reason, several extra-articular reconstruction (EAR) techniques have been proposed to address rotation instability by adding a lateral tenodesis or reconstructing anatomically the ALL.<sup>6-8</sup> Moreover,

recently with the advent of new surgical techniques, materials, and devices, there has been renewed interest in primary repair of acute ACL tears in proximal tears with good tissue quality of the tibial remnant.<sup>9-11</sup> This technique demonstrates the use of arthroscopic primary ACL repair concurrently with percutaneous minimally invasive reinforcement of the ALL using suture augmentation.

## Surgical Technique (With Video Illustration)

A careful preoperative patient selection is required for this technique. Patients with proximal ACL tears who have sufficient length of the ACL remnant to reapproximate to the femoral stump of the torn ligament and sufficient tissue quality to hold sutures are candidates for this technique, regardless of age or activity level. We would recommend this technique be performed within 2 weeks of the initial injury, taking advantage of the inflammatory phase possibly enhancing the spontaneous healing potential of the ACL and ALL.

## Indications

Magnetic resonance imaging (MRI) appearance of the ACL tears is preoperatively classified according to van der List et al.<sup>12</sup> into 1 of 5 types. Type I is a proximal avulsion of the ligament from its femoral insertion (distal remnant length >90% total ligament length), type II is a proximal tear (75%-90%), type III is a midsubstance tear (25%-75%), type IV is a distal tear (10%-25%), and type V is a distal avulsion tear

From the Department of Orthopaedic Surgery, S. Andrea Hospital, University of Rome "La Sapienza," Rome, Italy (E.M., D.M., F.M., A.A., A.C., A.F.); and Kansas City University, Kansas City, Missouri, U.S.A. (M.D.).

The authors report the following potential conflicts of interest or sources of funding: E.M., M.D., and A.F. are consultants for Arthrex, Naples, FL, USA, outside the submitted work. Full ICMJE author disclosure forms are available for this article online, as supplementary material.

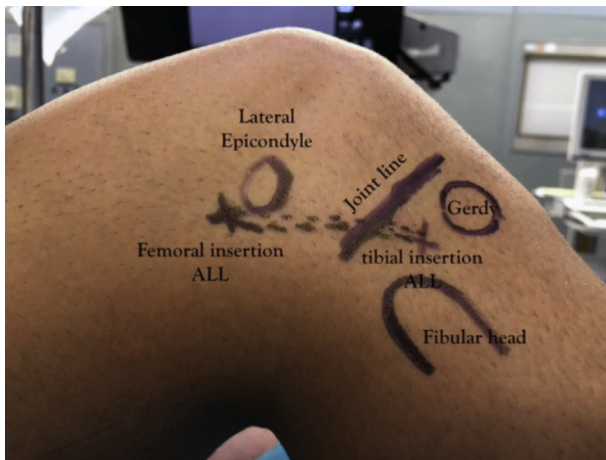
Received December 30, 2020; accepted March 2, 2021.

Address correspondence to Alessandro Annibaldi, M.D., Via di Grottarossa, 1035, 00189, Rome, Italy. E-mail: [alessandro.annibaldi91@gmail.com](mailto:alessandro.annibaldi91@gmail.com)

© 2021 THE AUTHORS. Published by Elsevier Inc. on behalf of the Arthroscopy Association of North America. This is an open access article under the CC BY-NC-ND license (<http://creativecommons.org/licenses/by-nc-nd/4.0/>).

2212-6287/202097

<https://doi.org/10.1016/j.eats.2021.03.007>



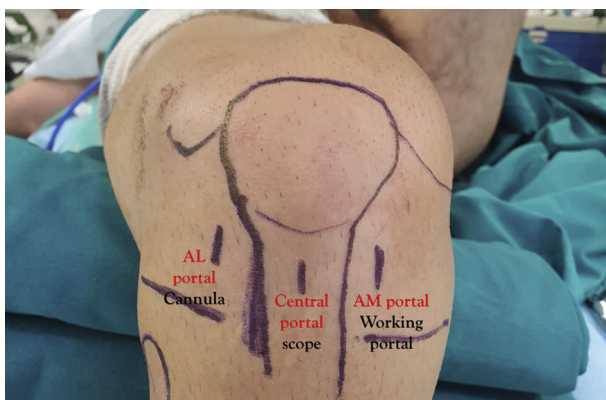
**Fig 1.** Anatomical landmarks for the ALL internal brace. (ALL, anterolateral ligament.)

(0%-10%). Also, the tissue quality of the ACL on the preoperative MRI is evaluated to predict eligibility for ACL repair and classified as good, fair, and poor.<sup>13</sup>

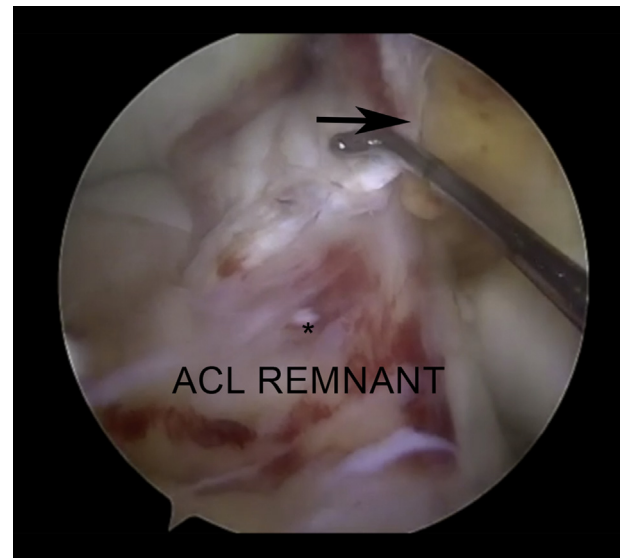
Arthroscopic primary repair is only performed in patients with proximal type I, type II, and type III tears with more than 50% of the tibial remnant intact and with good tissue quality to have good reapproximation of the ligament toward the femoral stump. These conditions are usually seen in the acute surgery, within 14 days from injury. The indications for adding an ALL internal brace (IB) augmentation are a grade 2 or 3 of PS, as evaluated with physical examination under anesthesia, and a tear of the ALL, as evaluated with preoperative 1.5-T MRI.<sup>4,5,14,15</sup>

### General Preparation

All patients provide informed consent before undergoing to ACL repair with ALL IB augmentation. Patients receive standard preoperative antibiotics and regional anesthesia and are placed in the supine position with



**Fig 2.** Arthroscopic portals: central portal (diagnostic arthroscopy), anteromedial portal (working portal), and the anterolateral portal (cannula). (AL, anterolateral; AM, anteromedial.)



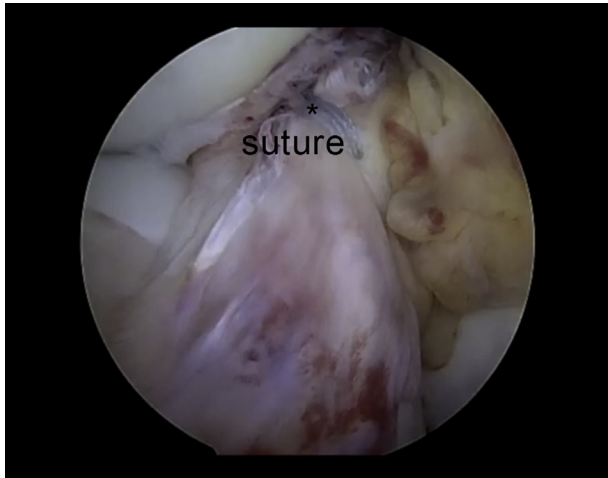
**Fig 3.** Diagnostic evaluation of ACL tear type. The asterisk indicates the ACL tibial remnant of a type II tear with good tissue quality. The arrow indicates the femoral stump of the ACL at the level of the lateral femoral condyle. (ACL, anterior cruciate ligament.)

the knee free to move from full extension to 90° of flexion (Fig 1). Examination under anesthesia is performed on both knees to confirm the injuries of the affected leg. Finally, a tourniquet is applied around the proximal thigh, and the leg is prepared and draped in a sterile fashion.

A transtendinous portal is used for diagnostic arthroscopy, and the anteromedial portal is used as a working portal (Fig 2). The torn ACL is carefully evaluated and probed to identify the tear type and determine tissue quality (Fig 3). For those knees with type I, type II, and type III tears with more than 50% of the tibial remnant intact and with good tissue quality, we proceed with the ACL repair technique. An accessory anterolateral portal is created, and a 6-mm PassPort Cannula (Arthrex, Naples, FL) is inserted to facilitate suture passage and management (Fig 1).

The ACL remnant on the tibial side is prepared by suture passage into the ligament with a scorpion suture passer using No.2 FiberWire and TigerWire stitches (Arthrex). The sutures are then looped through the ligament using a lasso-loop knot-tying configuration. The stitches are passed through the anteromedial and posterolateral bundle of the ACL. The strength of suture fixation is tested by pulling traction on the ends of the stitches (Fig 4).

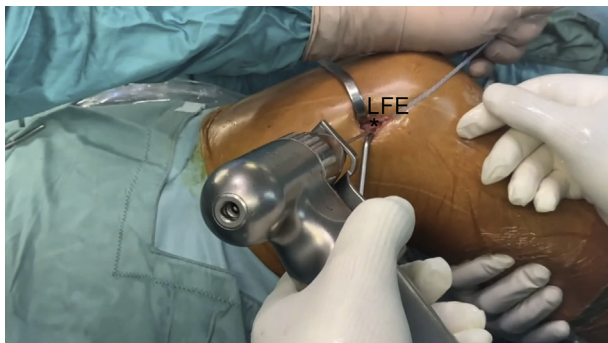
Next, a femoral outside-in ACL guide is used to create a femoral tunnel. The guide is placed at the origin of the femoral stump for anatomic guidance. It should be noted that the femoral stump is not debrided at all to ensure anatomic positioning and facilitate healing of



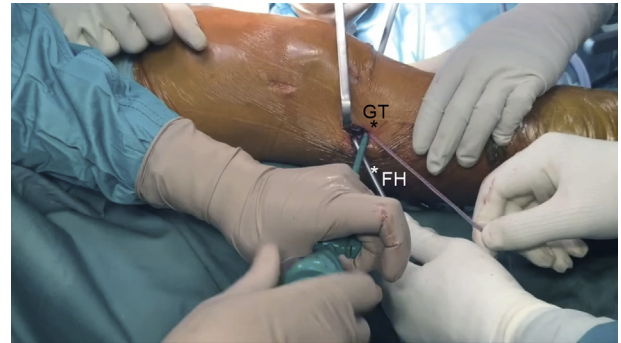
**Fig 4.** Final arthroscopic evaluation of the repaired ACL. The asterisk indicates anatomic reapproximation of the ACL remnant at the level of femoral anatomic footprint. (ACL, anterior cruciate ligament.)

the repaired ACL. The femoral tunnel is drilled using an outside-in technique using a 4-mm drill. On the lateral side of the knee, the guide is placed close to the anatomical insertion of the ALL at the level of the lateral epicondyle. A FiberStick No. 2 (Arthrex) is then passed from outside to in through the guide trocar and retrieved with a grasper from the anteromedial portal. The FiberStick is then passed to the anterolateral portal and used to pass the ACL repair stitches up through the femoral tunnel to reapproximate the tibial ACL remnant to the femoral ACL stump.

On the lateral aspect of the knee, the 2 anatomical insertion points of the ALL are approached via a mini skin incision. Two 2.4-mm K-wires are fixed in the anatomical footprints of the ALL: in the femur posterior and proximal to the lateral epicondyle (femoral insertion) and in the tibia between the Gerdy's tubercle and the fibula head 1 cm above the joint line (tibial insertion; Fig 5). A suture is passed over the 2 wires and isometry is checked through range of motion (ROM) to



**Fig 5.** Drilling of the socket for ALL internal brace at its anatomical insertion posterior and proximal to the lateral femoral epicondyle (LFE). The asterisk indicates the LFE.



**Fig 6.** Fixation of the anterolateral ligament internal brace at its tibial insertion between the Gerdy's tubercle (GT) and the fibular head (FH). The asterisks indicate the GT and the FH.

have a graft that tightens in extension and slacks in flexion and also to avoid any possible overconstraint of the normal flexion and internal rotation of the knee.

The repair stitches of the ACL coming out from the joint are then passed through a 4.75-mm bioabsorbable knotless anchor (SwiveLock; Arthrex) and fixed through a 4 × 20-mm bone socket drilled at the level of femoral insertion of the ALL. Before final fixation of the ACL, the repair stitches are tensioned by cycling the knee and then fixed with the knee in full extension. Subsequently, the wires coming out from the femoral bone socket, and already fixed with the first knotless anchor (SwiveLock; Arthrex), are then passed subcutaneously and deep to the iliotibial band to reach the skin incision at the level of the anatomical tibial insertion of the ALL. At this level a second 4 × 20-mm bone socket is drilled and the wires are fixed by using a 4.75-mm absorbable knotless anchor (SwiveLock; Arthrex) with the knee in full extension, completing the IB of the ALL (Fig 6). Finally, the repaired ACL is probed and evaluated at different degrees of flexion to confirm the integrity of the repair, and the ALL IB is double-checked by moving the knee from full extension to 90° of flexion to avoid any possible overconstraint (Video 1).

The arthroscopic portals and skin incision are closed with skin sutures. A short brace locked in extension is applied at the end of the procedure (Table 1).

## Rehabilitation

Patients are discharged the day after the procedure with a short brace locked in full extension, which is

**Table 1.** Tips and Tricks

- Use 3 arthroscopic portals (central transtendinous, AM, and AL)
- Leave the ACL femoral stump intact
- Use the ACL femoral stump as reference for femoral tunnel placement
- Use 2 K-wires to check isometry of ALL IB
- Fix the ACL repair in full extension
- Fix the ALL IB in full extension

ACL, anterior cruciate ligament; AL, anterolateral; ALL IB, anterolateral ligament internal brace; AM, anteromedial.

**Table 2.** Indications and Contraindications of Arthroscopic Primary ACL Repair With ALL Augmentation

Indications	Absolute contraindications
<ul style="list-style-type: none"> <li>• Type I ACL tear</li> <li>• Type II ACL tear</li> <li>• Type III ACL tear with at least 50% of tibial remnant intact</li> </ul>	<ul style="list-style-type: none"> <li>• Type IV ACL tear</li> <li>• Type V ACL tear</li> </ul>
Good tissue quality	Poor tissue quality
Acute injury (injury-to-surgery interval maximum 2 weeks)	Re-rupture of a repaired ACL
Patients of all age and activity levels	Relative contraindications
Grade 2 or 3 pivot shift	Previous experience or familiarity with the procedure
Incomplete ALL tear	Grade 1 pivot shift or no MRI sign of ALL tears

ACL, anterior cruciate ligament; ALL, anterolateral ligament; MRI, magnetic resonance imaging.

worn for 4 weeks. Weight-bearing in the locked brace is allowed the day after surgery. Continuous passive motion between 0° and 90° is initiated the day after surgery, with a goal of reaching full ROM within 4 weeks. The brace is unlocked to 90° of flexion after 1 week and to complete ROM after 2 weeks and removed after 4 weeks. Physical therapy is begun the day after surgery, focusing on early ROM by maintaining full extension and progressively increasing flexion. Specific muscle control and strengthening exercises were started 4 weeks after surgery. Patients begin sport-specific training at 2 months post-operatively. Pivoting sports are allowed if the neuromuscular function has recovered, which usually occurs within 6 months.

## Discussion

Anterior cruciate ligament reconstruction (ACLR) is one of the most frequent orthopaedic procedures, with an estimated 100,000 to 175,000 ACL reconstructions (ACLRs) performed annually.<sup>16</sup> The primary goal of an ACL surgery is to stabilize the knee, especially by controlling the PS phenomenon. In fact, a residual rotatory instability, which has been reported from 11% to 30% in several studies, is related to poor outcomes and less satisfactory results.<sup>17,18</sup> Although the results of the several ACLRs techniques are satisfactory, concerns remain about the ability to fully control the PS phenomenon.<sup>15,17</sup>

The majority of ACL injuries occur secondary to a noncontact mechanism as a result of a PS like injury, which is a complex series of movements involving knee valgus, varus, internal rotation, and external rotation moments, with an anterior-translation force.<sup>19,20</sup> As a consequence of this injury mechanism, other structures can be damaged along with the ACL at the time of

injury, such as the structures of the anterolateral complex, which includes the ALL, the iliotibial band and the lateral meniscus.<sup>3,21,22</sup>

Tears to the ALL frequently occur, as it is damaged concurrently with the ACL in almost 90% of cases in acute settings, as demonstrated by Ferretti et al.,<sup>15</sup> with a systematic surgical exposure of the lateral compartment in acute ACL surgeries. These findings are consistent with results reported when a lateral incision was standardly performed using the old-style open ACL reconstruction techniques.<sup>23,24</sup> A similar prevalence of injury to the secondary restraints was found using preoperative MRI in acute ACL tears.<sup>4,5</sup>

The ALL has been described as a distinct structure located proximally and posteriorly to the lateral femoral epicondyle and extending to a point midway between the Gerdy's tubercle and fibular head on the tibia.<sup>25</sup> Several navigated studies have demonstrated the biomechanical role of the ALL in controlling the rotational stability of the knee and the PS phenomenon, as well as the role of its anatomic reconstruction.<sup>26</sup>

Several techniques have been evaluated for the treatment of ALL lesions and subsequent anterolateral rotational instability of the knee. Both nonanatomical lateral extra-articular tenodesis and anatomical ALL reconstruction techniques have shown excellent results and a reduction of failure rate in a high number of patients.<sup>6,27</sup> Moreover, EAR techniques as well as ALL reconstructions are able to reduce the force applied to the ACL up to 80%, possibly protecting the repaired ACL during its spontaneous healing.<sup>28</sup>

This protective effect of EAR techniques has been also recently confirmed in an MRI study of Cavaignac et al.<sup>29</sup> They concluded that ACL grafts showed generally better incorporation and maturation when combined with lateral extra-articular tenodesis.

Some preliminary reports and original techniques for ALL repair and ALL augmentation with suture tape have been already described.<sup>27</sup> Internal bracing involves the augmentation of a ligament repair with

**Table 3.** Advantages and Disadvantages of Arthroscopic Primary ACL Repair With ALL Augmentation

Advantages	Disadvantages
Minimally invasive technique without skin incisions	Only in selected group of patients
Anatomical repair of the ACL	Long-term outcomes (>5 years) unknown
Anatomical augmentation of the ALL	
Early ROM	
Lower risk of infection vs ACLR + EAR	
Less pain and swelling vs EAR	

ACL, anterior cruciate ligament; ACLR, anterior cruciate ligament reconstruction; ALL, anterolateral ligament; EAR, extra-articular reconstruction; ROM, range of motion.

suture tape, which reinforces the ligament and promotes natural healing by protecting the ligament during the healing phase and allowing early mobilization.<sup>30</sup>

The addition of ALL augmentation to ACL repair, presented in [Video 1](#), is based on the mentioned results of ALL reconstruction in terms of protection of the intra-articular ACL repair procedure and also, acting as an IB, as a prevention of subsequent injury.

Primary repair of ACL tears was the standard treatment for all ACL tears until the middle to the late 1980s. Although clinical results were initially promising, mid-term follow-up studies showed significantly greater rates of continued instability and pain and thus with the advent of arthroscopy, ACL reconstruction subsequently became the gold standard technique for all tear types. With the advent of new surgical techniques, materials, and devices, there has been a renewed interest in primary repair of ACL, with some recent studies on ACL repair showing good-to-excellent results and failure rate ranging from 7% to 15% of cases.<sup>9-11</sup>

The main advantages of repair as compared with reconstruction lie in the avoidance of any harvesting-related morbidity and complications, absence of any graft remodeling, and ligamentization process with a more physiological and anatomical healing. Moreover, fewer postoperative infections, easier rehabilitation, and earlier return to sports and daily activities of living should also be expected.<sup>31,32</sup>

DiFelice et al.<sup>33</sup> reported excellent outcomes after primary ACL repair with a failure rate of 9% at a mean 3.5-year follow-up. Achtnich et al.<sup>34</sup> compared primary repair with the gold standard of ACL reconstruction and noted equivalent functional outcomes after both procedures with a trend toward more revision after primary repair. Ferretti et al.<sup>11</sup> showed good short-term clinical outcomes after ACL repair in acute injuries and also excellent MRI findings with early recovery of a normal morphology and signal intensity.

Recently, the results of ACL repair techniques have been reported in some reviews and meta-analyses of the literature with some conflicting results noted. The first, which was focused exclusively on arthroscopic ACL repair techniques, examined 13 studies and 1101 patients, showing how 3 different techniques (primary repair without augmentation, with static and with dynamic augmentation) are safe, with failure rates between 7% and 11%. The second, which looked at 28 studies and 2401 patients, reported how ACL reconstruction results in better survivorship and patients perceived postoperative improvement greater than repair.<sup>31,35</sup>

There are limitations to this technique. Absolute contraindications include patients with tears who have a distal remnant that is too short for reinsertion, tissue quality that cannot hold sutures (i.e., poor tissue

quality), or re-rupture of a repaired ACL. Relative contraindications could be complete tears of ALL as well as Segond's fracture. In such a case, direct repair and retensioning of the ALL with refixation of the bony fragment when present should be suggested, with or without IB augmentation. Other relative contraindications for this technique are surgical experience and surgical familiarity with the procedure. The indication for adding an ALL IB augmentation is a grade 2 or 3 of PS as evaluated with physical examination under anesthesia and a tear of the ALL as evaluated with preoperative 1.5-T MRI. We do not recommend IB in the case of 1 + PS and in patients without any direct or indirect MRI sign of ALL tear ([Table 2](#)).

The purposed technique presents some advantages: it is a minimally invasive technique without skin incision. Only arthroscopic portals and 2 small incisions on insertion points of the ALL are needed. The technique allows an anatomical repair of the ACL and also an anatomical augmentation of the ALL, possibly improving the spontaneous healing of the ACL. The accelerated postoperative protocol can decrease the risk of knee arthrofibrosis after acute ACL surgery. In addition, ALL IB augmentation leads to less postoperative pain and swelling in comparison with the extra-articular tenodesis techniques, thus allowing for earlier initiation of postoperative rehabilitation, which begins the day after surgery ([Table 3](#)).

This paper has some limitations. This is only the presentation of a surgical technique and no results are presented, so it is not possible to extrapolate consideration about clinical results at long-term follow-up as well as possible complications. However, in a recent study, Hopper et al.<sup>36</sup> showed excellent outcomes at 2 years of follow-up in 94.7% of patients undergoing a combined ACL repair and ALL IB augmentation.

In conclusion, a recent resurgence of interest in ACL preservation has been noted using arthroscopic primary repair in patients with proximal tears. Treatment of anterolateral rotatory instability of the knee should include treatment of ALL tears and for this reason ALL IB is added. Moreover, ALL IB is able to protect healing of the ligament and enable ROM during the early phases of rehabilitation. In this Technical Note, we have described the surgical technique of arthroscopic primary repair of proximal ACL tears with ALL suture augmentation.

## References

1. Granan LP, Bahr R, Lie SA, Engebretsen L. Timing of anterior cruciate ligament reconstructive surgery and risk of cartilage lesions and meniscal tears: A cohort study based on the Norwegian national knee ligament registry. *Am J Sports Med* 2009;37:955-961.
2. Mok YR, Wong KL, Panjwani T, Chan CX, Toh SJ, Krishna L. Anterior cruciate ligament reconstruction

- performed within 12 months of the index injury is associated with a lower rate of medial meniscus tears. *Knee Surg Sport Traumatol Arthrosc* 2019;27:117-123.
3. Ferretti A, Monaco E, Gaj E, et al. Risk factors for grade 3 pivot shift in knees with acute anterior cruciate ligament injuries: A comprehensive evaluation of the importance of osseous and soft tissue parameters from the SANTI study group. *Am J Sports Med* 2020;48:2408-2417.
  4. Helito CP, Helito PVP, Costa HP, Demange MK, Bordalo-Rodrigues M. Assessment of the anterolateral ligament of the knee by magnetic resonance imaging in acute injuries of the anterior cruciate ligament. *Arthroscopy* 2017;33:140-146.
  5. Monaco E, Helito CP, Redler A, et al. Correlation between magnetic resonance imaging and surgical exploration of the anterolateral structures of the acute anterior cruciate ligament-injured knee. *Am J Sports Med* 2019;47:1186-1193.
  6. Sonnery-Cottet B, Thaunat M, Freychet B, Pupim BH, Murphy CG, Claes S. Outcome of a combined anterior cruciate ligament and anterolateral ligament reconstruction technique with a minimum 2-year follow-up. *Am J Sports Med* 2015;43:1598-1605.
  7. Bernholt DL, Kennedy MI, Crawford MD, DePhillipo NN, LaPrade RF. Combined anterior cruciate ligament reconstruction and lateral extra-articular tenodesis. *Arthrosc Tech* 2019;8:e855-e859.
  8. Helito CP, Bonadio MB, Gobbi RG, et al. Combined intra- and extra-articular reconstruction of the anterior cruciate ligament: the reconstruction of the knee anterolateral ligament. *Arthrosc Tech* 2015;4:e239-e244.
  9. Jonkergouw A, Van der List JP, DiFelice GS. Arthroscopic primary repair of proximal anterior cruciate ligament tears: Outcomes of the first 56 consecutive patients and the role of additional internal bracing. *Knee Surg Sports Traumatol Arthrosc* 2019;27:21-28.
  10. Van der List JP, DiFelice GS. Role of tear location on outcomes of open primary repair of the anterior cruciate ligament: A systematic review of historical studies. *Knee* 2017;24:898-908.
  11. Ferretti A, Monaco E, Annibaldi A, et al. The healing potential of an acutely repaired ACL: A sequential MRI study. *J Orthop Traumatol* 2020;21:14.
  12. Van der List JP, Mintz DN, DiFelice GS. The location of anterior cruciate ligament tears: A prevalence study using magnetic resonance. *Orthop J Sports Med* 2017;5:2325967117709966.
  13. Van der List JP, DiFelice GS. Preoperative magnetic resonance imaging predicts eligibility for arthroscopic primary anterior cruciate ligament repair. *Knee Surg Sport Traumatol Arthrosc* 2018;26:660-671.
  14. Ariel de Lima D, Helito CP, Lima FRA, Leite JAD. Surgical indications for anterior cruciate ligament reconstruction combined with extra-articular lateral tenodesis or anterolateral ligament reconstruction. *Rev Bras Ortop* 2018;53:661-667.
  15. Ferretti A, Monaco E, Fabbri M, Maestri B, De Carli A. Prevalence and classification of injuries of anterolateral complex in acute anterior cruciate ligament tears. *Arthroscopy* 2017;33:147-154.
  16. Desai VS, Anderson GR, Wu IT, et al. Anterior cruciate ligament reconstruction with hamstring autograft: A matched cohort comparison of the all-inside and complete tibial tunnel techniques. *Orthop J Sports Med* 2019;7:2325967118820297.
  17. Tashman S, Collon D, Anderson K, Kolowich P, Anderst W. Abnormal rotational knee motion during running after anterior cruciate ligament reconstruction. *Am J Sports Med* 2004;32:975-983.
  18. Park YB, Lee HJ, Ro DH, Lee GY, Kim S, Kim SH. Anterolateral ligament injury has a synergic impact on the anterolateral rotatory laxity in acute anterior cruciate ligament-injured knees. *Knee Surg Sport Traumatol Arthrosc* 2019;27:3334-3344.
  19. Alentorn-Geli E, Myer GD, Silvers HJ, et al. Prevention of non-contact anterior cruciate ligament injuries in soccer players. Part 1: Mechanisms of injury and underlying risk factors. *Knee Surg Sports Traumatol Arthrosc* 2009;17:705-729.
  20. Owusu-Akyaw KA, Kim SY, Spritzer CE, et al. Determination of the position of the knee at the time of an anterior cruciate ligament rupture for male versus female patients by an analysis of bone bruises. *Am J Sports Med* 2018;46:1559-1565.
  21. Praz C, Vieira TD, Saithna A, et al. Risk factors for lateral meniscus posterior root tears in the anterior cruciate ligament-injured knee: An epidemiological analysis of 3956 patients from the SANTI Study Group. *Am J Sports Med* 2019;47:598-605.
  22. Minami T, Muneta T, Sekiya I, et al. Lateral meniscus posterior root tear contributes to anterolateral rotational instability and meniscus extrusion in anterior cruciate ligament-injured patients. *Knee Surg Sports Traumatol Arthrosc* 2018;26:1174-1181.
  23. Muller W. *The knee: Form, function and ligamentous reconstruction surgery*. Berlin: Springer, 1982.
  24. Hughston JC. A surgical approach to the medial and posterior ligaments of the knee. *Clin Orthop Relat Res* 1973;91:29-33.
  25. Claes S, Vereecke E, Maes M, Victor J, Verdonk P, Bellemans J. Anatomy of the anterolateral ligament of the knee. *J Anat* 2013;223:321-328.
  26. Rasmussen MT, Nitri M, Williams BT, et al. An in vitro robotic assessment of the anterolateral ligament, part 1: Secondary role of the anterolateral ligament in the setting of an anterior cruciate ligament injury. *Am J Sports Med* 2016;44:585-592.
  27. Monaco E, Mazza D, Redler A, Drogo P, Wolf MR, Ferretti A. Anterolateral ligament repair augmented with suture tape in acute anterior cruciate ligament reconstruction. *Arthrosc Tech* 2019;8:e369-e373.
  28. Marom N, Ouanezar H, Jahandar H, et al. Lateral extra-articular tenodesis reduces anterior cruciate ligament graft force and anterior tibial translation in response to applied pivoting and anterior drawer loads. *Am J Sports Med* 2020;48:3183-3193.
  29. Cavaignac E, Mesnier T, Marot V, et al. Effect of lateral extra-articular tenodesis on anterior cruciate ligament graft incorporation. *Orthop J Sports Med* 2020;8:2325967120960097.

30. Mackay GM, Blyth MJ, Anthony I, Hopper GP, Ribbans WJ. A review of ligament augmentation with the InternalBrace™: The surgical principle is described for the lateral ankle ligament and ACL repair in particular, and a comprehensive review of other surgical applications and techniques is presented. *Surg Technol Int* 2015;26:239-255.
31. Van der List JP, Vermeijden HD, Sierevelt IN, DiFelice GS, van Noort A, Kerkhoffs GMMJ. Arthroscopic primary repair of proximal anterior cruciate ligament tears seems safe but higher level of evidence is needed: A systematic review and meta-analysis of recent literature. *Knee Surg Sports Traumatol Arthrosc* 2020;28:1946-1957.
32. Van der List JP, DiFelice GS. Range of motion and complications following primary repair versus reconstruction of the anterior cruciate ligament. *Knee* 2017;24:798-807.
33. DiFelice GS, Villegas C, Taylor SA. Anterior cruciate ligament preservation: Early results of a novel arthroscopic technique for suture anchor primary anterior cruciate ligament repair. *Arthroscopy* 2015;31:2162-2171.
34. Achtnich A, Herbst E, Forkel P, et al. Acute proximal anterior cruciate ligament tears: Outcomes after arthroscopic suture anchor repair versus anatomic single-bundle reconstruction. *Arthroscopy* 2016;32:2562-2569.
35. Nwachukwu BU, Patel BH, Lu Y, Allen AA, Williams RJ 3rd. Anterior cruciate ligament repair outcomes: An updated systematic review of recent literature. *Arthroscopy* 2019;35:2233-2247.
36. Hopper GP, Aithie JMS, Jenkins JM, Wilson WT, Mackay GM. Combined anterior cruciate ligament repair and anterolateral ligament internal brace augmentation. *Orthop J Sports Med* 2020;8. 2325967120968557.