

SPECIAL ISSUE: TOPICS

Catheter ablation of ventricular tachycardia in nonischemic cardiomyopathy

Kenji Okubo MD  | Lorenzo Gigli MD | Paolo Della Bella MD

Arrhythmia Unit and Electrophysiology Laboratories, Ospedale San Raffaele, Milano, Italy

Correspondence: Kenji Okubo, MD, Arrhythmia Unit and Electrophysiology Laboratories, Ospedale San Raffaele, Via Olgettina 60, Milan, Italy (kenji.okubo@gmail.com).

Abstract

The number of patients with nonischemic cardiomyopathy (NICM) undergoing catheter ablation of ventricular tachycardia (VT) has increased by the years, however, there are no randomized studies of VT ablation in this population. Many studies have reported more mixed or inferior outcome after the ablation in patients with NICM as compared to in those with ischemic cardiomyopathy (ICM)—likely because of the heterogeneous VT substrates in each etiology. While, various ablation strategies for substrate modification in the setting of ICM, including low voltage area ablation, late potential abolition, and local abnormal ventricular activity elimination, have been well established, it is still unknown which ablation strategy is effective for prevention of recurrence VTs in NICM patients. Therefore, this review will highlight the recent progress made in VT ablation in patients with NICM.

KEYWORDS

catheter ablation, nonischemic cardiomyopathy, ventricular tachycardia

1 | INTRODUCTION

Ventricular tachycardias (VTs) increase mortality in patients with a structure heart disease.¹

To manage the VTs in this population, there are three feasible options: antiarrhythmic drugs (AADs), implantable cardioverter-defibrillator (ICD), and catheter ablation (CA).

Apart from beta-blockers, none of the AADs for ventricular arrhythmias has been shown to improve survival; amiodarone, although being the most effective AAD for preventing VT and reducing arrhythmic death,² doesn't reduce the all-cause mortality,³ likely because of its long-term side effects counterbalancing its benefits.⁴

Implantable cardioverter-defibrillator is the mainstay of the VTs therapy in those patients who are at risk of sudden cardiac death: however, while the benefit of ICDs in patients with ischemic cardiomyopathies (ICMs) has been well described,^{4–6} no randomized trials have yet clarified their beneficial role in nonischemic cardiomyopathies (NICMs).^{7,8}

Catheter ablation has emerged as an effective option for treating recurrent VTs^{9,10} and a recent multicenter study has demonstrated the

benefit of a successful ablation in preventing VT recurrences and prolonging the survival.¹¹ In patients with ICMs, a randomized control trial has reported that the rate of a composite outcome (death, VT storm and appropriate ICD shocks) was significantly lower among the patients undergoing catheter ablation than among those receiving an escalated antiarrhythmic drug therapy¹²; furthermore, in the setting of ICMs, various ablation strategies for substrate modification including low voltage area ablation, late potential (LP) abolition and local abnormal ventricular activity (LAVA) elimination have been well established.^{13,14}

On the other hand, there are no randomized studies of catheter ablation of VT in NICM patients. Many studies have reported more mixed or inferior outcome after the ablation in patients with NICM as compared to in those with ICM^{15–17}—likely because of the heterogeneous VT substrates in each etiology and different VT ablation strategies.¹⁸

As the number of patients with NICM undergoing VT ablation has increased by the years,¹⁹ it is important to review the progress that has been recently made in the ablation treatment of VT in patients with NICMs.

This is an open access article under the terms of the Creative Commons Attribution-NonCommercial-NoDerivs License, which permits use and distribution in any medium, provided the original work is properly cited, the use is non-commercial and no modifications or adaptations are made.

© 2018 The Authors. *Journal of Arrhythmia* published by John Wiley & Sons Australia, Ltd on behalf of the Japanese Heart Rhythm Society.

2 | PREPROCEDURAL CONSIDERATION

2.1 | VT morphology

The preprocedural analysis of the VT morphology is an indispensable tool for planning the ablation and increase the probability of success.²⁰

We reported the correlation between VT morphology and scar area in NICM patients²¹: in this study, where patients were classified into two groups (anteroseptal or inferolateral scar type) according to the endocardial unipolar voltage, the left inferior VT axis was predictive of an anteroseptal scar (positive predictive value: 100%) and the right superior axis for inferolateral ones (positive predictive value: 89%).

If the clinical VT morphology in a 12-lead ECG should not be available due to appropriate ICD interventions, we recommend to perform a noninvasive program stimulation (NIPS) or an electrophysiological study (induction of VT) before the ablation, to check the inducibility and VT morphology.

2.2 | Baseline ECG

On the other hand, the VT is not always inducible before the procedure and its morphology can't be obtained: in these cases, the baseline ECG—its characteristics are well correlated with the unipolar low-voltage distribution in high-density endo-epicardial maps—might be helpful to predict the arrhythmogenic substrate. Oloriz et al²² reported that the conduction disturbance with an atrioventricular block, left bundle branch block and widened QRS was associated with an anteroseptal scar in the endocardium, whereas the low QRS voltage in the limb leads was correlated with voltage abnormalities in the inferolateral area in the epicardium.

2.3 | Magnetic resonance imaging

Ventricular tachycardia ablation in patients with NICMs is considered to be challenging partly because of the frequent intramural and subepicardial location of the arrhythmogenic substrate, which can often be identified by a magnetic resonance imaging (MRI) scan that may thus have important clinical implications for preprocedural planning and intraprocedural substrate identification.²³ Piers et al²⁴ used contrast-enhanced MRI to describe two typical scar patterns (anteroseptal and inferolateral), accounting for 89% of the arrhythmogenic substrates in patients with NICM. Anteroseptal scars are approached from the endocardium, whereas inferolateral scars frequently require an epicardial approach.

2.4 | Computed tomography

While MRI is the gold standard for identifying myocardial scars, it is often not feasible in patients with an ICD, for which a safe alternative could be the multidetector computed tomography (CT).

Delayed enhancement cardiac CT can provide a 3D description of the structural substrate at the VT origin, together with a detailed heart anatomy. Preprocedural cardiac CT imaging offers important clues in the planning of VT ablations (Figure 1).²⁵

2.5 | Extracorporeal membrane oxygenation

Nakahara et al²⁶ described how, when facing unstable VTs in a NICM setting, the substrate modification approach based on late potential abolition and/or pace-mapping offered limited success when compared to the ICMs. Therefore, when patients, especially in idiopathic dilated cardiomyopathy (IDCM), have low EF (<30%), and/or episodes of hemodynamically intolerated VTs, it could be reasonable to consider setting up an extracorporeal membrane oxygenation (ECMO) support for VT mapping and ablation, which allows for rhythm stabilization and low procedure mortality.²⁷

3 | WHEN DO WE NEED AN EPICARDIAL ABLATION?

From 2010 to 2016, 523 VT ablations on NICM patients were performed in our center.

Out of them, 263 cases (50%) required an epicardial access, chosen after weighting several factors (Figure 2A).

3.1 | Etiology

As it is well known that patients with postmyocarditis or arrhythmogenic right ventricular dysplasia (ARVD) are often characterized by epicardial substrates, the epicardial access could be considered as a first-line approach. In our experience, 88% of the patients with postmyocarditis and 70% of those with ARVD underwent an epicardial access.

In the setting of IDCM, the need for a first-line epicardial access has yet to be clarified.

As the previous study on VT mapping showed, scars are often more extended in the epicardium than in the endocardium, and an epicardial ablation is likely to improve the ablation success rate²⁸; however, as we reported recently, it might be reasonable to attempt the epicardial approach only when a free wall location of the scar was expected.²¹

3.2 | MRI

Magnetic resonance imaging is a good tool to guide the decision to a first-line epicardial approach, because it can easily identify the epicardial extension of the scarred tissue.²⁹ If patients have no implanted device, MRI is recommended before procedure.

3.3 | ECG

Ventricular tachycardia morphology can be an important clue to identify which patients are likely to benefit from an epicardial approach.³⁰

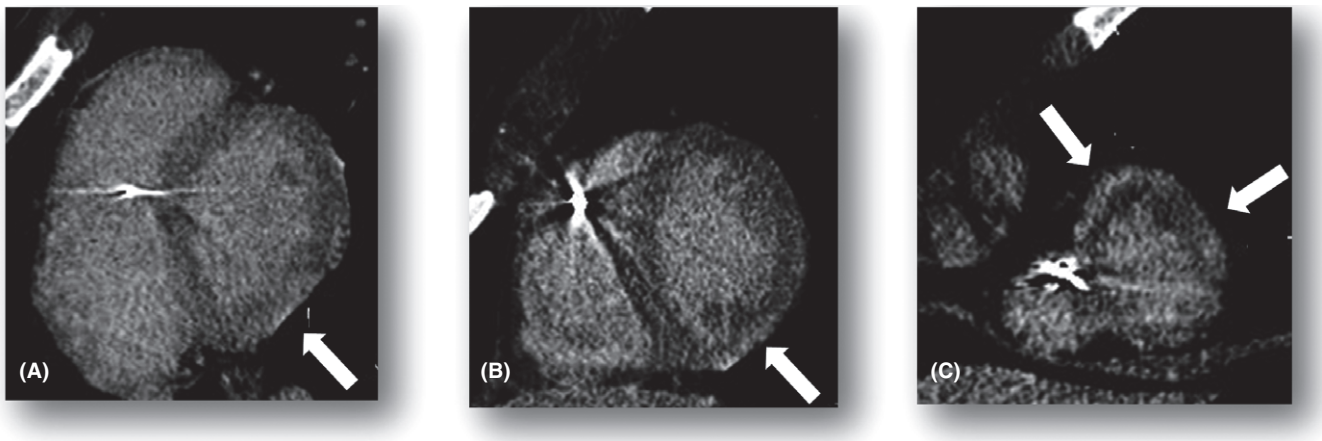


FIGURE 1 Late iodine enhancement scan in a patient with postmyocarditis scar. Short-axis (left→right = base→apex) of late iodine enhancement (LIE) scan acquired according to the method previously validated by Esposito et al²⁵ in a patient with ICD. LIE scan shows a thin subepicardial area of hyperdensity involving the infero-lateral wall from the base to the apex (A,B,C) and the anterior and lateral apical wall. LIE findings were referable to postmyocarditis scar. Courtesy of Antonio Esposito and Anna Palmisano

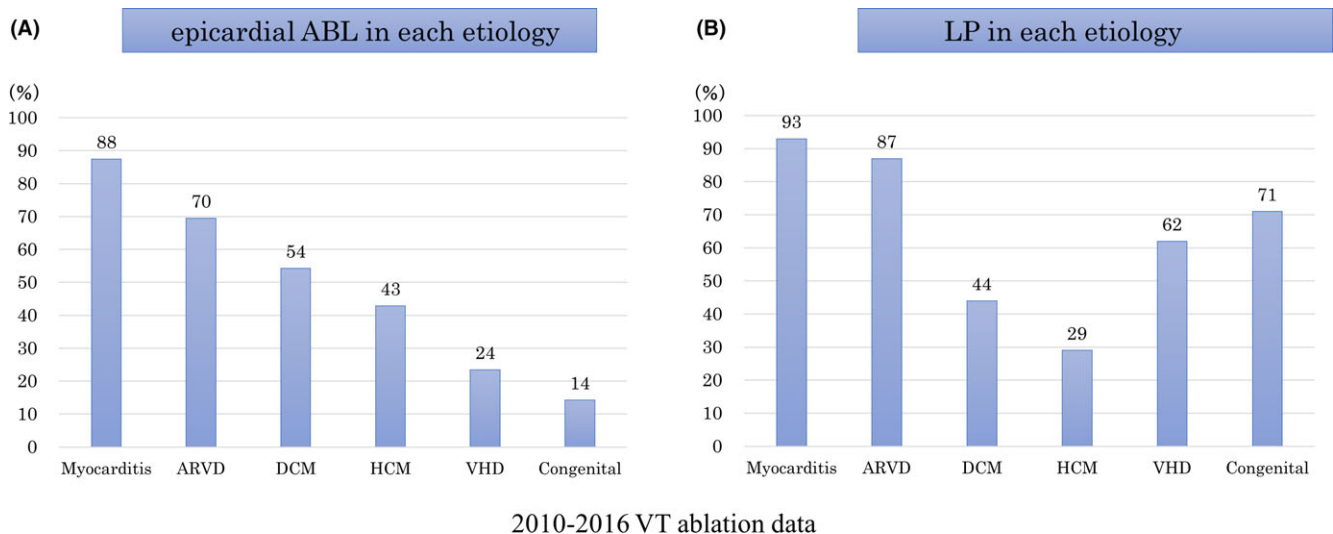


FIGURE 2 Proportion of epicardial ablation (A) and late potential presence in each etiology. ABL, ablation; ARVD, arrhythmogenic right ventricular dysplasia; DCM, dilated cardiomyopathy; HCM, hypertrophic cardiomyopathy; LP, late potential; VHD, valvular heart disease

The previous study importantly suggested that the presence of a q wave in lead I, create a high degree of suspicion for a probable epicardial location in the setting of NICM.³¹

In patients with ARVD, while the presence of a QS pattern in lead V1-V3 is predictive of an epicardial RV-VT, QS pattern in the inferior leads is common in the patients with an epicardial superior axis RV VT.³²

The 12-lead ECG of the baseline rhythm, particularly when there is a contraindication to the MRI or the VT morphology is not available, may also help to exclude the possible epicardial origin of the VT and avoid the epicardial access.²²

3.4 | Electroanatomical findings during ablation

Besides a history of a previously failed endocardial procedure, electroanatomical findings during procedure—such as the absence of LP

and low voltage area in the endocardium—provide good reasons to resort to the epicardial access. Additionally, when the unipolar penumbra area, defined as the unipolar scar beyond the bipolar low voltage area, is observed in the endocardium,³³ the epicardial mapping can be rewarding.^{34,35}

Recently, Gökoglan demonstrated the superiority of the end-epicardial ablation (scar homogenization) over the standard ablation (the epicardial mapping/ablation was performed in patients for whom either the VT was inducible after the endocardial ablation or there was no endocardial scar) in patients with dilated NICMs and VT.¹⁵ In the study, after a single procedure and with a mean follow-up period of 14 ± 2 months, the freedom from any ventricular arrhythmia in the scar homogenization group was 64%, compared with 39% in the standard ablation cohort; consequently, the epicardial ablation might be indicated for this population. On the other hand, a European multicenter study reported that the complication rate related to the

epicardial access was not low, even in high experienced centers.³⁶ For the above-mentioned reasons, the authors suggest that we should carefully evaluate the indication to an epicardial access with a patient-by-patient approach.

4 | MAPPING AND ABLATION

The procedures are performed under general anesthesia. Since the stability of the catheter and the quality of the contact depend on the anatomy of the heart and on the site of the ablation, the standard approach in our center involves a double access (retrograde transaortic and antegrade transseptal approach), allowing for a more flexible ablation strategy.

If a first-line combined epicardial and endocardial mapping approach is undertaken, the epicardial puncture and mapping are performed before transseptal puncture.

What follows is a summary of our VT ablation workflow:

1. Activation mapping and substrate ablation:
 - 1.1. Patients presenting incessant VTs at the beginning of the procedure undergo an activation mapping-guided CA and, after the VT termination, a substrate modification is attempted during sinus or paced rhythm.
 - 1.2. Patients in sinus rhythm (SR) undergo a substrate mapping, followed by a programmed ventricular stimulation and ablation guided by the activation map built during the VT; after the VT termination, the CA continues during SR, aiming at completing the substrate modification.
2. Activation mapping ablation: in cases of inducible VTs and absence of targetable substrate during SR.
3. Substrate ablation: in patients in whom the VT was not inducible, the CA was performed during SR aiming for the achieving the substrate modification.

Substrate modification was performed with the aim of abolishing the LPs or, in case of absence of the LPs, targeting the LAVAs or the bipolar/unipolar low voltage area (<1.5 and <8.3 mV, respectively). For mapping, we recommend using multielectrode catheters, such as the Pentaray (Biosense Webster, Diamond Bar, CA), the Livewire (St. Jude Medical, Saint Paul, MN) and the Orion (Boston Scientific, Marlborough, MA) mapping catheter: acquiring the points is rapid and the high-resolution permits to differentiate near-field from far-field ventricular signals, not as easy with conventional mapping catheters; furthermore, using a multielectrode catheter facilitates the identification of the conduction system site, leading to a clear bundle branch reentry diagnosis during the procedure.

The procedure end-point is always the combination of LP abolition and VT noninducibility, verified by performing a programmed ventricular stimulation (≤ 4 extrastimuli) at the right ventricular apex and at multiple left ventricular sites.

5 | CONSIDERATIONS BY EACH ETIOLOGY

We believe it is important to consider practical ablation strategies according to each etiology.

5.1 | IDCM

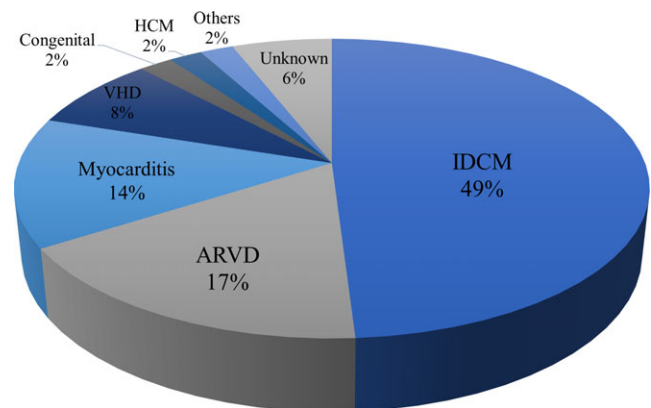
Idiopathic dilated cardiomyopathy is the most common etiology among NICM patients, accounting for about 50% of our whole population undergoing a VT ablation (Figures 3 and 4).

However, when compared to ICM patients, several studies have suggested unsatisfying long-term outcomes after the ablation,^{16,17,28,37,38} probably because of the less defined arrhythmia substrate (patchy or diffuse microscarring process) and the frequent intramural or subepicardial location.

Hsia et al³⁹ studied 19 patients with IDCM and VT using electroanatomic mappings, observing how the regions of abnormal electrograms were mainly located at the basal and lateral aspects of the LV, adjacent to the mitral valve annulus.

Soejima et al²⁸ described the importance of the epicardial mapping and ablation and reported on the scar being predominantly in the basal perivalvular area; the concept of a basal interventricular septum scar was subsequently further investigated by Haqqani et al.⁴⁰ These findings suggest the possibility of an intramural or epicardial substrate, which may translate into limited results after ablation.

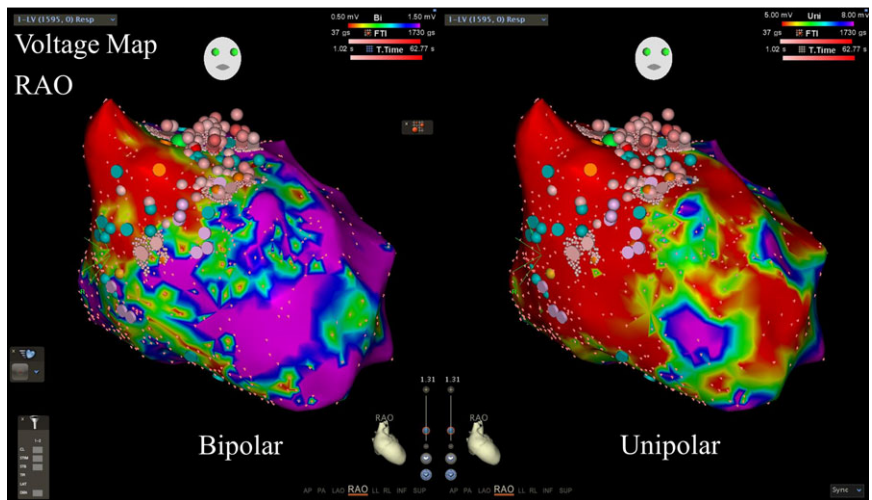
On the other hand, Muser et al⁴¹ recently reported favorable outcomes on a population of 282 patients with IDCM, with a VT-free survival after the ablation of about 70% at a 5 year follow-up. Notably, according to his experience, the majority of the procedures can be effectively approached through an endocardial strategy only, whereas just 32% of the patients required an epicardial ablation; this further confirms the necessity of an ad-hoc evaluation of every case, as no clear criteria is yet available to identify the need of an epicardial approach.



2010-2016 VT ablation data

FIGURE 3 Distribution of etiologies in NICM patients. ARVD, arrhythmogenic right ventricular dysplasia; IDCM, idiopathic dilated cardiomyopathy; HCM, hypertrophic cardiomyopathy; NICM, nonischemic cardiomyopathy; VHD, valvular heart disease

FIGURE 4 Voltage map in a patient with IDCM. Voltage map in bipolar (left panel) and unipolar (right panel) shows low voltage area (LVA) at basal and septal area in right anterior oblique view (RAO). Ablation (pink tags) targeting diastolic pathway of ventricular tachycardia (VT) at the anterobasal area was performed, leading to VT termination. IDCM, idiopathic dilated cardiomyopathy



Finally, a substrate modification strategy targeting the LPs appears to be less applicable in patients with ICMs, because of the LPs being less frequently observed in this population in our study, only 44% of the IDCM patients showed LPs at baseline (Figure 2B).

5.2 | ARVD

In ARVDs, the arrhythmogenic substrate often involves the perivalvular area (the tricuspid annulus and pulmonic valve annulus), mainly at the right ventricular free wall, while the apex are typically spared⁴²; in this setting, epicardial ablations are more frequently required compared with patients with ICMs.⁴³

In ARVD patients undergoing catheter ablation, the freedom from VT recurrence is generally good during long-term follow-up.⁴⁴ (Figure 5)

Kirubakaran et al³² reported 29 ARVD patients undergoing VT ablation, classifying their cardiomyopathies as “electrical” or “structural” according on the presence of major structural criteria. In patients with an electrical cardiomyopathy the scar was only found close to the epicardial surface, mainly in the outflow tract, whereas patients with a structural disease showed a greater involvement of the endocardium. Targeting the LPs proved to be effective to prevent VT recurrences in both groups, although, when compared with the electrical cardiomyopathies, patients with a structural RV cardiomyopathy showed a trend toward higher recurrence rates (40% vs 15%).

5.3 | Postmyocarditis

Postmyocarditis seems to be characterized by an arrhythmogenic substrate set predominantly in the epicardium.⁴⁵ The previous study reported how 23 patients with postmyocarditis (88% of the study population) required an epicardial ablation, and that catheter ablation was a safe and effective solution in the short term (77% of the patients remained free of VT recurrences during the 2 year follow-up period).⁴⁶

Due to the lateral LV wall localization of the arrhythmogenic substrate, the epicardial ablations were frequently limited by the

presence of the coronary arteries and phrenic nerve; 19% of the patients required their phrenic nerve to be displaced with a valvuloplasty balloon, allowing to complete the LP abolition in the majority of the cases (Figure 6). However, the proximity of a coronary artery to the ablation site remains an unresolved issue.

5.4 | Valve heart disease

Sustained VTs can occur any time after undergoing after a valve surgery. Eckart et al⁴⁷ reported that periannular scars were frequently observed in patients with VT developed after the valve repair.

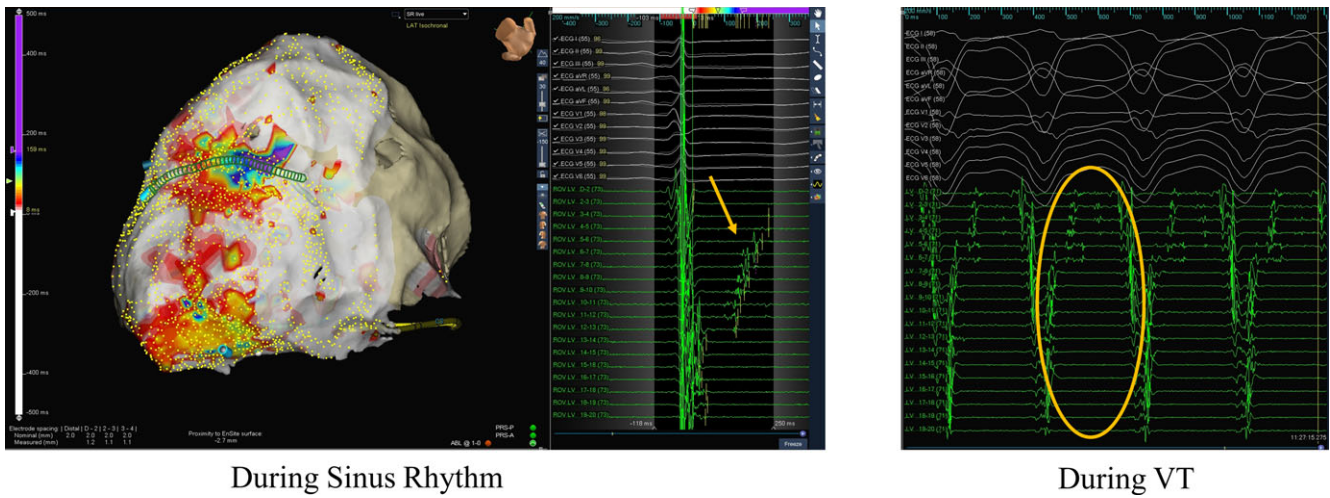
Although the main challenge when dealing with this population is the limited LV accessibility, hindered by the mechanical prosthetic valve, Soejima et al⁴⁸ described the feasibility of the epicardial ablation in patients who had previously undergone an aortic and mitral valve mechanical repair; all patients presented abnormally low voltage areas with fractionated or delayed isolated potentials on the apical epicardium, and a microscopic pathological evaluation of the resected tissue of two patients revealed more dense fibrosis on the epicardium than the endocardium. These findings may allow the option of an ablation strategy based on the epicardial access only to be considered even in case of previous mechanical prosthetic valve surgery.

5.5 | Hypertrophic cardiomyopathy

In patients with hypertrophic cardiomyopathies (HCMs), the occurrence of monomorphic VTs is rare. Dukkipati et al⁴⁹ studied 10 such patients, identifying an epicardial scar in 8 of them (80%) and an endocardial scar in 6 (60%); 78% of the patients remained free from VT recurrences during the follow-up period (median of about 3 years).

5.6 | Lamin A/C cardiomyopathy

About 10% of the DCM patients present pathogenic genetic mutations in proteins encoded by the Lamin A/C (LMNA) gene. This



During Sinus Rhythm

During VT

FIGURE 5 Late potential (LP) mapping and VT activation pattern in a patient with ARVD. Representative case of LP mapping and ablation. 3D activation map in patients with arrhythmogenic right ventricular dysplasia. During creating the sinus activation map (left panel), LPs were recorded after QRS offset (blue arrow), while, during the ventricular tachycardia (VT) (right panel), these same LPs became the whole diastolic potential (orange arrow) connecting the first QRS to the next one. Therefore, we performed the ABL aiming at the area where we had recorded the LPs, finally obtaining the VT noninducibility

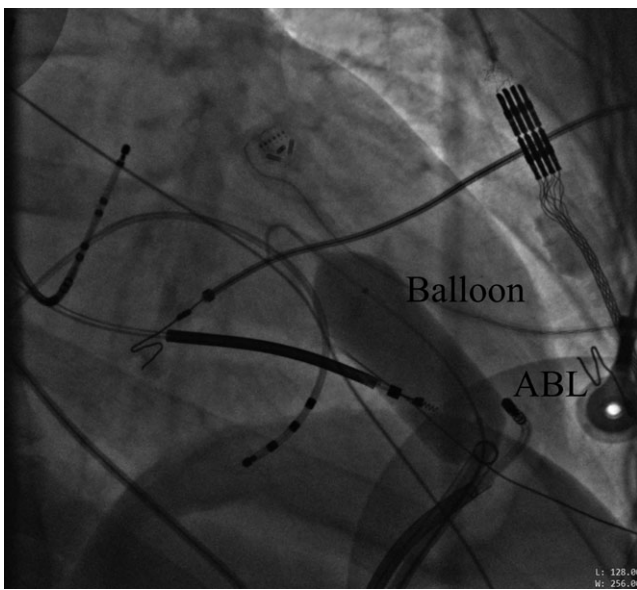


FIGURE 6 Phrenic nerve displacement with balloon in a patient with myocarditis. Fluoroscopic images of the displacement of the phrenic nerve using a large balloon (20 mm × 45 mm) in the right anterior oblique view in the myocarditis case. When the balloon was inflated, the phrenic capture successfully disappeared. After confirming the PN displacement, a late potential abolition was performed at that site. ABL, ablation catheter

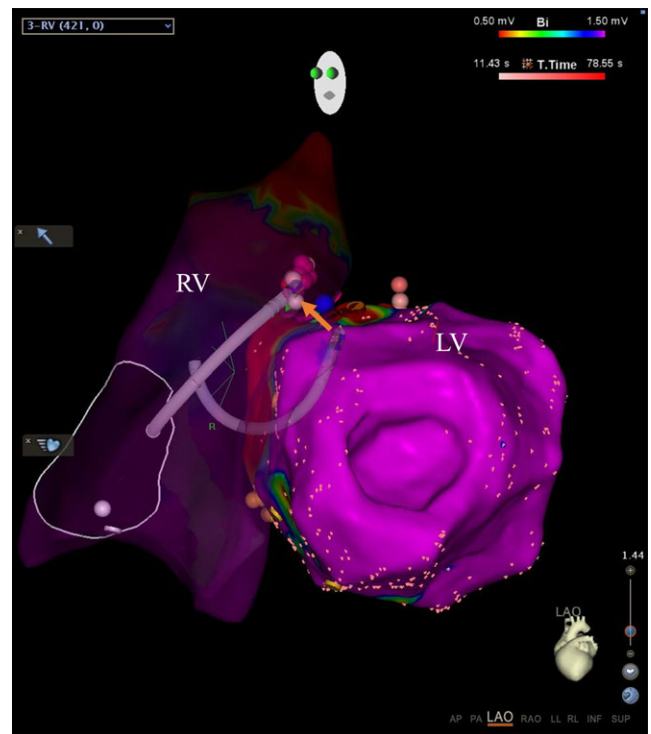


FIGURE 7 Bipolar ablation in a patient with IDCM. Right ventricle (RV) and left ventricle (LV) in left anterior oblique view (LAO). Orange arrow indicates the correlation between the two ablation catheter's tips during RF delivery to create transmural lesion at septum. IDCM, idiopathic dilated cardiomyopathy

autosomal dominant heart disease is generally more severe than other kind of DCMs, and it's characterized by a progressive conduction system impairment and a high risk of life-threatening ventricular arrhythmias.⁵⁰ The arrhythmogenic substrate in patients with the LMNA mutation is usually represented by an intramural and/or basal perivalvular scar, which probably explains why performing a catheter ablation in this setting is particularly challenging and less effective.⁵¹

5.7 | Cardiac sarcoidosis

Cardiac sarcoidosis is usually characterized by a severe progressive heart failure, conduction system disorders and malignant ventricular arrhythmias; unfortunately, CA in these patients is burdened by a

high recurrence rate, coherent with the rapid progression of the pathology.⁵² A recent study on this condition identified the VT mechanisms as being either scar- or Purkinje-related, and showed how a systematic approach combining amiodarone, a systemic corticosteroids therapy and CA could effectively reduce the incidence of VT recurrences.⁵³

6 | WHAT SHOULD WE DO?

Recently, a multicenter study reported positive data on VT ablation in a huge number of patients with NICMs: among the 133 529 patients hospitalized with a principal diagnosis of VT in NICMs, 14 651 (11.0%) underwent an ablation.¹⁹ The in-hospital mortality numbered 172 of 14 318 (1.2%) patients in the catheter ablation group that, when compared with the 297 deceased among the 14 156 (2.1%) patients undergoing a medical therapy, led the authors to conclude that catheter ablation was the safest option.

Although randomized trials will be necessary to confirm these findings, such a large-scale study surely encourage us to consider the ablation of VT more feasible option in the setting of NICMs.

Our group previously reported that a combined endpoint of LP abolition and VT noninducibility was effective to increase the long-term arrhythmia-free survival in patients with ICM¹³; on the other hand, it is still unknown whether such benefit extends also to patients with NICM.

In our experience, comprising 403 patients with NICMs, the above mentioned combined endpoint was independently associated with free survival from VT (hazard ratio (HR) 0.42, 95% Confidence Interval (CI) [0.28-0.64], $P < 0.0001$) and cardiac death (HR 0.42, 95%CI [0.21-0.82], $P = 0.001$); more specifically, the 1-year VT free survival rate differed across the aetiologies, with a 62% for patients with DCMs, 79% in case of myocarditis, 86% for ARVDs, 68% in presence of a valvular heart disease and 72% in the remaining etiologies. We concluded that, even for patients with NICMs, the strategy of LP abolition and noninducibility could bear positive results in the long term. However, we again strongly recommend to plan the ablation according to the particular characteristics of every single patient, as the blind application of general criteria might prove misleading.

7 | NEW TOOLS FOR VT ABLATION

A new multipolar grid mapping catheter⁵⁴ has recently been made available and, being able to create different voltage/activation maps considering the bipolar electrograms from orthogonal wavefront direction relative to the electrodes orientation, it might be useful for mapping the ventricle.

We have been investigating the impact of a bipolar ablation to treat VTs with a septal substrate, approached with two ablation catheters opposing each other across the septum to create a transmural lesion (Figure 7).⁵⁵ For intramural lesion, irrigated needle ablations might be of future help.⁵⁶

8 | CONCLUSION

As the number of VT ablations in patients with NICMs is rising, it is more than ever necessary to identify the best strategy to treat this population. To attain this goal, however, further studies are necessary.

ACKNOWLEDGEMENTS

None.

CONFLICT OF INTEREST

Authors declare no conflict of interests for this article.

ORCID

Kenji Okubo  <http://orcid.org/0000-0003-2370-461X>

REFERENCES

- Poole JE, Johnson GW, Hellkamp AS, et al. Prognostic importance of defibrillator shocks in patients with heart failure. *N Engl J Med.* 2008;359:1009–17.
- Ferreira-González I, Dos-Subirá L, Guyatt GH. Adjunctive antiarrhythmic drug therapy in patients with implantable cardioverter defibrillators: a systematic review. *Eur Heart J.* 2007;28:469–77.
- Julian DG, Camm AJ, Frangin G, et al. Randomised trial of effect of amiodarone on mortality in patients with left-ventricular dysfunction after recent myocardial infarction: EMIAT. *European Myocardial Infarct Amiodarone Trial Investigators. Lancet.* 1997;349:667–74.
- Bardy GH, Lee KL, Mark DB, et al. Amiodarone or an implantable cardioverter-defibrillator for congestive heart failure. *N Engl J Med.* 2005;352:225–37.
- Buxton AE, Lee KL, Fisher JD, Josephson ME, Prystowsky EN, Hafley G. A randomized study of the prevention of sudden death in patients with coronary artery disease. *Multicenter Unsustained Tachycardia Trial Investigators. N Engl J Med.* 1999;341:1882–90.
- Moss AJ, Zareba W, Hall WJ, et al. Prophylactic implantation of a defibrillator in patients with myocardial infarction and reduced ejection fraction. *N Engl J Med.* 2002;346:877–83.
- Kadish A, Dyer A, Daubert JP, et al. Prophylactic defibrillator implantation in patients with nonischemic dilated cardiomyopathy. *N Engl J Med.* 2004;350:2151–8.
- Køber L, Thune JJ, Nielsen JC, et al. Defibrillator implantation in patients with nonischemic systolic heart failure. *N Engl J Med.* 2016;375:1221–30.
- Della Bella P, Baratto F, Tsiachris D, et al. Management of ventricular tachycardia in the setting of a dedicated unit for the treatment of complex ventricular arrhythmias: long-term outcome after ablation. *Circulation.* 2013;127:1359–68.
- Sacher F, Tedrow UB, Field ME, et al. Ventricular tachycardia ablation: evolution of patients and procedures over 8 years. *Circ Arrhythm Electrophysiol.* 2008;1:153–61.
- Tung R, Vaseghi M, Frankel DS, et al. Freedom from recurrent ventricular tachycardia after catheter ablation is associated with improved survival in patients with structural heart disease: an International VT Ablation Center Collaborative Group study. *Heart Rhythm.* 2015;12:1997–2007.

12. Sapp JL, Wells GA, Parkash R, et al. Ventricular tachycardia ablation versus escalation of antiarrhythmic drugs. *N Engl J Med*. 2016;375:111–21.
13. Silberbauer J, Oloriz T, Maccabelli G, et al. Noninducibility and late potential abolition: a novel combined prognostic procedural end point for catheter ablation of postinfarction ventricular tachycardia. *Circ Arrhythm Electrophysiol*. 2014;7:424–35.
14. Yamashita S, Cochet H, Sacher F, et al. Impact of new technologies and approaches for post-myocardial infarction ventricular tachycardia ablation during long-term follow-up. *Circ Arrhythm Electrophysiol*. 2016;9:e003901.
15. Gökoçlan Y, Mohanty S, Gianni C, et al. Scar homogenization versus limited-substrate ablation in patients with nonischemic cardiomyopathy and ventricular tachycardia. *J Am Coll Cardiol*. 2016;68:1990–8.
16. Tokuda M, Tedrow UB, Kojodjojo P, et al. Catheter ablation of ventricular tachycardia in nonischemic heart disease. *Circ Arrhythm Electrophysiol*. 2012;5:992–1000.
17. Dinov B, Fiedler L, Schönbauer R, et al. Outcomes in catheter ablation of ventricular tachycardia in dilated nonischemic cardiomyopathy compared with ischemic cardiomyopathy: results from the Prospective Heart Centre of Leipzig VT (HELP-VT) Study. *Circulation*. 2014;129:728–36.
18. Liang JJ, Santangeli P, Callans DJ. Long-term outcomes of ventricular tachycardia ablation in different types of structural heart disease. *Arrhythm Electrophysiol Rev*. 2015;4:177–83.
19. Briceño DF, Gupta T, Romero J, et al. Catheter ablation of ventricular tachycardia in non-ischemic cardiomyopathy: a propensity score-matched analysis of in-hospital outcomes in the United States. *J Cardiovasc Electrophysiol*. 2018;29:771–9.
20. Miller JM, Jain R, Dandamudi G, Kambur TR. Electrocardiographic localization of ventricular tachycardia in patients with structural heart disease. *Card Electrophysiol Clin*. 2017;9:1–10.
21. Oloriz T, Silberbauer J, Maccabelli G, et al. Catheter ablation of ventricular arrhythmia in nonischemic cardiomyopathy: anteroseptal versus inferolateral scar sub-types. *Circ Arrhythm Electrophysiol*. 2014;7:414–23.
22. Oloriz T, Wellens HJJ, Santagostino G, et al. The value of the 12-lead electrocardiogram in localizing the scar in non-ischaemic cardiomyopathy. *Eurospace*. 2016;18:1850–9.
23. Bogun FM, Desjardins B, Good E, et al. Delayed-enhanced magnetic resonance imaging in nonischemic cardiomyopathy: utility for identifying the ventricular arrhythmia substrate. *J Am Coll Cardiol*. 2009;53:1138–45.
24. Piers SRD, Tao Q, van Huls van Taxis CFB, Schaliij MJ, van der Geest RJ, Zeppenfeld K. Contrast-enhanced MRI-derived scar patterns and associated ventricular tachycardias in nonischemic cardiomyopathy: implications for the ablation strategy. *Circ Arrhythm Electrophysiol*. 2013;6:875–83.
25. Esposito A, Palmisano A, Antunes S, et al. Cardiac CT with delayed enhancement in the characterization of ventricular tachycardia structural substrate: relationship between ct-segmented scar and electro-anatomic mapping. *JACC Cardiovasc Imaging*. 2016;9:822–32.
26. Nakahara S, Tung R, Ramirez RJ, et al. Characterization of the arrhythmogenic substrate in ischemic and nonischemic cardiomyopathy implications for catheter ablation of hemodynamically unstable ventricular tachycardia. *J Am Coll Cardiol*. 2010;55:2355–65.
27. Baratto F, Pappalardo F, Oloriz T, et al. Extracorporeal membrane oxygenation for hemodynamic support of ventricular tachycardia ablation. *Circ Arrhythm Electrophysiol*. 2016;9:e004492.
28. Soejima K, Stevenson WG, Sapp JL, Selwyn AP, Couper G, Epstein LM. Endocardial and epicardial radiofrequency ablation of ventricular tachycardia associated with dilated cardiomyopathy: the importance of low-voltage scars. *J Am Coll Cardiol*. 2004;43:1834–42.
29. Reithmann C, Herkommer B, Fiek M. Epicardial ventricular tachycardia substrate visualized by magnetic resonance imaging: need for a transpericardial ablation approach? *Clin Res Cardiol*. 2016;105:827–37.
30. Berruezo A, Mont L, Nava S, Chueca E, Bartholomay E, Brugada J. Electrocardiographic recognition of the epicardial origin of ventricular tachycardias. *Circulation*. 2004;109:1842–7.
31. Vallès E, Bazan V, Marchlinski FE. ECG criteria to identify epicardial ventricular tachycardia in nonischemic cardiomyopathy. *Circ Arrhythm Electrophysiol*. 2010;3:63–71.
32. Kirubakaran S, Bisceglia C, Silberbauer J, et al. Characterization of the arrhythmogenic substrate in patients with arrhythmogenic right ventricular cardiomyopathy undergoing ventricular tachycardia ablation. *Eurospace*. 2017;19:1049–62.
33. Tsiachris D, Silberbauer J, Maccabelli G, et al. Electroanatomical voltage and morphology characteristics in postinfarction patients undergoing ventricular tachycardia ablation: pragmatic approach favoring late potentials abolition. *Circ Arrhythm Electrophysiol*. 2015;8:863–73.
34. Polin GM, Haqqani H, Tzou W, et al. Endocardial unipolar voltage mapping to identify epicardial substrate in arrhythmogenic right ventricular cardiomyopathy/dysplasia. *Heart Rhythm*. 2011;8:76–83.
35. Dinov B, Schratte A, Schirripa V, et al. Procedural outcomes and survival after catheter ablation of ventricular tachycardia in relation to electroanatomical substrate in patients with nonischemic-dilated cardiomyopathy: the role of unipolar voltage mapping. *J Cardiovasc Electrophysiol*. 2015;26:985–93.
36. Della Bella P, Brugada J, Zeppenfeld K, et al. Epicardial ablation for ventricular tachycardia: a European multicenter study. *Circ Arrhythm Electrophysiol*. 2011;4:653–9.
37. Kottkamp H, Hindricks G, Chen X, et al. Radiofrequency catheter ablation of sustained ventricular tachycardia in idiopathic dilated cardiomyopathy. *Circulation*. 1995;92:1159–68.
38. Dinov B, Arya A, Schratte A, et al. Catheter ablation of ventricular tachycardia and mortality in patients with nonischemic dilated cardiomyopathy: can noninducibility after ablation be a predictor for reduced mortality? *Circ Arrhythm Electrophysiol*. 2015;8:598–605.
39. Hsia HH, Callans DJ, Marchlinski FE. Characterization of endocardial electrophysiological substrate in patients with nonischemic cardiomyopathy and monomorphic ventricular tachycardia. *Circulation*. 2003;108:704–10.
40. Haqqani HM, Tschabrunn CM, Tzou WS, et al. Isolated septal substrate for ventricular tachycardia in nonischemic dilated cardiomyopathy: incidence, characterization, and implications. *Heart Rhythm*. 2011;8:1169–76.
41. Muser D, Santangeli P, Castro SA, et al. Long-term outcome after catheter ablation of ventricular tachycardia in patients with nonischemic dilated cardiomyopathy. *Circ Arrhythm Electrophysiol*. 2016;9:e004328.
42. Marchlinski FE, Zado E, Dixit S, et al. Electroanatomic substrate and outcome of catheter ablative therapy for ventricular tachycardia in setting of right ventricular cardiomyopathy. *Circulation*. 2004;110:2293–8.
43. Garcia FC, Bazan V, Zado ES, Ren J-F, Marchlinski FE. Epicardial substrate and outcome with epicardial ablation of ventricular tachycardia in arrhythmogenic right ventricular cardiomyopathy/dysplasia. *Circulation*. 2009;120:366–75.
44. Santangeli P, Zado ES, Supple GE, et al. Long-term outcome with catheter ablation of ventricular tachycardia in patients with arrhythmogenic right ventricular cardiomyopathy. *Circ Arrhythm Electrophysiol*. 2015;8:1413–21.
45. Berte B, Sacher F, Cochet H, et al. Postmyocarditis ventricular tachycardia in patients with epicardial-only scar: a specific entity requiring a specific approach. *J Cardiovasc Electrophysiol*. 2015;26:42–50.
46. Maccabelli G, Tsiachris D, Silberbauer J, et al. Imaging and epicardial substrate ablation of ventricular tachycardia in patients late after myocarditis. *Eurospace*. 2014;16:1363–72.

47. Eckart RE, Hruczkowski TW, Tedrow UB, Koplan BA, Epstein LM, Stevenson WG. Sustained ventricular tachycardia associated with corrective valve surgery. *Circulation*. 2007;116:2005–11.
48. Soejima K, Nogami A, Sekiguchi Y, et al. Epicardial catheter ablation of ventricular tachycardia in no entry left ventricle: mechanical aortic and mitral valves. *Circ Arrhythm Electrophysiol*. 2015;8:381–9.
49. Dukkupati SR, d'Avila A, Soejima K, et al. Long-term outcomes of combined epicardial and endocardial ablation of monomorphic ventricular tachycardia related to hypertrophic cardiomyopathy. *Circ Arrhythm Electrophysiol*. 2011;4:185–94.
50. Pinto YM, Elliott PM, Arbustini E, et al. Proposal for a revised definition of dilated cardiomyopathy, hypokinetic non-dilated cardiomyopathy, and its implications for clinical practice: a position statement of the ESC working group on myocardial and pericardial diseases. *Eur Heart J*. 2016;37:1850–8.
51. Kumar S, Androulakis AFA, Sellal J-M, et al. Multicenter experience with catheter ablation for ventricular tachycardia in lamin A/C cardiomyopathy. *Circ Arrhythm Electrophysiol*. 2016;9:e004357.
52. Koplan BA, Soejima K, Baughman K, Epstein LM, Stevenson WG. Refractory ventricular tachycardia secondary to cardiac sarcoid: electrophysiologic characteristics, mapping, and ablation. *Heart Rhythm*. 2006;3:924–9.
53. Naruse Y, Sekiguchi Y, Nogami A, et al. Systematic treatment approach to ventricular tachycardia in cardiac sarcoidosis. *Circ Arrhythm Electrophysiol*. 2014;7:407–13.
54. Massé S, Magtibay K, Jackson N, et al. Resolving myocardial activation with novel omnipolar electrograms. *Circ Arrhythm Electrophysiol*. 2016;9:e004107.
55. Gizurarson S, Spears D, Sivagangabalan G, et al. Bipolar ablation for deep intra-myocardial circuits: human ex vivo development and in vivo experience. *Eurospace*. 2014;16:1684–8.
56. Berte B, Cochet H, Magat J, et al. Irrigated needle ablation creates larger and more transmural ventricular lesions compared with standard unipolar ablation in an ovine model. *Circ Arrhythm Electrophysiol*. 2015;8:1498–506.

How to cite this article: Okubo K, Gigli L, Della Bella P. Catheter ablation of ventricular tachycardia in nonischemic cardiomyopathy. *J Arrhythmia*. 2018;34:347–355.
<https://doi.org/10.1002/joa3.12099>