

# Comparison the clinical outcomes and complications of high-viscosity versus low-viscosity in osteoporotic vertebral compression fractures

Zhao Guo, MD<sup>a</sup>, Wei Wang, MD<sup>a</sup>, Wen-shan Gao, MD<sup>b</sup>, Fei Gao, MD<sup>b</sup>, Hui Wang, MD<sup>a</sup>, Wen-Yuan Ding, MD<sup>a,\*</sup>

## Abstract

To compare the clinical outcomes and complications of high viscosity and low viscosity bone cement percutaneous vertebroplasty (PVP) for osteoporotic vertebral compression fractures (OVCF).

From September 2009 to September 2015, 100 patients with OVCF were randomly divided into 2 groups: group H, using high viscosity cement (n=50) or group L, using low viscosity cement (n=50). The clinical outcomes were assessed by the visual analog scale (VAS), Oswestry Disability Index (ODI), kyphosis Cobb angle, vertebral height, and complications.

Significant improvements in the VAS, ODI, kyphosis Cobb angle, and vertebral height were noted in both groups, and the VAS score in the H group showed greater benefit than in the L group. Cement leakage was observed less in group H. Postoperative assessment using computed tomography identified cement leakage in 27 of 98 (27.6%) vertebrae in group H and in 63 of 86 (73.3%) vertebrae in group L ( $P = .025$ ).

Compared with PVP using low viscosity bone cement, PVP using high viscosity bone cement can provide the same clinical outcomes with fewer complications and is recommended for routine clinical use.

**Abbreviations:** CT = computed tomography, ODI = Oswestry Disability Index, OVCF = osteoporotic vertebral compression fractures, PE = pulmonary embolism, PKP = percutaneous vertebroplasty, PVP = percutaneous vertebroplasty, VAS = visual analog scale.

**Keywords:** high viscosity, low viscosity, osteoporotic vertebral compression fractures

## 1. Introduction

Osteoporotic vertebral compression fractures (OVCF) are one of the most common osteoporotic fractures in elderly patients, causing back pain and spinal deformity.<sup>[1–3]</sup> Many traditional conservative therapies, including bed rest and the use of analgesics, have been applied to relieve pain and restore mechanical strength.<sup>[4]</sup> Open surgery is not always an optimal treatment for OVCF because of the poor quality of osteoporotic bones.<sup>[5–7]</sup> Percutaneous vertebroplasty (PKP), a new technique, is one of the most successful treatments for OVCF to relieve pain

and deformity, with a low incidence of adverse events and morbidity.

However, bone cement leakage remains an unsolved problem that puzzles most orthopedic surgeons, and it has been reported that nearly 43% to 45% of patients whose PKP was performed with low viscosity bone cement had leakage detected by X-ray and 78% to 91.9% detected by computed tomography (CT) scan.<sup>[8–10]</sup> Cement leakage can cause neurologic deficits and fateful complications such as pulmonary embolism (PE).

To avoid cement leakage and subsequent complications, technical improvements, high viscosity bone cement, and accurate imaging in the hands of skilled operators were adopted; however, the outcomes is inconclusive. Recent studies have demonstrated that viscosity is a major influencing factor for cement leakage, and high viscosity is an efficient method to reduce the risk of extravasation and enhance the safety of PKP. Nieuwenhuijse et al<sup>[11]</sup> compared low versus medium viscosity bone cement in percutaneous vertebroplasty (PVP) and found no significant difference between the 2 groups. Thus, the patients in our hospital who received high viscosity and low viscosity cement for PVP were reviewed to identify the most safe and effective method and to reduce cement leakage.

## 2. Materials and methods

From September 2009 to September 2015, 100 patients with vertebral compression fractures who underwent vertebroplasty were reviewed. There were 25 males and 25 females, mean age  $77.2 \pm 8.1$  years old (range 60–88 years old), in the high viscosity group and 28 males and 22 females, mean age  $75.4 \pm 6.8$  years old

Editor: Goran Augustin.

The authors have no funding and conflicts of interest to disclose.

<sup>a</sup> Department of Spine Surgery, the Third Hospital of Hebei Medical University, Shijiazhuang, <sup>b</sup> Department of Orthopedics, the Affiliated Hospital of Hebei University, Baoding, China.

\* Correspondence: Wen-Yuan Ding, Department of Spine Surgery, the Third Hospital of Hebei Medical University, 139 Ziqiang Road, Shijiazhuang 050051, China (e-mail: dongtianleng2017@163.com).

Copyright © 2017 the Author(s). Published by Wolters Kluwer Health, Inc. This is an open access article distributed under the terms of the Creative Commons Attribution-Non Commercial License 4.0 (CCBY-NC), where it is permissible to download, share, remix, transform, and buildup the work provided it is properly cited. The work cannot be used commercially without permission from the journal.

Medicine (2017) 96:48(e8936)

Received: 20 February 2017 / Received in final form: 7 November 2017 /

Accepted: 8 November 2017

<http://dx.doi.org/10.1097/MD.00000000000008936>

**Table 1**  
Surgical parameters of the studied population.

Parameter	H group	L group	$t/\chi^2$ value	<i>P</i>
Patients	50	50		
Male/female	25:25	28:22	3.672	.055
Age, y	77.2±8.1	75.4±6.8	1.076	.285
Vertebral bodies (n)	98	86	NS	NS
BMI, kg/m <sup>2</sup>	23.4±3.5	24.1±2.8	0.988	.326
Disease duration, d	4.4±2.3	3.8±1.9	1.272	.207
Operative time, min	45.7±10.4	42.1±8.7	1.679	.097
Injected cement volume, mL	3.4±0.6	3.5±0.8	0.632	.529
Unipedicular/bipedicular approach	25:25	26:24	0.170	.680

BMI = body mass index, NS = not significant.

(range 59 to 86 years old), in the low viscosity group. Follow-up times in the high viscosity and low viscosity groups were 1.2 to 3.4 years (mean 2.5±0.8 years) and 1.1 to 3.8 years (2.2±1.6 years), respectively. Some patients had low back pain, pain when turning over and were unable to stand up, along with pain when supine, which worsened when bending over. Detailed patient information can be seen in Table 1. This study was approved by the ethics committee of the Third Hospital of Hebei Medical University.

### 2.1. Inclusion and exclusion criteria

Patients were included in the study if they had clinical symptoms in accordance with physical examination and imaging examination (international recognized imaging [X plain film, CT, MRI]); were above 55 years old; had severe OVCFs (part of the vertebral body collapsed to less than one-third of original height); had back pain related to the location of the OVCF on spinal radiographs and a visual analog scale (VAS) score >5; and were diagnosed to have an apparent bone edema in the fractured vertebra on MRI T2-weighted short tau inversion recovery sequences. Patients were excluded if they had a history of mental illness, cardiopulmonary disease, or history of hormone use; had spinal cord compression or stenosis of the vertebral canal >30% of the local canal diameter; had neurologic deficits or uncorrectable bleeding disorders; and had systemic or local spine infections or pathologic fracture.

### 2.2. Procedures

All patients lay prostrate on a 4-point support frame for spine surgery to keep the chest and abdomen hung, with the head fixed by the head frame. A C-arm X-ray machine was used to locate and mark the entry point. Then, regular skin disinfection was performed and sterile drapes were placed on the entry point. Next, 1% lidocaine was used in subcutaneous local anesthesia, the puncture needle was inserted into the superior outer edge, and the needle direction was determined under fluoroscopy. The puncture needle was slowly inserted ventrally into the 3rd vertebral body, and the C-arm X-ray machine was used to confirm that the needle was in satisfactory position. Adjusted bone cement was injected into the vertebral body under C-arm X-ray machine fluoroscopy and was gradually spread out. Pathological examination was made if necessary.

High viscosity bone cement (Heraeus Medical GmbH, Germany) was used in the high viscosity bone cement group, and high viscosity bone cement was adjusted to the wire drawing stage, following manufacturer directions, which was injected into

the vertebral body with an injection syringe and special hydraulic propulsion pump. Low viscosity bone cement (Tecres S P A, Italy) was used in the low viscosity bone cement group, and low viscosity bone cement was adjusted following manufacturer directions. Patients were in the supine position and were under close observation postoperatively. Blood pressure, heart rate, and oxygen saturation were checked per 15 minutes in the 1st postoperative hour. Specific treatment was applied to osteoporotic patients. According to the patients' rehabilitation condition, patients were guided to exercise the function of low back muscles and were helped to walk with the protection of a lumbar brace. Imaging examination, including X plain film, was applied at 1 day and 3 months postoperatively.

### 2.3. Observation indexes

Evaluation of distribution and leakage of bone cement: spine X-ray plain film at the 1st day postoperatively and spine CT were read by 2 independent radiologists to check whether bone cement contacted both the upper and lower endplates simultaneously and if there was bone cement side distribution. The bone cement leakage included vein effusion, paravertebral leakage, and intervertebral disc leakage. Pain relief assessment: the 11-point VAS was used to assess pain at 1 day and 3 months postoperatively. Evaluation for the improvement of spinal function: Oswestry Disability Index (ODI) was used to assess spinal function preoperatively and at 1 day and 3 months postoperatively. Evaluation for height rehabilitation of fractured vertebrae: Cobb angle was measured in vertebral lateral X plain film to assess the front height of vertebral body fracture and rehabilitation of kyphosis deformity. Rate of bone cement pulmonary embolization postoperatively: the postoperative vertebral refracture of the surgical vertebral body or nonsurgical vertebral body was evaluated by X-ray plain film and CT.

### 2.4. Statistical analysis

Software SPSS 20.0 (SPSS, Chicago, IL) was used for statistical analysis. The continuous outcomes were expressed as the mean ± standard deviation, and statistical analysis was performed with Student paired *t* test. And discontinuous outcomes were analyzed by chi-square test; *P* < .05 was regarded as significant.

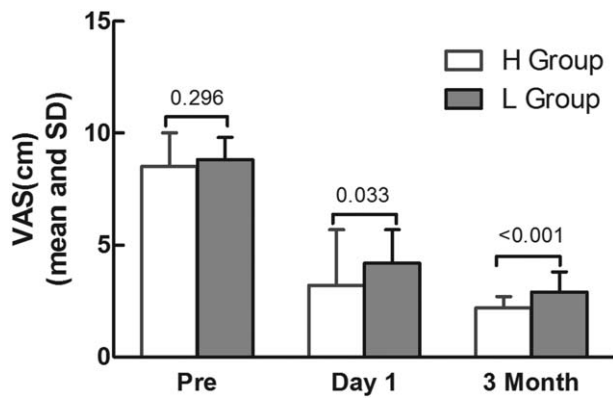
## 3. Results

### 3.1. General procedure results

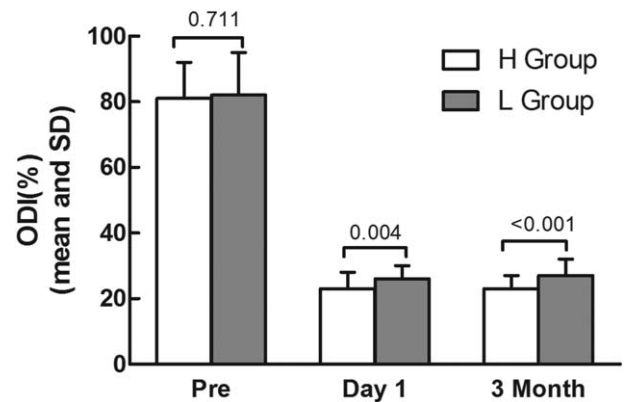
All surgeries were performed successfully, and there was no significant difference (*P* > .05) between the operating time in the high viscosity and the low viscosity groups. The bone cement volume injected was 3.4±0.6 and 3.5±0.8 mL, respectively, in the high viscosity and low viscosity groups, and this difference was not significant (*P* > .05). There were 25 patients in the high viscosity group and 23 patients in the low viscosity group who underwent the unipedicular approach; and 23 patients and 24 patients in the high viscosity and low viscosity groups, respectively, who underwent the bipedicular approach; there was no significant difference between the 2 groups.

### 3.2. Comparison of VAS and ODI between the 2 groups

There was no significant difference in the preoperative VAS score between the 2 groups (*t* = 1.052, *P* = .296); however, the VAS score in the H group was significantly lower than the L group at



**Figure 1.** Comparison of visual analog scale (VAS) score between the 2 groups preoperatively, 1 day postoperative and 3 months postoperative. H group, high viscosity group; L group, low viscosity group; Pre, preoperation.



**Figure 2.** Comparison of Oswestry Disability Index (ODI) between the 2 groups preoperatively, 1 day postoperative and 3 months postoperative. H group, high viscosity group; L group, low viscosity group; Pre, preoperation.

postoperative day 1 and 3 months after operation ( $t=2.169$ ,  $P=.033$ ,  $t=4.300$ ,  $P<.001$ , Fig. 1, Table 2).

There was no significant difference in the preoperative ODI between the 2 groups ( $t=0.371$ ,  $P=.711$ ), but the ODI score in the H group was significantly lower than the L group at postoperative day 1 and 3 months after vertebroplasty ( $t=2.963$ ,  $P=.004$ ,  $t=3.951$ ,  $P<.001$ , Fig. 2 and Table 3).

**3.3. Comparison of Cobb angle and vertebral angle between the 2 groups**

There was no significant difference in the preoperative Cobb angle between the 2 groups ( $t=0.105$ ,  $P=.917$ ), and Cobb angle in the H group was significantly lower than in the L group at postoperative day 1 and 3 months after vertebroplasty ( $t=7.904$ ,  $P<.001$ ,  $t=7.597$ ,  $P<.001$ , Fig. 3, Table 4).

There was no significant difference in preoperative vertebral height between the 2 groups ( $t=1.052$ ,  $P=.296$ ), and vertebral height in the H group was significantly higher than in the L group at postoperative day 1 and 3 months after vertebroplasty ( $t=2.604$ ,  $P=.011$ ,  $t=9.519$ ,  $P<.001$ , Fig. 4, Table 5).

**3.4. Comparison of bone cement leakage rates and bone cement distribution inside the vertebral body**

There were 98 treatment segments in the H group and 86 treatment segments in the L group. As for total leakage rate, the bone cement occurrence rate in the H group (27.6%) is significantly lower than in the L group (73.3%), and the difference is statistically significant ( $\chi^2=38.291$ ,  $P<.001$ , Table 6); however, there are no significant differences between the H and L groups in terms of intracranial leakage and paravertebral leakage ( $\chi^2=0.835$ ,  $P=.361$ ,  $\chi^2=1.031$ ,  $P=.310$ ,

Table 6). The occurrence rate of intervertebral disc leakage and vein leakage in the H group is significantly lower than in the L group, and the difference is statistically significant ( $\chi^2=15.569$ ,  $P<.001$ ,  $\chi^2=9.116$ ,  $P=.003$ , Table 6).

The postoperative refracture rate of surgical vertebral body or nonsurgical body and rate of bone cement PE between 2 groups.

There was 1 refracture of surgical vertebral body in the low viscosity bone cement group during follow-up and no refractures in the high viscosity bone cement group. One case of postoperative adjacent vertebral fracture was found in the low viscosity bone cement group. There was no significant difference in the refracture rate of surgical vertebral body or nonsurgical vertebrae body in both groups. No patients in either group had PE of bone cement postoperatively.

**4. Discussion**

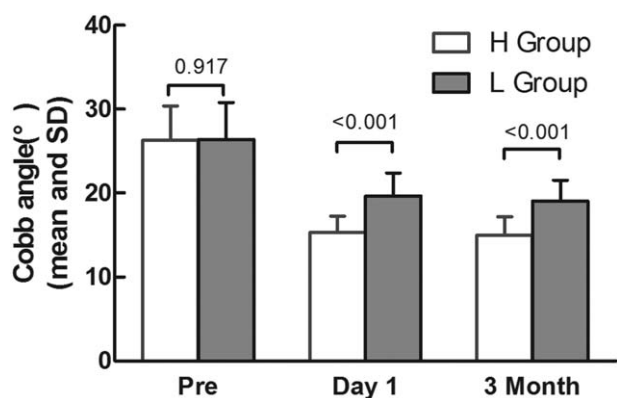
Osteoporosis is a common disease worldwide that has a severe impact on elderly health and large economic costs. It is reported that approximately 30% to 40% of women will be at risk of osteoporotic fracture and thus, the cost for fractures will increase correspondingly. It is reported that approximately 40% of osteoporotic patients will experience an OVCF. OVCFs are always associated with poor general condition and thus lead to a significant occurrence of morbidity and respiratory complications.<sup>[1,12,13]</sup> PVP has been identified as one the most successful and safe treatment options for OVCF for many years.<sup>[5-7]</sup> Some researchers have proposed that patients with OVCF should be treated with PVP or PKP as soon as possible.<sup>[14]</sup> However, with the long-term clinical experience of PVP, the severe clinical complications are bone cement leakage and subsequently, PE.<sup>[15]</sup> Some studies showed that compared with high viscosity bone

**Table 2**  
Change in visual analog scale (VAS) score between the 2 groups.

Group	N	Preoperative	Operative day 1	Final follow-up
H group	50	8.5±1.5	3.2±2.5	0.5±0.7
L group	50	8.8±1.0	3.0±1.8	0.9±0.9
t value		1.052	2.169	4.300
P value		.296	.033	<.000

**Table 3**  
Change of Oswestry Disability Index (ODI) score and vertebral height between the 2 groups.

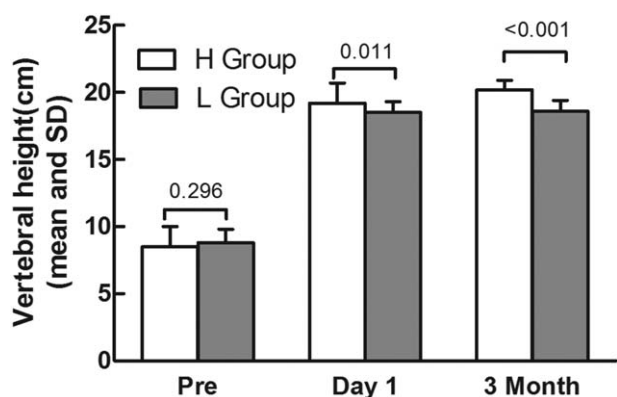
Group	Preoperative	Operative day 1	Final follow-up
H group	81±11	23±5	23±4
L group	82±13	26±4	27±5
t value		0.371	2.963
P value		.711	.004
			<.001



**Figure 3.** Comparison of Cobb angle between the 2 groups preoperatively, 1 day postoperative and 3 months postoperative. H group, high viscosity group; L group, low viscosity group; Pre, preoperation.

**Table 4**  
Change of Cobb angle between the 2 groups.

Group	Preoperative	Operative day 1	Final follow-up
H group	26.3±4.1	15.3±2.0	15.0±2.2
L group	26.4±4.4	19.6±2.8	19.0±2.5
t value	0.105	7.904	7.597
P value	.917	<.001	<.001



**Figure 4.** Comparison of vertebral height between the 2 groups preoperatively, 1 day postoperative and 3 months postoperative. H group, high viscosity group; L group, low viscosity group; Pre, preoperation.

cement, low viscosity bone cement had a higher rate of vein leakage and para-vertebral leakage.<sup>[16]</sup>

The results of our clinical research indicated that compared with the preoperative VAS score, PVP with both high viscosity

**Table 5**  
Change of vertebral height between the 2 groups.

Group	N	Preoperative	Operative day 1	The final follow-up
H group	50	8.5±1.5	19.2±1.5	20.2±0.7
L group	50	8.8±1.0	18.5±0.8	18.6±0.8
t value		1.052	2.604	9.519
P value		.296	.011	<.001

and low viscosity bone cement can reduce this score, with high viscosity bone cement showing greater benefit than low viscosity bone cement. The mechanism may be that high viscosity and low viscosity bone cement have equal function in thermal and chemistry damage to nerves and the reconstruction of vertebral height. These outcomes concur with other studies. Zeng et al<sup>[17]</sup> reviewed 40 patients using high and low viscosity bone cement in vertebroplasty for the treatment of OVCF and found that high viscosity bone cement was equal to low viscosity bone cement for pain control. Nevertheless, the sample in the above studies was limited and additional trials are needed. In past years, Bhatia et al<sup>[18]</sup> administered the routine preinjection of gelfoam embolization during PKP to avoid bone cement leakage; however, the complexity of the procedure limits application of the operation. The rate of venous leakage was 24.4% and 8.2%, respectively, in the low and high viscosity groups. The reason for this differential in rates can be interpreted as venous cement leakage is correlated with cement viscosity; therefore, the high viscosity bone cement can decrease cement leakage.<sup>[19]</sup> Nonetheless, intervertebral disc leakage does not affect final clinical effect, and the occurrence of refracture will be increased.<sup>[20]</sup> As for operating time, there is no significant difference between the 2 groups, so economically related expenditures cannot be increased.

Although there is a lack of clinical evidence to determine the optimal volume of cement to be injected, 2 to 6 mL cement per vertebral body represents the current standard when fractures are located at the lumbar and lower thoracic spine. However, to achieve full kyphosis correction and restore segmental stiffness in the thoracolumbar region, up to 8 mL may be needed. A trade-off may be that a larger volume of injected cement is also more likely to result in extravasations.

The main limitation of this study was the relatively small sample of vertebrae and patients included. Moreover, the duration of follow-up was not long enough; long-term follow-up is needed to identify clinical outcomes.

**5. Conclusion**

In conclusion, high viscosity bone cement could significantly decrease the bone cement leakage rate in PVP, in which high viscosity bone cement has a better effect on OVCF than low viscosity bone cement. Therefore, the administration of high viscosity bone

**Table 6**  
Detailed cement leakage in the 2 groups.

Group	n	Treatment segment	Vein leakage	Intervertebral disc leakage	Para-vertebral leakage	Intracranial leakage	Total leakage rate
H group	50	98	8/98 (8.2%)	7/98 (7.1%)	9/98 (9.2%)	3/98 (3.1%)	27/98 (27.6%)
L group	50	86	21/86 (24.4%)	25/86 (29.1%)	12/86 (14.0%)	5/86 (5.8%)	63/86 (73.3%)
χ <sup>2</sup> value			9.116	15.569	1.031	0.835	38.291
P value			.003	<.001	.310	.361	<.001

cement in PVP could be a more effective and safe method for treating osteoporotic lumbar vertebrae compression fractures.

## References

- [1] Kim K-W, Cho K-J, Kim S-W, et al. A nation-wide, outpatient-based survey on the pain, disability, and satisfaction of patients with osteoporotic vertebral compression fractures. *Asian Spine J* 2013;7: 301–7.
- [2] Zhang L, Wang J, Feng X, et al. A comparison of high viscosity bone cement and low viscosity bone cement vertebroplasty for severe osteoporotic vertebral compression fractures. *Clin Neurol Neurosurg* 2015;129:10–6.
- [3] Dewar C. Diagnosis and treatment of vertebral compression fractures. *Radiol Technol* 2015;86:301–23.
- [4] Macías-Hernández SI, Chávez-Arias DD, Miranda-Duarte A, et al. Percutaneous vertebroplasty versus conservative treatment and rehabilitation in women with vertebral fractures due to osteoporosis: a prospective comparative study. *Rev Invest Clin* 2014;67:98–103.
- [5] Chen D, An Z-Q, Song S, et al. Percutaneous vertebroplasty compared with conservative treatment in patients with chronic painful osteoporotic spinal fractures. *J Clin Neurosci* 2014;21:473–7.
- [6] Xiaochun Li M, Min Yao M, Penfei Y, et al. Comparing pain reduction following vertebroplasty and conservative treatment for osteoporotic vertebral compression fractures: a meta-analysis of randomized controlled trials. *Pain Physician* 2013;16:455–64.
- [7] Lange A, Kasperk C, Alvares L, et al. Survival and cost comparison of kyphoplasty and percutaneous vertebroplasty using German claims data. *Spine* 2014;39:318–26.
- [8] Peh WC, Gilula LA, Peck DD. Percutaneous vertebroplasty for severe osteoporotic vertebral body compression fractures. *Radiology* 2002;223: 121–6.
- [9] Young C, Munk PL, Heran MK, et al. Treatment of severe vertebral body compression fractures with percutaneous vertebroplasty. *Skeletal Radiol* 2011;40:1531–6.
- [10] Chen C, Bian J, Zhang W, et al. Unilateral versus bilateral vertebroplasty for severe osteoporotic vertebral compression fractures. *J Spinal Disord Tech* 2014;27:E301–4.
- [11] Nieuwenhuijse MJ, Muijs SP, van Erkel AR, et al. A clinical comparative study on low versus medium viscosity polymethylmetacrylate bone cement in percutaneous vertebroplasty: viscosity associated with cement leakage. *Spine* 2010;35:E1037–44.
- [12] Lee Y-K, Jang S, Lee H, et al. Mortality after vertebral fracture in Korea. *Osteoporos Int* 2012;23:1859–65.
- [13] Sakuma M, Endo N, Oinuma T, et al. Incidence of osteoporotic fractures in Sado, Japan in 2010. *J Bone Miner Metab* 2014;32:200–5.
- [14] Feng H, Huang P, Zhang X, et al. Unilateral versus bilateral percutaneous kyphoplasty for osteoporotic vertebral compression fractures: a systematic review and meta-analysis of RCTs. *J Orthop Res* 2015;33:1713–23.
- [15] Zhu S-Y, Zhong Z-M, Wu Q, et al. Risk factors for bone cement leakage in percutaneous vertebroplasty: a retrospective study of four hundred and eighty five patients. *Int Orthop* 2016;1–6.
- [16] Lin EP, Ekholm S, Hiwatashi A, et al. Vertebroplasty: cement leakage into the disc increases the risk of new fracture of adjacent vertebral body. *Am J Neuroradiol* 2004;25:175–80.
- [17] Zeng T-H, Wang Y-M, Yang X-J, et al. The clinical comparative study on high and low viscosity bone cement application in vertebroplasty. *Int J Clin Exp Med* 2015;8:18855–60.
- [18] Bhatia C, Barzilay Y, Krishna M, et al. Cement leakage in percutaneous vertebroplasty: effect of preinjection gelfoam embolization. *Spine* 2006;31:915–9.
- [19] Baroud G, Crookshank M, Bohner M. High-viscosity cement significantly enhances uniformity of cement filling in vertebroplasty: an experimental model and study on cement leakage. *Spine* 2006;31: 2562–8.
- [20] Chen LH, Hsieh MK, Liao JC, et al. Repeated percutaneous vertebroplasty for refracture of cemented vertebrae. *Arch Orthop Trauma Surg* 2011;131:927–33.