



Brachioradial Pruritus Caused by Cervical Disc Herniation Precipitated by Trauma Treated with Anterior Cervical Discectomy and Fusion: Report of Two Cases and Review of the Literature

Nicholas S. Hernandez James L. Rogers^{1b} Martin H. Pham

¹ Tufts University School of Medicine, Boston, Massachusetts, United States

² Vanderbilt University School of Medicine, Nashville, Tennessee, United States

³ Department of Neurosurgery, University of California San Diego School of Medicine, La Jolla, California, United States

Address for correspondence Martin H. Pham, MD, Assistant Professor of Neurological Surgery, 9300 Campus Point Drive, MC7893, La Jolla, CA 92037, United States (e-mail: mhpham@health.ucsd.edu).

Asian J Neurosurg 2024;19:101–104.

Abstract

Brachioradial pruritus (BRP) is a rare form of dermatomal pruritus that appears to be caused both by cervical radiculopathy and exposure to ultraviolet-light, although the exact pathophysiology for the manifestation of these symptoms remains to be determined. A diagnosis of BRP is typically confirmed with the “ice-pack” test and evidence of cervical spine pathology using magnetic resonance imaging. Treatment options consist of application of ice, reduction in sun exposure, and topical capsaicin, antiepileptics, or tricyclic antidepressants. Patients with refractory symptoms and cervical spine pathology may be candidates for surgical decompression, particularly at the C5 and C6 levels. However, there are currently no established guidelines to treat BRP, or surgical procedures that have shown to be superior. Here, we report two cases of cervical disc herniations after traumatic events that presented as BRP. Both cases were successfully treated with anterior cervical discectomy and fusion with complete resolution of symptoms.

Keywords

- ▶ brachioradial pruritus
- ▶ cervical disc herniation
- ▶ surgical fusion
- ▶ ACDF
- ▶ traumatic herniation

Introduction

Brachioradial pruritus (BRP) is a neuropathic itch over the brachioradialis muscle of the dorsolateral forearms.¹ BRP results from damage along the afferent sensory pathway, typically due to ultraviolet sunlight exposure or spinal conditions that cause nerve compression, such as herniated discs or osteoarthritis.^{1–4} Binder published a seminal report on a case of neuropathic BRP caused by cervical disc herniation,⁵

with several groups since publishing similar case reports.^{6–8} Treatment of BRP includes ice application, physical therapy, topical corticosteroids, oral antihistamines, and antiepileptics.^{9–11} In rare cases, surgical management of BRP is considered. Here, the authors describe two cases of BRP that began after trauma which were localized to cervical disc herniations and successfully treated with anterior cervical discectomy and fusion (ACDF).

article published online
April 9, 2024

DOI <https://doi.org/10.1055/s-0043-1772760>.
ISSN 2248-9614.

© 2024. Asian Congress of Neurological Surgeons. All rights reserved.

This is an open access article published by Thieme under the terms of the Creative Commons Attribution-NonDerivative-NonCommercial-License, permitting copying and reproduction so long as the original work is given appropriate credit. Contents may not be used for commercial purposes, or adapted, remixed, transformed or built upon. (<https://creativecommons.org/licenses/by-nc-nd/4.0/>)

Thieme Medical and Scientific Publishers Pvt. Ltd., A-12, 2nd Floor, Sector 2, Noida-201301 UP, India

Case History

Patient 1

A 54-year-old female was involved in a motor vehicle accident and immediately afterward reported an acute onset of left-sided lateral forearm pain, itching, and a rash. This worsened at night and with exposure to the sun. She underwent a full dermatologic evaluation with treatments including various topical creams with no significant improvement. Her dermatologist pursued further workup with a magnetic resonance imaging (MRI) of the cervical spine that demonstrated C5–6 degenerative change with foraminal stenosis worse on the left (►Fig. 1). A transforaminal cervical epidural steroid injection (ESI) was performed at that level with moderate improvement in her symptoms over 2 weeks. With a working diagnosis of BRP from disc herniation established, she subsequently underwent a C4–5 ACDF (►Fig. 2). Her symptoms improved in the early postoperative period and completely resolved at 6 weeks. At 2-year follow-up, she remains symptom free.

Patient 2

A 49-year-old female was involved in a motor vehicle collision. After that event, she described severe neck pain, burning arm pain, and severe itching associated with a rash. This involved a distribution that predominantly involved the right outer upper arm, outer forearm, into the thumb and index finger. An MRI of the cervical spine demonstrated foraminal stenosis worse at the right-sided C4–5 and C5–6 levels (►Fig. 3). She underwent conservative management of her neck pain with physical therapy and cervical ESI without significant benefit. Her dermatologist prescribed her a variety of dermatologic treatments for the severe itching without improvement as well. She subsequently underwent a C4–6 ACDF (►Fig. 4). Her preoperative

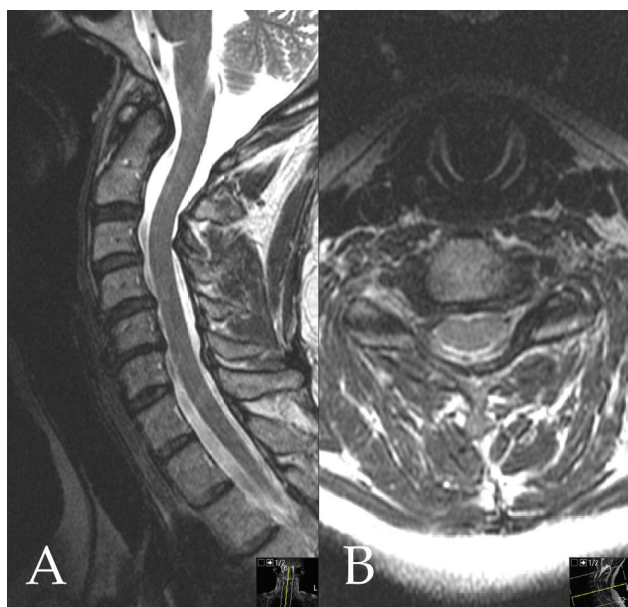


Fig. 1 (A) Sagittal and (B) axial magnetic resonance imaging of patient 1 showing disc height loss at C5–6 resulting in right greater than left foraminal stenosis.

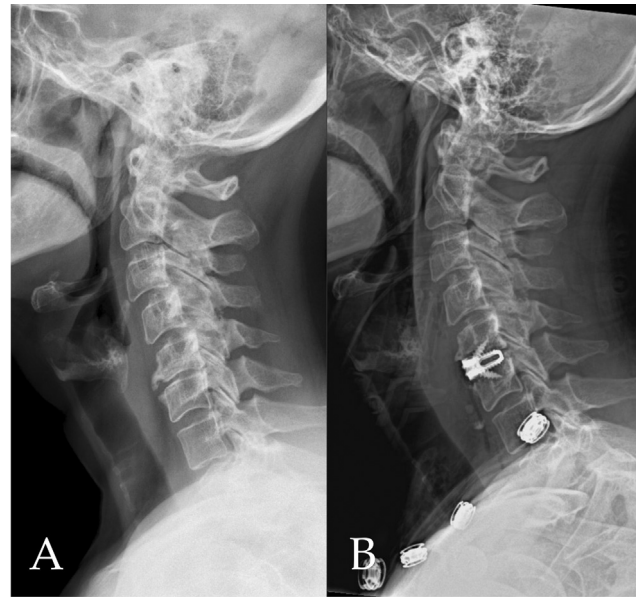


Fig. 2. (A) Preoperative and (B) postoperative X-rays of patient 1 showing the C5–6 anterior cervical discectomy and fusion.

symptoms completely resolved at 4 weeks. She remains symptom-free at 1-year follow-up.

Discussion

BRP is an uncommonly encountered clinical condition that was first described as a solar pruritis.¹² Crevits outlined four main origins of itch including pruritoceptive, neuropathic, neurogenic, and psychogenic from which BRP may receive several contributions.¹ In this report, we describe two patients who presented with BRP likely instigated by traumatic events and were found to have cervical disc herniations. Both patients recovered from BRP after treatment with ACDF. Our cases support the hypothesis that BRP may be a neurogenic manifestation of cervical nerve compression that may be treated with surgical decompression and fusion.

Indeed, a neurogenic explanation for BRP is supported by the activation of mechanoresponsive C-fibers within peripheral nerves, which are described as a part of a nonhistaminergic neuropathic circuit of itch.¹³ Clinically, this hypothesis is supported by reports of improvement in BRP after cervical nerve block and medications used to treat neuropathic pain.^{4,14} It is difficult, however, to discern whether direct mechanical compression of a cervical nerve or inflammatory irritation contributes most to BRP. A case of BRP has been described in a patient suffering simultaneously from cervical disc herniation and Parsonage–Turner syndrome, raising the question of the particular mechanism that activates neuropathic itch in BRP.⁶ However, cervical canal stenosis, foraminal stenosis, and disc protrusion or herniation remain to be the strongest clinical and anatomic correlates to BRP.

In a review of 41 patients diagnosed with BRP, 80.5% were found to have cervical nerve compression by magnetic resonance tomography, and all compression was found either at C5 or C6.⁷ Earlier reports have suggested that plain radiographs may identify cervical disease that correlate with BRP.³

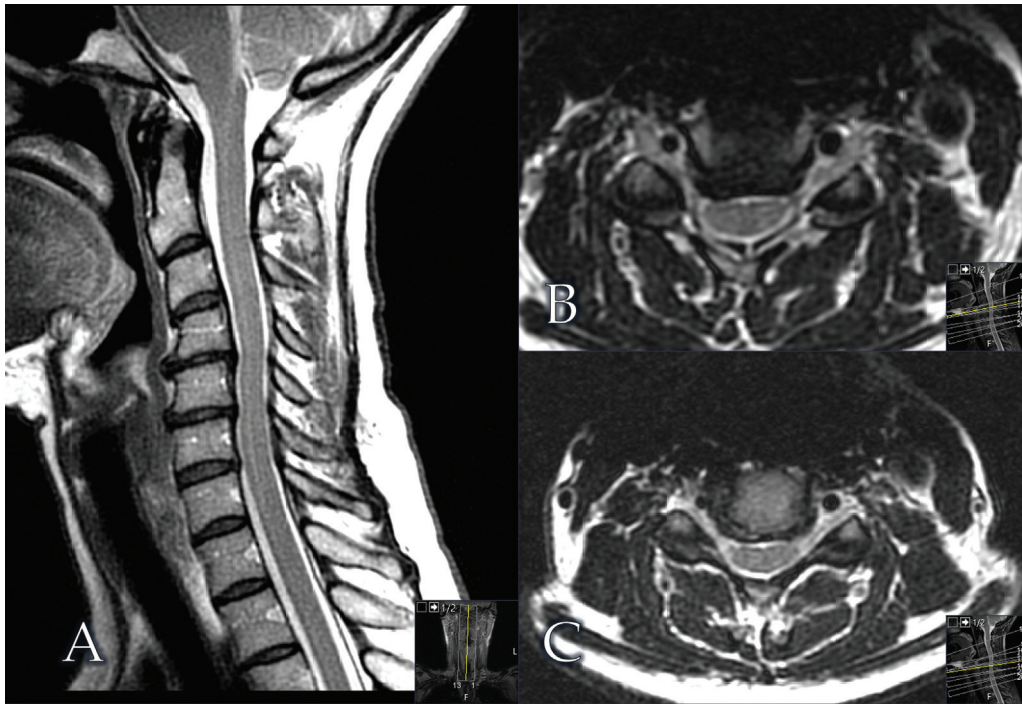


Fig. 3. Magnetic resonance imaging of patient 2. (A) Sagittal image showing disc height loss with degenerative change at C4-5 and C5-6. (B) C4-5 axial and (C) C5-6 axial imaging showing right-sided foraminal stenosis.

Cervical spine pathology as an underlying mechanism for BRP may be analogous to nostalgia paresthetica, which also presents with a dermatomal distribution of itch.¹¹ Vertebral degeneration and disc herniation are described in up to 79.1% of patients with a dermatologic diagnosis of nostalgia paresthetica.¹⁵ Interestingly, Alai and Skinner described a case of coexisting nostalgia paresthetica and BRP.¹⁶ It stands to reason that these conditions may share spinal compression as a common etiology, and may therefore benefit from treatment with surgical decompression.

Currently, there are no evidence-based guidelines to treat BRP. Conservative treatments are favored and include sun protection, ice application, and neuropathic medications.¹⁰ If symptoms are refractory, and cervical spine disease has been

demonstrated, surgical decompression may be considered. Binder et al treated a patient with BRP using microdiscectomy, laminectomy, and instrumented fusion.⁵ In this report, we demonstrate that ACDF in two patients with BRP led to complete resolution of their symptoms. We advocate that patients with refractory BRP and known cervical spine disease may be surgical candidates, and that similar to patients with degenerative conditions, ACDF is a viable option for the treatment of their pruritus. Further, refractory BRP should be treated accordingly if surgery is indicated as BRP has been shown to progress to a more generalized and debilitating itch that may extend beyond the upper extremities if left untreated.¹⁷ It is important to note, however, that long-term follow-up studies have suggested that cervical compression is unlikely to be an exclusive mechanism to BRP, and exposure to ultraviolet-light also plays an important role. As such, although BRP may be a clinical manifestation of cervical radiculopathy amenable to treatment with ACDF, multimodal approaches to symptom relief will most likely provide superior outcomes for these patients.

Conclusion

Here, we describe two cases of refractory BRP that were successfully treated with ACDF. Surgery may be a viable option to treat BRP and should be considered in patients with cervical spine disease that has not improved with conservative treatment.

Authors' Contribution

MHP was involved in conceptualization and data acquisition. MHP and NSH helped in literature search, manuscript

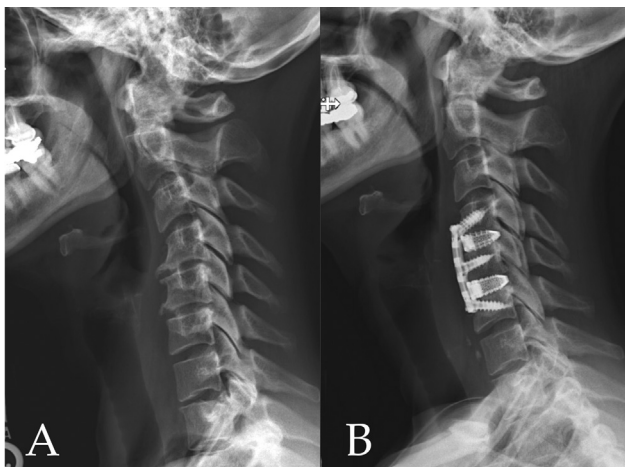


Fig. 4 (A) Preoperative and (B) postoperative X-rays of patient 2 showing the C4-6 anterior cervical discectomy and fusion.

editing and review. NSH, MHP, and JLR prepared manuscript. MHP has provided guarantee.

Funding

None.

Conflict of Interest

MHP reports consultant fees with Medtronic and Thompson Surgical.

References

- 1 Crevits L. Brachioradial pruritus—a peculiar neuropathic disorder. *Clin Neurol Neurosurg* 2006;108(08):803–805
- 2 Cohen AD, Masalha R, Medvedovsky E, Vardy DA. Brachioradial pruritus: a symptom of neuropathy. *J Am Acad Dermatol* 2003;48(06):825–828
- 3 Goodkin R, Wingard E, Bernhard JD. Brachioradial pruritus: cervical spine disease and neurogenic/neuropathic [corrected] pruritus. *J Am Acad Dermatol* 2003;48(04):521–524
- 4 Mirzoyev SA, Davis MD. Brachioradial pruritus: Mayo Clinic experience over the past decade. *Br J Dermatol* 2013;169(05):1007–1015
- 5 Binder A, Fölster-Holst R, Sahan G, et al. A case of neuropathic brachioradial pruritus caused by cervical disc herniation. *Nat Clin Pract Neurol* 2008;4(06):338–342
- 6 Carvalho S, Sanches M, Alves R, Selores M. Brachioradial pruritus in a patient with cervical disc herniation and Parsonage-Turner syndrome. *An Bras Dermatol* 2015;90(03):401–402
- 7 Marziniak M, Phan NQ, Raap U, et al. Brachioradial pruritus as a result of cervical spine pathology: the results of a magnetic resonance tomography study. *J Am Acad Dermatol* 2011;65(04):756–762
- 8 Veien NK, Laurberg G. Brachioradial pruritus: a follow-up of 76 patients. *Acta Derm Venereol* 2011;91(02):183–185
- 9 Poterucha TJ, Murphy SL, Davis MD, et al. Topical amitriptyline-ketamine for the treatment of brachioradial pruritus. *JAMA Dermatol* 2013;149(02):148–150
- 10 Yilmaz S, Ceyhan AM, Baysal Akkaya V. Brachioradial pruritus successfully treated with gabapentin. *J Dermatol* 2010;37(07):662–665
- 11 Lane JE, McKenzie JT, Spiegel J. Brachioradial pruritus: a case report and review of the literature. *Cutis* 2008;81(01):37–40
- 12 Waisman M. Solar pruritus of the elbows (brachioradial summer pruritus). *Arch Dermatol* 1968;98(05):481–485
- 13 De Ridder D, Hans G, Pals P, Menovsky T. A C-fiber-mediated neuropathic brachioradial pruritus. *J Neurosurg* 2010;113(01):118–121
- 14 Weinberg BD, Amans M, Deviren S, Berger T, Shah V. Brachioradial pruritus treated with computed tomography-guided cervical nerve root block: a case series. *JAAD Case Rep* 2018;4(07):640–644
- 15 Savk O, Savk E. Investigation of spinal pathology in nostalgia paresthetica. *J Am Acad Dermatol* 2005;52(06):1085–1087
- 16 Alai NN, Skinner HB. Concurrent nostalgia paresthetica and brachioradial pruritus associated with cervical degenerative disc disease. *Cutis* 2018;102(03):185, 186, 189, 190
- 17 Kwatra SG, Stander S, Bernhard JD, Weisshaar E, Yosipovitch G. Brachioradial pruritus: a trigger for generalization of itch. *J Am Acad Dermatol* 2013;68(05):870–873