



New-onset anosmia and taste distortion: see beyond COVID-19

Sara Casciato¹ · Sergio Paolini¹ · Giancarlo Di Gennaro¹

Received: 19 August 2020 / Accepted: 10 October 2020 / Published online: 14 October 2020
© Fondazione Società Italiana di Neurologia 2020

Dear Editor,

We have read carefully the very interesting article titled “The neurological manifestations of Covid-19: a review article” by Niazkar et al. [1], recently published on your Journal. The Authors reviewed neurological signs and symptoms due to SARS-CoV 2 infection categorized in central nervous system (CNS) and peripheral nervous system (PNS) associated ones. Anosmia and ageusia are the most common PNS manifestation of COVID-19 occurring suddenly and usually with fewer nasal symptoms, such as nasal obstruction or excessive nasal secretion. Recently, Patel et al. [2] investigated the prevalence of anosmia and ageusia in 141 adult patients with a laboratory-confirmed diagnosis of infection with severe acute respiratory distress syndrome coronavirus-2 (SARS-CoV-2). They found that more than half of positive patients reported anosmia and ageusia, thus suggesting that they should be added to the case definition and used to guide self-isolation protocols. Mild community-treated patients were more likely to report anosmia than those admitted to hospital. This evidence supports emerging data associating new-onset anosmia with mild or absent other COVID-19 symptoms [3].

Anosmia can result from many underlying diseases. The most common causes are sinonasal diseases and postinfectious and post-traumatic disorders. Other etiologies (e.g., congenital, idiopathic, toxic disorders, or disorders caused by a neurodegenerative disease) are less common but nonetheless important to rule out [4]. Unfortunately, the COVID-19 pandemic deeply impacted on the management of acute and chronic neurological conditions. Non-urgent surgical procedures, medical appointments, and diagnostic tests

have been cancelled to increase bed capacity and care for patients with the infection [5].

In the dramatic context of the COVID-19 outbreak in Italy, a 44-year-old female has been referred us for new-onset anosmia and taste distortion (“I badly distinguish flavors, the food had little taste”), associated to headache not responsive to common analgesic, gradually developed in a couple of weeks. During a previous consultation, as the symptoms were not accompanied by fever or cough, it has been hypothesized that the anosmia and the taste dysfunction could have a functional origin rather than organic, probably unconsciously shaped on the peculiar COVID-19 clinical picture, heavily disseminated by the media and information organs.

Neurological examination was unremarkable with the exception of complete anosmia and mild dysgeusia. Despite the difficulties in performing diagnostic tests due to the pandemic, a brain MRI scan was obtained and showed a large, contrast-enhancing space-occupying lesion compatible with an olfactory groove meningioma (Fig. 1). The patient was promptly referred to a neurosurgeon for surgical removal of the tumor. At the scheduled hospital admission, following procedures for safety of patients and staff, the patients tested negative for SARS-COV-2 despite the presence of symptoms abovementioned. After the operation, the headache disappeared in a few days, while the sensory disturbances persisted unchanged.

The olfactory nerve is often neglected. Indeed, neurologists often do not test it during clinical examination, valuing it only in neurodegenerative diseases and in a few other conditions [4]. Whether on one hand the COVID-19 shed a new light on this “forgotten” cranial nerve, on the other hand, this pandemic “stoles the show” not only diverting attention from other diseases but even disrupting partially or completely health services, with unavoidable diagnostic and therapeutic delays. Although the patient had, in addition to anosmia, also a slight alteration in taste, shaped by one’s profession, we did not think about the possibility of a mild form of COVID-19, but of a space-occupying lesion of the anterior cranial fossa, attributing the taste disturbance to possible dysfunction of

✉ Giancarlo Di Gennaro
gdigennaro@neuromed.it

¹ IRCCS NEUROMED, Pozzilli, (IS), Italy

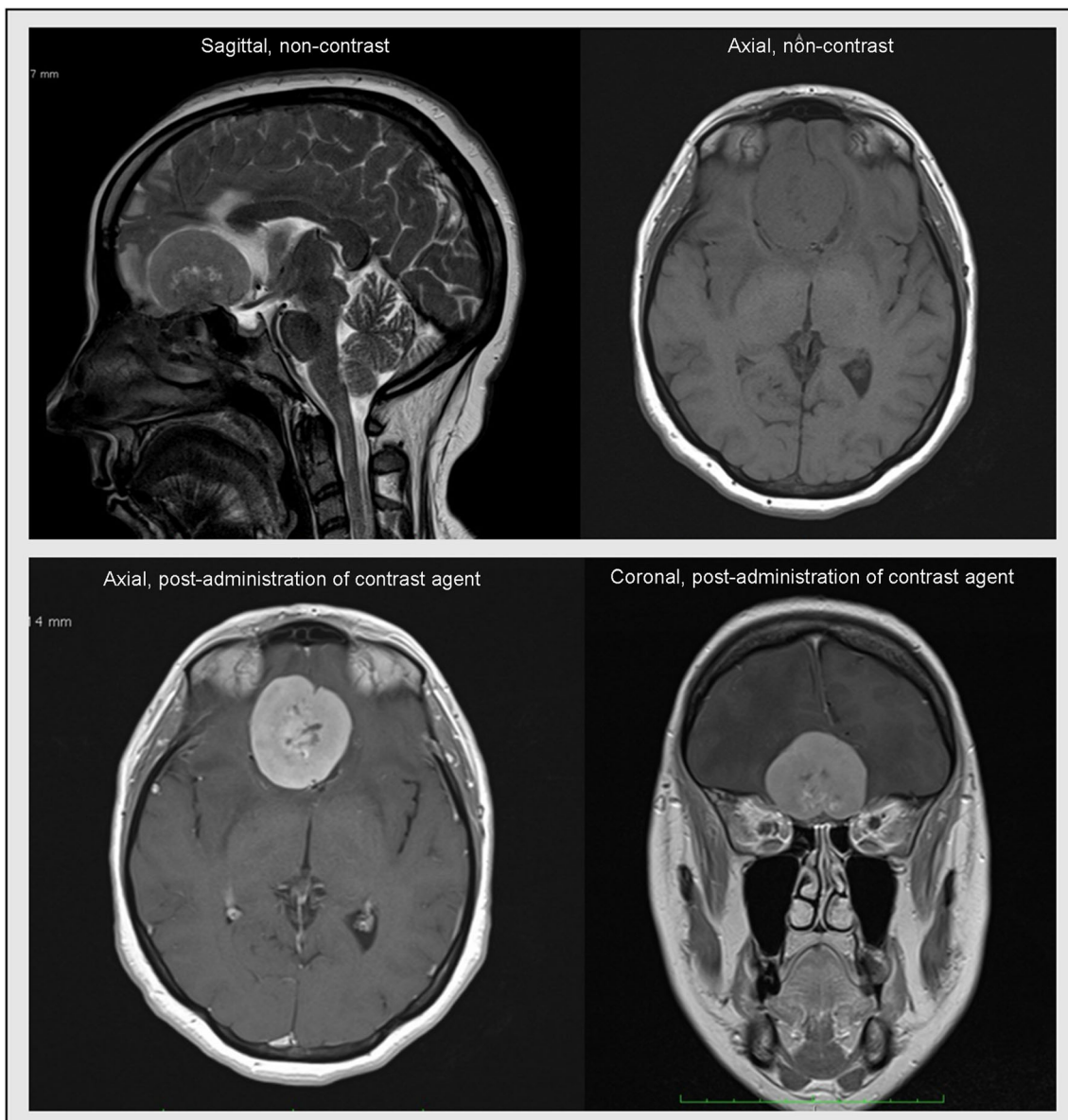


Fig. 1 T1- and T2-weighted MRI scans acquired in sagittal, axial, and coronal planes with 1.5 T show a large extra-axial, contrast-enhancing mass located in anterior cranial fossa (olfactory groove), which is compatible with meningioma

orbito- and mesio-frontal structures whose role played in odor-taste integration is well-known [6]. However, a conceptually intriguing alternative hypothesis is that this case could represent an example of “carryover effect,” negatively affecting our clinical practice. In fact, although in our opinion unlikely, we cannot rule out that the patient had a mild form of COVID-19 who led to the incidental discovery of an olfactory groove meningioma.

In conclusion, anosmia is highly prevalent in COVID-19, and it has also been identified as one of the most predictive symptoms of COVID-19. Although nowadays the attention of humanity and doctors is more

and more dramatically focused on COVID-19, we must always keep in mind, especially in this period, alternative and underestimated etiologies.

Compliance with ethical standards

Conflict of interest The authors declare that they have no conflict of interest.

Ethics approval and consent to participate The work described has been carried out in accordance with the Code of Ethics of the World Medical Association (Declaration of Helsinki). Written informed consent was obtained by the patient.

References

1. Niazkari HR, Zibaei B, Nasimi A et al (2020) The neurological manifestations of COVID-19: a review article. *Neurol Sci* 41: 1667–1671. <https://doi.org/10.1007/s10072-020-04486-3>
2. Patel A, Charani E, Ariyanayagam D et al (2020) New-onset anosmia and ageusia in adult patients diagnosed with SARS-CoV-2 infection [published online ahead of print, 2020 Jun 2]. *Clin Microbiol Infect* 26(9):1236–1241. <https://doi.org/10.1016/j.cmi.2020.05.026>
3. Xydakis MS, Dehgani-Mobaraki P, Holbrook EH, et al (2020) Smell and taste dysfunction in patients with COVID-19 [published online ahead of print, 2020 Apr 15]. *Lancet Infect Dis* S1473-3099(20): 30293-0. [https://doi.org/10.1016/S1473-3099\(20\)30293-0](https://doi.org/10.1016/S1473-3099(20)30293-0)
4. Boesveldt S, Postma EM, Boak D et al (2017) Anosmia—a clinical review [published correction appears in *Chem Senses*. 2017 Sep 1;42(7):607]. *Chem Senses* 42(7):513–523. <https://doi.org/10.1093/chemse/bjx025>
5. The Lancet Neurology (2020) The neurological impact of COVID-19. *Lancet Neurol* 19(6):471. [https://doi.org/10.1016/S1474-4422\(20\)30142-3](https://doi.org/10.1016/S1474-4422(20)30142-3)
6. Small DM, Prescott J (2005) Odor/taste integration and the perception of flavor. *Exp Brain Res* 166:345–357. <https://doi.org/10.1007/s00221-005-2376-9>

Publisher's note Springer Nature remains neutral with regard to jurisdictional claims in published maps and institutional affiliations.