

Open to Debate – Referee

Conservative Treatment of Upper Urinary Tract Urothelial Carcinoma: Referee

Elisabeth Grobet-Jeandin^{a,b}, Ugo Pinar^b, Morgan Rouprêt^{b,*}

^a Division of Urology, Geneva University Hospitals, Geneva, Switzerland; ^b GRC 5 Predictive Onco-Urology, Sorbonne University, APHP, Pitié-Salpêtrière Hôpital, Paris, France

Article info

Article history:

Accepted August 5, 2021

Associate Editor:

Jochen Walz

Upper tract urothelial cell carcinoma (UTUC) is an uncommon disease accounting for 5–10% of urothelial cancers [1]. The incidence of UTUC seems to have been rising in the past decade, with a mean age at diagnosis of 73 yr [2]. Family cases account for 10–20% of all UTUCs and are related to hereditary nonpolyposis colorectal cancer spectrum disease [2]. UTUC diagnosis relies on a combination of imaging, endoscopy, and pathologic analysis. Computed tomography is recommended for staging and urethrocytoscopy is necessary to rule out concomitant bladder cancer [3]. Ureterorenoscopy (URS) exploration with biopsy accurately predicts tumor stage, even in small-volume samples [4], but is not sufficient to define the tumor stage and to guide clinical decisions [3]. Unlike bladder tumors, it is difficult to accurately stage UTUC tumors preoperatively because of the suboptimal sensitivity of imaging and the technical limits in obtaining muscularis tissue in biopsy samples [5]. Radical nephroureterectomy (RNU) with excision of the ipsilateral bladder cuff has long been considered the gold-standard treatment for all UTUCs [6] except for imperative cases (single anatomic or functional kidney) and unfit patients.

The surgical armamentarium for conservative treatment of UTUC has recently widened with the development of laser use in URS, allowing extension of the indications. The aim of conservative treatment is to use a nephron-sparing strategy associated with lower morbidity while maintaining the oncologic outcomes obtained after RNU [7]. However, UTUC prognosis depends on the pathologic stage, with 5-yr survival dropping from 68.9% for T1–2 tumors to 28.7% for T3–4 tumors [8]. Therefore, kidney-sparing treatment (KST) must be considered in the context of a risk-stratified strategy that depends on patient and tumor characteristics [5].

Since accurate preoperative staging of UTUC is difficult, a risk stratification has been proposed and distinguishes two tumor groups: low-risk and high-risk disease (Fig. 1) [3]. According to the European Association of Urology (EAU) guidelines, the gold standard for high-risk disease is RNU, while KST can be offered as the primary treatment for low-risk disease [3]. In fact, similar survival rates after KST versus RNU have been observed for low-grade and noninvasive UTUC when using URS or percutaneous ablation of tumor [7]. Furthermore, segmentary ureterectomy (SU) offers a safe alternative to RNU in selected patients with high-grade and invasive UTUC [7]. The EAU guidelines therefore suggest considering KST for all nonmetastatic low-risk UTUCs and selected cases of high-risk UTUC (eg, SU for tumors limited to the distal ureter) with the aim of reducing morbidity while maintaining similar oncologic outcomes [3]. From an economic point of view, cost analysis data for UTUC patients demonstrate a three- to tenfold cost saving with nephron-sparing treat-

DOIs of original articles: <http://dx.doi.org/10.1016/j.euro.2021.08.001>, <http://dx.doi.org/10.1016/j.euro.2021.08.003>.

* Corresponding author. GRC 5 Predictive Onco-Urology, Sorbonne University, APHP, Pitié-Salpêtrière Hôpital, F-75013 Paris, France. Tel.: +33 1 42177297.

E-mail address: morgan.roupret@aphp.fr (M. Rouprêt).

<http://dx.doi.org/10.1016/j.euro.2021.08.002>

2666-1683/© 2021 The Author(s). Published by Elsevier B.V. on behalf of European Association of Urology. This is an open access article under the CC BY-NC-ND license (<http://creativecommons.org/licenses/by-nc-nd/4.0/>).



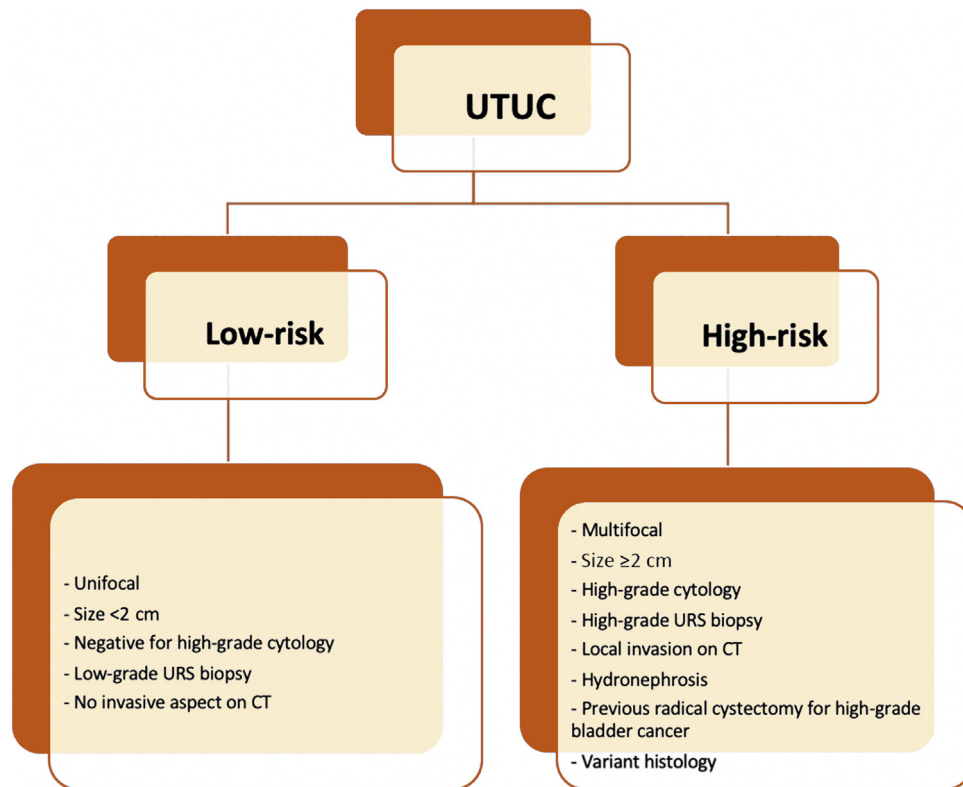


Fig. 1 – Risk stratification of nonmetastatic UTUC according to the EAU guidelines. UTUC=upper tract urothelial carcinoma; URS=ureteroscopy; CT=computed tomography.

ment compared to RNU over a 10-yr period [9]. This difference can probably be attributed to patient comorbidities, multiple episodes of care, and complications associated with radical nephrectomy [10], such as end-stage renal disease, chronic kidney disease, and secondary cardiovascular disease.

Endoscopic, cytologic, and radiologic follow-up is mandatory after RNU to detect metachronous bladder tumors [3], since studies showed a 5-yr intravesical recurrence-free rate of 41.5% after surgery [11]. Conservative management of UTUC requires even more meticulous and stringent follow-up given the need for additional endoscopic monitoring of the upper urinary tract [12]. Therefore, KST should be offered to compliant patients to prevent at best local recurrence and progression. The cost-effectiveness of KST may be questioned given the potential costs associated with iterative endoscopic controls and the need for further salvage RNU in cases of local recurrence. The aim was to expose the therapeutic dilemma in the UTUC management outlining the advantages and disadvantages of KST.

In light of the views expressed, we can conclude that RNU is no longer the gold-standard treatment for all nonmetastatic UTUC tumors. Technologic advances have made possible the development of new KST strategies on the one hand, and also the optimization of perioperative management by RNU on the other hand. The choice of treatment must rely on a risk-based strategy that distinguishes low-risk and high-risk tumors. With the aims of avoiding morbidity, overtreatment, and being cost-efficient,

KST must be considered for all low-risk tumors since it seems to be oncologically safe compared to RNU. RNU remains the gold-standard treatment for high-risk UTUC, except for very selected cases of distal ureteral tumors, for which SU can be proposed. Further efforts must be made to achieve more accurate preoperative staging and thus better selection of patients who are candidates for KST. As for many other cancer types, molecular classifications of UTUC are emerging. Four molecular subtypes with distinct clinical behaviors have been identified [13], but their clinical use is not clear yet and further studies are needed to validate them. In all cases, the choice for KST must be made as part of shared decision-making with the patient because of the mandatory meticulous and close follow-up.

Conflicts of interest: The authors have nothing to disclose.

References

- [1] Siegel RL, Miller KD, Fuchs HE, Jemal A. Cancer statistics, 2021. *CA Cancer J Clin* 2021;71:7–33. <http://dx.doi.org/10.3322/caac.21654>.
- [2] Soria F, Shariat SF, Lerner SP, et al. Epidemiology, diagnosis, preoperative evaluation and prognostic assessment of upper-tract urothelial carcinoma (UTUC). *World J Urol* 2017;35:379–87. <http://dx.doi.org/10.1007/s00345-016-1928-x>.
- [3] Rouprêt M, Babjuk M, Burger M, et al. European Association of Urology guidelines on upper urinary tract urothelial carcinoma: 2020 update. *Eur Urol* 2021;79:62–79. <http://dx.doi.org/10.1016/j.eururo.2020.05.042>.

- [4] Rojas CP, Castle SM, Llanos CA, et al. Low biopsy volume in ureteroscopy does not affect tumor biopsy grading in upper tract urothelial carcinoma. *Urol Oncol* 2013;31:1696–700. <http://dx.doi.org/10.1016/j.urolonc.2012.05.010>.
- [5] Rouprêt M, Colin P, Yates DR. A new proposal to risk stratify urothelial carcinomas of the upper urinary tract (UTUCs) in a predefinitive treatment setting: low-risk versus high-risk UTUCs. *Eur Urol* 2014;66:181–3. <http://dx.doi.org/10.1016/j.eururo.2013.12.007>.
- [6] Margulis V, Shariat SF, Matin SF, et al. Outcomes of radical nephroureterectomy: a series from the Upper Tract Urothelial Carcinoma Collaboration. *Cancer* 2009;115:1224–33. <http://dx.doi.org/10.1002/cncr.24135>.
- [7] Seisen T, Peyronnet B, Dominguez-Escrig JL, et al. Oncologic outcomes of kidney-sparing surgery versus radical nephroureterectomy for upper tract urothelial carcinoma: a systematic review by the EAU Non-muscle Invasive Bladder Cancer Guidelines Panel. *Eur Urol* 2016;70:1052–68. <http://dx.doi.org/10.1016/j.eururo.2016.07.014>.
- [8] Lughezzani G, Jeldres C, Isbarn H, et al. Nephroureterectomy and segmental ureterectomy in the treatment of invasive upper tract urothelial carcinoma: a population-based study of 2299 patients. *Eur J Cancer* 2009;45:3291–7. <http://dx.doi.org/10.1016/j.ejca.2009.06.016>.
- [9] Fiuk JV, Schwartz BF. Upper tract urothelial carcinoma: paradigm shift towards nephron sparing management. *World J Nephrol* 2016;5:158–65. <http://dx.doi.org/10.5527/wjn.v5.i2.158>.
- [10] Thacker K, Raman JD, McLean T, Said J, Oliver L, Gore JL. Understanding the economic burden of treating low-grade upper tract urothelial cancer in the United States. *Urol Pract* 2021;8:1–7. <http://dx.doi.org/10.1097/UPJ.000000000000161>.
- [11] Shigeta K, Kikuchi E, Hagiwara M, et al. The conditional survival with time of intravesical recurrence of upper tract urothelial carcinoma. *J Urol* 2017;198:1278–85. <http://dx.doi.org/10.1016/j.juro.2017.06.073>.
- [12] Seisen T, Colin P, Rouprêt M. Risk-adapted strategy for the kidney-sparing management of upper tract tumours. *Nat Rev Urol* 2015;12:155–66. <http://dx.doi.org/10.1038/nrurol.2015.24>.
- [13] Moss TJ, Qi Y, Xi L, et al. Comprehensive genomic characterization of upper tract urothelial carcinoma. *Eur Urol* 2017;72:641–9. <http://dx.doi.org/10.1016/j.eururo.2017.05.048>.