

A novel *PCDH19* missense mutation, c.812G>A (p.Gly271Asp), identified using whole-exome sequencing in a Chinese family with epilepsy female restricted mental retardation syndrome

Xuechao Zhao¹ | Yanhong Wang² | Shiyue Mei² | Xiangdong Kong¹ 

¹Genetics and Prenatal Diagnosis Center, The First Affiliated Hospital of Zhengzhou University, Henan Engineering Research Center for Gene Editing of Human Genetic Disease, Erqi District, Zhengzhou, People's Republic of China

²Henan provincial key laboratory of children's genetics and metabolic diseases, Children's Hospital Affiliated to Zhengzhou University, Zhengzhou Children's Hospital, Zhengzhou, Zhengzhou, China

Correspondence

Xiangdong Kong, Genetics and Prenatal Diagnosis Center, The First Affiliated Hospital of Zhengzhou University, Henan Engineering Research Center for Gene Editing of Human Genetic Disease, Jianshe Rd, Erqi District, Zhengzhou, Henan 450052, People's Republic of China.
Email: kxd1968@163.com

Funding information

This work was supported by the National Natural Science Foundation of China [grant number 81701125].

Abstract

Background: Epilepsy limited to females with mental retardation (EFMR) is a rare type of epilepsy with an X-linked mode of inheritance, which affect heterozygous females while the males are not affected. Mutations within the protocadherin 19 (*PCDH19*) gene have been identified as the direct cause of EFMR. The phenotype of EFMR is characterized by seizure onset in infancy with or without cognitive impairment, intellectual disturbances, and autistic features.

Methods: Whole-exome sequencing (WES) was performed in the proband to identify the underlying genetic mutations. The candidate genes were confirmed by Sanger sequencing following PCR amplification. In silico analyses were conducted to predict the effect of the novel missense mutation on the function of *PCDH19* protein.

Results: We identified three female patients in a family with a novel missense mutation in *PCDH19*, c.812G>A (p. (Gly271Asp)). The patients III-1 and III-2 presented with more severe clinical phenotypes and an earlier age of onset (6 and 11 months, respectively), intellectual disability, and movement disorders. By contrast, patient II-4 has a later age of onset (23 months), and there was no relapse of seizures without antiepileptic treatment after the age of six. In silico analyses showed that p. (Gly271Asp) in the *PCDH19* affects a highly conserved residue.

Conclusions: Our results indicated that patients with the same *PCDH19* mutation in a family may show intrafamilial phenotypic variability. Givening the mother of the proband was 18 weeks pregnant and intends to have a prenatal diagnosis, the more reasonable and less harmful strategies for prenatal diagnosis could be chosen based on the results of noninvasive prenatal testing and genetic testing.

KEYWORDS

epilepsy, missense mutation, *PCDH19* gene, prenatal diagnosis

1 | INTRODUCTION

Epilepsy and mental retardation limited to females (EFMR; MIM300088) is a disorder with an X-linked mode of inheritance and an unusual sex-limited expression pattern. Different from the classic X-linked pattern characterized by affected males and unaffected carrier females, the females affected by EFMR are connected through unaffected males. In 1971, Juberg and Hellman first reported the EFMR pattern, with main clinical features including an early infantile onset of seizures with or without cognitive impairment, intellectual disturbances, and resistance to antiepileptic drugs (Juberg & Hellman, 1971; Smith et al., 2018; Yang et al., 2019). Patients often display fever-related seizures which typically cluster, and the types are diverse, including tonic, clonic or tonic-clonic, and partial seizures (Juberg & Hellman, 1971; Marini et al., 2012).

Dibbens et al., (2008) first reported that *PCDH19* (MIM: 300088) gene mutations were associated with EFMR. The *PCDH19* gene is located at Xq22 and is composed of six exons which encode an 1148-amino-acid protein belonging to the protocadherin (PCDH) 82 subgroup within the cadherin superfamily of cell-cell adhesion molecules (Dibbens et al., 2008). *PCDH19* contains a signal sequence at its N-terminus, six extracellular cadherin (EC) repeats, a transmembrane domain, and a cytoplasmic region with conserved CM1 and CM2 domains. *PCDH* is predominantly expressed in the nervous system and may play a role in the development of neuronal connections and signal transduction at the synaptic membrane (Bassani et al., 2018; Compagnucci et al., 2015; Kurian et al., 2018; Pederick et al., 2018).

With the development of next-generation sequencing technology, the number of diagnosed cases of *PCDH19*-related epilepsy is increasing since 2008. According to the Human Gene Mutation Database (HGMD: <http://hgmd.cf.ac.uk>, 2019.4), 283 different mutations of the *PCDH19* genes have been reported, 172 of which are missense and non-sense mutations. Here, we report three female patients from a Chinese family presenting with epilepsy due to a missense mutation (G to A transversion at position 812 in exon 1) of *PCDH19*. Since the mother of the proband was pregnant for 18 weeks, our results provided important information for pre-natal genetic counseling of the family.

2 | MATERIALS AND METHODS

2.1 | Ethical compliance

The study and procedures were approved by the Research Ethics Committee of Zhengzhou University. The subjects gave informed signed consents.

2.2 | Samples and DNA extraction

Genomic DNA was extracted from EDTA peripheral blood samples using a Lab-Aid® 824 DNA Extraction Kit (ZEESAN), according to the manufacturer's protocol.

2.3 | Whole-exome sequencing

First, 1 µg of genomic DNA was fragmented to an average size of 200 bp using a Biorupter UCD-200 (Diagenode). The DNA fragments were then end-repaired, and an A was added to the 3' end. Second, the DNA fragments were connected with sequencing adaptors, and fragments of approximately 320 bp were collected using XP beads. After PCR amplification, the DNA fragments were hybridized and captured using the IDT's xGen Exome Research Panel (Integrated DNA Technologies) according to the manufacturer's protocol. The hybrid products were eluted and collected. Then the DNA was PCR amplified and purified. Next, the libraries were tested for enrichment by qPCR, and their size distribution and concentration were determined using an Agilent Bioanalyzer 2100 (Agilent Technologies). Finally, a Novaseq6000 platform (Illumina), with 150-bp paired-end reads was used for sequencing the genomic DNA of the family. Raw image files were processed using CASAVA v1.82 for base calling and generating raw data.

The sequencing reads were aligned to the human reference genome (hg19/GRCh37) using the Burrows-Wheeler Aligner tool, and PCR duplicates were removed using Picard v1.57 (<http://picard.sourceforge.net/>). The Verita Trekker® Variants Detection System by Berry Genomics and the third-party software GATK (<https://software.broadinstitute.org/gatk/>) were employed for variant calling. Variant annotation and interpretation were conducted using ANNOVAR (Wang, Li, & Hakonarson, 2010) and the Enliven® Variants Annotation Interpretation System authorized by Berry genomics. The variants were classified into the five categories—"pathogenic," "likely pathogenic," "uncertain significance," "likely benign," and "benign"—according to the American College of Medical Genetics and Genomics (ACMG) guidelines for interpretation of genetic variants (Richards et al., 2015). Variants with minor allele frequencies (MAF) <1% in exonic regions or with splicing impact were taken for deep interpretation considering ACMG category, evidence of pathogenicity and clinical synopsis, and inheritance model of the associated disease. Annotated whole-exome sequencing (WES) data were examined for variants in 100 genes selected for relevance for the epilepsy phenotypes (Lindy et al., 2018): *SCN1A*, *KCNQ2*, *CDKL5*, *SCN2A*, *PRRT2*, *PCDH19*, *STXBP1*, *SLC2A1*, *GABRG2*, *SCN8A*, *UBE3A*, *MECP2*, *GRIN2A*, *TSC2*, *FOXG1*,

GABRA1, TPP1, ZEB2, CHRNA4, ARX, TSC1, ALDH7A1, CHRNA7, TCF4, POLG, SLC9A6, SCN1B, MEF2C, SPTAN1, EPM2A, PNPO, MBD5, KCNQ3, TBC1D24, CLN5, ATP1A2, LGI1, KANSL1, GAMT, GRIN2B, CLN6, CLN3, CNTNAP2, CHRNB2, NHLRC1, KCNJ10, PNKP, PPT1, SCARB2, ADSL, MFSD8, SYN1, KCTD7, CLN8, ATP6AP2, CACNB4, CHRNA2, CSTB, CTSD, DNAJC5, EFHC1, FOLR1, GATM, GOSR2, LIAS, MAGI2, NRXN1, PRICKLE1, SLC25A22, SRPX2, HNRNPU, CACNA1A, ST3GAL2, CNTN5, CASK, NEDD4L, ARHGEF9, MAPK10, IQSEC2, GABRA6, TBC1D24, SZT2, PLCB1, CLCN2, SLC2A1, ME2, ARHGEF15, CLCN4, DNMI1, KCNH5, EEF1A2, RYR3, FASN, GABBR2, KCNB1, DOCK7, SLC13A5, CHD2, VRK2, KCNMA1. Variants identified using WES were confirmed by Sanger sequencing.

3 | RESULTS

3.1 | Case report

The proband (III-1) was a 9-year-old girl, who suffered from repetitive seizures for more than 8 years. The disease onset was at 6 months and the symptoms included predominantly generalized tonic–clonic seizures. The seizures recurred with a fever and frequently lasted for 4 to 6 days. Magnetic

TABLE 1 Clinical information of the three EFMR patients investigated in this case report

Patients features	III-1	III-2	II-4
Age at present age (years)	9	13	40
Age at seizure onset (months)	6	11	23
Type of seizures at onset	GTCS	GTCS	TS
Presence of febrile seizures	Yes	Yes	Yes
Absence	–	–	–
Cluster/repetitive	+	+	+
GTC	+	+	–
Myoclonic jerks	–	–	–
Partial	–	–	–
Status epilepticus	+	–	–
Results of head MRI	N	NP	NP
Persistence of seizures in spite of treatment	+	+	–
Intellectual disability	+	+	–
Language delay	+	+	–
Behavioral disturbances (Crying/Irritability/Outbursts)	+	+	–
Autistic features	+	+	–
Motor delay	+	+	–

Abbreviations: GTCS, generalized tonic–clonic seizures; N, normal; NP, not performed; TS, tonic seizure.

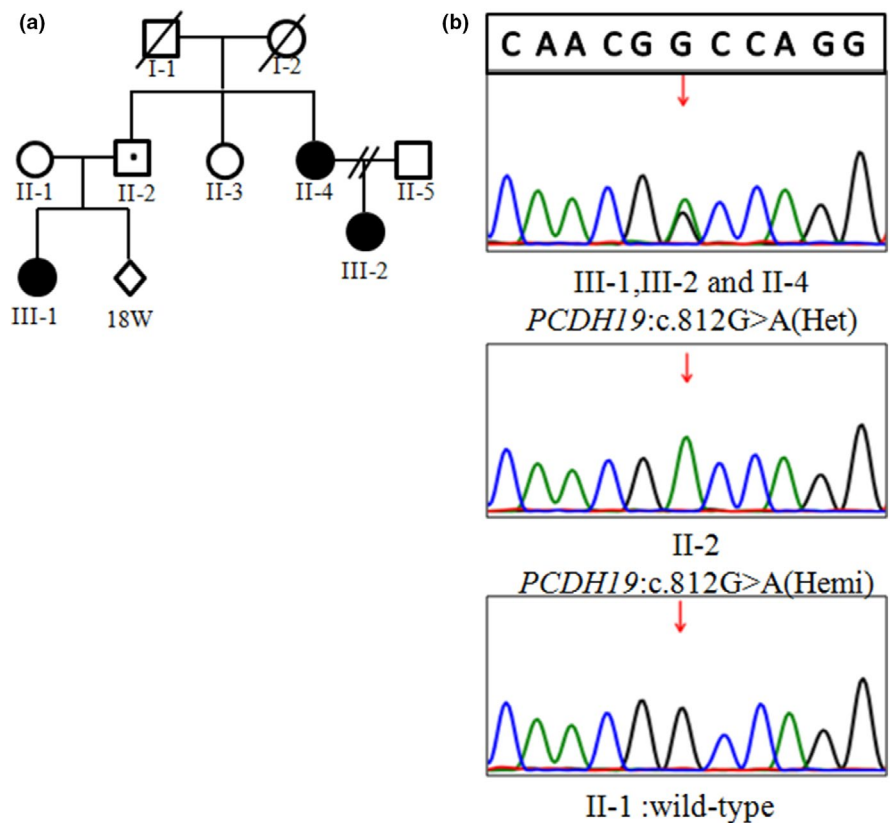


FIGURE 1 (a) Pedigree of the three-generation kindred and associated *PCDH19* c.812G>A genotypes. A solid circle denotes an affected female, an open circle denotes an unaffected female, and an open square with a small point denotes an unaffected male who is a carrier for the *PCDH19* c.812G>A mutation. (b) Electropherograms of Sanger sequencing of the *PCDH19* confirming the c.812G>A missense mutation

TABLE 2 Information of three candidate gene variants obtained after variant calling

Gene	Transcript	Mutation	Sequencing depth	Sanger sequencing	Mode of inheritance	Phenotype	Source of variation
<i>PCDH19</i>	NM_001184880.1	c.812G>A	102/61	Positive	XL	Epileptic encephalopathy, early infantile, 9 (OMIM:300088)	Father
<i>SCN1A</i>	NM_001165963	c.2378C>T	27/27	Positive	AD	Dravet syndrome(OMIM:607208)	Mother
<i>HNRNPU</i>	NM_031844	c.16_17delGT	25/33	Negative	AD	Epileptic encephalopathy, early infantile, 54(OMIM:617391)	—

Abbreviations: AD, autosomal dominant; XL, X-linked.

p.Gly271Asp

Homo_sapiens.pro	.NASDPDEGTNGQVVYSFYGYVNDR'
Bos_taurus.pro	.NATDPDEGTNGQVVYSFYGYVNDR'
Danio_rerio.pro	.NATDPDEGTNGeVVYSFinfvsnl'
Gallus_gallus.pro	.NASDPDEGTNGQVLYSFhsYVsDR.
Macaca_mulatta.pro	.NASDPDEGTNGQVVYSFYGYVNDR'
Mus_musculus.pro	.NASDPDEGTNGQVVYSFYGYVNDR'
Xenopus_tropicalis.pro	.NATDPDEGTNGeiVYSFnsYVsDk'

FIGURE 2 Alignment of the p. (Gly271Asp) mutation with *PCDH19* orthologs in different vertebrate species. Position 271 is indicated by the red box**TABLE 3** The pathogenicity of the *PCDH19*, p. (Gly271Asp) variant was supported by multiple in silico analyses

Method	Score	Prediction
PhyloP	7.892	Conserved
phastCons	1.000	Conserved
GERP++	5.95	Conserved
Polyphen-2_HDIV	1.0	Probably_damaging
Polyphen-2_HVAR	1.0	Probably_damaging
Mutation Taster	1	Disease_causing
SIFT	0.0	Damaging
PROVEAN	-5.89	Damaging

resonance imaging (MRI) was normal and the electroencephalogram (EEG) showed nonspecific slow waves. In infancy, she showed normal early developmental milestones, but later exhibited signs of intellectual disability (ID) and autism. She was inattentive, very impulsive, and prone to crying. When running or going up and down the stairs, she walked unsteadily and would frequently fall. Although she received antiepileptic treatments, including levetiracetam, sodium valproate, carbamazepine, and topiramate, the treatment effects were limited. The patient III-2 was a 13-year-old girl and her seizure onset was at 11 months. The other symptoms were similar to those of the proband III-1, such as intellectual disability (ID), autism, and resistance to antiepileptic drugs (Table 1). The patient II-4, who was the mother of proband III-2, was a 40-year-old female and her seizure onset was at 23 months. Although she didn't receive antiepileptic treatments, her seizures had disappeared after 6 years old. She showed normal intelligence and had no signs of autism.

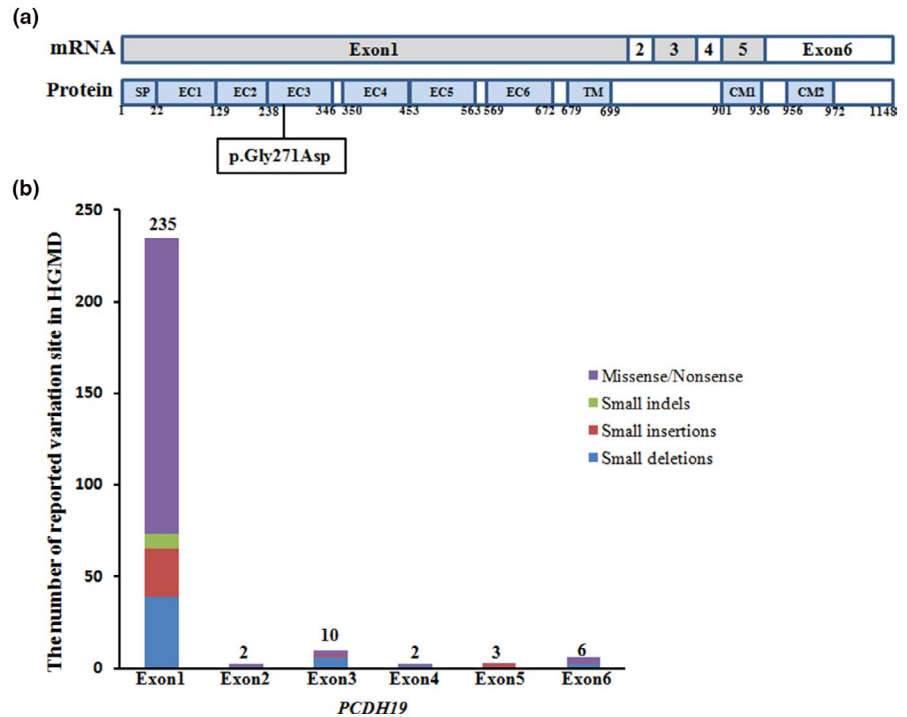
3.2 | Whole-exome sequencing revealed a novel *PCDH19* c.812G>A (p. (Gly271Asp)) missense variant

Whole-exome sequencing was performed on the proband (III-1), and variant filtering was performed as described in the methods. Two non-synonymous variants and one frameshift variant were identified in genes associated with epilepsy. One variant in the *PCDH19* (NM_001184880.1: c.812G>A) was not previously reported in variant databases including NCBI dbSNP, 1000Genomes, gnomAD, and ExAC. Two additional variants were also considered because of their low minor allele frequency (MAF < 0.1%) (*SCN1A*, c.2378C>T, NM_001165963 and *HNRNPU*, c.16_17delGT, NM_031844). Sanger sequencing confirmed the heterozygous c.812G>A variant of the *PCDH19* in the proband III-1, which was inherited from her unaffected father. The two affected female patients III-2 and II-4 in the family also carried heterozygous variation in *PCDH19* (Figure 1). The variant c.2378C>T of *SCN1A* in the proband was inherited from her unaffected mother. We did not find the c.16_17delGT variant in the *HNRNPU* by Sanger sequencing, and it was presumed to be a false positive of the WES technology (Table 2). Considering the nontypical inheritance mode of the family and the known association of *PCDH19* with EFMR, the *PCDH19* c.812G>A variant was identified as the most promising candidate.

3.3 | In silico analyses showed that the p. (Gly271Asp) variant of *PCDH19* affects a highly conserved residue

The p. (Gly271Asp) mutation is located in the cadherin functional domain and amino acid sequence alignment showed

FIGURE 3 (a) Schematic representation of the structure of the *PCDH19* mRNA and protein. Square indicate the point mutations identified in the three EFMR females. SP, signal peptide; EC, extracellular cadherin domain; TM, transmembrane domain; CM1 and CM2, cytoplasmic domains 1 and 2. The figure is adapted from Depienne et al. (2009). (b) The number of reported *PCDH19* exon 1–6 variants (small deletions, small insertions, small indels, and missense/nonsense mutations) in the HGMD



that it occurs at a highly conserved residue in *PCDH19* with surrounding amino acid residues being conserved between orthologs (Figure 2). The conservation of the Gly271 amino acid residue and pathogenicity of the p. (Gly271Asp) variant were predicted by multiple in silico analysis techniques (Table 3). The scores obtained using PhyloP (Pollard, Hubisz, Rosenbloom, & Siepel, 2010) (<http://compugen.cshl.edu/phastweb/runtool.php>), phastCons (Siepel et al., 2005), and GERP (Davydov et al., 2010) (<http://mendel.stanford.edu/sidowlab/downloads/gerp/index.html>) demonstrated that the Gly271 amino acid residue was highly evolutionarily constrained. Furthermore, the Polyphen2 (Adzhubei et al., 2010) (<http://genetics.bwh.harvard.edu/pph2/>), PROVEAN (Choi, Sims, Murphy, Miller, & Chan, 2012) (http://provean.jcvi.org/seq_submit.php), SIFT (Sim et al., 2012) (https://sift.bii.a-star.edu.sg/www/SIFT_seq_submit2.html), and MutationTaster2 (Schwarz, Cooper, Schuelke, & Seelow, 2014) (<http://www.mutationtaster.org/>) scores indicated that the functional effect of the p. (Gly271Asp) variant was damaging (Table 3).

4 | DISCUSSIONS

According to the clinical manifestations, genetic testing report, and the typical pedigree, the proband in this family was diagnosed as having EFMR resulting from a *PCDH19* c.812G>A variant. The female children with the *PCDH19* mutation showed phenotypic diversity. Most EFMR patients show epilepsy with or without mental retardation, and some share certain features with the Dravet syndrome (DS), caused

by mutations in *SCN1A*. These common features include early onset in infancy, fever sensitivity, cognitive impairment, and resistance to antiepileptic treatment (Liu et al., 2017; Trivisano et al., 2016). Additionally, a few female family members with the *PCDH19* mutation may have fever convulsions or normal phenotypes (Depienne et al., 2009; Marini et al., 2010). The age of onset of *PCDH19*-related epilepsy ranges between 1 and 70 months, with a median of 10 months (Dibbens et al., 2008; Kolc et al., 2019). In this family, the patients III-1 and III-2 displayed more severe clinical phenotypes with earlier onset age (6 and 11 months, respectively), intellectual disability, behavioral disturbances, and movement disorders (Table 1). By contrast, the onset age for patient II-4 was later (23 months), she did not have other disorders, and there was no relapse of seizures after the age of six, even without antiepileptic treatment. Thus, our results indicate that patients with the same *PCDH19* mutation may show intrafamilial phenotypic variability.

The *PCDH19* gene consists of 6 exons, whereby the first one encodes the transmembrane domain and the entire extracellular domain of the protein (Dibbens et al., 2008), which plays an important role for the normal cadherin function (Figure 3a). Reported mutations of the *PCDH19* gene are most commonly located in exon 1, and are extremely rare in exon 2–6. The Human Gene Mutation Database (HGMD: <http://hgmd.cf.ac.uk>, 2019.4), contains 283 different mutations of the *PCDH19*, including 172 missense/nonsense mutations, 48 small deletions, 30 small insertions, 8 small indels, 6 splicing mutations, 1 duplication, and 18 large fragment deletions. Among the 258 small variations (small deletions, small insertions, small indels,

and missense/nonsense mutations), 235 (91%) were located in exon 1 (Figure 3b).

In this family, we found the novel missense mutation p. (Gly271Asp) in the *PCDH19*, which was also located in exon 1 and the genotypes corresponded to the atypical phenotypes of EFMR (affected female and unaffected males). This variant can be classified as “likely pathogenic” according to guidelines determined by the American College of Medical Genetics and Genomics (PM1 + PM2 + PP3 + PP4).

The unique sex-limited expression pattern of EFMR may be explained by a “cellular interference” model (Depienne et al., 2009; Dibbens et al., 2008). The X-inactivation in females heterozygous for a *PCDH19* mutation would lead to the coexistence of two cell populations (expressing wild-type and mutated *PCDH19*), which may interfere with cell–cell interaction thus manifesting clinically as EFMR. By contrast, normal individuals and hemizygous carrier males with homogeneous cell populations would not develop the disease (Jamal, Basran, Newton, Wang, & Milunsky, 2010). This hypothesis was supported by the report that two symptomatic males carried two mosaic *PCDH19* point mutations (Terracciano et al., 2016). In this family, the father of proband III-1 was asymptomatic because of a hemizygous mutation in *PCDH19*.

Because of the atypical symptoms of EFMR, genetic testing plays an important role in the diagnosis. The mother of the proband was 18 weeks pregnant and intended to have a prenatal diagnosis. The noninvasive prenatal testing indicated that the fetus is a boy, and the X chromosome of the fetus comes from the mother, did not carry the p. (Gly271Asp) mutation in the *PCDH19* gene. Consequently, we did not recommend an interventional prenatal diagnosis for this family.

In conclusion, we identified three patients in a family with clinical presentation of EFMR having a new *PCDH19* mutation not previously described in the scientific literature. The study provides important information for genetic counseling in this family and enriches our knowledge of mutations that can cause EFMR.

ACKNOWLEDGMENTS

The authors thank the subjects and family for participating in the study.

CONFLICT OF INTERESTS

The authors report no relevant conflicts of interests related to the manuscript.

AUTHOR CONTRIBUTIONS

Xuechao Zhao and Xiangdong Kong designed the experiments. Yanhong Wang performed the experiments. Xuechao

Zhao and Shiyue Mei analyzed the data. Xuechao Zhao and Xiangdong Kong wrote the paper.

ORCID

Xiangdong Kong  <https://orcid.org/0000-0001-5685-8055>

REFERENCES

- Adzhubei, I. A., Schmidt, S., Peshkin, L., Ramensky, V. E., Gerasimova, A., Bork, P., ... Sunyaev, S. R. (2010). A method and server for predicting damaging missense mutations. *Nature Methods*, 7(4), 248–249. <https://doi.org/10.1038/nmeth0410-248>
- Bassani, S., Cwetsch, A. W., Gerosa, L., Serratto, G. M., Folci, A., Hall, I. F., ... Passafaro, M. (2018). The female epilepsy protein PCDH19 is a new GABAAR-binding partner that regulates GABAergic transmission as well as migration and morphological maturation of hippocampal neurons. *Human Molecular Genetics*, 27(6), 1027–1038. <https://doi.org/10.1093/hmg/ddy019>
- Choi, Y., Sims, G. E., Murphy, S., Miller, J. R., & Chan, A. P. (2012). Predicting the functional effect of amino acid substitutions and indels. *PLoS ONE*, 7(10), e46688. <https://doi.org/10.1371/journal.pone.0046688>
- Compagnucci, C., Petrini, S., Higurashi, N., Trivisano, M., Specchio, N., Hirose, S., ... Terracciano, A. (2015). Characterizing PCDH19 in human induced pluripotent stem cells (iPSCs) and iPSC-derived developing neurons: Emerging role of a protein involved in controlling polarity during neurogenesis. *Oncotarget*, 6(29), 26804–26813. <https://doi.org/10.18632/oncotarget.5757>
- Davydov, E. V., Goode, D. L., Sirota, M., Cooper, G. M., Sidow, A., & Batzoglou, S. (2010). Identifying a high fraction of the human genome to be under selective constraint using GERP++. *PLoS Computational Biology*, 6(12), e1001025. <https://doi.org/10.1371/journal.pcbi.1001025>
- Depienne, C., Bouteiller, D., Keren, B., Cheuret, E., Poirier, K., Trouillard, O., ... LeGuern, E. (2009). Sporadic infantile epileptic encephalopathy caused by mutations in PCDH19 resembles Dravet syndrome but mainly affects females. *PLoS Genetics*, 5(2), e1000381. <https://doi.org/10.1371/journal.pgen.1000381>
- Dibbens, L. M., Tarpey, P. S., Hynes, K., Bayly, M. A., Scheffer, I. E., Smith, R., ... Gécz, J. (2008). X-linked protocadherin 19 mutations cause female-limited epilepsy and cognitive impairment. *Nature Genetics*, 40(6), 776–781. <https://doi.org/10.1038/ng.149>
- Jamal, S. M., Basran, R. K., Newton, S., Wang, Z., & Milunsky, J. M. (2010). Novel de novo PCDH19 mutations in three unrelated females with epilepsy female restricted mental retardation syndrome. *American Journal of Medical Genetics Part A*, 152A(10), 2475–2481. <https://doi.org/10.1002/ajmg.a.33611>
- Juberg, R. C., & Hellman, C. D. (1971). A new familial form of convulsive disorder and mental retardation limited to females. *Journal of Pediatrics*, 79(5), 726–732. [https://doi.org/10.1016/s0022-3476\(71\)80382-7](https://doi.org/10.1016/s0022-3476(71)80382-7)
- Kolc, K. L., Sadleir, L. G., Scheffer, I. E., Ivancevic, A., Roberts, R., Pham, D. H., & Gécz, J. (2019). A systematic review and meta-analysis of 271 PCDH19-variant individuals identifies psychiatric comorbidities, and association of seizure onset and disease severity. *Molecular Psychiatry*, 24(2), 241–251. <https://doi.org/10.1038/s41380-018-0066-9>
- Kurian, M., Korff, C. M., Ranza, E., Bernasconi, A., Lubbig, A., Nangia, S., ... Bast, T. (2018). Focal cortical malformations in children

- with early infantile epilepsy and PCDH19 mutations: Case report. *Developmental Medicine and Child Neurology*, 60(1), 100–105. <https://doi.org/10.1111/dmcn.13595>
- Lindy, A. S., Stosser, M. B., Butler, E., Downtain-Pickersgill, C., Shanmugham, A., Retterer, K., ... McKnight, D. A. (2018). Diagnostic outcomes for genetic testing of 70 genes in 8565 patients with epilepsy and neurodevelopmental disorders. *Epilepsia*, 59(5), 1062–1071. <https://doi.org/10.1111/epi.14074>
- Liu, A., Xu, X., Yang, X., Jiang, Y., Yang, Z., Liu, X., ... Zhang, Y. (2017). The clinical spectrum of female epilepsy patients with PCDH19 mutations in a Chinese population. *Clinical Genetics*, 91(1), 54–62. <https://doi.org/10.1111/cge.12846>
- Marini, C., Darra, F., Specchio, N., Mei, D., Terracciano, A., Parmeggiani, L., ... Guerrini, R. (2012). Focal seizures with affective symptoms are a major feature of PCDH19 gene-related epilepsy. *Epilepsia*, 53(12), 2111–2119. <https://doi.org/10.1111/j.1528-1167.2012.03649.x>
- Marini, C., Mei, D., Parmeggiani, L., Norci, V., Calado, E., Ferrari, A., ... Guerrini, R. (2010). Protocadherin 19 mutations in girls with infantile-onset epilepsy. *Neurology*, 75(7), 646–653. <https://doi.org/10.1212/WNL.0b013e3181ed9e67>
- Pederick, D. T., Richards, K. L., Piltz, S. G., Kumar, R., Mincheva-Tasheva, S., Mandelstam, S. A., ... Thomas, P. Q. (2018). Abnormal cell sorting underlies the unique X-linked inheritance of PCDH19 epilepsy. *Neuron*, 97(1), 59–66.e5. <https://doi.org/10.1016/j.neuron.2017.12.005>
- Pollard, K. S., Hubisz, M. J., Rosenbloom, K. R., & Siepel, A. (2010). Detection of nonneutral substitution rates on mammalian phylogenies. *Genome Research*, 20(1), 110–121. <https://doi.org/10.1101/gr.097857.109>
- Richards, S., Aziz, N., Bale, S., Bick, D., Das, S., Gastier-Foster, J., ... Rehm, H. L. (2015). Standards and guidelines for the interpretation of sequence variants: A joint consensus recommendation of the American College of Medical Genetics and Genomics and the Association for Molecular Pathology. *Genetics in Medicine*, 17(5), 405–424. <https://doi.org/10.1038/gim.2015.30>
- Schwarz, J. M., Cooper, D. N., Schuelke, M., & Seelow, D. (2014). MutationTaster2: Mutation prediction for the deep-sequencing age. *Nature Methods*, 11(4), 361–362. <https://doi.org/10.1038/nmeth.2890>
- Siepel, A., Bejerano, G., Pedersen, J. S., Hinrichs, A. S., Hou, M., Rosenbloom, K., ... Haussler, D. (2005). Evolutionarily conserved elements in vertebrate, insect, worm, and yeast genomes. *Genome Research*, 15(8), 1034–1050. <https://doi.org/10.1101/gr.3715005>
- Sim, N. L., Kumar, P., Hu, J., Henikoff, S., Schneider, G., & Ng, P. C. (2012). SIFT web server: Predicting effects of amino acid substitutions on proteins. *Nucleic Acids Research*, 40(W1), W452–W457. <https://doi.org/10.1093/nar/gks539>
- Smith, L., Singhal, N., El Achkar, C. M., Truglio, G., Rosen Sheidley, B., Sullivan, J., & Poduri, A. (2018). PCDH19-related epilepsy is associated with a broad neurodevelopmental spectrum. *Epilepsia*, 59(3), 679–689. <https://doi.org/10.1111/epi.14003>
- Terracciano, A., Trivisano, M., Cusmai, R., De Palma, L., Fusco, L., Compagnucci, C., ... Specchio, N. (2016). PCDH19-related epilepsy in two mosaic male patients. *Epilepsia*, 57(3), e51–e55. <https://doi.org/10.1111/epi.13295>
- Trivisano, M., Pietrafusa, N., Ciommo, V. D., Cappelletti, S., Palma, L. D., Terracciano, A., ... Specchio, N. (2016). PCDH19-related epilepsy and Dravet Syndrome: Face-off between two early-onset epilepsies with fever sensitivity. *Epilepsy Research*, 125, 32–36. <https://doi.org/10.1016/j.eplepsyres.2016.05.015>
- Wang, K., Li, M., & Hakonarson, H. (2010). ANNOVAR: Functional annotation of genetic variants from high-throughput sequencing data. *Nucleic Acids Research*, 38(16), e164. <https://doi.org/10.1093/nar/gkq603>
- Yang, L., Liu, J., Su, Q., Li, Y., Yang, X., Xu, L., ... Li, B. (2019). Novel and de novo mutation of PCDH19 in girls clustering epilepsy. *Brain and Behavior*, 9(12), e01455. <https://doi.org/10.1002/brb3.1455>

How to cite this article: Zhao X, Wang Y, Mei S, Kong X. A novel *PCDH19* missense mutation, c.812G>A (p.Gly271Asp), identified using whole-exome sequencing in a Chinese family with epilepsy female restricted mental retardation syndrome. *Mol Genet Genomic Med*. 2020;8:e1234. <https://doi.org/10.1002/mgg3.1234>