

## ORIGINAL ARTICLE

# Transumbilical scarless surgery with thoracic trocar: easy and low-cost

Ibrahim Uygun, Mehmet Hanifi Okur, Bahattin Aydogdu, Mehmet Serif Arslan, Hasan Cimen, Selcuk Otcu

Department of Pediatric Surgery and Pediatric Urology, Dicle University Faculty of Medicine, Diyarbakir, Turkey

**Purpose:** Single-site laparoscopic surgery has become increasingly common. We herein report an easy and low-cost thoracic trocar technique (TTT) for these types of procedures and recommend the simpler name “transumbilical scarless surgery” (TUSS) to minimize confusion in nomenclature. **Methods:** We retrospectively reviewed patients who underwent TUSS by TTT using a thoracic trocar and surgical glove in our hospital between November 2011 and November 2012. Operating time, postoperative stay, and complications were detailed. **Results:** A total of 101 TUSS by TTT were successfully performed, comprising appendectomy (n = 63), ovarian cyst excision (n = 7), splenectomy (n = 5), nephroureterectomy (n = 5), orchidopexy (n = 4), pyeloplasty (n = 3), nephrolithotomy (n = 2), orchiectomy (n = 2), varicocelelectomy (n = 2), lymphangioma excision (n = 2), ureterectomy (n = 1), Morgagni diaphragmatic hernia repair (n = 1), ovarian detorsion (n = 1), antegrade continence enema (n = 1), intestinal resection anastomosis (n = 1), and intestinal duplication excision (n = 1). Kirschner wires were used for some organ traction. Nine patients required an additional port, but no major complications occurred. The postoperative stay (mean ± standard deviation) was  $3.2 \pm 1.4$  days, and operating time was  $58.9 \pm 38.3$  minutes. **Conclusion:** We recommend the simpler name of TUSS to minimize confusion in nomenclature for all transumbilical single-incision laparoendoscopic surgeries. TTT is an easy and low-cost TUSS technique.

**Key Words:** Minimally invasive surgical procedures, Laparoscopy, Appendectomy

## INTRODUCTION

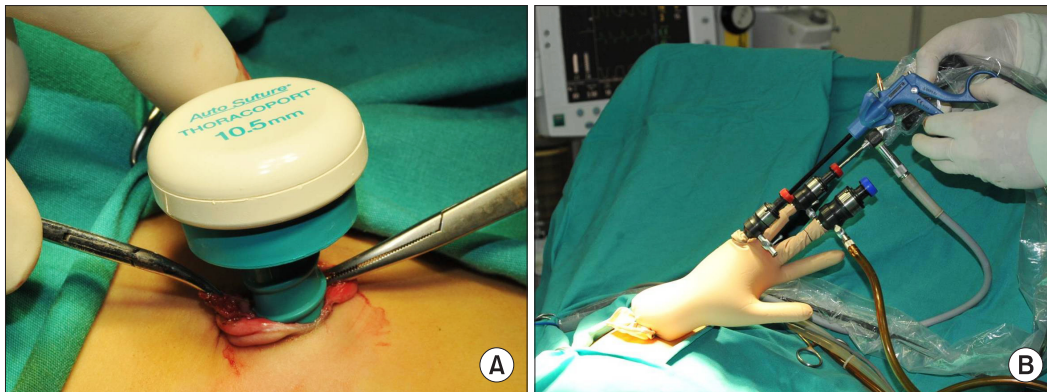
Single-site endoscopic surgical procedures have become increasingly common worldwide in the last decade following reports of one-trocar appendectomy in adults and children [1-15]. Various laparoscopic instruments and entry techniques, both privately and commercially produced, have been developed for these almost-scarless procedures [1-6,15-20]. However, they often result in addi-

tional expenses. These procedures and techniques have been given various names, such as laparoendoscopic single-site surgery, single-port access surgery, single-access site surgery, single-port thoracoscopy, single-incision laparoscopic surgery (SILS), transumbilical single-port surgery, transumbilical flexible endoscopic surgery, single-incision pediatric endosurgery, and single-port incisionless-intracorporeal conventional equipment-endoscopic surgery. [3-7,15-20]. Notably, all are based on two key ele-

Received December 21, 2012, Reviewed February 14, 2013, Accepted February 20, 2013

Correspondence to: Ibrahim Uygun  
Department of Pediatric Surgery and Pediatric Urology, Dicle University Faculty of Medicine, Diyarbakir 21280, Turkey  
Tel: +90-412-248-8514, Fax: +90-412-248-8523, E-mail: iuygun@hotmail.com

© Journal of the Korean Surgical Society is an Open Access Journal. All articles are distributed under the terms of the Creative Commons Attribution Non-Commercial License (<http://creativecommons.org/licenses/by-nc/3.0/>) which permits unrestricted non-commercial use, distribution, and reproduction in any medium, provided the original work is properly cited.



**Fig. 1.** Transumbilical scarless surgery for appendectomy by the thoracic trocar technique constructed with the standard 10.5-mm threaded thoracic trocar (A), surgical glove, and conventional instruments (B).

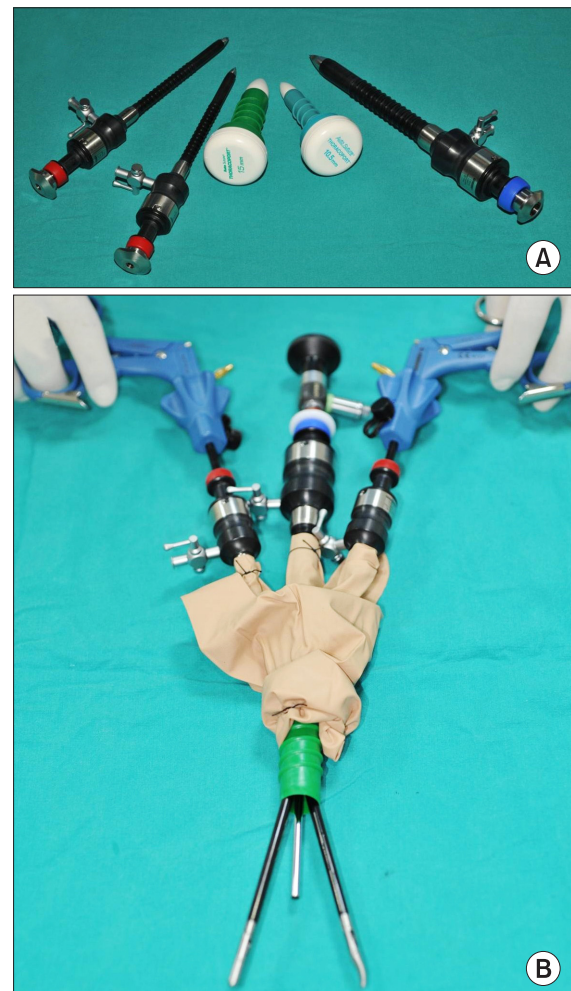
ments: they are scarless (no appreciable scar) and access is through the umbilicus, wherein the surgical scar is virtually hidden [9]. Therefore, we believe that it would be adequate and correct to simply name these procedures transumbilical scarless surgery (TUSS) to minimize confusion in nomenclature. We refer to all of these scarless surgeries as TUSS in the current study.

We herein report a single-port entry TUSS technique that is easy, and low-cost using a thoracic trocar and surgical glove.

## METHODS

In November 2011, we began performing the single-port laparoscopic appendectomies followed by other surgeries. We had soon developed a single-port entry TUSS method that is easy, unmodified, and low-cost using a thoracic trocar and surgical glove as described below, and named it the thoracic trocar technique (TTT).

The entry device was constructed with a standard 10.5-mm (for appendectomy) or 15-mm (for other TUSS) threaded thoracic trocar (Thoracoport, Covidien AG, Norwalk, CT, USA) along with a size 7 latex or nonlatex sterile surgical glove (Figs. 1, 2). Once the thoracic trocar is inserted using the standard screwing method (open cut-down technique), the cuff of the glove is snapped onto the external top and an airtight seal is created around the ports with 1-0 silk suture. Conventional reusable laparo-

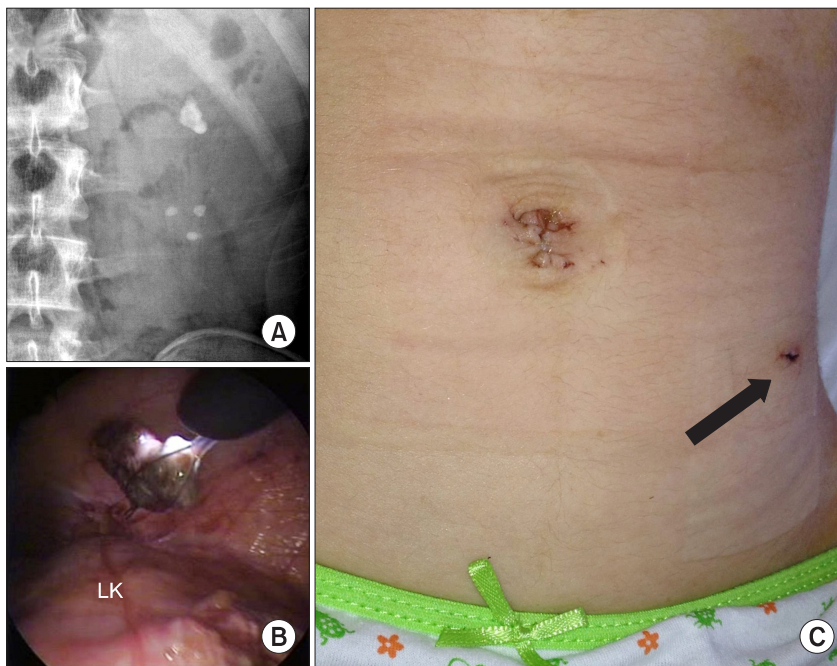


**Fig. 2.** (A) Thoracic trocars (10.5- and 15-mm) and reusable laparoscopic trocars. (B) Thoracic trocar technique for transumbilical scarless surgery requires three instruments constructed with the standard 15-mm threaded thoracic trocar.

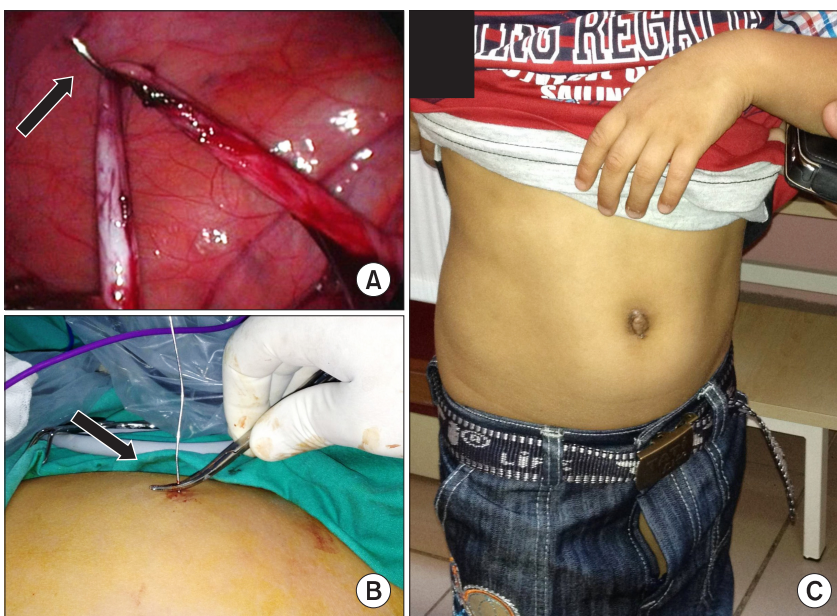scopic ports (one 10-mm and one or two 5-mm ports) are then inserted through the fingers and fixed as the top airtight seal (Figs. 1, 2). These ports provide a conduit for all instruments (e.g., graspers, vessel sealing devices, articulating device) that are exchanged during the operation for a 4-mm scope (Karl Storz GmbH, Tuttlingen, Germany). We prefer reusable instruments over disposable instru-

ments (e.g., trocars, grasper, scissors) for cost-effectiveness.

Between November 2011 and November 2012, a total of 101 patients underwent TUSS by TTT in our hospital. Patients with appendicitis were diagnosed based on the physical examination findings. Late-presenting patients with signs and symptoms of generalized peritonitis or in-



**Fig. 3.** Transumbilical scarless surgery for nephrolithotomy. (A) Four kidney stones on a plain X-ray. (B) Extraction of the larger stone using a second imaging system with a cystoscope and basket catheter (LK, left kidney). (C) After 2 days, the scar is nearly gone (arrow, second 5-mm port entry).



**Fig. 4.** Transumbilical scarless surgery for nephroureterectomy. (A) Traction of the ureter by a Kirschner wire (arrow). (B) Fixation of the wire onto the abdominal wall (arrow). (C) After 1 month, there is no scar.

testinal obstruction were treated openly. All other cases with appendicitis with or without perforation were selected for TUSS. Among patients with other surgical diseases that could be laparoscopically treated, we selected appropriate cases as feature cases to demonstrate available instruments. Operating time, postoperative stay, and complications were retrospectively reviewed.

## RESULTS

A total of 101 TUSS by TTT (59 males [58.4%] and 42 females [41.6%]; 63 appendectomies [62.4%] and 38 others surgeries [37.6%]; mean age, 8.3 years; age range, 6 months to 15 years) were performed. Surgeries other than appendectomy included ovarian cyst excision (n = 7), splenectomy (n = 5), nephroureterectomy (n = 5), orchidopexy (n = 4), pyeloplasty (n = 3), nephrolithotomy (n = 2), orchiectomy (n = 2), varicocelelectomy (n = 2), lymphangioma excision (n = 2), ureterectomy (n = 1), Morgagni diaphragmatic hernia repair (n = 1), ovarian detorsion (n = 1), antegrade continence enema (n = 1), intestinal resection anastomosis (n = 1), and intestinal duplication excision (n = 1). In all appendectomies, orchidopexies, orchiectomies, varicocelelectomies, ovarian detorsion, antegrade continence

enema, and one ovarian cyst excision, a single 10.5-mm thoracic trocar was used; in all other surgeries, a single 15-mm thoracic trocar was used for TUSS. However, nine patients (8.9%) required one additional 2.8-mm or 5-mm port. Two patients with perforated appendicitis required an additional port; in one, the port site was used for drainage tube insertion. A patient who underwent previous open nephrolithotomy and had four large kidney stones on the same side, the largest of which was 2 cm × 1 cm, required one additional port for entry into the lower pole of the hydronephrotic kidney to reach the intrarenal pelvis, and stone extraction was performed using a cystoscope with a basket catheter (Fig. 3). In one ovarian cyst excision case, one miniature 2.8-mm additional trocar was used. In all five splenectomy cases, one additional trocar was inserted to allow for the use of a vessel-sealing device. Almost all appendectomies were performed extracorporeally using previously reported methods [2,8,9]. A fine Kirschner wire ( $\leq 1$ -mm diameter) was used for traction of the organ to be removed in five appendectomy cases and all nephroureterectomy and ureterectomy cases as previously reported (Fig. 4) [21]. All pyeloplasty anastomoses were performed extracorporeally with laparoscopic assistance through the umbilicus. No major complications were encountered during or after the TUSS, although

**Table 1.** Patient characteristics and postoperative findings after TUSS (n = 101)

| Procedure                        | No. of patients | Male/female | Age (yr)   | Operating time (min) | Postoperative stay (day) |
|----------------------------------|-----------------|-------------|------------|----------------------|--------------------------|
| Appendectomy                     | 63              | 39/24       | 9 (4-15)   | 42 (10-125)          | 3.1 (1-7)                |
| Ovarian cyst excision            | 7               | 0/7         | 9 (0.5-15) | 80 (30-110)          | 3.1 (2-4)                |
| Splenectomy                      | 5               | 1/4         | 7 (5-9)    | 155 (115-210)        | 3.5 (2-5)                |
| Nephroureterectomy               | 5               | 5/0         | 7 (2-15)   | 120 (110-135)        | 4 (2-6)                  |
| Orchidopexy                      | 4               | 4/0         | 2 (1-3)    | 18 (10-35)           | 1.5 (1-2)                |
| Pyeloplasty                      | 3               | 2/1         | 1.7 (1-2)  | 63 (60-70)           | 4 (3-5)                  |
| Nephrolithotomy                  | 2               | 1/1         | 13 (12-14) | 150 (140-160)        | 7 (6-8)                  |
| Orchiectomy                      | 2               | 2/0         | 5 (1-8)    | 12 (10-15)           | 1.5 (1-2)                |
| Varicocelelectomy                | 2               | 2/0         | 13 (12-14) | 45 (30-60)           | 2 (1-3)                  |
| Lymphangioma excision            | 2               | 1/1         | 10 (6-14)  | 100 (80-120)         | 4 (3-5)                  |
| Ureterectomy                     | 1               | 1/0         | 13         | 55                   | 4                        |
| Morgagni hernia repair           | 1               | 0/1         | 4          | 125                  | 6                        |
| Ovarian detorsion                | 1               | 0/1         | 11         | 15                   | 2                        |
| Antegrade continence enema       | 1               | 1/0         | 11         | 60                   | 3                        |
| Intestinal resection anastomosis | 1               | 1/0         | 12         | 125                  | 6                        |
| Intestinal duplication excision  | 1               | 1/0         | 5          | 110                  | 6                        |

Values are presented as mean (range).  
TUSS, transumbilical scarless surgery.

three minor complications (4.8%) occurred. Two cases of minor umbilical humping without hernia were seen; one after ureterectomy and the other after appendectomy. Abdominal urine leakage was observed and treated with a double J stent in a nephrolithotomy case. Only one splenectomy patient required blood transfusion. The postoperative stay (mean  $\pm$  standard deviation) was  $3.2 \pm 1.4$  days, and operating time was  $58.9 \pm 38.3$  minutes. The features and postoperative findings of the patients after TUSS are summarized in Table 1.

## DISCUSSION

TUSS in children was first reported in 1998 by Esposito [2], who performed 25 laparoscopic appendectomies using a single trocar and operative telescope. To date, TUSS has been increasingly performed in the medical world as an option for several surgical procedures, such as appendectomy, cholecystectomy, splenectomy, nephroureterectomy, nephrolithotomy, diaphragmatic hernia repair, and ovarian cyst excision [1-16,20-23]. Development of instruments and techniques, such as articulating instruments, vessel-sealing devices, and single-site entry techniques and devices, has improved these less invasive scarless surgeries with almost increase in cost [3-7,15-20].

In Turkey, the Social Security Institution, which services governmental universal health insurance, only pays fixed all-inclusive prices (including procedure costs, disposable instruments, hospitalization, medications, and foods) to revolving funds of a university hospital for almost all surgical procedures. For example, 1,232 dollars are paid for laparoscopic splenectomy cases excluding complicated cases. Therefore, we believe that surgery costs must be reduced. We use reusable instruments and medical supplies as much as possible.

Commercial use of TUSS entry devices, such as the single-use disposable SILS Port (Covidien, Mansfield, MA, USA) and the TriPort Access System (Olympus KeyMed, Southend, UK), are expensive (approximately 300 to 600 dollars in Turkey). Thus, many privately made TUSS entry devices have been developed worldwide to reduce the cost of TUSS. Among them, the most commonly used is

the glove port [3,4,15,17-19]. In the literature, the glove port is mostly described as being made from a disposable wound retractor (ALEXIS Wound Protector/Retractor, Applied Medical, Rancho Santa Margarita, CA, USA) and surgical glove, and it has been used for all TUSS, including robotic surgery [15,17-19]. These techniques are very simple and efficient for TUSS and are low-cost as compared with other commercial devices. However, the cost of the disposable wound retractor is approximately 170 dollars, which is not low-cost as compared with commercial devices. In addition, some privately made devices have been modified from other disposable medical supplies, such as rings and the sheath of a central venous catheter guide wire, which are unacceptable for use in humans [17,18]. Our TTT procedure is nonmodified, easily applicable, and low-cost (in total, approximately 21 dollars for a single-use thoracic trocar plus surgical glove) as compared with other procedures.

Martinez-Ferro et al. [20] first used the thoracic trocar successfully in single-port thoracoscopic surgery for the treatment of pleural empyema in children. They applied two instruments (one 5-mm scope and one instrument through an 11.5-mm thoracic trocar) without additional devices, such as a glove port. In our study, we first used a thoracic trocar with a glove port in TUSS.

For appendectomy in TUSS, we used a 10.5-mm thoracic trocar with a blunt tip mandarin that was easily inserted into the abdomen through a small umbilical incision of approximately 12 mm by screwing along its threads (Fig. 1A). This trocar is slightly thinner than an 11-mm standard laparoscopic trocar (Fig. 2A). Other TUSS entry devices, such as the SILS Port (Covidien), require a  $\geq 20$  mm incision [3]. Thus, the incision is smaller than that used with other techniques. It is also secure because of its threads and can be easily inserted and removed through the incision. A larger trocar (15-mm) can be used if necessary or if an additional third instrument is required.

We prefer to routinely use 5-mm instruments and a 4- or 5-mm/ $0^\circ$  scope for appendectomy through a 10.5-mm thoracic trocar (Fig. 1). For other TUSS, we have successfully used all sizes of scopes and instruments (including vessel-sealing devices, articulating graspers) through the 15-mm thoracic trocar, as well as a 15-mm specimen bag

for splenectomy. In TTT, there is no need for a special instrument or scope. For example, there is no need for a special operative scope for appendectomy because the thoracic trocar is shorter than an 11-mm conventional trocar, and thus a 4- or 5-mm scope and one instrument can move and cross in it easily (Fig. 1) [5].

All appendectomies excluding the first four cases were excised extracorporeally as previously reported in children by Esposito [2], and more recently by Stylianos et al. [9] and Alkhoury et al. [8].

For traction of organs that will be removed, we used a fine, blunt-tip Kirschner wire as previously reported by Cuesta et al. [21] for cholecystectomy. We slung the six appendices and three ureters and could move and pull them up much further by twisting around the wire if needed (Fig. 4A, B). We did not prefer the sling or swing sutures previously described by a Turkish team because of application difficulties, inability to use in the ureter, double punctures (sling), bleeding due to the needle, inability to adequately move organs, and inability to increase organ traction [5].

TUSS for almost all endoscopic surgical procedures has been increasingly performed worldwide. We also use this technique, and in addition prefer TTT for multiport classical laparoscopic procedures to decrease the number of ports used. We are improving the learning curve for TUSS. In the current series, nine patients required additional ports. However, we believe that improving the learning curve of the surgical team and developing an instrument with technological advances will make TUSS the gold standard surgery in the future.

The nomenclature of single-site endoscopic surgical procedures is intricate, as mentioned in the introduction. However, we believe that TUSS, named by us to clarify its nomenclature and based on the two key elements of no appreciable scar and access through the umbilicus, is simple and clear. All transumbilical single-incision or single-port laparoscopic approaches, including additional scar-free entries such as that facilitated by miniature instruments (2.8 mm in diameter, ALPHADUR microinstruments; Gimmi GmbH, Tuttlingen, Germany), Kirschner wires, and sling or swing sutures, can also be called TUSS.

Cost-effectiveness is an important factor, especially

when using disposable medical supplies in surgical conditions [9]. Stylianos et al. [9] reported that an all-in-one laparoscopic appendectomy technique using a transumbilical standard port with an operative scope and reusable instruments is quick, scarless, and less costly than conventional multiport techniques. In TTT, the use of disposable medical supplies in the operating room is also much less costly (total cost: approximately 30 to 50 dollars; thoracic trocar: 20 dollars). If a reusable thoracic trocar is used, the cost further decreases. Thus, we believe that worldwide medical costs should be decreased as much as possible by decreasing invasiveness without compromising life quality and health.

In terms of the scars from TUSS, patients reported that they were excellent, as if the operation had not occurred. However, the operating time and postoperative stay were higher compared with previously reported series [5,8,9]. We believe that improving the learning curve of the surgery team will decrease all of these parameters in TUSS.

TUSS has also been increasingly used in pediatric urology, such as in pyeloplasty, nephrectomy, orchidopexy, varicocele, and nephrolithotomy, and in our pediatric urology clinic. However, our data and the data available in the literature on laparoscopic management of pediatric urological disease, especially in urolithiasis, are too limited for comparison [10,22,23].

In conclusion, we recommend the simpler name "TUSS" to minimize confusion in nomenclature for all single transumbilical entry laparoendoscopic scarless surgeries. TTT is an easy, nonmodified, and low-cost procedure that involves a thoracic trocar and surgical glove for all TUSS. However, further prospective randomized studies are needed to evaluate the use of TUSS in children in parallel with instrument developments and technologic advances.

## CONFLICTS OF INTEREST

No potential conflict of interest relevant to this article was reported.

## REFERENCES

- Pelosi MA, Pelosi MA 3rd. Laparoscopic appendectomy using a single umbilical puncture (minilaparoscopy). *J Reprod Med* 1992;37:588-94.
- Esposito C. One-trocar appendectomy in pediatric surgery. *Surg Endosc* 1998;12:177-8.
- Garey CL, Laituri CA, Ostlie DJ, St Peter SD. A review of single site minimally invasive surgery in infants and children. *Pediatr Surg Int* 2010;26:451-6.
- Canes D, Desai MM, Aron M, Haber GP, Goel RK, Stein RJ, et al. Transumbilical single-port surgery: evolution and current status. *Eur Urol* 2008;54:1020-9.
- Akgur FM, Olguner M, Hakguder G, Ates O. Appendectomy conducted with Single Port Incisionless-Intracorporeal Conventional Equipment-Endoscopic Surgery. *J Pediatr Surg* 2010;45:1061-3.
- de Armas IA, Garcia I, Pimpalwar A. Laparoscopic single port surgery in children using Triport: our early experience. *Pediatr Surg Int* 2011;27:985-9.
- Muensterer OJ, Keijzer R. Single-incision pediatric endosurgery-assisted ileocectomy for resection of a NEC stricture. *Pediatr Surg Int* 2011;27:1351-3.
- Alkhoury F, Burnweit C, Malvezzi L, Knight C, Diana J, Pasaron R, et al. A prospective study of safety and satisfaction with same-day discharge after laparoscopic appendectomy for acute appendicitis. *J Pediatr Surg* 2012;47: 313-6.
- Stylianou S, Nichols L, Ventura N, Malvezzi L, Knight C, Burnweit C. The "all-in-one" appendectomy: quick, scarless, and less costly. *J Pediatr Surg* 2011;46:2336-41.
- Park J, Kwak H, Kim SG, Lee S. Single-port laparoscopic appendectomy: comparison with conventional laparoscopic appendectomy. *J Laparoendosc Adv Surg Tech A* 2012;22:142-5.
- Bi Y, Lu L, Ruan S. Using conventional 3- and 5-mm straight instruments in laparoendoscopic single-site pyeloplasty in children. *J Laparoendosc Adv Surg Tech A* 2011;21:969-72.
- Jung GO, Park DE, Chae KM. Clinical results between single incision laparoscopic cholecystectomy and conventional 3-port laparoscopic cholecystectomy: prospective case-matched analysis in single institution. *J Korean Surg Soc* 2012;83:374-80.
- Koo EJ, Youn SH, Baek YH, Roh YH, Choi HJ, Kim YH, et al. Review of 100 cases of single port laparoscopic cholecystectomy. *J Korean Surg Soc* 2012;82:179-84.
- Kim HO, Yoo CH, Lee SR, Son BH, Park YL, Shin JH, et al. Pain after laparoscopic appendectomy: a comparison of transumbilical single-port and conventional laparoscopic surgery. *J Korean Surg Soc* 2012;82:172-8.
- Lee JS, Choi YI, Lim SH, Hong TH. Transumbilical single port laparoscopic appendectomy using basic equipment: a comparison with the three ports method. *J Korean Surg Soc* 2012;83:212-7.
- Hong TH, You YK, Lee KH. Transumbilical single-port laparoscopic cholecystectomy: scarless cholecystectomy. *Surg Endosc* 2009;23:1393-7.
- Khiangte E, Newme I, Phukan P, Medhi S. Improvised transumbilical glove port: a cost effective method for single port laparoscopic surgery. *Indian J Surg* 2011;73:142-5.
- Day W, Lau P. Novel "glove" access port for single port surgery in right hemicolectomy: a pilot study. *Surg Laparosc Endosc Percutan Tech* 2011;21:e145-7.
- Won Lee J, Arkoncel FR, Rha KH, Choi KH, Yu HS, Chae Y, et al. Urologic robot-assisted laparoendoscopic single-site surgery using a homemade single-port device: a single-center experience of 68 cases. *J Endourol* 2011;25:1481-5.
- Martinez-Ferro M, Duarte S, Laje P. Single-port thoracoscopy for the treatment of pleural empyema in children. *J Pediatr Surg* 2004;39:1194-6.
- Cuesta MA, Berends F, Veenhof AA. The "invisible cholecystectomy": a transumbilical laparoscopic operation without a scar. *Surg Endosc* 2008;22:1211-3.
- Bayazit Y, Aridogan IA, Abat D, Satar N, Doran S. Pediatric transumbilical laparoendoscopic single-site nephroureterectomy: initial report. *Urology* 2009;74:1116-9.
- Agrawal V, Bajaj J, Acharya H, Chanchalani R, Raina VK, Sharma D. Laparoscopic management of pediatric renal and ureteric stones. *J Pediatr Urol* 2013;9:230-3.