

# A case of heart failure complicated with double ventricular response triggered by beta blocker



Shingo Kazama, MD, Toru Kondo, MD, PhD, Kazumasa Suga, MD, Satoshi Yanagisawa, MD, PhD, Ryota Morimoto, MD, PhD, Takahiro Okumura, MD, PhD, Yasuya Inden, MD, PhD, Toyoaki Murohara, MD, PhD

From the Department of Cardiology, Nagoya University Graduate School of Medicine, Nagoya, Japan.

## Introduction

The double ventricular response is a rare supraventricular tachycardia that results from simultaneous antegrade conduction over the fast and slow pathways of the atrioventricular (AV) node. And certain electrophysiological conditions must be met for double ventricular response to occur. Here we report a unique case of double ventricular response triggered by beta blocker use in heart failure patients.

## Case report

A 35-year-old man with a complaint of 3-day dyspnea was admitted to a prior hospital with a diagnosis of acute heart failure. The patient was diagnosed with Graves disease 5 years previously; the condition had been well controlled with oral thiamazole (15 mg/day) and levothyroxine sodium hydrate (100 µg/day). However, a heart disease was never diagnosed, including heart failure and arrhythmia, until the

present hospitalization, with no family history of a heart disease.

Despite the treatment with inotropes and diuretics, his symptoms further deteriorated, and he was transferred to our hospital after the implantation of an intra-aortic balloon pump (IABP). Upon admission to the intensive care unit at our hospital, his blood pressure was 107/65 mm Hg, heart rate 123 beats/min, oxygen saturation 98% (nasal oxygen flow rate 2 L/min). Electrocardiography (ECG) showed sinus tachycardia with atrial premature complexes (Figure 1A), and different forms of supraventricular tachycardias frequently appeared (Figure 1B and 1C). Pulmonary congestion was observed on chest radiography. A transthoracic echocardiography revealed left ventricular ejection fraction (LVEF) of 16.7% with diffuse hypokinesis. Left ventricular end-diastolic diameter (LVDd) was dilated to 71 mm. In laboratory data, serum B-type natriuretic peptide (BNP) level was elevated to 422 pg/mL, and levels of thyroid stimulating hormone and thyroxine 4 were within normal values (2.06 µU/mL and 0.97 ng/mL, respectively).

**KEYWORDS** Acute heart failure; Arrhythmia-induced cardiomyopathy; Beta blocker; Double ventricular response; Slow pathway (Heart Rhythm Case Reports 2021;7:174–177)

**Funding Sources:** This research did not receive any specific grant from funding agencies in the public, commercial, or not-for-profit sectors. **Disclosures:** Satoshi Yanagisawa is affiliated with a department sponsored by Medtronic Japan. Takahiro Okumura has received research grants from Ono Pharmaceutical Co, Ltd, Bayer Pharmaceutical Co, Ltd, Daiichi-Sankyo Pharma Inc, and Amgen Astellas BioPharma K.K. outside the submitted work. Takahiro Okumura received honorariums from Ono Pharmaceutical Co, Ltd, Otsuka Pharmaceutical Co, Ltd, Novartis Pharma K.K., and Medtronic Japan Co, Ltd. Toyoaki Murohara received lecture fees from Bayer Pharmaceutical Co, Ltd, Daiichi-Sankyo Co, Ltd, Dainippon Sumitomo Pharma Co, Ltd, Kowa Co, Ltd, MSD K.K., Mitsubishi Tanabe Pharma Co, Nippon Boehringer Ingelheim Co, Ltd, Novartis Pharma K.K., Pfizer Japan Inc, Sanofi-Aventis K.K., and Takeda Pharmaceutical Co, Ltd. Toyoaki Murohara received unrestricted research grants for Department of Cardiology, Nagoya University Graduate School of Medicine from Astellas Pharma Inc, Daiichi-Sankyo Co, Ltd, Dainippon Sumitomo Pharma Co, Ltd, Kowa Co, Ltd, MSD K.K., Mitsubishi Tanabe Pharma Co, Nippon Boehringer Ingelheim Co, Ltd, Novartis Pharma K.K., Otsuka Pharma Ltd, Pfizer Japan Inc, Sanofi-Aventis K.K., Takeda Pharmaceutical Co, Ltd, and Teijin Pharma Ltd. The remaining authors have no conflicts of interest relevant to this article to disclose. **Address reprint requests and correspondence:** Dr Toru Kondo, Department of Cardiology, Nagoya University Hospital, 65 Tsurumai-cho, Showa-ku, Nagoya 466-8550, Japan. E-mail address: [toru.k0927@med.nagoya-u.ac.jp](mailto:toru.k0927@med.nagoya-u.ac.jp).

Inotropes (dobutamine 3 µg/kg/min, milrinone 0.13 µg/kg/min) and diuretics (furosemide 40 mg/day, tolvaptan 3.75 mg/day) were used along with the IABP. By maintaining the cardiac index (CI) around 2.5 L/min/m<sup>2</sup>, pulmonary congestion on the chest radiography was improved, and BNP level dropped to 290 pg/mL on day 3. Because supraventricular tachycardias were frequently observed, we started a beta blocker (carvedilol 1.25 mg/day) on day 4 (dobutamine 3 µg/kg/min, milrinone 0.13 µg/kg/min). Although supraventricular tachycardia disappeared, the frequent atrial premature complex-like waveform appeared with a higher heart rate (Figure 1D). This arrhythmia caused loss of synchrony with the IABP, and CI decreased sharply (1.9 L/min/m<sup>2</sup>), resulting in exacerbation of heart failure.

First, we used amiodarone (24 mg/h), but that failed to control arrhythmia and heart failure. On the ECG, 1 P wave seemed to trigger 2 QRS complexes repeatedly, suggesting a possibility of a double ventricular response (Figure 1D). Therefore, we performed an electrophysiological study (EPS) on day 5. During the EPS, a 10-pole electrode was placed at the coronary sinus, His bundle,

## KEY TEACHING POINTS

- Double ventricular response is a rare supraventricular tachycardia. It is difficult to diagnose and is often mistaken for other supraventricular arrhythmias, such as atrial premature complex or atrial fibrillation.
- Double ventricular response can be triggered by beta blocker use. The presence of double ventricular response should be considered when atrial premature complex–like arrhythmia occurs after beta blocker use.
- In cases of heart failure complicated with double ventricular response, early electrophysiological study and slow pathway ablation are recommended.

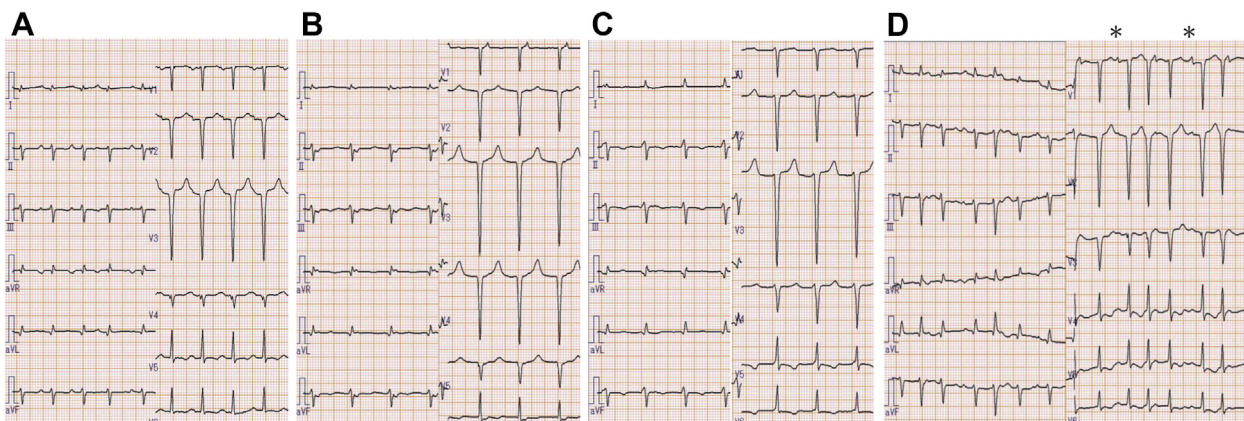
and high right atrial region, and a 4-pole electrode was placed on the right ventricular apex. By atrial S1–S2 stimulation at 600/430 ms, a single atrial stimulus produced 2 ventricular depolarizations with the preceding bundle of His deflections, and there was also retrograde conduction, of which the earliest atrial excitation site was the coronary sinus ostium (Figure 2). These findings confirmed that 1 atrial stimulus was transmitted to the ventricles via both fast and slow pathways, and also confirmed the existence of retrograde conduction through the intermediate pathway. Therefore, the patient was diagnosed with a triple AV nodal pathway and a double ventricular response. We performed radiofrequency ablation of the slow pathway with a 4-mm-tip ablation catheter (NAVISTAR THERMOCOOL, Biosense Webster Inc, Diamond Bar, CA) in a temperature-controlled mode with a target temperature of 55°C and maximum power output of 20 W. The endpoints of the ablation were the disappearance of the double ventricular response, the disappearance of the atrium–His interval jump, and the disappearance of the AV nodal echo beat.

These endpoints were achieved even under the extra or burst pacing with isoproterenol.

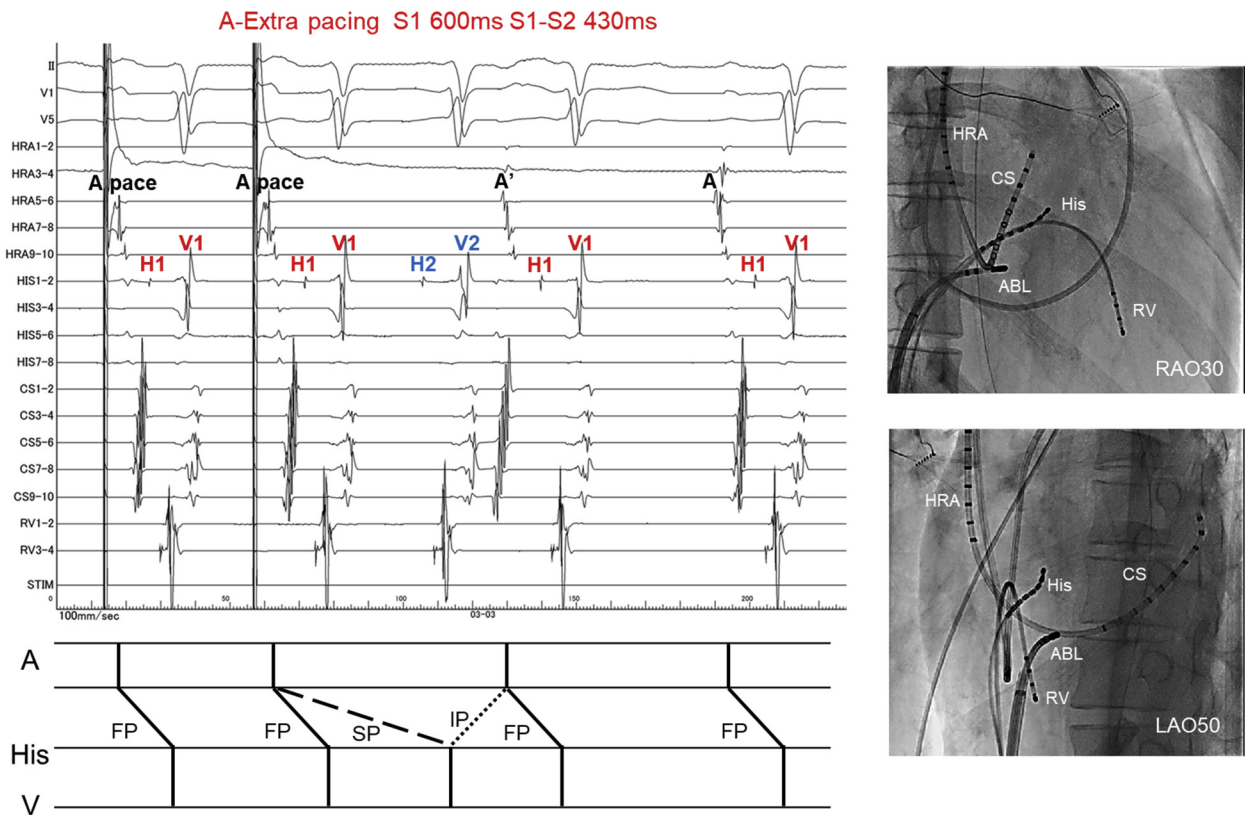
After the session, the CI recovered to 2.5 L/min/m<sup>2</sup> on the next day, and hemodynamics were steadily maintained. The IABP was removed on day 7, and the patient was discharged from the intensive care unit on day 13. Because LVEF was severely impaired, the patient was slowly weaned off inotropes and beta blocker was introduced gradually. When the dose of bisoprolol reached 1.875 mg/day on day 82, abnormal ECG findings suggestive of a double ventricular response were observed again. Although we performed EPS again on day 85, it was difficult to induce a reproducible double ventricular response during EPS despite the frequent occurrence of arrhythmias in the ward. Because the arrhythmia was clinically presumed to be double ventricular response, we performed slow pathway ablation at the same site as the first session, after which the arrhythmia disappeared in the ward. After that, the arrhythmia disappeared completely, and the patient was discharged on day 94. We prescribed bisoprolol 3.125 mg/day, enalapril 2.5 mg/day, and spironolactone 25 mg/day for heart failure with reduced ejection fraction at the time of discharge. With no recurrence of arrhythmia, we added bisoprolol gradually up to 5 mg. Six months postdischarge, the serum BNP level had normalized. On transthoracic echocardiography, we observed that LVEF improved to 46.1% and LVDd reduced to 49.1 mm.

## Discussion

Double ventricular response is a rare supraventricular tachycardia in patients with dual AV nodal pathways. Double ventricular response is difficult to diagnose and is often mistaken for other supraventricular arrhythmias, such as atrial premature complex or atrial fibrillation.<sup>1,2</sup> The following conditions are required for the presence of a double ventricular response<sup>3</sup>: (1) conduction through the slow pathway must be significantly delayed; (2) the effective refractory periods of the AV node distal common pathway and His–Purkinje system must be shorter than the difference between the conduction times of the fast and slow pathways; (3) retrograde ventriculoatrial conduction through the slow



**Figure 1** A: Electrocardiogram at admission. B,C: Supraventricular tachycardias after hospitalization. D: The electrocardiogram after introduction of beta blocker. One P wave (\*) triggers 2 QRS repeatedly, suggesting the possibility of double ventricular response.



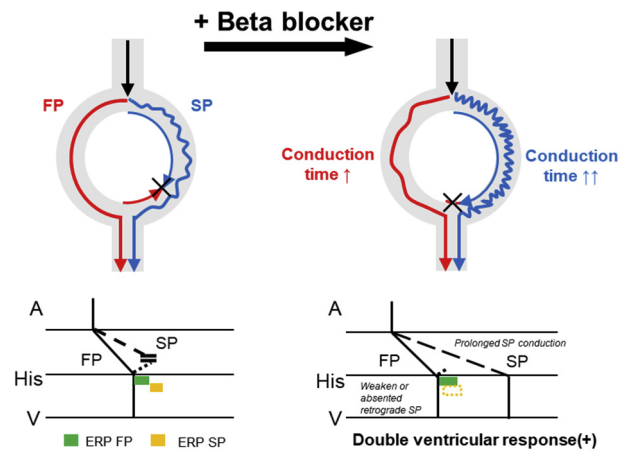
**Figure 2** The electrophysiology study finding and the fluoroscopic image during slow pathway ablation. By atrial S1–S2 stimulation at 600/430 ms, a single atrial stimulus produced 2 ventricular depolarizations with preceding His bundle deflections, and there was also retrograde conduction, of which the earliest atrial excitation site was coronary sinus ostium. ABL = ablation; CS = coronary sinus; FP = fast pathway; HRA = high right atrium; IP = intermediate pathway; RV = right ventricular; SP = slow pathway.

pathway must be poor or absent; and (4) the refractory period of the fast pathway must be relatively short. In summary, double ventricular response would occur only when the complex conditions are met by combinations of the following factors: the conduction velocities of fast and slow pathways, the refractory period of fast and slow pathways, the refractory period of the His-Purkinje system, and ventricular muscle.

In this case, double ventricular response seemed to be triggered by the initiation and increase of beta blocker, which has the effect of slowing the conduction velocity.<sup>4</sup> The reason for this can be explained by the following mechanisms: (1) retrograde conduction of the slow pathway is blocked, and antegrade conduction of the slow pathway can be transmitted to the lower conduction system; (2) the conduction of the slow pathway is relatively delayed; and (3) the His-Purkinje system can escape the refractory period before the conduction reaches it (Figure 3). Celikyurt and colleagues<sup>5</sup> reported a case of double ventricular response that developed 5 years after slow pathway ablation. In this case, it is considered that double ventricular response appeared owing to partial restoration of electrophysiological function at slow pathway. However, to the best of our knowledge, this is the first report of double ventricular response triggered by beta blocker.

We thought there was a retrograde intermediate pathway conduction that was sandwiched between the antegrade fast

pathway and the antegrade slow pathway conduction (Figure 2). The intermediate pathway might be another slow pathway, because the sequence of retrograde conduction of intermediate pathway shows that the earliest atrial excitation



**Figure 3** The mechanism of double ventricular response triggered by beta blocker. (1) Retrograde conduction of the slow pathway is blocked, and antegrade conduction of the slow pathway can be transmitted to the lower conduction system. (2) Conduction of the slow pathway is relatively delayed, and the His-Purkinje system can escape the refractory period before the conduction reaches it. ERP = effective refractory period; FP = fast pathway; SP = slow pathway.



site was the coronary sinus ostium. However, the antegrade conduction of the intermediate pathway was not proved during the first session. And the double ventricular response disappeared clinically after the second session by the slow pathway ablation at the same site as the first session. Therefore, we speculate that the slow pathway recurred, but it cannot be determined because it was difficult to induce reproducible double ventricular response during the second EPS, unfortunately.

Arrhythmia-induced cardiomyopathy is characterized by left ventricular systolic dysfunction (LVSD), which is caused by rapid and/or irregular ventricular rate.<sup>6</sup> However, the causal relationship between arrhythmia and LVSD is often difficult to determine.<sup>7</sup> In the early phase, the dilation of the left ventricle in patients with arrhythmia-induced cardiomyopathy is less pronounced than in patients with dilated cardiomyopathy. Thus, small LVDD is a key finding to suggest arrhythmia-induced cardiomyopathy.<sup>8,9</sup> However, structural remodeling progresses when arrhythmia lasts for a long period,<sup>10</sup> causing difficulty in strict discrimination of heart failure etiology. After all, the diagnosis of arrhythmia-induced cardiomyopathy is considered definitive if LVSD is fully reversible within only a few weeks or months of successful treatment for arrhythmia, such as by catheter ablation. In this case, although LVDD was severely enlarged upon admission, we believe that arrhythmia-induced cardiomyopathy contributed to the etiology of heart failure because substantial improvement of LVSD was achieved after 6 months. Also in previous reports of heart failure with double ventricular response,<sup>5,11–13</sup> LVEF was improved after slow pathway ablation in all cases, which are consistent with our report. Catheter ablation was the cornerstone for the treatment in this case because paroxysmal supraventricular tachycardia and dual response made it difficult to control heart failure despite IABP and drug treatment.

## Conclusion

Double ventricular response can exacerbate heart failure. The presence of double ventricular response should be considered

when atrial premature complex–like arrhythmia occurs after beta blocker use. EPS enables the diagnosis of double ventricular response, and slow pathway ablation is effective for the treatment of heart failure.

## Acknowledgments

The authors thank Hiroaki Hiraiwa for devoted contributions to patient care and research work.

## References

1. Li JX, Chen Q, Hu JX, et al. Double ventricular response in dual AV nodal pathways mimicking interpolated premature beat. *Herz* 2018; 43:156–160.
2. Dixit S, Callans DJ, Gerstenfeld EP, Marchlinski FE. Reentrant and nonreentrant forms of atrio-ventricular nodal tachycardia mimicking atrial fibrillation. *J Cardiovasc Electrophysiol* 2006;17:312–316.
3. Wang NC. Dual atrioventricular nodal nonreentrant tachycardia: a systematic review. *Pacing Clin Electrophysiol* 2011;34:1671–1681.
4. Philippon F, Plumb VJ, Kay GN. Differential effect of esmolol on the fast and slow AV nodal pathways in patients with AV nodal reentrant tachycardia. *J Cardiovasc Electrophysiol* 1994;5:810–817.
5. Celikyurt U, Gawaz M, Schreieck J, Seizer P. Double ventricular responses leading to reversible cardiomyopathy as late complication after slow-pathway ablation. *Case Rep Cardiol* 2015;2015:326576.
6. Huizar JF, Ellenbogen KA, Tan AY, Kaszala K. Arrhythmia-induced cardiomyopathy. *J Am Coll Cardiol* 2019;73:2328–2344.
7. Simantirakis EN, Koutalas EP, Vardas PE. Arrhythmia-induced cardiomyopathies: the riddle of the chicken and the egg still unanswered? *Europace* 2012; 14:466–473.
8. Sossalla S, Vollmann D. Arrhythmia-induced cardiomyopathy. *Dtsch Arztebl Int* 2018;115:335–341.
9. Jeong Y-H, Choi K-J, Song J-M, et al. Diagnostic approach and treatment strategy in tachycardia-induced cardiomyopathy. *Clin Cardiol* 2008;31:172–178.
10. Raymond-Paquin A, Nattel S, Wakili R, Tadros R. Mechanisms and clinical significance of arrhythmia-induced cardiomyopathy. *Can J Cardiol* 2018; 34:1449–1460.
11. Gaba D, Pavri BB, Greenspon AJ, Ho RT. Dual antegrade response tachycardia induced cardiomyopathy. *Pacing Clin Electrophysiol* 2004;27:533–536.
12. Akbarzadeh MA, Fazelifar AF, Bafraee NB. A case of dual atrioventricular nodal nonreentrant tachycardia: an unusual cause of tachycardia-induced cardiomyopathy. *J Arrhythm* 2015;31:328–330.
13. Clementy N, Casset-Senon D, Giraudeau C, Cosnay P. Tachycardiomyopathy secondary to nonreentrant atrioventricular nodal tachycardia: recovery after slow pathway ablation. *Pacing Clin Electrophysiol* 2007; 30:925–928.