

OPEN

# Splenic Artery Transposition for Liver Transplantation: An Underutilized Technique?

Matthew B. Goss, MS,<sup>1</sup> N. Thao N. Galván, MD, MPH,<sup>2</sup> Joseph D. Geha, DDS,<sup>2</sup> Nicolas F. Moreno, BS,<sup>1</sup> Ronald T. Cotton, MD,<sup>2</sup> Abbas Rana, MD,<sup>2</sup> Christine A. O'Mahony, MD,<sup>2</sup> and John A. Goss, MD<sup>2</sup>

**Background.** Successful liver transplantation is dependent on restoration of hepatic arterial (HA) flow. Although uncommon, some native recipient HAs are not suitable or inadequate for anastomosis, thereby necessitating extra-anatomic HA reconstruction. Splenic artery transposition (SAT) is 1 method of HA reconstruction, in which the recipient splenic artery is transposed to reestablish perfusion of the donor liver. Due to the rarity of the technique, literature describing outcomes is limited. In the current report, we describe 3 patients (2 adults, 1 pediatric) who underwent complex upper abdominal surgery before whole-organ deceased donor liver transplantation with SAT. **Methods.** The demographic and patient care information was collected prospectively and subsequently reviewed retrospectively. Given the de-identified nature of the data included, this study was exempt from approval from an ethics board. **Results.** Recipient splenic arteries were dissected from their origin at the celiac trunk, for approximately 3–5 cm to ensure a gentle anterior-cranial curve toward the right upper quadrant, allowing anastomosis to the donor celiac trunk in an end-to-end fashion. Postoperatively, all 3 patients had rapid normalization of liver function tests and brisk HA flow demonstrated by Doppler ultrasound. Longer-term follow-up, ranging from 1 to 3 years, reveals continued patency of the reconstructed HAs and liver function tests within normal limits. **Conclusions.** Our experience points to SAT as a safe and effective technique for extra-anatomic HA reconstruction.

(*Transplantation Direct* 2021;7: e661; doi: 10.1097/TXD.0000000000001103. Published online 26 January, 2021.)

Restoration of hepatic artery (HA) blood flow to the liver allograft is essential to achieve successful liver transplantation and avoid bile duct injury. In most cases, HA reconstruction is completed via anastomosis between the donor celiac trunk and the recipient common HA. While infrequent, the recipient HA may not be suitable for anastomosis. Beyond HA anatomic variations, occurring in ~24%

of the United States population as described by Hiatt et al,<sup>1</sup> poor HA compatibility may also derive from narrow diameter, stenosis, and injury. Moreover, transarterial chemoembolization (TACE) and the rare postoperative vascular complications of HA pseudoaneurysm<sup>2</sup> and HA thrombosis (HAT)<sup>3</sup> may necessitate measures exceeding standard HA reconstruction to preserve hepatic blood flow. Multiple techniques have been described to achieve extra-anatomic HA reconstruction, many of which utilize donor-derived arterial grafts and originate from the recipient's infra- or suprarenal aorta or right iliac artery. These techniques work well in most cases but require additional dissection around and clamping of the aorta as well as an increased number of anastomoses. Such dissections can be challenging in obese patients, especially those with a history of abdominal surgery. Aortic conduits have been correlated with an increased incidence of HAT in both adults<sup>3</sup> and children<sup>4</sup> and pseudoaneurysm,<sup>5</sup> and in rare cases, lower extremity paralysis,<sup>6</sup> although more recent literature suggests very good long-term patency<sup>7</sup> and near equivalence of suprarenal and infrarenal options.<sup>8</sup> While previously described,<sup>9</sup> literature centered on splenic artery transposition (SAT) for HA reconstruction, particularly in the realm of outcomes, remains scarce. We share our institutional experience with SAT grafts in 3 complex patients to highlight successful application and prompt dialogue as to whether the splenic artery (SA) should garner consideration as the conduit of choice for extra-anatomic HA reconstruction, particularly in the obese patient, moving forward.

Received 29 September 2020. Revision received 23 October 2020.

Accepted 3 November 2020.

<sup>1</sup> McGovern Medical School, University of Texas Health Science Center at Houston, Houston, TX.

<sup>2</sup> Michael E. DeBakey Department of Surgery, Division of Abdominal Transplantation, Baylor College of Medicine, Houston, TX.

M.B.G. wrote the article, N.T.N.G. contributed to drafting and participated in research design, J.D.G. produced figure, N.F.M. contributed to drafting, R.T.C. participated in data analysis, A.R. participated in research design, C.A.O. contributed to drafting, and J.A.G. designed research/study.

The authors declare no funding or conflicts of interest.

Correspondence: Matthew B. Goss, MS, McGovern Medical School, University of Texas Health Science Center at Houston, 6431 Fannin St, Houston, TX 77030. (matthew.b.goss@uth.tmc.edu).

Copyright © 2021 The Author(s). *Transplantation Direct*. Published by Wolters Kluwer Health, Inc. This is an open-access article distributed under the terms of the Creative Commons Attribution-Non Commercial-No Derivatives License 4.0 (CCBY-NC-ND), where it is permissible to download and share the work provided it is properly cited. The work cannot be changed in any way or used commercially without permission from the journal.

ISSN: 2373-8731

DOI: 10.1097/TXD.0000000000001103

## PATIENTS AND METHODS

Between January 2017 and June 2020, 2 adults, both with end-stage liver disease and hepatocellular carcinoma secondary to nonalcoholic steatohepatitis (1 64-y-old female and 1 55-y-old male), and a single pediatric patient with end-stage liver disease due to biliary atresia and a failed Kasai procedure (10-y-old female) underwent whole-organ deceased donor liver transplantation. Our center's pretransplant screening ubiquitously includes abdominal MRI without alteration in the context of nonalcoholic steatohepatitis or TACE(s). Intraoperatively, the patients were found to have unacceptable HA flow after initial interrupted anastomosis of the donor celiac trunk to the recipient proximal common HA. The reasons for arterial inflow inadequacy (determined via intraoperative postreperfusion ultrasound and clinical evaluation including palpation of donor HA) were HA damage by multiple TACEs, injury to the common HA during dissection, and a small aberrant HA in the child. The demographic and patient care information was collected prospectively and subsequently reviewed retrospectively. It is noteworthy that both adult patients were obese with body mass index exceeding 35 kg/m<sup>2</sup>, and all 3 patients had a history of complex upper abdominal surgery. The patient data are summarized in Tables 1 and 2. Given the de-identified nature of the data included, this study was exempt from approval from an ethics board.

## SPLenic ARTERY TRANSPOSITION TECHNIQUE

In the setting of arterial inadequacy with the proximal common HA (our center's preferred inflow source), we first rule out SA steal syndrome by dissecting proximally and placing a vascular clamp. If no improvement, we dissect proximally to evaluate the SA and celiac trunk before considering infrarenal aortic conduit. The determination between SA and celiac trunk is made based upon ease of accessibility and how the respective artery lies after anastomosis.

Our SAT technique is as follows: the gastrohepatic ligament is divided, and the recipient common HA is dissected and followed proximally. Any arterial branches encountered

are ligated/divided, and the perihepatic lymph nodes are removed to optimize exposure of the SA. Care must be taken to identify the left gastric (coronary) vein. The relationship of the left gastric vein and SA is very consistent, and the left gastric vein needs to be ligated/divided. Upon reaching the origin of the SA, the dissection is continued around the SA and onto the celiac trunk to facilitate the mobility and length of the SA. If the left gastric artery is encountered, it is ligated/divided. The SA is then dissected circumferentially for an approximate length of 4cm, and any branches encountered are ligated/divided. This length is required to create a gentle curve directed slightly cranially and toward the right upper quadrant so the HA anastomosis is neither under tension nor kinked. The celiac trunk is then clamped, the distal SA divided and oversewn, and the SA is prepared for anastomosis to the donor celiac trunk in an end-to-end manner. As shown in Figure 1, the donor celiac trunk to recipient SA anastomosis is performed in an end-to-end fashion with interrupted 7.0 PROLENE sutures.

## RESULTS

All 3 patients had immediate allograft function with a median peak aspartate aminotransferase and alanine aminotransferase of 512 U/L and 451 U/L, respectively. The 3 recipients underwent Doppler ultrasound on postoperative day 1 and demonstrated patency of the recipient SA and donor HA. All 3 patients had quick return of gastrointestinal function, tolerated a diet, and had a median length of stay of 9 days. None of the transplant recipients developed pancreatitis or suffered from splenic abscess during the early postoperative period (Tables 1 and 2). None of the patients underwent pneumococcal vaccination as splenic blood flow was maintained via the short gastric vessels from the stomach and collateral flow through the pancreas.

At a median follow-up of 523 days, all 3 recipients are alive with continued HA patency as demonstrated by Doppler ultrasound and have a median total bilirubin, aspartate aminotransferase, alanine aminotransferase, and alkaline phosphatase of 0.9 mg/dL, 22 U/L, 27 U/L, and 92 U/L, respectively.

**TABLE 1.**

### Patient information

Patient	Sex	Age	Height	Weight (lbs)	BMI	PAS	Diagnosis	Peak ALT	Current ALT	P/O day 1 U/S
1	Female	64	6 feet 1 inch	287	38	Yes	NASH/HCC	451	33	Patent
2	Female	10	4 feet 9 inches	97	21	Yes	BA	387	23	Patent
3	Male	55	5 feet 8 inches	266	40	Yes	NASH/HCC	604	27	Patent

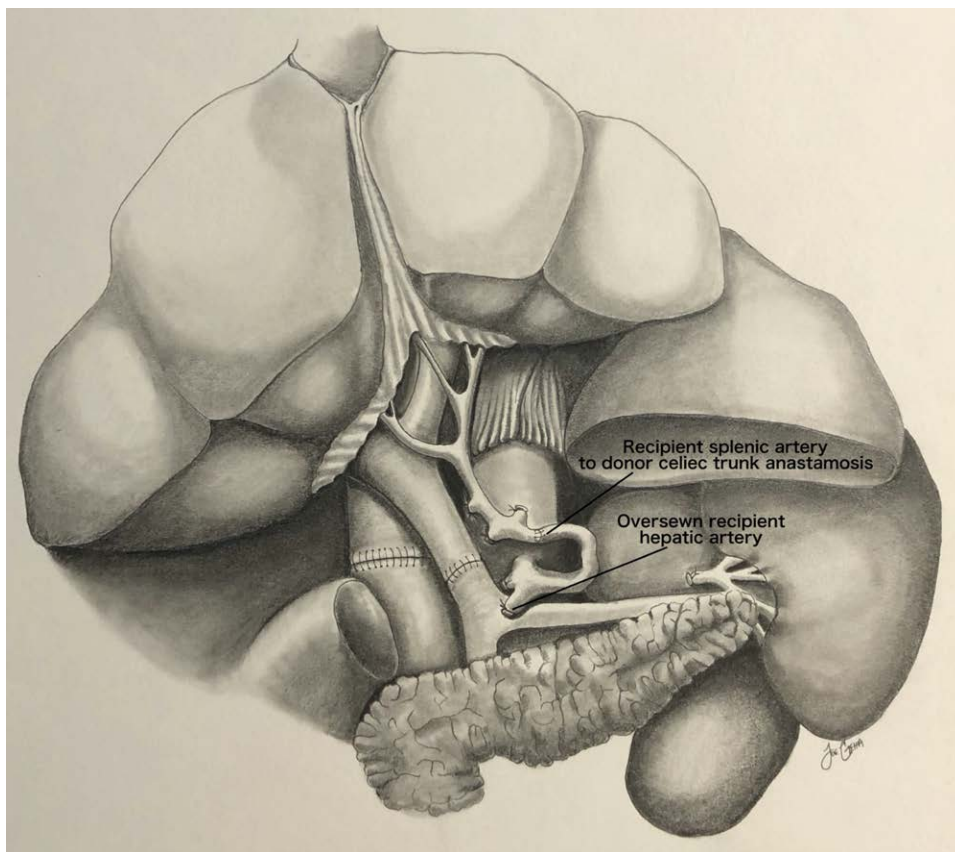
ALT, alanine aminotransferase; BA, biliary atresia; BMI, body mass index; HCC, hepatocellular carcinoma; NASH, nonalcoholic steatohepatitis; P/O, postoperative; PAS, previous abdominal surgery; U/S, ultrasound.

**TABLE 2.**

### Patient information

Patient	Current U/S	Peak lipase	Pancreatitis	Splenic abscess	LOS (d)	Outcome
1	Patent	57	No	No	7	Alive
2	Patent	127	No	No	11	Alive
3	Patent	109	No	No	9	Alive

LOS, length of stay; U/S, ultrasound.



**FIGURE 1.** Illustration depicting recipient splenic artery to donor celiac trunk in an end-to-end fashion.

## DISCUSSION

Our report demonstrates the successful application of SAT in deceased donor liver transplant for 3 patients who had inadequate HA blood flow following initial HA reconstruction. In both adult cases, the patients were obese, barrel-chested, and had multiple adhesions from previous upper abdominal surgeries. Further dissection to mobilize the bowel, dissect the supraceliac or infrarenal aorta, and place an aortic conduit would have complicated the operations and increased patient risk. In addition, in the larger patient (body mass index of 40 kg/m<sup>2</sup>), a single iliac arterial conduit did not provide enough length to reach the upper abdomen, requiring additional anastomoses to garner suitable aortic conduit length. Fortunately, in both adult patients, the SA was palpable in situ, and we felt this provided a safer and simpler option than the additional dissection necessary to expose the aorta. SAT may, in fact, be beneficial in the patient with renal insufficiency or marginal renal reserve as it avoids aortic cross-clamping when creating an aortic conduit. In both cases, the SA was of adequate size with an uncomplicated dissection along the superior aspect of the pancreas. The technical challenges of extra-anatomic HA reconstruction may often be minimized with SAT given the large size of SAs in liver transplant candidates secondary to portal hypertension and splenomegaly.<sup>10</sup> In such procedures, care must be taken to protect the pancreas and ensure that ample length is available for the completion of the HA anastomosis without tension while providing a gentle curve to the right upper quadrant. As presented in Figure 1, we performed both of the adult anastomoses in an end-to-end

fashion to avoid the previously described complication of intimal hyperplasia associated with end-to-side anastomoses.<sup>11</sup> Neither of our adult patients experienced the previously described complications of pancreatitis,<sup>11</sup> splenic infarction,<sup>12</sup> or splenic abscess.<sup>13</sup>

In our pediatric case, the patient's anatomy was unusual in that the common HA was very small and long. We initially dissected this artery and attempted to use it for HA inflow, but the flow was inadequate. We could palpate the SA along the superior aspect of the pancreas and were able to dissect it free of the pancreas after removing the perihepatic lymph nodes and ligating/dividing the left gastric vein. The artery was large and easily rotated toward the right upper quadrant to complete anastomosis to the donor celiac trunk, providing excellent arterial flow. The child had immediate bowel function, avoided an aortic anastomosis, had a short length of stay, did not develop pancreatitis or splenic infarct/abscess, and has continued to do well. Easy accessibility (relative to extra-anatomic jump grafts<sup>14</sup>) and appropriate dimensions for anastomosis make SAT an attractive technique for extra-anatomic HA reconstruction, although SAT is contraindicated if prior splenectomy or pancreatitis.

In conclusion, while acknowledging that our experience reported is limited in scope, we feel that this technique could be performed more frequently, especially in complex or obese liver transplant patients, avoiding the aortic conduit when extra-anatomic HA reconstruction would have been otherwise needed. We feel that SAT can be performed safely without undue concern for splenic or pancreatic complications as we regularly ligate/divide the recipient SA in both our adult

and pediatric liver transplant recipients. The likelihood of HAT is decreased significantly by performing HA anastomosis to the recipient very proximal common HA or even the recipient celiac trunk when feasible.

## REFERENCES

1. Hiatt JR, Gabbay J, Busuttil RW. Surgical anatomy of the hepatic arteries in 1000 cases. *Ann Surg*. 1994;220:50–52.
2. Ma L, Chen K, Lu Q, et al. Case report of hepatic artery dissection secondary to hepatic artery pseudoaneurysm after living donor liver transplantation. *BMC Gastroenterol*. 2016;16:44.
3. Tzakis AG, Gordon RD, Shaw BW Jr, et al. Clinical presentation of hepatic artery thrombosis after liver transplantation in the cyclosporine era. *Transplantation*. 1985;40:667–671.
4. Mazzaferro V, Esquivel CO, Makowka L, et al. Hepatic artery thrombosis after pediatric liver transplantation—a medical or surgical event? *Transplantation*. 1989;47:971–977.
5. Todo S, Makowka L, Tzakis AG, et al. Hepatic artery in liver transplantation. *Transplant Proc*. 1987;19(1 Pt 3):2406–2411.
6. Goss JA, Seu P, Shackleton CR, et al. Lower extremity paralysis after use of the supraceliac aorta for hepatic arterial reconstruction of the transplanted liver. *Transplantation*. 1997;63:163–164.
7. Nikitin D, Jennings LW, Khan T, et al. Twenty years of follow-up of aortohepatic conduits in liver transplantation. *Liver Transpl*. 2008;14:1486–1490.
8. Livingston D, Lee DD, Croome S, et al. Comparison of supraceliac and infrarenal aortic conduits in liver transplantation: is there a difference in patency and postoperative renal dysfunction? *Transplant Direct*. 2019;5:e499.
9. Alim A, Dayangac M, Erdogan Y, et al. Splenic artery transposition for arterial reconstruction in living donor liver transplantation. *Transplant Proc*. [Online ahead of print. June 3, 2020]. doi: 10.1016/j.transproceed.2020.02.155.
10. Bolognesi M, Merkel C, Sacerdoti D, et al. Role of spleen enlargement in cirrhosis with portal hypertension. *Dig Liver Dis*. 2002;34:144–150.
11. Vanderlan WB, Abouljoud MS, Yoshida A, et al. Experience with recipient splenic artery inflow in adult liver transplantation: a case series. *Cases J*. 2008;1:82.
12. Valentine RJ, Rossi MB, Myers SI, et al. Splenic infarction after spleno-renal arterial bypass. *J Vasc Surg*. 1993;17:602–606.
13. Balci D, Taner B, Dayangac M, et al. Splenic abscess after splenic artery ligation in living donor liver transplantation: a case report. *Transplant Proc*. 2008;40:1786–1788.
14. Kazemi K, Samidoost P, Deilami HN, et al. A new consideration in hepatic artery reconstruction in adult liver transplant: arterial transposition versus extra-anatomic jump grafts. *Exp Clin Transplant*. 2017;15(Suppl 1):204–207.