



Using Lymphovenous Anastomosis and Lymph Node to Vein Anastomosis for Treatment of Posttraumatic Chylothorax with Increased Thoracic Duct Pressure in 3-Year-Old Child

Yeongsong Kim, MD¹ Hyung B. Kim, MD¹ Changsik J. Pak, MD, PhD¹
Hyunsuk P. Suh, MD, PhD¹ Joon P. Hong, MD, PhD, MMM¹

¹Department of Plastic Surgery, Asan Medical Center, University of Ulsan, College of Medicine, Seoul, Korea

Arch Plast Surg 2022;49:549–553.

Address for correspondence Joon P. Hong, MD, PhD, MMM, Department of Plastic and Reconstructive Surgery, Asan Medical Center, University of Ulsan, College of Medicine, 88, Olympic-Ro 43-Gil, Songpa-Gu, Seoul 138-736, Korea (e-mail: joonphong@amc.seoul.kr).

Abstract

Chylothorax is a rare disease and massive lymph fluid loss can cause life-threatening condition such as severe malnutrition, weight loss, and impaired immune system. If untreated, mortality rate of chylothorax can be up to 50%. This is a case report of a 3-year-old child with iatrogenic chylothorax. Despite conservative treatment and procedures, like perm catheter insertion, the patient failed to improve the respiratory symptoms over 3 months of period. As an alternative to surgical option, such as pleurodesis and thoracic duct ligation which has high complication rate, the patient underwent lymphovenous anastomosis (LVA) and lymph node to vein anastomosis (LNVA). Follow-up at fourth month showed clear lungs without breathing difficulty despite perm catheter removal. This is the first report to show the effectiveness of LVA and LNVA against iatrogenic chylothorax.

Keywords

- ▶ iatrogenic chylothorax
- ▶ supermicrosurgery
- ▶ lymphovenous anastomosis
- ▶ lymph node to vein anastomosis

Introduction

Chylothorax is a condition collecting lymphatic fluid in the pleural space from various etiology. It usually occurs after direct injury to the thoracic duct and procedures, like central-line insertion, are rare but known to cause chylothorax.^{1,2} Fortunately, the overall incidence is rare but once occurs, it can rapidly aggravate to a life-threatening condition especially in infant and child.³

The thoracic duct and the lymphatic system carries approximately 2 to 4L of fluid per day and leakage from this system can cause nutritional deficiencies and reduction of immunoglobulins.^{3,4} The immunodeficiency caused by

hypogammaglobulinemia will make patients vulnerable to infection and may even result in septic shock.^{5–7} To prevent such mortality by chylothorax, surgical intervention such as thoracic duct ligation and pleurodesis are initiated if conservative managements fails.³

Conservative management includes a fat-free diet with medium-chain triglycerides (MCT) which will bypass the lymphatics and directly enter the portal system reducing the chyle/lymphatic flow to thoracic duct. In addition to diet modification, somatostatin/octreotide is known to reduce the chyle/lymphatic flow by decreasing splanchnic blood flow with intestinal fluid secretion.^{8,9} However, success rate of conservative treatment in traumatic chylothorax is only

DOI <https://doi.org/10.1055/s-0042-1751026>.
ISSN 2234-6163.

© 2022. The Korean Society of Plastic and Reconstructive Surgeons. All rights reserved.

This is an open access article published by Thieme under the terms of the Creative Commons Attribution-NonDerivative-NonCommercial-License, permitting copying and reproduction so long as the original work is given appropriate credit. Contents may not be used for commercial purposes, or adapted, remixed, transformed or built upon. (<https://creativecommons.org/licenses/by-nc-nd/4.0/>)

Thieme Medical Publishers, Inc., 333 Seventh Avenue, 18th Floor, New York, NY 10001, USA

approximately 33 to 49% often requiring adjunctive chest tube insertion to drainage the fluid accumulation in pleural space.^{3,4} Clinical deterioration occurs when 1,000 to 1,500 mL of chyle is drained every day for more than 2 weeks, thus requiring surgical intervention to prevent fatal condition.⁴

There is no consensus about which surgical management should be first line of treatment. Conventional surgical approach like thoracic duct ligation has high complication rate and mortality rate can be up to 25%.⁴ As an alternative approach, Kovach et al introduced thoracic duct to venule anastomosis for young patients.¹⁰ Stemming from this approach, Hayashida et al have done a lymphovenous anastomosis (LVA) for congenital chylothorax in a low birth weight infant. However, there are no report for LVA for iatrogenic chylothorax.¹¹ The authors report the first case of iatrogenic chylothorax using LVA and lymph node to vein anastomosis (LNVA) to successfully relieve the symptom and prevent further aggravation.

Case

A 3-year-old male child was born with posterior urethral valves, bilateral dysplastic kidney, and severe hydronephrosis. Immediately after bilateral nephrectomy, a permanent catheter was inserted on the left subclavian vein for hemodialysis. However, catheter malfunction was noted and catheter was changed on May of 2020. After 5 months in October, he is admitted for chest retraction, swelling of face, abdomen and both lower extremity, and was found with left pleural effusion on chest X-ray. A pigtail was inserted to drain the fluid and evaluated which was found to be chylous effusion. Further evaluation by computed tomography scan showed permanent catheter injuring the subclavian vein obstructing the drainage of the thoracic duct. The catheter was removed and magnetic resonance (MR) lymphangiogram revealed abnormally dilated lymphatics in the left lower neck, chest wall with contrast media leaking into the neck, axilla, and pulmonary interstitial space confirming chylothorax (►Fig. 1).

The drainage from the pigtail plateaued approximately 200 to 500 cc per day prior to surgery and conservative treatment with octreotide, medium chain triglycerides was initiated. Unfortunately, there was no improvement of the drainage amount despite dietary conservative care and the chest effusion on X-ray continuously aggravated (►Fig. 2). The immunoglobulin G level decreased to 223.2 from 947.6 mg/dL, and the patient went into septic condition. Fever was up to 39.9°C and blood culture result showed *Klebsiella pneumoniae* needing antibiotic treatment. The patient was referred for surgical intervention due to lack of response from conservative care.

The Rationale

Clinical deterioration continued with septic condition and poor respiratory symptom due to the obstruction of the thoracic duct leading to chyle leakage. Without drainage of fluid from the chest pigtails, the respiratory symptom will be catastrophic, and with the pigtail, the metabolic imbalance

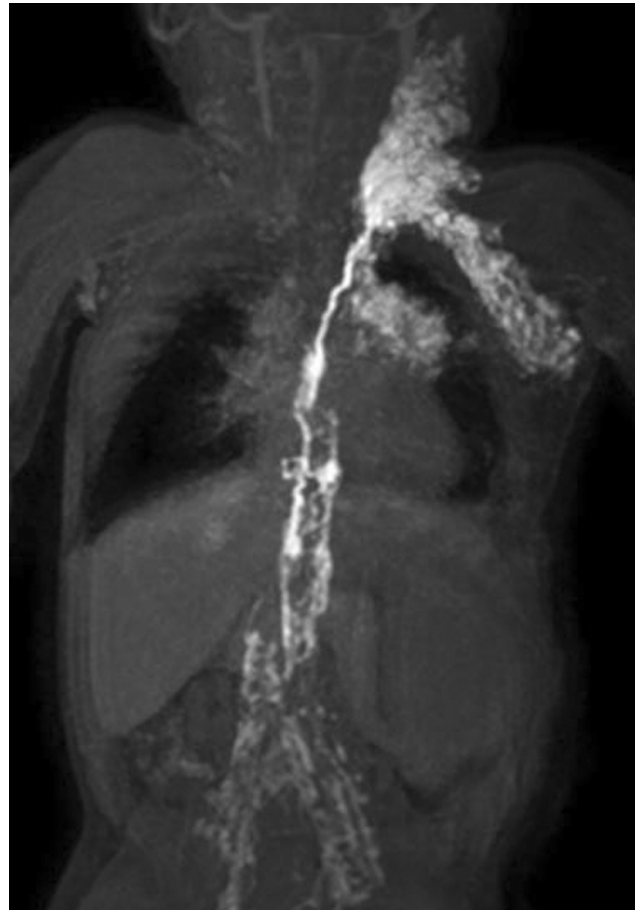


Fig. 1 MR, central lymphatics show most of lymphatic flow was drain into the left neck, axilla, pulmonary interstitial space. MR, magnetic resonance.

would be almost impossible to correct. Thus the patient was considered for surgical intervention with thoracic duct ligation or thoracic duct embolization to seal the leakage. However, the severe scarring around the duct and vein was considered to be high risk for mortality and less likely to be successful. Knowing that both extremity had swelling prior to insertion of pigtail, most likely from lymphedema caused by obstruction of lymphatic drainage, we hypothesized that inflow of lymphatic fluid to the chest can be reduced by creating a bypass between lymphatic vessels and veins. This option was considered as the best surgical approach after careful review of the patient condition.

Surgical Procedure

To find the lymphatics and the adjacent superficial vein, MR lymphangiography (MRL) and duplex ultrasonography were used preoperatively^{12,13} (►Fig. 3). During the operation, indocyanine green (ICG) and fluorescein sodium (Fluorescite, Alcon, Fort Worth, TX) dye were used to identify the functioning lymphatics located under the superficial fascia.¹⁴ The lymphatic vessel on exploration showed ecstatic diameter of 0.5 mm. The side of the lymphatic vessel was anastomosed to the end of the superficial vein using a 11–0 nylon on dorsal region of the ankle for both legs avoiding any interruption of lymphatic flow. Bilateral LNVA was also

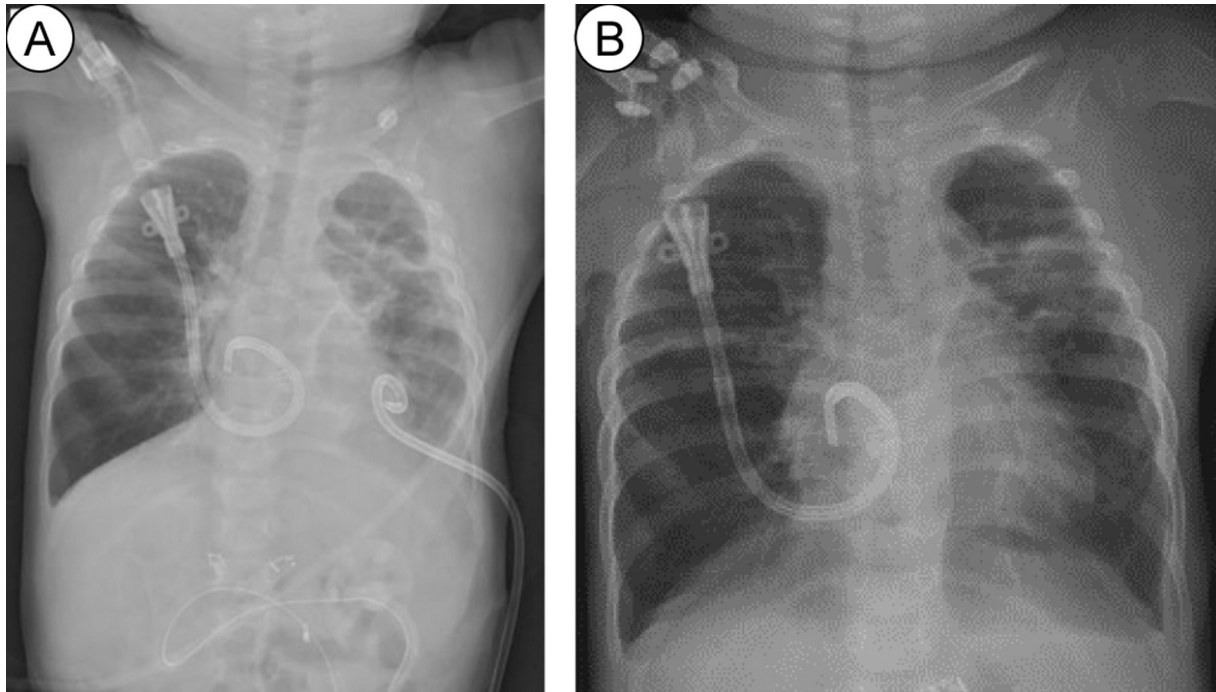


Fig. 2 After removal of permanent catheter inserted on left jugular vein, patients undergoing hemodialysis using catheter inserted directly to the right atrium. (A) For chest X-ray, day before surgery, pigtail was inserted on left-sided lung. (B) At postoperative 10 weeks, chest X-ray shows no aggravation of effusion, even after pigtail on left lung was removed.

performed after mapping draining lymph nodes from the abdomen.¹⁵ (►Fig. 4) One lymph node from each side was used to perform LNVA avoiding any interruption of flow. After anastomosis, spontaneous drainage from lymphatic vessel and lymph node to vein was noted confirming the higher pressure of lymphatics draining into the vein using the ICG under the operating microscope.^{14,15}

Postoperative Progress

The postoperative response to LVA and LNVA was determined on several factors including the amount of daily drainage from the pigtail, periodic chest X-ray, and clinical laboratory studies. The drainage reached 600 cc on day 3 and started to

gradually decrease to 205 cc on day 8, 90 cc on day 15, 30 cc on day 25, and ultimately 0 cc on postoperative day 39. The MCTs feeding was stopped at this time. The drain was removed and the symptoms of chest retraction disappeared and effusion on the chest X-ray was cleared despite the removal of the pigtail (►Fig. 2). Improvement of the immunoglobulin G level recovering up to 604 from 223.2 mg/dL was noted on postoperative day 34. Due to these improved factors, the patient was discharged on postoperative day 65 without any respiratory symptom or fever. Bandaging for the extremity was performed only during admission. On postoperative day 126, the visit the outpatient clinic maintaining chest X-ray without effusion and clear of any respiratory symptoms and reduced swelling of the face.

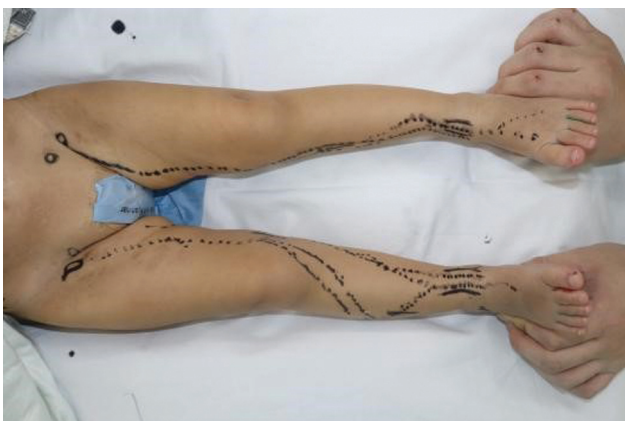

Fig. 3 Lymphatic vessel and adjacent vein tracing was performed using ICG dye and duplex ultrasound preoperatively. Side-to-end lymphovenous anastomosis performed on dorsal region of the ankle for both legs. Bilateral lymph node to vein anastomosis was performed on inguinal area. ICG, indocyanine green.

Discussion

Chylothorax can be life-threatening as loss of lymph fluid leads to malnutrition, weight loss, and impaired immune system.¹⁶ If remained untreated, mortality rate of chylothorax can be high as 50%. Therefore, early surgical approach should be initiated in refractory chylothorax.^{4,17} However surgical treatments, like thoracic duct ligation or pleurodesis, are known to have high complication rate.

The thoracic duct flow starts from the cisterna chyli in which the lymph from the lower extremity meets the chyle from the intestine. And injury to thoracic duct by iatrogenic cause can result in chyle leakage to thorax interstitium space due to the pressure gradient resulting in chylothorax.

The LVA and LNVA is aimed to reduce lymphatic collection by allowing the lymphatic fluid to bypass into lower pressure veins and ultimately reducing the lymphatic

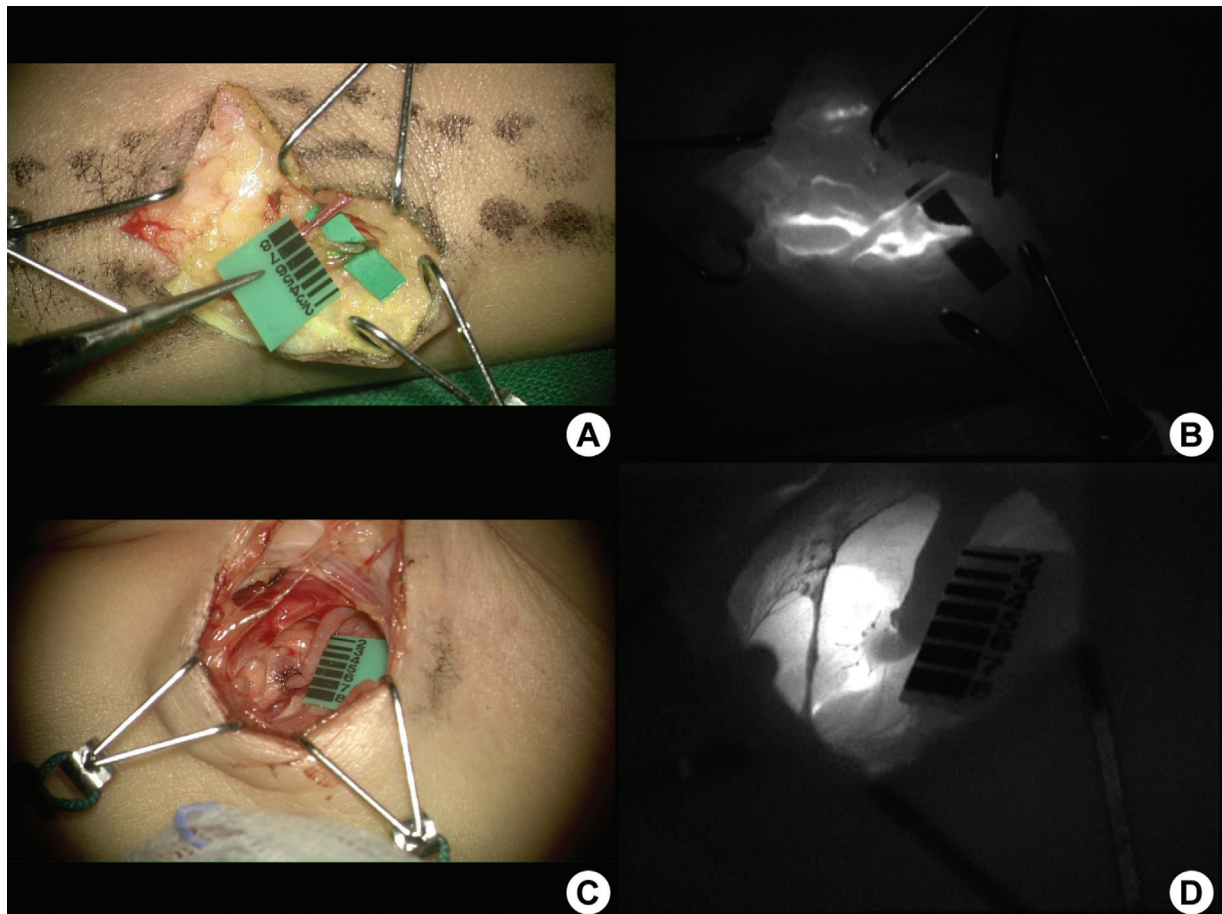


Fig. 4 (A, B) LVA done at dorsum of foot (C, D) LNVA done above inguinal crease. LNVA, lymph node to vein anastomosis; LVA, lymphovenous anastomosis.

pressure.^{12,18–20} This principle can be applied for chylothorax who has pathology of increased thoracic duct pressure. Thus, by reducing the inflow to the thoracic duct, LVA and LNVA may be an useful procedure to redistribute the pressure gradient between thoracic duct, lymphatic system, and venous system. By anastomosing from the side of the lymphatic vessel to the end of the vein, there was no interruption of the lymphatic flow but allowed the high pressure lymphatic fluid to drain into the vein. This change of pressure dynamics along thoracic duct system will redirect the lymphatic flow and regulate the chyle flow, and eventually reducing the chyle leakage as shown in this case report. Other reports have shown similar success for congenital chylothorax.¹¹ Being a minimally invasive surgery with little complication, this approach may shed new promise for chylothorax with increased thoracic duct pressure compared with the direct approach to thoracic duct which can cause complication in up to 38.3% and mortality in 25%.^{4,21,22}

This article has a limitation of being a single case report and further evaluation is needed to confirm this approach. However, this article is the first paper to show the possible role of LVA and LNVA as a safer and an effective physiologic solution for posttraumatic chylothorax patient with increased thoracic duct pressure. Further research and clinical practice are warranted based on this case report.

Author Contributions

Conceptualization, data curation, formal analysis, methodology, visualization: J.P.H. Writing-original draft: Y.K. and H.B.K. Writing-review and editing: H.P.S. and C.J.P.

Patient Consent

Written informed consent was obtained from all the patients.

Funding

None.

Conflict of Interest

C.J.P., H.P.S., and J.P.H. is an editorial board member of the journal but was not involved in the peer reviewer selection, evaluation, or decision process of this article. No other potential conflicts of interest relevant to this article were reported.

References

- 1 Chan SY, Lau W, Wong WH, Cheng LC, Chau AK, Cheung YF. Chylothorax in children after congenital heart surgery. *Ann Thorac Surg* 2006;82(05):1650–1656
- 2 Saxena P, Shankar S, Kumar V, Naithani N. Bilateral chylothorax as a complication of internal jugular vein cannulation. *Lung India* 2015;32(04):370–374

- 3 Tutor JD. Chylothorax in infants and children. *Pediatrics* 2014;133(04):722–733
- 4 Schild HH, Strassburg CP, Welz A, Kalff J. Treatment options in patients with chylothorax. *Dtsch Arztebl Int* 2013;110(48):819–826
- 5 Kovacikova L, Lakomy M, Skrak P, Cingelova D. Immunologic status in pediatric cardiosurgical patients with chylothorax. *Bratisl Lek Listy* 2007;108(01):3–6
- 6 Mohan H, Paes ML, Haynes S. Use of intravenous immunoglobulins as an adjunct in the conservative management of chylothorax. *Paediatr Anaesth* 1999;9(01):89–92
- 7 Wasmuth-Pietzuch A, Hansmann M, Bartmann P, Heep A. Congenital chylothorax: lymphopenia and high risk of neonatal infections. *Acta Paediatr* 2004;93(02):220–224
- 8 Cannizzaro V, Frey B, Bernet-Buettiker V. The role of somatostatin in the treatment of persistent chylothorax in children. *Eur J Cardiothorac Surg* 2006;30(01):49–53
- 9 Yin R, Zhang R, Wang J, et al. Effects of somatostatin/octreotide treatment in neonates with congenital chylothorax. *Medicine (Baltimore)* 2017;96(29):e7594
- 10 Weissler JM, Cho EH, Koltz PF, et al. Lymphovenous anastomosis for the treatment of chylothorax in infants: a novel microsurgical approach to a devastating problem. *Plast Reconstr Surg* 2018;141(06):1502–1507
- 11 Hayashida K, Yamakawa S, Shirakami E. Lymphovenous anastomosis for the treatment of persistent congenital chylothorax in a low-birth-weight infant: a case report. *Medicine (Baltimore)* 2019;98(43):e17575
- 12 Kwon JG, Hong DW, Suh HP, Pak CJ, Hong JP. Patient-specific surgical options for breast cancer-related lymphedema: technical tips. *Arch Plast Surg* 2021;48(03):246–253
- 13 Cho MJ, Kwon JG, Pak CJ, Suh HP, Hong JP. The role of duplex ultrasound in microsurgical reconstruction: review and technical considerations. *J Reconstr Microsurg* 2020;36(07):514–521
- 14 Cha HG, Oh TM, Cho MJ, et al. Changing the paradigm: lymphovenous anastomosis in advanced stage lower extremity lymphedema. *Plast Reconstr Surg* 2021;147(01):199–207
- 15 Pak CS, Suh HP, Kwon JG, Cho MJ, Hong JP. Lymph node to vein anastomosis (LNVA) for lower extremity lymphedema. *J Plast Reconstr Aesthet Surg* 2021;74(09):2059–2067
- 16 Soto-Martinez M, Massie J. Chylothorax: diagnosis and management in children. *Paediatr Respir Rev* 2009;10(04):199–207
- 17 McGrath EE, Blades Z, Anderson PB. Chylothorax: aetiology, diagnosis and therapeutic options. *Respir Med* 2010;104(01):1–8
- 18 Koshima I, Inagawa K, Urushibara K, Moriguchi T. Supermicrosurgical lymphaticovenular anastomosis for the treatment of lymphedema in the upper extremities. *J Reconstr Microsurg* 2000;16(06):437–442
- 19 Lee YW, Lee SH, You HJ, Jung JA, Yoon ES, Kim DW. Lymphatic vessel mapping in the upper extremities of a healthy Korean population. *Arch Plast Surg* 2018;45(02):152–157
- 20 Aulia I, Yessica EC. Surgical management of male genital lymphedema: a systematic review. *Arch Plast Surg* 2020;47(01):3–8
- 21 Rosian K, Stanak M. Efficacy and safety assessment of lymphovenous anastomosis in patients with primary and secondary lymphoedema: a systematic review of prospective evidence. *Microsurgery* 2019;39(08):763–772
- 22 Nath DS, Savla J, Khemani RG, Nussbaum DP, Greene CL, Wells WJ. Thoracic duct ligation for persistent chylothorax after pediatric cardiothoracic surgery. *Ann Thorac Surg* 2009;88(01):246–251