

[CASE REPORT]

Suffocation due to Acute Airway Edema in a Patient with Hereditary Angioedema Highlighted the Need for Urgent Improvements in Treatment Availability in Japan

Daisuke Honda¹, Isao Ohsawa^{1,2}, Yuki Shimizu¹, Masayuki Maiguma¹, Teruo Hidaka¹,
Hitoshi Suzuki¹, Hiroaki Io¹, Satoshi Mano¹, Hisatsugu Takahara¹, Hisaki Rinno¹,
Yasuhiko Tomino^{1,3} and Yusuke Suzuki¹

Abstract:

A 42-year-old Japanese man with hereditary angioedema suffered accidental trauma to his jaw in Shizuoka Prefecture, Japan, which gradually caused facial edema. Since plasma-derived human C1 inhibitor (pdh C1-INH) was unavailable, he had to be transferred to Juntendo University Hospital in Tokyo. Due to his severe edema, he suffered asphyxiation leading to cardiopulmonary arrest upon arrival. The patient was resuscitated and promptly treated with pdh C1-INH. In Japan, the self-administration of pdh C1-INH is not allowed, and every prefecture does not always possess stocks of pdh C1-INH. This case emphasizes the need for urgent improvements in treatment availability in Japan.

Key words: hereditary angioedema, plasma-derived human C1 inhibitor, acute attack, suffocation, trauma, Japan

(Intern Med 57: 3193-3197, 2018)

(DOI: 10.2169/internalmedicine.9262-17)

Introduction

Hereditary angioedema (HAE) is a rare autosomal dominant disease caused primarily by the deficiency or functional impairment of C1 inhibitor (C1-INH). This deficiency can lead to the production of excess bradykinin, a vasoactive peptide in the kallikrein-kinin system, which induces acute attacks of localized subcutaneous or submucosal angioedema in the extremities, face, gastrointestinal tract, larynx or trachea (1-4). The initial symptoms of HAE typically present in childhood, and angioedema attacks are triggered by mental stress, trauma, drugs, surgical procedures and other unknown reasons (5). Untreated upper airway edema in HAE patients may lead to asphyxia. Therefore, HAE attacks should be treated as early as possible (3, 6).

In Western countries, plasma-derived human C1-INH (pdh

C1-INH) has been a first-line therapy for HAE attacks and has been permitted for prophylactic use for several decades (6). Pdh C1-INH helps suppress the contact activation of the kallikrein-kinin system, thereby reducing the vascular permeability and quelling the clinical manifestations, such as edema (7). Early treatment with pdh C1-INH decreases the morbidity and improves outcomes (8, 9).

In Japan, the degree of recognition of HAE among physicians is low, and the mean time from the presentation of initial symptoms to obtaining the correct diagnosis is 13.8 years (10). Furthermore, the use of HAE-specific therapies, such as pdh C1-INH, is limited; only some hospitals keep stocks of pdh C1-INH, and the health insurance system in Japan does not permit the self-administration of pdh C1-INH. Therefore, many patients with HAE may not receive appropriate treatment (11) and often in fear of their next HAE attack.

¹Department of Nephrology, Juntendo University Faculty of Medicine, Japan, ²Nephrology Unit, Saiyu Soka Hospital, Japan and ³Medical Corporation SHOWAKAI, Japan

Received: March 29, 2017; Accepted: March 5, 2018; Advance Publication by J-STAGE: April 27, 2018

Correspondence to Dr. Isao Ohsawa, iohsawa@juntendo.ac.jp

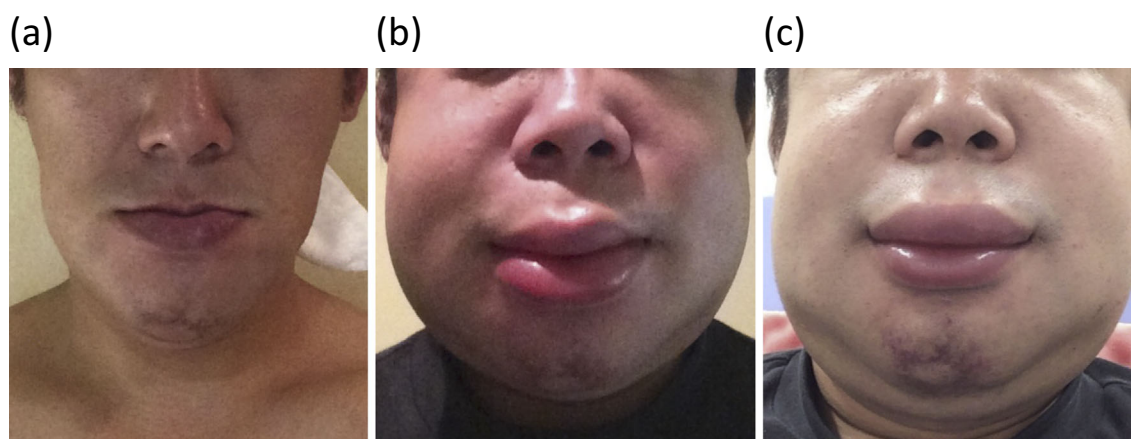

Figure 1. Progression of edema in the patient's face. a) Shortly following injury. b) Fourteen hours after the injury. c) Seventeen hours after the injury.

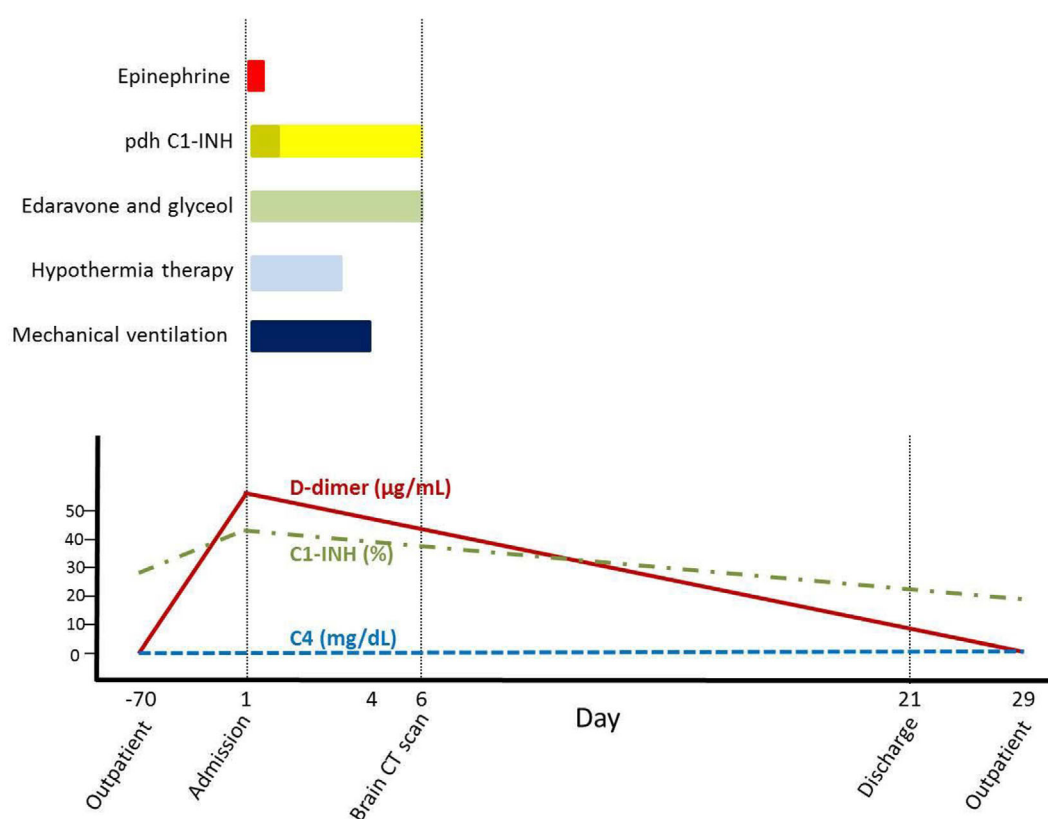


Figure 2. The levels of C1-INH, C4 and D-dimer (all measured on day of admission), and treatment administered, following admission. Upon admission to Juntendo University Hospital, CPR with the infusion of epinephrine (four 1-mg doses) and emergency tracheotomy were performed, and mechanical ventilation was started. Therapeutic hypothermia was induced as a neuroprotective strategy, and edaravone (60 mg/day) and glyceol (400 mL/day) were administered. A 6-day course of pdh C1-INH (Berinert P®; 2,000 U/day 1; 1,000 U/day 2-6) improved the laryngeal and facial edema, and mechanical ventilation was ceased on the fourth day. The patient gradually recovered and was discharged from hospital on the 21st day. CT: computed tomography

We herein report a case of an HAE patient who experienced cardiopulmonary arrest (CPA) following suffocation from an acute attack due to difficulty in accessing treatment with pdh C1-INH in a remote area in Japan. We hope that

this case highlights the need for greater awareness and improved treatment for patients with HAE in Japan.

Table. Blood Test Results upon Admission to Juntendo University Hospital.

Blood test	Result
White blood cells	27,500 / μ L
Neutrophils	60.0 %
Lymphocytes	31.6 %
Eosinophils	1.0 %
Red blood cells	566 \times 10 ⁴ / μ L
Hemoglobin	17.7 g/dL
Hematocrit	52.4 %
Platelets	20.9 \times 10 ⁴ / μ L
D-dimer	57.5 μ g/mL
Aspartate aminotransferase (AST)	98 IU/L
Alanine aminotransferase (ALT)	110 IU/L
Lactate dehydrogenase	424 IU/L
Blood urea nitrogen	9 mg/dL
Creatinine	1.16 mg/dL
Sodium	143 mmol/L
Potassium	3.1 mmol/L
Immunoglobulins	
IgG	869 mg/dL
IgA	215 mg/dL
IgM	142 mg/dL
IgE	7 mg/dL
Complement C3	95 mg/dL
Complement C4	<2 mg/dL
Complement CH50	7.6 mg/dL
C1 inhibitor activity	43 %
C-reactive protein	0.4 mg/dL

Case Report

The patient was a 42-year-old smoking man with a history of childhood asthma and no history of allergies. His paternal aunt and a cousin had both previously been diagnosed with HAE. From 19 years of age, the patient suffered repeated episodes of unexplained facial edema that appeared for several days and then went into remission. At 35 years of age, he was rushed to the hospital with symptoms of airway obstruction and diagnosed and treated for Quincke's edema. At 39 years of age, he relocated to Tokyo for work and was diagnosed with HAE at a university hospital, whereupon he was given tranexamic acid (Transamin[®]) for prophylaxis. From 42 years of age he started to be managed by an HAE specialist at Juntendo University Hospital. He began taking pdh C1-INH (Berinert P[®]) for acute HAE attacks, which usually led to rapid improvement.

In October 2014, he visited a construction site in Shizuoka Prefecture, and a metal bar struck his lower jaw. The injury led to an attack of edema, which was restricted initially to the lower jaw area (Fig. 1a). The next day the edema expanded to include the lower face, particularly the lips and pharynx (Fig. 1b). He visited a local major emergency hospital, whereupon his vital signs were stable, and he was still able to speak. The hospital did not store pdh

C1-INH, so he was treated with 1,000 mg tranexamic acid intravenously. The patient experienced progressive disturbance of his speech and a severe cough due to the edema around his throat, neck and upper face and larynx, which were at risk of leading to suffocation at any moment (Fig. 1c). Therefore, he was transferred by emergency air ambulance 180 km to Juntendo University Hospital in Tokyo, where a sufficient stock of pdh C1-INH is maintained. During the flight, the patient was alert, conscious and could breathe with little difficulty. However, upon arrival at Juntendo University Hospital his respiratory condition rapidly deteriorated. Cardiopulmonary resuscitation (CPR) was started immediately, and the patient was admitted to the intensive-care unit (Fig. 2).

Blood test results revealed that his serum levels of C4 and C1-INH activity were very low, which is characteristic of HAE (Table). The levels of white blood cells, hemoglobin, hematocrit, aspartate aminotransferase, alanine aminotransferase, lactate dehydrogenase, and creatinine were increased, possibly as a result of CPR. Furthermore, he had elevated plasma D-dimer levels, which are associated with acute HAE attacks (12).

Laryngeal edema resulted in considerable difficulty in performing tracheal intubation through the oral cavity. Emergency tracheotomy was performed, and mechanical ventilation was started. As a result of the resuscitation procedures, the patient's heart was restarted about 10 minutes following the onset of CPA. Pdh C1-INH was administered, and therapeutic hypothermia was induced as a neuroprotective strategy (34°C for 24 hours, then raising the core body temperature again over 48 hours). A course of edaravone (Radicut[®], 60 mg/day) and glyceol (Glyceol[®], 400 mL/day) was administered until the sixth day of treatment, when computed tomography indicated no neurological abnormalities in his brain. After administering a multi-day course of pdh C1-INH (Berinert P[®]; first day of treatment 2,000 U/day, then 1,000 U/day until the sixth day of treatment), steady improvement in the laryngeal and facial edema was gradually observed. On the fourth hospital day, the mechanical ventilation was removed, and the patient was able to drink water; the following day, he was able to eat. Owing to careful management of the patient's condition, he gradually recovered without signs of post-resuscitation encephalopathy and was discharged from hospital on the 21st day.

Discussion

HAE attacks can be life-threatening and/or fatal if they are not treated appropriately. Acute treatment aims to reduce the duration and severity of HAE attacks, and it is recommended that all patients have access to on-demand medications, such as pdh C1-INH (1). The present case not only highlights the consequences of inadequate treatment for acute HAE attacks but also underscores the need for improved access to treatment for HAE patients in Japan. Our patient had previously received pdh C1-INH for the treat-

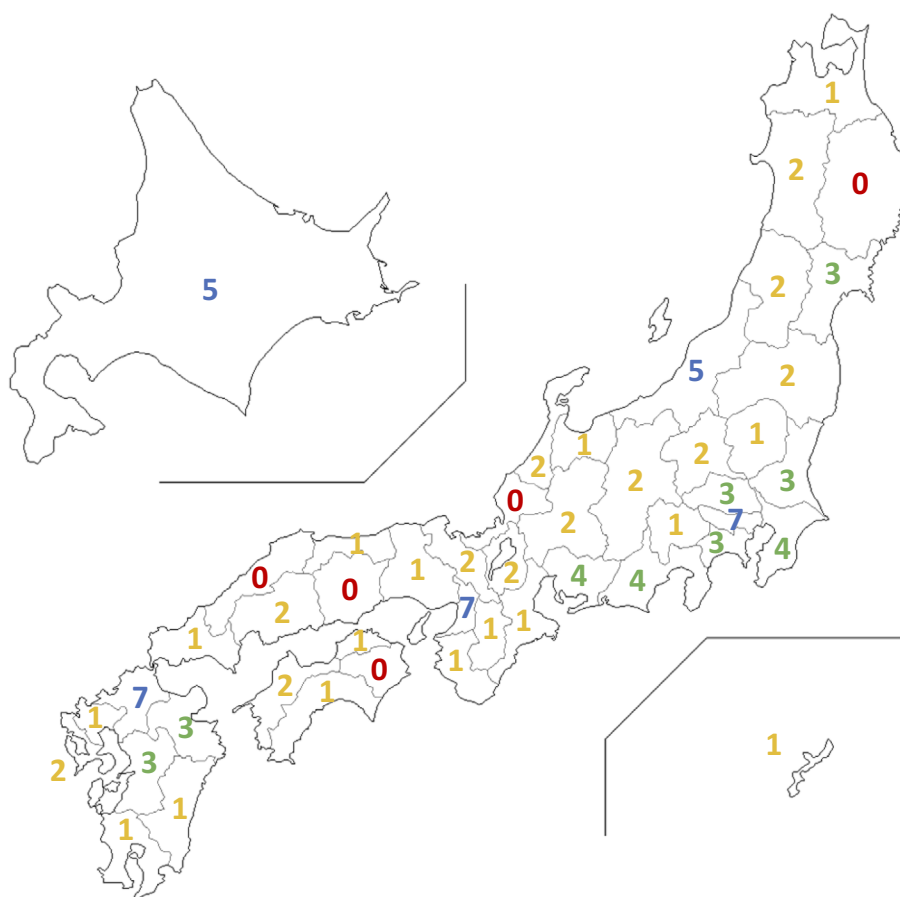


Figure 3. Facilities with publicly disclosed stocks of pdh C1-INH by prefecture in September 2018 in Japan. There are few medical facilities with disclosed stocks of pdh C1-INH in Japan; some prefectures do not have a single medical facility with publicly disclosed stocks of pdh C1-INH (14).

ment of HAE attacks. This was administered at Juntendo University Hospital within several hours of the attack commencing and typically resulted in the resolution of the HAE attack without serious consequences. However, due to difficulties accessing pdh C1-INH in a remote area of Japan, an HAE attack experienced by the patient led to suffocation, the need for CPA and the need for extended hospitalization.

Pdh C1-INH (Berinert P[®]) is available in 39 countries, including the US, Europe and Japan. However, Japan is the only one of these countries where intravenous self-administration of Berinert P[®] is not approved. This conflicts with the recommendations by The World Allergy Organization stating that every individual with HAE types 1 or 2 should be considered for home therapy and self-administration training (3). Although HAE was designated as an intractable disease by the Japanese government in 1994, the self-administration of pdh C1-INH has not been approved. Japanese patients with HAE can therefore only receive pdh C1-INH intravenously when administered by medical staff. In addition, in Japan, the number of hospitals where HAE patients can receive pdh C1-INH is unacceptably low; there are some prefectures with no medical facilities with publicly disclosed stocks of pdh C1-INH (Fig. 3). As pdh C1-INH can only be administered at a limited number hospitals, it is important to re-distribute pdh C1-INH to

major hospitals around an area in order to allow HAE patients to access treatment within a few hours of an acute attack. Allowing patients to carry pdh C1-INH as rescue medication may also enable patients to receive treatment in hospitals that do not carry their own stock of C1-INH.

This case report highlights the need for urgent improvement in the access to treatment in Japan in order to ensure that all HAE patients have continuous and consistent access to treatment. This report highlights the importance of the self-administration of pdh C1-INH and re-distribution of C1-INH stocks to local hospitals in Japan in order to improve the outcomes for patients with HAE. The authors hope that, by sharing this case experience, the medical environment for HAE in Japan will catch up with the progression of Western countries.

The authors state that they have no Conflict of Interest (COI).

References

1. Cicardi M, Bork K, Caballero T, et al. Evidence-based recommendations for the therapeutic management of angioedema owing to hereditary C1 inhibitor deficiency: consensus report of an International Working Group. *Allergy* **67**: 147-157, 2012.
2. Cicardi M, Agostoni A. Hereditary angioedema. *N Engl J Med*

- 334: 1666-1667, 1996.
3. Craig T, Aygoren-Pursun E, Bork K, et al. WAO guideline for the management of hereditary angioedema. *World Allergy Organ J* **5**: 182-199, 2012.
 4. Longhurst H, Cicardi M. Hereditary angio-oedema. *Lancet* **379**: 474-481, 2012.
 5. Zuraw BL. Clinical practice. Hereditary angioedema. *N Engl J Med* **359**: 1027-1036, 2008.
 6. Bowen T, Cicardi M, Farkas H, et al. 2010 International consensus algorithm for the diagnosis, therapy and management of hereditary angioedema. *Allergy Asthma Clin Immunol* **6**: 24, 2010.
 7. Cocchio C, Marzella N. Cinryze, a human plasma-derived c1 esterase inhibitor for prophylaxis of hereditary angioedema. *Pharm Ther* **34**: 293-328, 2009.
 8. Wang A, Fouche A, Craig TJ. Patients perception of self-administrated medication in the treatment of hereditary angioedema. *Ann Allergy Asthma Immunol* **115**: 120-125, 2015.
 9. De Serres J, Groner A, Lindner J. Safety and efficacy of pasteurized C1 inhibitor concentrate (Berinert P) in hereditary angioedema: a review. *Transfus Apher Sci* **29**: 247-254, 2003.
 10. Ohsawa I, Honda D, Nagamachi S, et al. Clinical manifestations, diagnosis, and treatment of hereditary angioedema: survey data from 94 physicians in Japan. *Ann Allergy Asthma Immunol* **114**: 492-498, 2015.
 11. Iwamoto K, Mihara S, Ikezawa Z, Hide M. National prevalence survey of hereditary angioedema in Japan. *Arerugi* **60**: 26-32, 2011 (in Japanese, Abstract in English).
 12. Reshef A, Zanichelli A, Longhurst H, Relan A, Hack EC. Elevated D-dimers in attacks of hereditary angioedema are not associated with increased thrombotic risk. *Allergy* **70**: 506-513, 2015.
 13. HAE Information Center in Japan. [cited 2016 Nov. 23]. Available from: <http://www.hae-info.jp/index.html> (in Japanese).

The Internal Medicine is an Open Access journal distributed under the Creative Commons Attribution-NonCommercial-NoDerivatives 4.0 International License. To view the details of this license, please visit (<https://creativecommons.org/licenses/by-nc-nd/4.0/>).