

Hip arthrodesis in the pediatric population: where do we stand?

Bernd Bittersohl,^{1,2} Daniela Zaps,^{1,2}
James D. Bomar,¹ Harish S. Hosalkar¹

¹Department of Orthopedic Surgery,
Children's Hospital San Diego, USA;

²Department of Orthopedics, Heinrich
Heine University Hospital, Dusseldorf,
Germany

Abstract

Reconstructive and salvage procedures have continued to evolve in orthopedic surgery with changing functional demands of the population as well as advances in implants and surgical techniques. What used to be popular or traditional care at some point may eventually become a thing of the past, and this is true as far as many orthopedic surgical procedures are concerned. Understanding the etiology, pathogenesis, and managing and postponing the destructive pathway of osteoarthritis (OA) has been the goal of orthopedists since the specialty began in the early part of 18th century. Options of treating the severe sequelae of an arthritic joint have varied in different treatment eras. Management options have changed from a spectrum of non-treatment and slow suffering to muscle and soft-tissue releases, interposition arthroplasty and eventual extreme options like joint fusion or arthrodesis. The concept and advent of joint replacement surgery started a new era in the management of OA and was a dream come true in many ways. Mobility and stability are achieved together during the arthroplasty (joint replacement) that allows the patient to maintain a good level of function. Arthroplasty certainly has its pros and cons as we have discovered in the past six decades. Pushing the envelope to younger population has its limitation in terms of longevity of the prosthesis, early loosening, need for repeated revisions that at some point may not be technically possible and risk of infection and disastrous consequences like PE and death associated with the gravity of the procedure. As infrequent as it is in today's clinical practice, arthrodesis of the hip joint has a role and remains a solid option for a well selected case.

The purpose of this review is to discuss the current indications in the pediatric population and outline surgical techniques for hip arthrodesis while pointing out limitations and shortcomings.

Introduction

Secondary osteoarthritis (OA) of the hip is common in various pathologies of the hip in the pediatric population and include Legg-Calvé-Perthes disease (LCPD),^{1,5} slipped capital femoral epiphysis (SCFE),^{6,8} developmental dysplasia of the hip (DDH),^{9,13} idiopathic femoroacetabular impingement (FAI)¹⁴⁻¹⁹ as well as juvenile polyarthritis,^{20,23} septic arthritis²⁴⁻²⁷ primary and secondary avascular necrosis.²⁸⁻³² The main purpose of intervention in this clinical setting is aimed at relieving pain, maintaining activity levels, restoration of hip joint function, and enhancement of quality of life.³³

Although arthroplasty of the hip joint (either surface replacement or traditional total hip arthroplasty [THA]) has become a fairly routine procedure in middle-aged and elderly population with reasonably predictable results, the data available on the long-term follow-up in adolescents and high-demand young adults is fairly limited.³⁴⁻³⁸ Some series reported unsatisfactory results with unacceptably high revision rates ranging from approximately 30% to 50%.³⁹⁻⁴² An arthrodesis of the hip joint, with its ability to offer stability and good function, even in a high-demand patient group, and an option to convert it to a THA later if needed, remains an acceptable modality of treatment.^{36,43} It is important to further recognize that this population remains unique from various perspectives including; life expectancy of likely more than 7-8 decades, higher activity levels that include sports, social demand, sexuality, and personal/individualized expectations of outcomes and function being markedly different from elderly patients who receive THA or hip arthrodesis as a treatment option.

This article provides a comprehensive overview on hip arthrodesis that may guide the treating clinician while approaching such a case. Indications for hip arthrodesis are elaborated and different surgical techniques to achieve a stable as functional hip arthrodesis are outlined and illustrated. Potential problems and their management strategies are discussed.

Indication

Hip arthrodesis in pediatric population (12-19 years, i.e. adolescents) could be recommended in patients with unilateral end-stage OA where hip-preservation procedures are no longer possible or predicted to certainly fail.³³ Etiology of secondary OA in this population has been previously outlined (*see above*). Arthrodesis may also be recommended in certain cases where THA is not feasible like in

Correspondence: Harish S Hosalkar, Rady Children's Hospital, San Diego, UCSD Pediatric Orthopedic Training Program Children's Hospital-San Diego 3030 Children's Way, Suite 410 San Diego, CA 92123, USA.
Tel. +1.858.966.5822 - Fax: +1.858.966.8519
E-mail: hhosalkar@rchsd.org

Key words: hip arthrodesis, pediatric, indication, technique, outcome.

Received for publication: 31 August 2011
Accepted for publication: 5 September 2011

This work is licensed under a Creative Commons Attribution NonCommercial 3.0 License (CC BY-NC 3.0).

©Copyright B. Bittersohl et al., 2011
Licensee PAGEPress, Italy
Orthopedic Reviews 2011; 3:e13
doi:10.4081/or.2011.e13

patients with advanced bone defects that may severely compromise implantation of THA and in cases of severe neurological disorders and neuromuscular insufficiency where soft-tissue balancing for stable THA is not possible.⁴⁴ Relative contraindications for THA are history of sepsis, severe obesity, predictable repetitive loading and excessive demand placed on the hip (example: planned career as construction worker), which make these relative indications for arthrodesis. The combination of an age less than 30 years with a history of multiple hip surgeries, post-traumatic arthritis, and/or post-infectious hip disease without pre-existing lower back pain, ipsilateral knee or contralateral hip arthritis in a highly active individual is potentially a strong indication for hip arthrodesis.³⁶ In contrast, poly-articular OA or symptomatic bilateral conditions should not be considered for unilateral arthrodesis because of the risk of development of contralateral symptoms and progression of contralateral arthritic changes.³⁶

Understandably, bilateral hip arthrodesis is not indicated in any patient. Of note, female patients tend to do as well as male patients, with no reported difficulties with childbirth.^{36,45}

Techniques

There are several factors to be considered while planning a successful hip arthrodesis.³⁶ These include proper patient selection (as outlined above), understanding the unique pre-existing morphology of the patient's hip to plan the surgical technique, choosing the right position for arthrodesis, and avoiding a significant limb-length discrepancy.

In the last century, several techniques to perform a successful hip arthrodesis have

been reported. These could be broadly categorized as: i) Trans-articular methods and ii) Combined Trans- and Extra-articular methods. In general, superior fusion rates have been reported for techniques that combine trans-articular compression and stable internal or external fixation.⁴⁶⁻⁴⁸ Some authors additionally favor subtrochanteric osteotomy with the hip fusion as they believe this leads to better alignment of the extremity and relieves tension across the hip joint by avoiding the long lever-arm effect.⁴⁹ The best surgical approach for intervention remains debatable and should be judged on a case-by-case basis.

What is the optimal position for hip arthrodesis?

The recommended position for hip joint fusion is 15°-40° flexion, 0°-10° abduction or adduction (anatomic femur axis to horizontal axis of the pelvis) and 0°-10° external rotation.^{36,50-55} It is critical to perform repeated measurements, clinically and also fluoroscopically during the procedure to avoid a less than ideal positioning.⁵² Hip arthrodesis with insufficient flexion can compromise the ability to sit while excessive flexion can exacerbate pre-existing shortening of the leg (LLD) and increase the conducted strain on the lumbar spine.³⁶ Karol *et al.* noted in a gait and function study of adolescents who underwent hip arthrodesis that walking was better in patients who had less flexion in the fused hip.⁵³ They concluded that there may be no specific position in flexion that guarantees both easy sitting and absence of pain in the lumbar spine and their recommendation for hip flexion in hip arthrodesis is a flexion of 20-25°. It is important to recognize individual activity levels in the preoperative planning process. For example, if the patient is likely spending most of his or her time in a sitting position (example: office occupation), hip fusion with a flexion towards 30° may be favorable whereas for patients who spend more time standing, a less degree of flexion (i.e. 20°) may be more suitable.³⁶ In the neutral leg/pelvis position, the anatomic axis of the femoral shaft has a mean adduction of 6° to the mechanical axis.³⁶ Based on the study of Lindahl, an increase of 3° of adduction causes *apparent* leg shortening of approximately one cm whereas abduction of an additional 3° creates an *apparent* lengthening of approximately one cm.⁵⁶ Equal leg length is desirable and LLD should be kept to a minimum (1-1.5 cm). From a procedure standpoint, the removal of acetabular and femoral cartilage will lead a further shortening that may add to a *true* LLD. A *true* LLD of two cm may be addressed with increase of abduction or adduction as described by Lindahl⁵⁶ thereby functionally helping the patient. Excessive abduction on the other hand, should be avoided as knee instability has been

reported to correlate with excessive hip abduction.⁵³ For a LLD above four cm, a two-stage procedure that involves limb-length correction (with any of the methods described) after the hip joint has been fused and/or epiphysiodesis at the appropriate time and location should be performed. In addition, variations in abduction or adduction of more than 6° have been reported to have a negative effect on the overall functional outcome.^{51,52} Rotation of the leg is assessed intra-operatively by aligning the patellar orientation to that of the pelvis. Slight (~10°-15°) external rotation is favorable to facilitate routine foot care and shoe wear. Excessive external rotation, on the other hand, will increase the load on the knee and internal rotation of the hip may induce unstable gait-pattern due to in-turning of the foot. Secondary functional problems and eventual disabling symptoms due to mal-positioning may occur.⁵⁷

Trans-articular methods

Trans-articular compression hip arthrodesis via anterior approach with muscle pedicle bone graft

The patient is placed on a fracture table in supine position, followed by routine preparation and draping.⁴⁹ Next, the hip capsule, greater trochanter, femoral head, and rim of the acetabulum are exposed via the anterior iliofemoral approach. If the access to the femoral head is insufficient and cannot be enhanced by flexion and rotation of the leg, the hip joint may be dislocated anteriorly. The arthritic cartilage of the femoral head and the acetabulum is then removed. Following the removal of soft tissue such as synovium or capsule, which can hinder osseous union, the femoral head is placed into the acetabulum. When an optimal alignment of the hip is confirmed, three or more long-threaded pins are inserted through the femoral neck and head across the joint into the ilium while compressing the fusion surfaces. Alternatively, an adult compression hip screw implant can be used. An additional subtrochanteric osteotomy may be performed when the optimal alignment of the hip as described above cannot be achieved.

Muscle-pedicle bone grafts with intact blood supply (reported to lower the rate of pseudoarthrosis)⁵⁸ consisting of the anterior-superior spine with adjacent bone and origins of sartorius and tensor fasciae lata, can be grafted at the site of arthrodesis. Good outcomes have been reported when using larger bone grafts by extending the osteotomy towards the acetabulum.⁵⁹ A bone slot is made across the hip joint from the ilium superior to the acetabular rim to the femoral head and neck reaching the intertrochanteric line. The muscle-pedicle bone graft is then placed within the slot and fixated with one screw in the ilium and the other screw in the femur avoiding torsion or tension on the

pedicle (Figure 1).

Post-operative management includes hip-spica cast immobilization until radiographic healing. Based upon clinical and radiographic findings, weight-bearing may be allowed after 12 weeks. If indicated, hardware removal can be performed one year after solid fusion.

Trans-articular hip arthrodesis with dynamic hip screw via lateral approach

The patient is placed on a standard radiolucent operating table in supine position. Following standard preparation and draping, the hip is exposed via the interval between tensor fascia lata and gluteus medius (Watson-Jones approach).^{60,61} This is followed by the anterior dislocation and exposure of the joint. The remaining articular cartilage of femoral head and acetabulum is removed using standard THA reamers. The resulting bone reamings can be used as supplementary bone graft later. Under fluoroscopic control in two planes, a wire is inserted through the neck and femoral head in order to guide the placement of the dynamic hip screw (DHS). Once the hip is aligned in proper position (as described above), the guide-wire is pushed forward superiorly into the acetabulum. Subsequently, the arthrodesis is fixed with the DHS system by a suitable lag screw con-

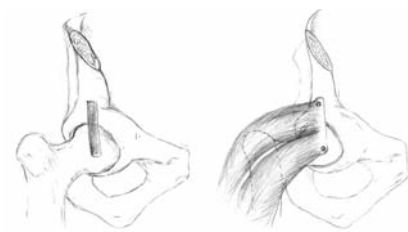


Figure 1. Trans-articular compression arthrodesis of the hip joint via the anterior approach involving a muscle pedicle bone graft.

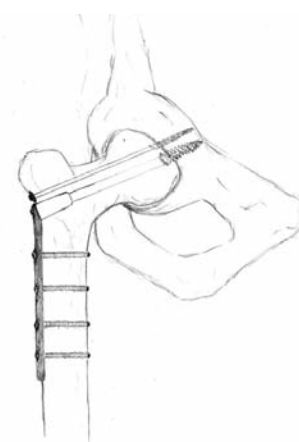

Figure 2. Trans-articular hip arthrodesis with a dynamic hip screw via the lateral approach.

nected to an appropriately sized 135° plate that is held in place by cortical screws. The use of an additional cancellous bone screw provides further rotational stability. A sub-trochanteric osteotomy may be added when necessary (Figure 2).

Immobilization is provided with a hip-spica cast. Depending on clinical and radiographic progress, subsequently the spica is either removed completely or converted into a removable molded polypropylene orthosis, which is worn until union is complete.

Of note, hip arthrodesis with the DHS technique has been reported to be a safe and effective method that does not technically compromise THA at a later stage.⁶⁰ It does not necessitate extensive surgical exposures in order to place bulky internal fixation devices.^{46,54,62} The impairment of the abductor mechanism is negligible and the blood supply to the femoral head is reportedly not affected. Furthermore, from the practical perspective, the implants required for this technique are rather inexpensive and commonly used and, thus, readily available. The study group of Bankes *et al.*,⁶⁰ who described this technique in ten patients (mean 19 years, range 14-35 years), reported a fusion rate of 78%.

Trans-articular hip arthrodesis via trochanteric flip osteotomy with open surgical dislocation of the hip

The technique of surgical dislocation of the hip as described by Ganz *et al.*⁶³ enables 360° exposure of the hip that has been reported in several studies for the treatment of various hip disorders.⁶⁴ We have successfully used this technique in cases with end-stage OA of the hip in adolescent patients.

The patient is placed on a radiolucent table in the lateral decubitus position. Special attention is paid to appropriately pad the pressure points and stabilize the opposite extremity. Once a stable positioning is ensured, the affected hip is prepped and draped to the subcostal margin in a standard sterile orthopedic fashion. The surgical approach is initiated by a lateral incision from the tip of the iliac crest down to the mid femur (modified Gibson approach).⁶⁵ This is carried through skin, subcutaneous tissue and fascia lata, which is split at the transition line between the tensor and gluteus maximus. A Charnley-retractor is used for self-retained retraction. The gluteus maximus is retracted posteriorly and the posterior aspect of the greater trochanter is identified. The vastus lateralis insertion into the greater trochanter is identified and marked with a bovie point. Next, the posterior border of the gluteus medius is identified at its insertion on the greater trochanter and another bovie mark is made at this insertion while leaving a few fibers of the gluteus medius (2-3 mm) posterior to the bovie mark (so as to be sure that the piriformis is protected). Subsequently, a Z osteotomy is cre-

ated with a digastric flap attached to the gluteus medius and vastus lateralis muscles. The greater trochanter is then flipped anteriorly and the capsule is identified. Beginning on the femoral side near the lesser trochanter, the capsulotomy is extended towards the acetabular rim in a classically described Z shaped manner. The superior capsulotomy is performed under direct visualization of the labrum.

The next step involves gentle external rotation to expose and divide the ligamentum teres under vision. This is followed by antero-superior hip dislocation enabling complete exposure of the hip joint. Osteotomes and a high-speed burr are used to denude the femoral head of articular cartilage and subchondral bone down to good bleeding bone. Standard THA reamers are then used to denude the acetabulum of fibro-fatty tissue, scar and also the articular cartilage up to well-bleeding subchondral bone. The hip is then positioned in the proper alignment as previously described. Holding the hip in this position with positioners and a separately prepped sterile Mayo-stand, three 7.3 mm guide pins are drilled into the superior acetabulum from the lateral proximal femur. These guide pins are then over-drilled and 7.3 mm cannulated screws are inserted while compressing the articulating surfaces. Additional bone-grafts are placed around the arthrodesis site as needed. After confirming an adequate hip compression and implant positioning, the greater trochanter is then replaced in its original position and two 3.5 mm fully-threaded stainless steel screws are inserted to re-position and compress the greater trochanter into place. Fluoroscopy is used to confirm suitable screw length and positioning. Upon wound closure and dressing, the patient is turned supine and a hip-spica cast is applied.

At six weeks, the cast is removed. Depending on clinical and radiographic findings (Figure 3), partial weight-bearing can be started after six weeks while full weight-bearing may be allowed after 12 weeks.

Similar to the techniques with the DHS, the trochanter flip approach for surgical hip dislocation and hip arthrodesis spares the abductor muscles. It is a safe and effective method in trained hands. Routine implants can be used for achieving fusion with this technique and a conversion to a THA is possible when indicated in future.

Combined trans- with extra-articular methods

Combined trans-with extra-articular hip arthrodesis via lateral approach with cobra plate (Vancouver technique)

The patient is positioned on a radiolucent table in the lateral decubitus position.⁶⁶ The opposite leg is placed in flexion in order to minimize the degree of lumbar lordosis. The leg is prepped and draped in the typical ortho-

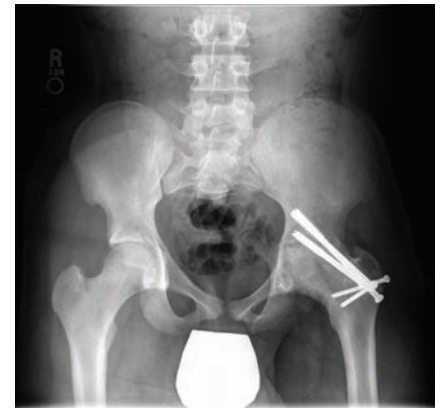

Figure 3. X-ray out of plaster at six weeks post-op following trans-articular hip arthrodesis via trochanteric flip osteotomy with open surgical dislocation of the hip.

pedic manner. A lateral incision centered over the greater trochanter that curves slightly posteriorly in its proximal extent is made. This is carried through the subcutaneous tissue and fascia lata, which is divided accordingly. The vastus lateralis is elevated and a standard osteotomy of the greater trochanter is conducted. The cut of the greater trochanter with abductor muscle origins is retracted proximally. This step is performed with the necessary diligence to spare the gluteus medius for a possible conversion to a THA in the future. The joint capsule is incised anteriorly and the hip is dislocated exposing acetabulum and femoral head. At this stage, the posterior soft tissues including external rotators and capsule are protected in order to preserve the blood supply to the femoral head from that route. The acetabulum is reamed and medialized using a standard THA reamer. The femoral cartilage is removed and the head is shaped with suitable instruments. Osteophytes are excised. If necessary, a matching concave reamer can be used to shape the femoral head in order to provide a spherically congruent arthrodesis site. The bone reamings can be used as bone grafts. Next, the hip is reduced and the leg aligned in the proper position with approximately 30° flexion, 10° adduction and 5° of external rotation. Subsequently, the cobra plate is initially fixed with one proximal screw to the supra-acetabular bone. However, the implementation of compression using the device may cause a slight increase of abduction. Thus, it is recommended to apply the plate with the leg adducted 10° more than the optimal final position. An outrigger compression screw applied through the femoral neck into the acetabulum is used to compress the femur to the acetabulum. Fluoroscopy in two planes is obtained in order to confirm proper implant placement and adequate hip alignment. If suitable, plate fixation and compression are completed. Next, the

greater trochanter is reattached in its anatomic position to ensure sufficient abductor length by using one or two screws (Figure 4). When the fluoroscopic check-up is satisfactory, the wound can be closed in the usual manner.

Postoperative management includes early rehabilitation. Of note, mobilization can be initiated on the first postoperative day with toe-touch weight-bearing, assuming the patient is confident on crutches. A fiberglass hip-spica cast can be considered if there are any concerns about the stability of the fixation and/or compliance of the patient. Partial weight-bearing on two crutches is performed for 12 weeks. If clinical and radiographic follow-up observation are satisfactory, weight-bearing may be gradually increased after six weeks.

The Vancouver technique, which represents a combined trans- and extra-articular method with compression and stable internal fixation technique, has been reported to provide reliable fusion,^{46,62,67} although a rate of only 64% with uneventful clinical and radiographic arthrodesis has been reported in a series of 11 adolescents.⁶⁸

Combined trans-with extra-articular hip arthrodesis via anterior plating technique

The patient is placed on a fracture table in supine position. Parts are prepared and draped. The hip is exposed through a modified Smith-Petersen approach⁶⁹ in the interval between the sartorius and tensor muscles. The exposure is deepened through the subcutaneous layer releasing the abdominal and abductor muscles from the iliac crest. Subsequently, both sartorius and rectus femoris are detached from the tensor fascia muscular sheet. In order to approach the femur and hip joint, the vastus lateralis is elevated anteriorly. As the hip joint is exposed, the cartilage from the femoral head and acetabulum are removed using the appropriate instruments. Once the desired hip position is confirmed, a 6.5 mm lag screw is inserted through the greater trochanter and femoral neck into the supra-acetabular bone that provides additional compression. Next, a 12- to 14-hole low-contact broad dynamic compression plate is contoured in order to match the bone pattern from the inner table of the ilium (internal iliac fossa) across the anterior acetabular rim and the anterior femoral neck onto the intertrochanteric area. Once the plate is contoured appropriately, it is fixed to the ilium and a tensioning device is applied to the distal end of the plate in order to create compression at the arthrodesis. The plate is subsequently fixed to the femur using screws of suitable length. If necessary, the plate may be adjusted to the femur in an under-contoured fashion to prevent favorable increased hip flexion. If required, iliac crest bone graft can be applied to the arthrodesis. If clinical and fluoroscopy control confirms a good surgical result, the wounds are

closed in a typical manner.

Postoperatively, partial weight-bearing for eight to ten weeks is recommended. Full weight-bearing is allowed after 12 weeks if clinical and radiographic data reveal stable bone fusion.

Of note, the aim of the anterior approach is to provide a stable fixation based upon a strong bone stock while preserving the abductor muscles and the vascularity of the femoral head. With the plate fixed on the internal iliac fossa laterally to the sacroiliac joint, which is an area of thick bone, excellent stability can be realized, making this technique a good alternative in cases where there is a fairly limited amount of acetabular or proximal femoral bone stock (Figure 5). Similar to the Vancouver technique, no external fixation (casting) is mandatory assuming the patient is confident on crutches and compliant with postoperative partial weight-bearing. Furthermore, with the patient supine the positioning of the arthrodesis may be easier to control. In a study of 12 patients, Matta *et al.* reported a fusion rate of 83% (mean follow-up: 24.8 months).⁵⁴ In their study, one patient developed a moderately symptomatic non-union while another patient revealed a painful non-union requiring a subsequent arthrodesis. In general, patient satisfaction in this small case series was high.

Pearls

The surgical technique chosen for the fusion should attempt to minimize trauma to the muscles around the hip to allow for a conversion into a THA at a later stage. Conversion THA is technically more challenging than a primary THA. During fusion, a proper hip position (15°-40° flexion, 0°-10° of adduction or abduction, and 0°-10° external rotation) to minimize excessive lumbar spine- and opposite knee compensatory motion is essential to prevent or limit secondary problems following hip arthrodesis.^{36,50-55} Subtrochanteric osteotomy for improved hip positioning may be necessary in some cases.^{70,71} Although, trans-articular techniques are safe and effective, fixation may be inferior to those achieved with extra-articular plate techniques and torque forces caused by the lever arm of the limb have to be considered. Therefore, a hip-spica cast may be necessary to ensure proper bone fusion.⁴⁷ The highest reported fusion rates have been obtained using techniques that combine trans-articular compression and stable internal or external fixation.⁴⁶⁻⁴⁸ Limb-length discrepancy resulting from disruption of the proximal femoral epiphysis may negatively affect the gait pattern.⁵³ Therefore, epiphyseodesis at the appropriate age and location to equalize LLD have to be planned and executed.

Pitfalls

Even with good patient selection and proper technique, many patients may have secondary problems or complications. Symptoms of adjacent joints (lumbar spine, ipsilateral knee joint, contralateral hip joint) related to the compensatory mechanism secondary to hip fusion can be problematic. Also in cases where patients need a secondary THA, results may not be entirely predictable. Occasionally, patients may never recover their full abductor function after THA and require crutches for the remainder of their life.⁴⁴

Back pain following hip arthrodesis

Low-back pain is most common in patients with previously performed hip fusion. In a

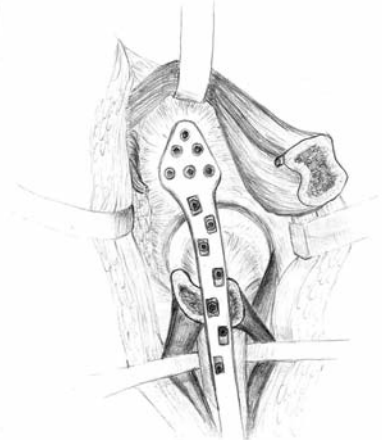


Figure 4. The Vancouver technique prior to wound closure.

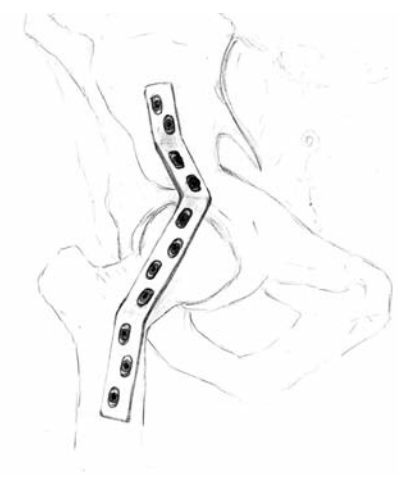


Figure 5. Combined trans- with extra-articular hip arthrodesis via anterior plating technique.

study investigating the long-term follow-up (mean follow-up: 35 years) after hip fusion, 17 patients (61%) revealed back pain after a mean time of 25 years after hip arthrodesis.⁴⁵ The pain correlated with extended sitting in 11 patients while in 14 others low-back pain occurred with prolonged standing or walking. No patient revealed back pain at rest or with sitting, standing or walking. Of note, all patients needed medical treatment, however; only one patient was admitted to hospital. One individual was unemployed related to back pain. In their case series, there was a lower incidence of back pain in patients whose hips were fused in adduction (50%) or neutral position (60%) than those whose hips were fused in abduction (78%). This is in keeping with the studies of Sponseller *et al.* who reported a 57% rate of low-back pain in their series of 53 patients who were less than 35 years old at the time of operation (mean follow-up: 38 years).⁷² Karol *et al.* noted a correlation between excessive lumbar motion and low-back pain, which was related to the amount of hip flexion.⁵³ In patients whose hips were fused with less flexion, their gait pattern, function and pain levels were favorable. Karol *et al.* noted that excessive hip flexion is related to excessive compensatory lumbar lordosis that can cause low-back pain. Of note, in Karol's series of nine adolescents who had an arthrodesis at an average age of 13 years and 5 months, seven out of nine patients (78%) revealed back pain (mean follow-up: 8 years and 10 months) and the onset of back pain was much earlier (range: 6-13 years) than those reported by Roberts and Fetto⁷³ and Callaghan *et al.*⁴⁵ This may be related to the higher activity levels in this study cohort of adolescents.

Although, low-back pain was most common in patients who underwent hip arthrodesis, low-back pain in general was not a major problem in either series of patients and may to some extent reflect the incidence of low-back pain of the general population.

Ipsilateral knee pain

In a follow-up study by Hauge *et al.* including 200 patients (mean age: 52 years, mean follow-up: 22 years) with unilateral hip fusion, more than 20% revealed ipsilateral knee pain or knee joint instability.⁷⁴ Clinically, 51% were noted with exhibiting genu valgum while 96% demonstrated frontal or rotatory instability. Radiographic OA was evident in 65%. However, a correlation between position of the fused hip and its potential effect on the ipsilateral knee could not be verified. These observations are in some ways similar to those of Sponseller *et al.*⁷² and Callaghan *et al.*⁴⁵ who noted ipsilateral knee pain rates of approximately 45% and 60% in their case series. In the study of Callaghan *et al.*,⁴⁵ the mean time of knee pain onset was 23.4 years following hip fusion. The

position of the hip fusion influenced the incidence of pain and radiographic changes in the knee. However, in contrast to Sponseller *et al.*,⁷² a direct correlation between hip arthrodesis position and deformity of the knee could not be observed. Of note, the incidence of ipsilateral knee pain was obviously higher in patients with fused hips in an excessively abducted position. Price and Lovell only noted one out of 14 patients who was complaining of ipsilateral knee pain (mean follow-up: 4.4 years).⁷⁵

Pain in the contralateral hip

Pain in the contralateral hip joint is a common problem in patients with previous hip fusion. In the study of Callaghan *et al.*, ten patients (36%) revealed a significant decrease of joint space in the contralateral hip joint and nine patients (32%) were symptomatic.⁴⁵ The mean time of onset of pain in the contralateral hip joint was 20 years (range: 10-28 years). In six cases this lead to a THA of the contralateral hip. Of note, Garvin *et al.* noted a higher rate of THA failure when the contralateral side has a long-standing fusion.⁷⁶

Leg-length discrepancy

Leg-length discrepancy with varying degrees of severity is a common finding in patients with hip fusion and may sometimes need to be addressed.⁵³ Gore *et al.* studied the walking pattern in men with unilateral hip arthrodesis. They noted favorable gait patterns in patients who have equal limb lengths and recommended treatment of the LLD.⁵² This is similar to the study of Benaroch *et al.* who studied a series of 13 adolescents who had previous hip arthrodesis (mean age: 15.6 years, mean follow-up: 6.6 years).⁷⁷ In this study, a significantly higher incidence of back pain was noted where LLD was above twocm. Based upon bone age, epiphyseodesis may be an effective and low-risk modality to decrease or correct the discrepancy in these cases. In some cases, a shoe lift may be used as well.⁷⁵

Arthrodesis or THA: patient choice in retrospect?

Hip arthrodesis may be the proper choice of treatment in certain cases as discussed extensively above. However, in the current era of hip preservation surgery and advanced bearing surfaces for THA decision-making may prove to be an extremely difficult task for patients. In a long term follow-up study performed by Callaghan *et al.*, 28 patients underwent hip arthrodesis with a mean follow-up of 35 years.⁴⁵ All patients were asked if they would choose hip arthrodesis or THA in retrospect having been through the arthrodesis. Eight patients were happy they chose an arthrodesis. Two patients would definitely have had a THA

in retrospect and 17 patients could not decide. One patient could not understand the question and was, therefore, excluded from the questionnaire.

Conversion of a hip arthrodesis to a total hip arthroplasty

Conversion of a hip arthrodesis to a THA has been reported to give favourable outcomes.⁷⁸⁻⁸⁸ Indications for conversion of a fused hip to a THA include functional disability and continuous pain in the back, knee, and/or contralateral hip secondary to hip fusion. Because of the lack in surgical landmarks, altered hip anatomy and likely compromised muscle function this procedure is technically demanding and results may not be as predictable as a primary THA.^{87,89} The patient has to be aware of higher complication rates and the possibility of decreased survivorship of the prosthesis than that seen with primary THA. Strathy and Fitzgerald noted a high complication (33%) and a revision rate (22%) in THA after hip ankylosis (mean follow-up: 10.4 years).⁹⁰ This study, performed in 1988, involved 80 cemented Charnley THA implantations in 74 patients who had either a spontaneous ankylosis or a surgical hip arthrodesis. Various risk factors for THA failure in fused hips could be identified. These include surgical fusion (48.5% failure rate in patients who underwent surgery versus 5% in patients who had spontaneous ankylosis), more than two surgeries, and patient age of 50 years or less at the time of conversion THA.

Hardinge *et al.* performed a retrospective study on 112 hips (104 patients) converted to THA after spontaneous or surgical fusion excluding ankylosing spondylitis (mean follow-up: 25 years).⁹¹ In this series, only 5% of patients were dissatisfied with THA, although optimum scores on hip evaluation were not achieved until 18 to 24 months after conversion.

Kilgus *et al.* reported on 41 ankylosed hips (38 patients) that were converted to THA.⁸⁰ In this study cohort 68% were spontaneous fusions while 32% were surgically fused. The mean follow-up after conversion to THA was seven years (range: 2-16.5 years). Indications for THA were: non-radicular, activity related back pain (68%), loss of function from immobility or malposition of the fused hip (50%), incidence of pain in the ipsilateral knee (42%), pain in the fused hip (16%), and pain in both contralateral knee and hip (8%). Postoperatively, range of motion was slightly less when compared to primary THA. The rate of failure was 8% for the group with previous spontaneous fusion and 23% in the group who had surgically fused hips. Of note, hip func-

tional scores before and after THA were not significantly different. Other risk factors for earlier failure were: age less than 45 years at the time of THA and two or more operations prior to conversion to a THA.

The outcome after THA in patients with fused hips was more favorable in recent case series revealing lower complication rates (11%, 12%) and better prosthetic survival rates (90%, 97%) after conversion of a fused hip to a cemented THA.^{83,84}

Peterson *et al.* retrospectively reviewed 30 patients who had previous spontaneous or surgical arthrodesis (mean follow-up: 10.4 years, range: 2-20.5 years).⁸⁸ Pain and function levels as well as factors influencing the survivorship of THA were assessed. A failure rate of 23% was noted. The overall survival rate was 86% at five years while a survival rate of 75% was observed after a follow-up of ten years. At the last follow-up visit, 91% had no or minimal pain, 87% of the patients limped, and 61% of the patients needed a walking aid. The survivorship of the prosthesis was superior in patients older than 50 years and in those patients whose arthrodesis had been performed more than 30 years ago. Of note, the survivorship in patients older than 50 years whose hip was fused for more than 30 years was 100% at a ten year follow-up.

Based on the study reported by Strathy *et al.*, the number of operations necessary to fuse the hip did not influence outcome of THA after hip arthrodesis.⁹⁰ Prosthesis survivor rate was similar in patients who had a previous spontaneous ankylosis and patients who had a previous surgical hip arthrodesis.

In general, conversion of a fused hip to THA may likely relieve pain in adjacent joints and meaning fully improve mobility of the hip (although not as good as with a primary THA). However, postoperative gait quality is strongly related to the preoperative abductor muscle function and it is likely that patients may require walking aids after conversion to THA. Full recovery may take up to two years or more.

Take home message

In adolescents and young adults hip arthrodesis remains an effective treatment option providing stability and pain relief without a significant loss of bone stock. Furthermore, it allows patients to fulfill their needs including strenuous activities and high-demand function. It can, if indicated, be converted into THA and may in certain cases be considered as a time buying procedure. Although various surgical approaches and techniques have somewhat similar outcomes, the surgical technique chosen for the fusion should attempt to minimize trauma to the

muscles around the hip so as to allow for a conversion to a THA in a later stage with some predictable outcome.

References

- Gigante C, Frizziero P, Turra S. Prognostic value of Catterall and Herring classification in Legg-Calve-Perthes disease: follow-up to skeletal maturity of 32 patients. *J Pediatr Orthop* 2002;22:345-9.
- Herring JA. The treatment of Legg-Calve-Perthes disease. A critical review of the literature. *J Bone Joint Surg Am* 1994;76:448-58.
- Herring JA, Neustadt JB, Williams JJ, et al. The lateral pillar classification of Legg-Calve-Perthes disease. *J Pediatr Orthop* 1992;12:143-50.
- Herring JA, Williams JJ, Neustadt JN, Early JS. Evolution of femoral head deformity during the healing phase of Legg-Calve-Perthes disease. *J Pediatr Orthop* 1993;13:41-5.
- Wenger DR, Ward WT, Herring JA. Legg-Calve-Perthes disease. *J Bone Joint Surg Am* 1991;73:778-88.
- Engelhardt P. [Natural course of epiphysiolysis of the femur head]. *Der Orthopade* 1994;23:195-9.
- Katz DA. Slipped capital femoral epiphysis: the importance of early diagnosis. *Pediatr Ann* 2006;35:102-11.
- Abraham E, Gonzalez MH, Pratap S, et al. Clinical implications of anatomical wear characteristics in slipped capital femoral epiphysis and primary osteoarthritis. *J Pediatr Orthop* 2007;27:788-95.
- Connolly P, Weinstein SL. [The course and treatment of avascular necrosis of the femoral head in developmental dysplasia of the hip]. *Acta Orthop Traumatol Turcica* 2007;41 Suppl 1:54-9.
- Fernandez CA, Dolan LA, Weinstein SL, Morcuende JA. Natural history of type III growth disturbance after treatment of developmental dislocation of the hip. *Iowa Orthop J* 2008;28:27-35.
- Murray KA, Crim JR. Radiographic imaging for treatment and follow-up of developmental dysplasia of the hip. *Semin Ultrasound CT MR* 2001;22:306-40.
- Sibinski M, Synder M, Pruszczynski B. [Hip joint development after closed reduction, complicated by growth disturbance of the capital femoral epiphysis]. *Chir Narzadow Ruchu Ortop Pol* 2006;71:33-6.
- Kalamchi A, MacEwen GD. Avascular necrosis following treatment of congenital dislocation of the hip. *J Bone Joint Surg Am* 1980;62:876-88.
- Ganz R, Parvizi J, Beck M, et al. Femoroacetabular impingement: a cause for osteoarthritis of the hip. *Clin Orthop Relat Res* 2003;(417):112-20.
- Wagner S, Hofstetter W, Chiquet M, et al. Early osteoarthritic changes of human femoral head cartilage subsequent to femoro-acetabular impingement. *Osteoarthritis Cartilage* 2003;11:508-18.
- Murphy S, Tannast M, Kim YJ, et al. Debridement of the adult hip for femoroacetabular impingement: indications and preliminary clinical results. *Clin Orthop Relat Res* 2004;(429):178-81.
- Tanzer M, Noiseux N. Osseous abnormalities and early osteoarthritis: the role of hip impingement. *Clin Orthop Relat Res* 2004;(429):170-7.
- Bittersohl B, Hosalkar HS, Kim YJ, et al. Delayed gadolinium-enhanced magnetic resonance imaging (dGEMRIC) of hip joint cartilage in femoroacetabular impingement (FAI): Are pre- and postcontrast imaging both necessary? *Magnetic resonance in medicine: official journal of the Society of Magnetic Resonance in Medicine. Magn Reson Med* 2009;62:1362-7.
- Wenger DR, Kishan S, Pring ME. Impingement and childhood hip disease. *J Pediatr Orthop B* 2006;15:233-43.
- Scott RD. Total hip and knee arthroplasty in juvenile rheumatoid arthritis. *Clin Orthop Relat Res* 1990;(259):83-91.
- Hyman BS, Gregg JR. Arthroplasty of the hip and knee in juvenile rheumatoid arthritis. *Rheumat Dis Clin North Am* 1991;17:971-83.
- Spencer CH, Bernstein BH. Hip disease in juvenile rheumatoid arthritis. *Curr Opin Rheumatol* 2002;14:536-41.
- Yun AG, Figgie M, Dorr LD, Scott RD. Hip disease in juvenile rheumatoid arthritis. *Orthopedics* 2006;29:233-9; quiz 40-1.
- Lim SJ, Park YS. Modular cementless total hip arthroplasty for hip infection sequelae. *Orthopedics* 2005;28:s1063-8.
- Grill F, Rustler T. [Late sequelae of coxitis in infants]. *Der Orthopade* 1997;26:848-57.
- Hallel T, Salvati EA. Septic arthritis of the hip in infancy: end result study. *Clin Orthop Relat Res* 1978;(132):115-28.
- Dudkiewicz I, Salai M, Chechik A, Ganel A. Total hip arthroplasty after childhood septic hip in patients younger than 25 years of age. *J Pediatr Orthop* 2000;20:585-7.
- Werner A, Jager M, Schmitz H, Krauspe R. Joint preserving surgery for osteonecrosis and osteochondral defects after chemotherapy in childhood. *Klin Padiatr* 2003;215:332-7.
- Hernigou P, Galacteros F, Bachir D, Goutallier D. Deformities of the hip in adults who have sickle-cell disease and had avascular necrosis in childhood.

- A natural history of fifty-two patients. *J Bone Joint Surg Am* 1991;73:81-92.
30. Mattes T, Fraitzl C, Ostertag O, Reichel H. [Differential diagnoses of avascular necrosis of the femoral head. Articular groin pain in adults]. *Der Orthopade* 2007;36:414, 6-22.
 31. Troum OM, Crues JV, 3rd. The young adult with hip pain: diagnosis and medical treatment, circa 2004. *Clin Orthop Relat Res* 2004;(418):9-17.
 32. Givon U, Bowen JR. Chronic slipped capital femoral epiphysis: treatment by pinning in situ. *J Pediatr Orthop B* 1999;8:216-22.
 33. Clohisy JC, Beaulé PE, O'Malley A, et al. Hip disease in the young adult: current concepts of etiology and surgical treatment. *J Bone Joint Surg Am* 2008;90:2267-81.
 34. Jager M, Begg MJ, Ready J, et al. Primary total hip replacement in childhood, adolescence and young patients: quality and outcome of clinical studies. *Technol Health Care* 2008;16:195-214.
 35. Kamath AF, Sheth NP, Hosalkar HH, et al. Modern Total Hip Arthroplasty in Patients Younger Than 21 Years. *J Arthroplasty* 2011. [Epub ahead of print]
 36. Beaulé PE, Matta JM, Mast JW. Hip arthrodesis: current indications and techniques. *J Am Acad Orthop Surg* 2002;10:249-58.
 37. Restrepo C, Lettich T, Roberts N, et al. Uncemented total hip arthroplasty in patients less than twenty-years. *Acta Orthop Belg* 2008;74:615-22.
 38. Clohisy JC, Oryhon JM, Seyler TM, et al. Function and fixation of total hip arthroplasty in patients 25 years of age or younger. *Clin Orthop Relat Res* 2010;468:3207-13.
 39. Dorr LD, Luckett M, Conaty JP. Total hip arthroplasties in patients younger than 45 years. A nine- to ten-year follow-up study. *Clin Orthop Relat Res* 1990;(260):215-9.
 40. Ortiguera CJ, Pulliam IT, Cabanela ME. Total hip arthroplasty for osteonecrosis: matched-pair analysis of 188 hips with long-term follow-up. *J Arthroplasty* 1999;14:21-8.
 41. Sochart DH. Factors affecting aseptic failure of fixation after primary Charnley total hip arthroplasty. Multivariate survival analysis. *J Bone Joint Surg Am* 1998;80:1553-4.
 42. Torchia ME, Klassen RA, Bianco AJ. Total hip arthroplasty with cement in patients less than twenty years old. Long-term results. *J Bone Joint Surg Am* 1996;78:995-1003.
 43. Liechti R. Hip arthrodesis and associated problems. Berlin, New York: Springer-Verlag; 1978.
 44. Eichinger S, Forst R, Kindervater M. [Indications and alternatives for arthroplasty in young patients]. *Der Orthopade* 2007;36:311-24.
 45. Callaghan JJ, Brand RA, Pedersen DR. Hip arthrodesis. A long-term follow-up. *J Bone Joint Surg Am* 1985;67:1328-35.
 46. Barmada R, Abraham E, Ray RD. Hip fusion utilizing the cobra head plate. *J Bone Joint Surg Am* 1976;58:541-4.
 47. Mowery CA, Houkom JA, Roach JW, Sutherland DH. A simple method of hip arthrodesis. *J Pediatr Orthop* 1986;6:7-10.
 48. Tavares JO, Frankovitch KF. Hip arthrodesis using the AO modular external fixator. *J Pediatr Orthop* 1998;18:651-6.
 49. Canale ST. Operative pediatric orthopaedics. St. Louis: Mosby Year Book; 1991.
 50. Lipscomb PR. Fracture-dislocation of the hip. *Instr Course Lect* 1961;18:102-9.
 51. Ahlback SO, Lindahl O. Hip arthrodesis. The connection between function and position. *Acta Orthop Scand* 1966;37:77-87.
 52. Gore DR, Murray MP, Seps SB, Gardner GM. Walking patterns of men with unilateral surgical hip fusion. *J Bone Joint Surg Am* 1975;57:759-65.
 53. Karol LA, Halliday SE, Gourineni P. Gait and function after intra-articular arthrodesis of the hip in adolescents. *J Bone Joint Surg Am* 2000;82:561-9.
 54. Matta JM, Siebenrock KA, Gautier E, et al. Hip fusion through an anterior approach with the use of a ventral plate. *Clin Orthop Relat Res* 1997;(337):129-39.
 55. Stover MD, Beaulé PE, Matta JM, Mast JW. Hip arthrodesis: a procedure for the new millennium? *Clin Orthop Relat Res* 2004;(418):126-33.
 56. Lindahl O. Functional capacity after hip arthrodesis. *Acta Orthop Scand* 1965;36:453-8.
 57. Reynolds D, Freeman MAR. Osteoarthritis in the young adult hip: options for surgical management. Edinburgh, New York: Churchill Livingstone; 1989.
 58. Davis JB. The muscle-pedicle bone graft in hip fusion. *J Bone Joint Surg Am* 1954;36-A:790-9.
 59. Ranawat CS, Jordan LR, Wilson PD, Jr. A technique of muscle-pedicle bone graft in hip arthrodesis. A report of its use in ten cases. *J Bone Joint Surg Am* 1971;53:925-34.
 60. Bankes MJ, Simmons JM, Catterall A. Hip arthrodesis with the dynamic hip screw. *J Pediatr Orthop* 2002;22:101-4.
 61. Watson-Jones R. Fractures of the neck of the femur. *Br J Surg* 1935;23:787.
 62. Murrell GA, Fitch RD. Hip fusion in young adults. Using a medial displacement osteotomy and cobra plate. *Clin Orthop Relat Res* 1994;(300):147-54.
 63. Ganz R, Gill TJ, Gautier E, et al. Surgical dislocation of the adult hip a technique with full access to the femoral head and acetabulum without the risk of avascular necrosis. *J Bone Joint Surg Br* 2001;83:1119-24.
 64. Sink EL, Beaulé PE, Sucato D, et al. Multicenter Study of Complications Following Surgical Dislocation of the Hip. *J Bone Joint Surg Am* 2011;93:1132-6.
 65. Gibson A. Posterior exposure of the hip joint. *J Bone Joint Surg Br* 1950;32-B:183-6.
 66. Barrack RL, Rosenberg AG, eds. The hip. Second edition. Philadelphia: Lippincott Williams & Wilkins; 2005.
 67. Duncan CP, Spangehl M, Beauchamp C, McGraw R. Hip arthrodesis: an important option for advanced disease in the young adult. *Canad J Surg* 1995;38 Suppl 1:S39-45.
 68. Klemme WR, James P, Skinner SR. Results of hip arthrodesis in adolescents by using the cobra-head plate for internal fixation. *J Pediatr Orthop* 1998;18:648-50.
 69. Smith-Petersen MN. Approach to and exposure of the hip joint for mold arthroplasty. *J Bone Joint Surg Am* 1949;31A:40-6.
 70. Thompson FR. Combined hip fusion and subtrochanteric osteotomy allowing early ambulation. *J Bone Joint Surg Am* 1956;38-A:13-22.
 71. Apley AG, Denham RA. Osteotomy as an aid to arthrodesis of the hip. *J Bone Joint Surg Br* 1955;37-B:185-90.
 72. Sponseller PD, McBeath AA, Perpich M. Hip arthrodesis in young patients. A long-term follow-up study. *J Bone Joint Surg Am* 1984;66:853-9.
 73. Roberts CS, Fetto JF. Functional outcome of hip fusion in the young patient. Follow-up study of 10 patients. *J Arthroplasty* 1990;5:89-96.
 74. Hauge MF. The knee in patients with hip joint ankylosis. Clinical survey and biomechanical aspects. *Acta Orthop Scand* 1973;44:485-95.
 75. Price CT, Lovell WW. Thompson Arthrodesis of the hip in children. *J Bone Joint Surg Am* 1980;62:1118-23.
 76. Garvin KL, Pellicci PM, Windsor RE, et al. Contralateral total hip arthroplasty or ipsilateral total knee arthroplasty in patients who have a long-standing fusion of the hip. *J Bone Joint Surg Am* 1989;71:1355-62.
 77. Benaroch TE, Richards BS, Haideri N, Smith C. Intermediate follow-up of a simple method of hip arthrodesis in adolescent patients. *J Pediatr Orthop* 1996;16:30-6.
 78. Amstutz HC, Ludwig RM, Schurman DJ, Hodgson AG. Range of motion studies for total hip replacements. A comparative study with a new experimental apparatus. *Clin Orthop Relat Res* 1975;(111):124-30.
 79. Brewster RC, Coventry MB, Johnson EW, Jr. Conversion of the arthrodesed hip to a total hip arthroplasty. *J Bone Joint Surg*

- Am 1975;57:27-30.
80. Kilgus DJ, Amstutz HC, Wolgin MA, Dorey FJ. Joint replacement for ankylosed hips. *J Bone Joint Surg Am* 1990;72:45-54.
81. Toni A, Sudanese A, Bueno Lozano AL, et al. Indications and limits of acetabular reimplantations using screwed prostheses. *Chir Organi Mov* 1994;79:387-96.
82. Wolfel AR, Walther M, Rader C, Beck H. [Endoprosthetic management of patients with hip arthrodesis]. *Z Orthop Ihre Grenzgeb* 2000;138:318-23.
83. Hamadouche M, Kerboull L, Meunier A, et al. Total hip arthroplasty for the treatment of ankylosed hips : a five to twenty-one-year follow-up study. *J Bone Joint Surg Am* 2001;83-A:992-8.
84. Joshi AB, Markovic L, Hardinge K, Murphy JC. Conversion of a fused hip to total hip arthroplasty. *J Bone Joint Surg Am* 2002;84-A:1335-41.
85. Hajny P, Kolman J. [Total endoprosthesis replacement after hip joint arthrodesis]. *Chir Orthop Traumatol Cech* 2004;71:101-5.
86. Zeiler G, Schuh A. [Arthrodesis of the hip and its conversion]. *Der Orthopade* 2004;33:939-56; quiz 57.
87. Lubbeke A, Katz JN, Perneger TV, Hoffmeyer P. Primary and revision hip arthroplasty: 5-year outcomes and influence of age and comorbidity. *J Rheumatol* 2007;34:394-400.
88. Peterson ED, Nemanich JP, Altenburg A, Cabanela ME. Hip arthroplasty after previous arthrodesis. *Clin Orthop Relat Res* 2009;467:2880-5.
89. Kilgus DJ, Namba RS, Gorek JE, et al. Total hip replacement for patients who have ankylosing spondylitis. The importance of the formation of heterotopic bone and of the durability of fixation of cemented components. *J Bone Joint Surg Am* 1990;72:834-9.
90. Strathy GM, Fitzgerald RH Jr. Total hip arthroplasty in the ankylosed hip. A ten-year follow-up. *J Bone Joint Surg Am* 1988;70:963-6.
91. Hardinge K, Murphy JC, Frenyo S. Conversion of hip fusion to Charnley low-friction arthroplasty. *Clin Orthop Relat Res* 1986;(211):173-9.