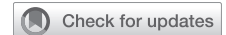

Surgical management of delayed-presentation diaphragm hernia: A single-institution experience



Emma K. Jones, MD, Rafael Andrade, MD, MHA, Amit Bhargava, MD, Ilitch Diaz-Gutierrez, MD, and Madhuri Rao, MD, FACS

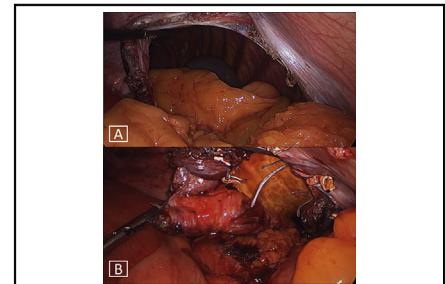
ABSTRACT

Objectives: Delayed-presentation diaphragm hernias are uncommon, and surgical management varies widely across practices. We describe our surgical experience with delayed-presentation diaphragm hernias as a case series of 14 patients, 9 of whom underwent minimally invasive repair.

Methods: We performed a retrospective chart review of our prospective database of all patients treated surgically for delayed-presentation diaphragm hernia at our institution from January 1, 2005, to April 30, 2021. We excluded patients with post-sternotomy, post-left ventricular assist device, and previously diagnosed congenital hernias. We recorded patient demographics, etiology, laterality, chronicity, operative details, postoperative complications, and long-term results.

Results: We performed surgical repair of delayed-presentation diaphragm hernia in 14 patients. Eleven patients (79%) were male, the median age was 61 (18-83) years, the median body mass index was 29.2 (14.5-33.7), and 8 (57%) hernias were left-sided. Etiology was trauma (n = 7, 50%), iatrogenic (n = 5, 36%), and unknown (n = 2, 14%). Median time to presentation in patients with traumatic and iatrogenic hernias was 7.5 years (6 weeks to 38 years). Nine patients (64%) underwent minimally invasive repair, and 5 patients (36%) underwent open repair. We used a synthetic patch in all but 2 patients (86%). Median length of stay was 5 (3-27) days. Two patients (14%) had major complications. There were no deaths. Twelve patients (86%) had follow-up imaging at a median follow-up of 17 months (1-192) with zero recurrences.

Conclusions: Our experience suggests that a minimally invasive or an open approach to patients with a delayed-presentation diaphragm hernia is safe and effective. We recommend tailoring the surgical approach based on patient characteristics, anatomic considerations, and surgeons' experience. (JTCVS Techniques 2022;13:263-9)



A, Laparoscopic view, left posterolateral hernia defect. B, Minimally invasive patch repair.

CENTRAL MESSAGE

Minimally invasive repairs of delayed-presentation diaphragm hernias are safe if the approach is tailored to patient characteristics, anatomic considerations, and surgeons' experience.

PERSPECTIVE

Delayed-presentation diaphragm hernia is a rare surgical disease, and literature detailing optimal surgical management is sparse. Existing case series focus on traumatic etiology and include acute and delayed presentation diaphragm hernias. We present a case series of 14 patients who underwent surgical management of delayed-presentation diaphragm hernia including 9 minimally invasive repairs.

▶ Video clip is available online.

Delayed-presentation diaphragm hernias in adults are rare, and the surgical management can be challenging. The pro-
tean presentation of these hernias leads to delays in diagnosis, and sometimes the etiology remains unknown.

Trauma is the most common etiology of acute and delayed-presentation acquired diaphragm hernia.

From the Division of Thoracic and Foregut Surgery, Department of Surgery, University of Minnesota, Minneapolis, Minn.

Date and number of Institutional Review Board (IRB) approval: 8/10/21 STUDY00013639. The IRB of the authors' institution approved the study protocol and publication of data. Patient written consent for the publication of the study data was waived by the IRB because the collection of data for this retrospective study posed minimal risk to patients.

Received for publication Oct 18, 2021; revisions received March 1, 2022; accepted for publication April 11, 2022; available ahead of print April 20, 2022.

Address for reprints: Madhuri Rao, MD, FACS, Division of Thoracic and Foregut Surgery, University of Minnesota, MMC 207, 420 Delaware St SE, Minneapolis, MN 55455 (E-mail: mvrhao@umn.edu).

2666-2507

Copyright © 2022 The Author(s). Published by Elsevier Inc. on behalf of The American Association for Thoracic Surgery. This is an open access article under the CC BY-NC-ND license (<http://creativecommons.org/licenses/by-nc-nd/4.0/>).

<https://doi.org/10.1016/j.jtc.2022.04.012>

Abbreviations and Acronyms

BMI	=	body mass index
LOS	=	length of stay
VATS	=	video-assisted thoracoscopic surgery

Diaphragm rupture occurs in approximately 5% of severe thoracoabdominal traumas.¹ Acute diaphragm ruptures typically present with abdominal pain and as a component of polytrauma; however, diagnostic tests miss up to 66% of acute traumatic diaphragm hernias.² The next most common etiology of delayed-presentation diaphragm hernia in adults is iatrogenic,³ although this is a rare cause of diaphragm hernias. Delayed-presentation diaphragm hernias are rare and can be asymptomatic for years, and eventual complications carry a high risk of morbidity (30%) and mortality (10%-20%).^{1,2,4,5} Minimally invasive repair is safe for acute-presentation traumatic diaphragm hernias in the absence of polytrauma.⁶ However, few reports describe minimally invasive repair of delayed-presentation diaphragm hernias. One series published in 2016 reports 5 patients who underwent minimally invasive repair of chronic diaphragm hernias.⁷ Given the uncommon and heterogeneous nature of the disease, there is no consensus in the literature regarding optimal timing and approach for surgical intervention.

Thoracotomy and laparotomy are the traditional approaches to repair chronic diaphragm hernias with or without patch or mesh.^{1,2,5,7-12} Since the first report of laparoscopic repair of a traumatic hernia in the English language surgical literature in 1994,¹³ individual case reports and several small case series have suggested that minimally invasive approaches are safe and effective.^{14,15} Even so, there is some hesitation among surgeons to embrace this due to concern for injury to hernia contents, inability to reduce the hernia, and difficult angles for patch or mesh suturing.¹⁶ This study reports our single-center experience with the repair of delayed-presentation diaphragm hernias using minimally invasive and open techniques.

PATIENTS AND METHODS

We performed a retrospective chart review of our prospective database of all patients treated surgically for delayed-presentation diaphragm hernia at our institution from January 1, 2005, to April 30, 2021. The institutional IRB approved this study on 8/10/21 (STUDY00013639). This retrospective study did not require written consent.

We excluded patients with hiatal, previously diagnosed congenital, poststernotomy, and post-left ventricular assist device hernias. We recorded patient demographics, etiology, chronicity, laterality, operative details, postoperative complications, and long-term results. We defined delayed-presentation diaphragm hernia as a diagnosis of a diaphragm hernia occurring after the initial admission associated with the inciting event when known. We determined chronicity as the time elapsed from the inciting event when known. In patients with an unknown etiology, we determined chronicity as the time elapsed between initial symptoms and

diagnosis of a diaphragmatic hernia. Recurrence was any radiographic evidence of recurrent hernia.

Patient demographics included gender, age at the time of surgery, and body mass index (BMI). We determined chronicity and etiology from chart review. Operative details included operative approach, laterality, use of patch or mesh, operative time, and estimated blood loss. Postoperative data included length of stay (LOS), morbidity, and mortality. Follow-up data included most recent follow-up date, type of most recent imaging, interval time from surgery to imaging, and imaging or clinical evidence of recurrence. We use descriptive statistics and present results as median with range for continuous variables and as frequency and percentage for categorical variables.

Surgical Techniques

We follow the same basic surgical principles for open and minimally invasive repairs. When preparing for surgery, we position and prep patients as for a thoracoabdominal approach. This allows access to both body cavities without repositioning, regardless of approach. Our practice is to start most repairs laparoscopically, and we add thoracoscopy if necessary. Laparoscopy facilitates hernia content release and hernia sac excision with clear visualization of viscera. The addition of thoracoscopy is particularly helpful for the repair of posterior defects, hernia repairs in obese patients (BMI >30), and to repair right-sided defects in proximity of the inferior vena cava. Thoracoscopy is also helpful to place stitches around the ribs posterolaterally if there is no adequate rim of diaphragm for suturing. In patients with very large right-sided hernias containing liver, we occasionally start with thoracotomy because of the difficulty of reducing the liver with minimally invasive techniques. Intraoperatively, we always open, circumferentially dissect, and attempt to fully remove the hernia sac. Dissection and resection of the hernia sac facilitate clear identification of the edges of the diaphragmatic defect and is essential to prevent postoperative intrathoracic fluid collections. At the end of the procedure, we always place an ipsilateral chest tube and remove it when the output is less than 200 to 300 mL per day.

We prefer to use patch material in all patients with defects greater than 3 cm, which we secure using permanent, braided, pledgeted #2 sutures. When patients have defects that extend laterally and result in loss of domain of diaphragm near the chest wall, we place sutures around the ribs to anchor the patch as shown in [Video 1](#). Our patch of choice is a 2-mm-thick polytetrafluoroethylene patch with 1 smooth and 1 rugated side (Gore DualMesh, WL Gore & Associates, Inc), and we place the smooth side towards the abdominal viscera. Our preferred suture is a coated, braided, polyester #2 suture on a large needle (Ti-Cron, Medtronic, Covidien).

RESULTS

We performed surgical repair of delayed-presentation diaphragm hernia in 14 patients during our study period. [Table 1](#) summarizes demographics, hernia etiology, laterality, chronicity, and presenting symptoms. Nine patients (64%) underwent minimally invasive repair, and 5 patients (36%) underwent open repair. [Table 2](#) summarizes the series by approach.

Median LOS was 5 (3-27) days regardless of approach, although there was more variation in the open repair group with a range of 3 to 27 days compared with 3 to 10 days in the minimally invasive group. Significant 30-day postoperative morbidity (Clavien Dindo III and IV) occurred in 2 patients (14%). One patient who underwent a thoracotomy for a massive post-traumatic hernia (chronicity of 38 years) had

TABLE 1. Patient demographics and hernia characteristics

Variable	value
Age in years*	61 (18-83)
Gender, n (%)	
Male	11 (79)
Female	3 (21)
BMI (kg/m ²)*	29.2 (14.5-33.7)
Etiology, n (%)	
Traumatic	7 (50)
Iatrogenic/postoperative	5 (36)
Hepatectomy for liver donation	2 (40)
Hepatectomy for cancer	1 (20)
Anterior approach spinal fusion	1 (20)
Transdiaphragmatic lung resection	1 (20)
Unknown	2 (14)
Chronicity in years*	7.5 (0.1-38)
Hernia laterality, n (%)	
Left	8 (57)
Right	6 (43)
Presenting symptom, n (%)	
Dyspnea	5 (36)
Abdominal pain	6 (43)
Chest pain	2 (14)
Bowel obstruction	3 (21)
Dysphagia	1 (7)
Cough	1 (7)
None	1 (7)

BMI, Body mass index. *Median and range.

a postoperative cerebrovascular accident, multisystem organ failure, delayed-presentation bowel fistula that required patch removal, and bronchopleural fistula requiring Eloesser flap. However, he eventually recovered after 2 years and multiple operations. The other patient developed a hemothorax after combined laparoscopic and video-assisted thoracoscopic surgery (VATS) repair requiring washout via thoracotomy on postoperative

day 1. Table 3 summarizes postoperative complications. Figure 2 shows the preoperative and postoperative imaging and intraoperative photographs of one of our minimally invasive repairs.

Twelve patients (86%) had follow-up imaging at a median follow-up of 17 months (1-192) with zero recurrences. Two patients were uninsured and could not afford follow-up imaging, but were asymptomatic at 30 and 32 months, respectively.

DISCUSSION

Our series of surgical management of delayed-presentation diaphragmatic hernias includes 9 patients who underwent minimally invasive repair. In our experience, adherence to the basic principles of a tailored approach based on patient and hernia characteristics, careful lysis of adhesions, sac reduction with precise delineation of the diaphragmatic defect, and liberal use of synthetic patch material leads to excellent mid-term results.

Our patient cohort had various etiologies of chronic diaphragmatic hernia. Trauma was the most common cause for acquired chronic diaphragmatic hernia in our experience (50%), followed by iatrogenic hernia in 36%, most commonly after liver resection. This is consistent with other published reports.^{2,3,5,17-20} We repaired 2 hernias for which we could not determine an etiology. These 2 patients were not previously diagnosed with congenital hernias, and the intraoperative anatomy was not typical of a congenital hernia. We included these 2 cases because the presentation, diagnosis, and management of chronic diaphragmatic hernias is essentially the same irrespective of congenital or acquired etiology.

We repaired 9 of 14 (64%) chronic diaphragmatic hernias via laparoscopy, VATS, or combined laparoscopic-VATS approach, 3 of these were right-sided, and we performed patch repair in 8 of the 9 patients (89%). Operative time and LOS were similar between minimally invasive and open approaches; however, intraoperative blood loss was higher in thoracotomy cases versus minimally

TABLE 2. Operative details

Approach, n	Etiology, n	Side, n	Patch, n	EBL in mL*	Operative time in minutes*	LOS in days*
Minimally Invasive						
Laparoscopy, 4	Trauma, 2	L, 4	4	50 (10-600)	268 (179-296)	5 (3-10)
	Unknown, 2					
VATS, 1	Iatrogenic, 1	R, 1	No	50	174	9
Laparoscopy + VATS, 4	Trauma, 2	L, 2	4	50 (20-500)	238 (160-546)	5 (4-8)
	Iatrogenic, 2	R, 2				
Open						
Thoracotomy, 4	Trauma, 3	L, 1	4	450 (100-2000)	280 (172-608)	4 (3-27)
	Iatrogenic, 1	R, 3				
Laparotomy, 1	Iatrogenic, 1	L, 1	No	100	188	6

EBL, Estimated blood loss; LOS, length of stay; VATS, video-assisted thoracoscopic surgery. *Median and range.

TABLE 3. Complete list of complications

Complication	Open n (%)	Minimally invasive n (%)
Cerebrovascular accident	1 (7)	0
Multisystem organ failure	1 (7)	0
Bowel fistula	1 (7)	0
Bronchopleural fistula	1 (7)	0
Hemothorax	0	1 (7)
Prolonged air-leak	1 (7)	0
Superficial wound infection	1 (7)	0
Chronic pain	0	1 (7)
Incisional hernia	0	1 (7)
Atrial fibrillation	1 (7)	0

invasive cases. Our numbers are too small to draw any conclusions based on these results, and we used thoracotomy for patients with very large and complex hernias, which likely explains the higher blood loss. In their series of delayed presentation diaphragm hernias, Liao and colleagues⁷ included 5 minimally invasive repairs, all treated laparoscopically without patch or mesh. In the same study, they included 19 patients with open repairs. They reported a LOS of 6 days for minimally invasive repairs, similar to ours, versus 16 days for open repairs. Although they detailed their surgical techniques, they did not report operative times or blood loss.

The decision of an open versus a minimally invasive approach depends on patient and hernia characteristics, hernia size, location, laterality, and surgeon’s experience. At our center, our experience with minimally invasive post-left ventricular assist device diaphragm hernia repair²¹ was instrumental in the development of our minimally invasive approaches to complex chronic diaphragm hernias. Our

current preference is to start laparoscopically in the majority of patients and add VATS or convert to thoracotomy or laparotomy depending on intraoperative findings. Based on our experience with laparoscopic diaphragm plication,²² the laparoscopic approach is best suited for patients with a BMI less than 30 and mid or anterior diaphragmatic defects. If the defect is posterolateral or a patient has a BMI greater than 30, then we generally combine laparoscopy with thoracoscopy. Thoracoscopy optimizes visualization of the posterior portion of the diaphragm and permits the surgeon to secure the patch to the ribs if necessary. There are reports in the literature of robot-assisted minimally invasive repair of congenital diaphragm hernias,¹⁵ acute diaphragm ruptures,²³ and delayed-presentation acquired diaphragm hernias.¹⁹ The proposed benefits of using the robotic platform include better visualization and precise dissection near critical structures such as the esophagus. However, it may be challenging to use in cases where a combined abdominal and thoracic approach is required.

We are more likely to use a thoracotomy in right-sided iatrogenic hernias because of postoperative scarring, difficulty reducing the liver, and the technical difficulty of suturing to the medial margin due to the proximity of the inferior vena cava. Three of 4 patients who underwent thoracotomy in our series had large complex right-sided hernias. We performed a left-sided thoracotomy in 1 patient who required concurrent rib resections and chest wall reconstruction due to traumatic rib fractures that were displaced into the thoracic cavity. Our single laparotomy was in a patient who had evidence of bowel ischemia requiring a bowel resection. In cases requiring complex repairs or bowel resections, we strongly recommend an open approach.

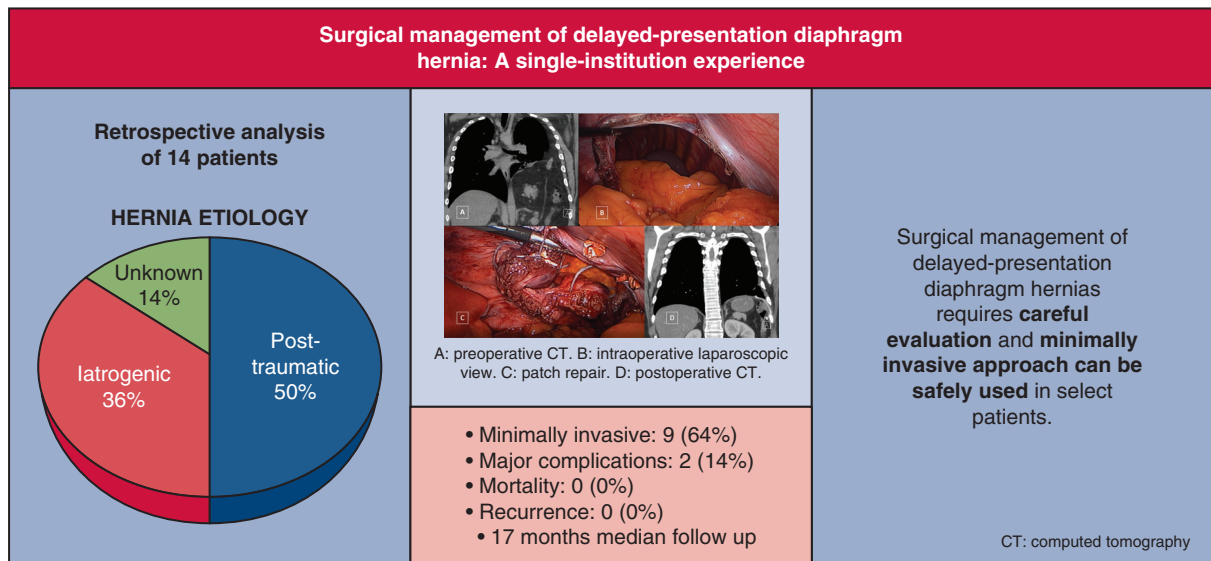


FIGURE 1. Summarizing objectives, methods, results, and outcomes of this study. CT, Computed tomography.

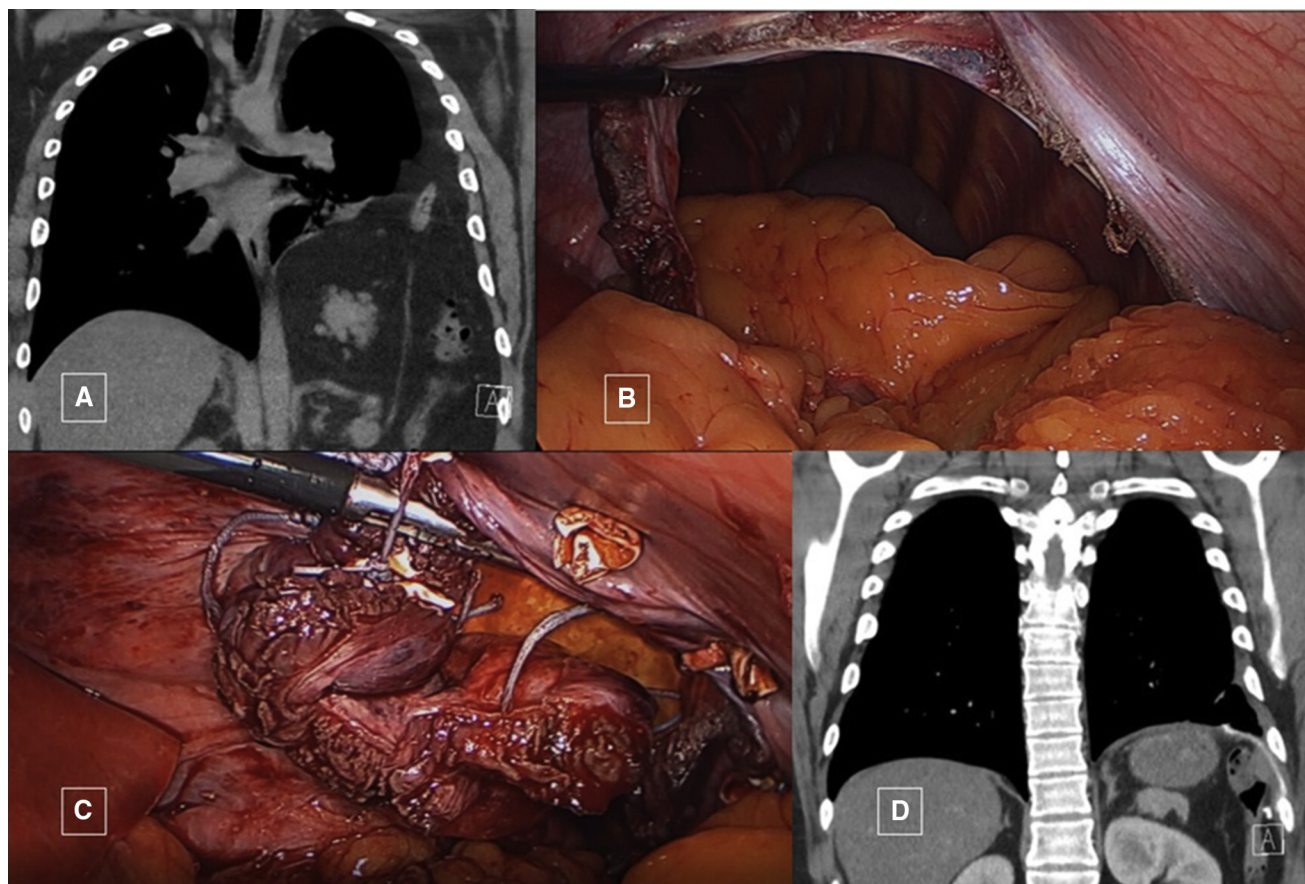


FIGURE 2. A, Preoperative CT scan. B, Intraoperative laparoscopic view. C, Patch repair. D, Postoperative CT (2 months after repair).

There are numerous studies reporting minimally invasive repair of acute traumatic diaphragm rupture in the absence of polytrauma.^{23,24} However, acute diaphragmatic rupture and chronic diaphragmatic hernias are clinically and technically different problems. The main consideration in acute diaphragm rupture is the presence of associated injuries, and a primary repair is usually sufficient.^{25,26} Chronic herniation of abdominal viscera into the chest cavity results in significant intrathoracic adhesions, very large diaphragmatic defects, and loss of abdominal domain. These 3 anatomic characteristics are the primary contributing factors to the technical difficulty of repairing chronic diaphragmatic hernias and differentiate them from acute diaphragmatic rupture.

Our preference is to repair chronic diaphragmatic hernias with a synthetic patch as we did in 12 of 14 patients (86%) unless the defect is small. We generally place patch material in hernia defects that are larger than 3 cm. We have occasionally closed slightly larger defects primarily if the ability to achieve a tension-free repair is unquestionable. To date, there are no clear criteria for patch or mesh repair.^{1,5,8,9,12} We believe using a patch is the safest technique for a tension-free and durable repair of chronic diaphragmatic

hernias because the defects are often large. When placing a patch, we always use a smooth surfaced polytetrafluoroethylene patch to reduce the possibility of fistulization. One of our patients had a delayed bowel fistula several weeks after discharge from his index operation and required reoperation with patch removal. This patient had the largest and most chronic hernia (38 years) in our series; we repaired his hernia via a right thoracotomy, and surgery was extremely challenging because of the lack of abdominal domain. He eventually recovered after 2 years and multiple operations. [Table 4](#) summarizes published series with approach, use of patch or mesh, and results.

As a precaution, all of our patients with herniated colon undergo a prophylactic bowel preparation. To date, we have not had a problem with intraoperatively detected bowel injury. In the case of bowel perforation, ischemic bowel, or intraoperatively identified bowel injury in a patient with a large diaphragmatic defect, we recommend completing the repair with biologic nonabsorbable mesh (Covidien Permacol Surgical Implant, Medtronic).

The timing of repair depends on presenting symptoms, the patient's clinical status and comorbidities, the size of the diaphragmatic defect, and the contents of the hernia.

TABLE 4. Existing case series of delayed-presentation diaphragm hernias

Author, year (reference)	n	Etiology	Surgical approach (n)	Mesh or patch	Complications (n, %)	Follow-up (mo)*	Recurrence
Davoodabadi, 2012 ⁸	6	Trauma	Thoracotomy (6)	Yes (1) No (5)	Death (1, 17%)	N/A	N/A
Tabrizian, 2012 ⁹	10	Iatrogenic	Laparotomy (10)	Yes (3) No (7)	N/A	36 (10-167)	1
Ganie, 2013 ²	11	Trauma	Thoracotomy (2) Thoracotomy + Laparotomy (9)	No	Death (3, 27%) Anastomotic leak, exploration (1, 9%)	N/A	1
Liao, 2016 ⁷	24	Trauma	Open (19) Laparoscopy (5)	No	Unspecified (5, 21%)	16 (6-24)	0
Lu, 2016 ¹⁰	6	Trauma	Thoracotomy (4) Laparotomy (2)	No	N/A	N/A	0
Testini, 2017 ¹	5	Trauma (1) Iatrogenic (1) Unknown (3)	Laparotomy (1) Thoraco-abdominal (1) Thoracotomy (1) Laparoscopy (1) Unspecified (1)	Yes (3) No (2)	N/A	N/A	0
Manzini, 2019 ¹¹	5	Iatrogenic	Laparotomy (3)	No	N/A	22 (8-36)	0
Zhao, 2019 ⁵	40	Trauma	Thoracotomy (38) Thoraco-abdominal (2)	Yes (4) No (36)	Bowel obstruction (1, 2.5%)	N/A	1
Raakow, 2021 ¹²	5	Iatrogenic	Open (4) Laparoscopy (1)	Yes (2) No (3)	None	41 (14-62)	3
Jones (present series)	14	Trauma (7) Iatrogenic (5) Unknown (2)	Laparotomy (1) Thoracotomy (4) Laparoscopy, VATS, or both (9)	Yes (12) No (2)	Hemothorax (1, 7%) Small bowel fistula, CVA, bronchopleural fistula (1, 7%)	17 (1-192)	0

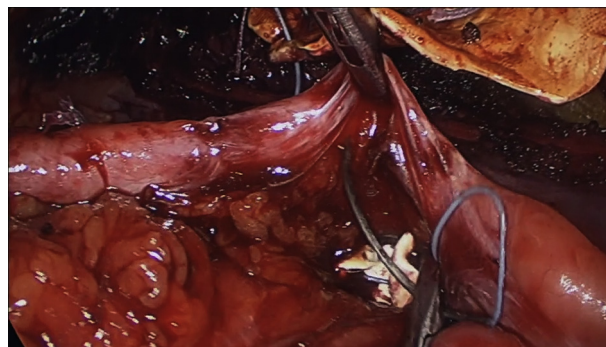
N/A, Not applicable; VATS, video-assisted thoracoscopic surgery; CVA, cerebrovascular accident. Minimally invasive approaches are in bold characters. *Median and range.

Patients who present with sepsis related to suspected bowel perforation or ischemia should undergo emergency repair via an open approach to facilitate resections as necessary and for better hemodynamic control. For patients who present with mild symptoms or asymptomatic incidentally found hernias, we typically schedule surgery as soon as they are medically optimized and at the patient's earliest convenience. We consider a more time-sensitive repair on patients who have had recent worsening of symptoms or have symptoms affecting daily activities or nutrition. We believe that small diaphragmatic defects with hollow visceral herniation are also more time-sensitive because of the potential for incarceration or strangulation.

Two patients (14%) in our series had major complications needing operative intervention: 1 in the open group and 1 in the minimally invasive group. Both patients had right-sided hernias and had technically challenging operations. The incidence of major complications in our report is consistent with the reported incidence of complications in 2 other series of 40 and 24 chronic diaphragmatic hernias (2.5% and 21%).^{5,7} It is important for surgeons to be aware of potential complications and the associated risks associated with right-sided hernias, large hernia size, and

chronicity. We had no visceral injury in any of our minimally invasive repairs. We had no operative mortality.

There are no follow-up guidelines for patients who have undergone a repair of a chronic diaphragmatic hernia. We recommend a baseline CT scan at 3 months postsurgery followed by yearly follow-up and CT imaging for 5 years if possible. The recurrence rate in our series at a median of 17 months is nil so far. Published recurrence rates range



VIDEO 1. Combined laparoscopic-video assisted thoracoscopic repair of a left sided delayed-presentation diaphragm hernia. Video available at: [https://www.jtcvs.org/article/S2666-2507\(22\)00243-7/fulltext](https://www.jtcvs.org/article/S2666-2507(22)00243-7/fulltext).

from 0% to 10% with a maximum reported median follow-up of 36 months.^{5,7,9}

Study Limitations

We cannot draw definitive conclusions on the best management of delayed-presentation diaphragm hernias because it is a rare problem and the sample size is limited. Our median follow-up is less than 2 years and is probably insufficient to determine the real recurrence rate, and we intend to follow our patients longitudinally. Additionally, we practice in a quaternary referral center and specialize in minimally invasive diaphragm surgery. Our single-institution experience and results may not be generalizable to all institutions.

CONCLUSIONS

Chronic traumatic and iatrogenic delayed-presentation diaphragm hernias are rare entities. Thoracic surgeons should tailor the surgical approach to patient characteristics, anatomic considerations, and surgeons' experience. Minimally invasive approaches are safe and effective in experienced centers and when used in well-selected patients. The [Video Abstract](#) and [Figure 1](#) summarize this study.

Conflict of Interest Statement

The authors reported no conflicts of interest.

The *Journal* policy requires editors and reviewers to disclose conflicts of interest and to decline handling or reviewing manuscripts for which they may have a conflict of interest. The editors and reviewers of this article have no conflicts of interest.

Statistical analysis was provided by Qi Wang, MS, University of Minnesota Clinical and Translational Research.

References

- Testini M, Girardi A, Isernia RM, De Palma A, Catalano G, Pezzolla A, et al. Emergency surgery due to diaphragmatic hernia: case series and review. *World J Emerg Surg.* 2017;12:23.
- Ganie FA, Lone H, Lone GN, Wani ML, Ganie SA, Wani NU, et al. Delayed presentation of traumatic diaphragmatic hernia: a diagnosis of suspicion with increased morbidity and mortality. *Trauma Mon.* 2013;18:12-6.
- Soufi M, Meillat H, Le Treut YP. Right diaphragmatic iatrogenic hernia after laparoscopic fenestration of a liver cyst: report of a case and review of the literature. *World J Emerg Surg.* 2013;8:2.
- Simon LV, Lopez RA, Burns B. *Diaphragm Rupture.* StatPearls; 2021.
- Zhao L, Han Z, Liu H, Zhang Z, Li S. Delayed traumatic diaphragmatic rupture: diagnosis and surgical treatment. *J Thorac Dis.* 2019;11:2774-7.
- Hanna WC, Ferri LE. Acute traumatic diaphragmatic injury. *Thorac Surg Clin.* 2009;19:485-9.
- Liao CH, Chu CH, Wu YT, Fu CY, Hsieh FJ, Wang SY, et al. The feasibility and efficacy of laparoscopic repair for chronic traumatic diaphragmatic herniation: introduction of a novel technique with literature review. *Hernia.* 2016;20:303-9.
- Davoodabadi A, Fakharian E, Mohammadzadeh M, Abdorrahim Kashi E, Mirzadeh AS. Blunt traumatic hernia of diaphragm with late presentation. *Arch Trauma Res.* 2012;1:89-92.
- Tabrizian P, Jibara G, Shrager B, Elsabbagh AM, Roayaie S, Schwartz ME. Diaphragmatic hernia after hepatic resection: case series at a single Western institution. *J Gastrointest Surg.* 2012;16:1910-4.
- Lu J, Wang B, Che X, Li X, Qiu G, He S, et al. Delayed traumatic diaphragmatic hernia: a case-series report and literature review. *Medicine (Baltimore).* 2016;95:e4362.
- Manzini G, Kuemmerli C, Reiner CS, Petrowsky H, Gutschow CA. Enterothorax after hepatic surgery: a single-center experience. *World J Surg.* 2019;43:902-9.
- Raakow J, Megaw IF, Schmelzle M, Schoening W, Lurje G, Biehl M, et al. Incidence, diagnosis and repair of a diaphragmatic hernia following hepatic surgery: a single center analysis of 3107 consecutive liver resections. *J Clin Med.* 2021;10:1011.
- Frantzides CT, Carlson MA. Laparoscopic repair of a penetrating injury to the diaphragm: a case report. *J Laparoendosc Surg.* 1994;4:153-6.
- Brusciano L, Izzo G, Maffettone V, Rossetti G, Renzi A, Napolitano V, et al. Laparoscopic treatment of Bochdalek hernia without the use of a mesh. *Surg Endosc.* 2003;17:1497-8.
- Chen B, Finnerty BM, Schamberg NJ, Watkins AC, DelPizzo J, Zarnegar R. Transabdominal robotic repair of a congenital right diaphragmatic hernia containing an intrathoracic kidney: a case report. *J Robot Surg.* 2015;9:357-60.
- Tessely H, Journe S, Therasse A, Hossey D, Lemaitre J. A case of colon necrosis resulting from a delayed traumatic diaphragmatic hernia. *J Surg Case Rep.* 2020;2020:rjaa101.
- Lodhia JV, Appiah S, Tcherveniakov P, Krysiak P. Diaphragmatic hernia masquerading as a pulmonary metastasis. *Ann R Coll Surg Engl.* 2015;97:e27-9.
- Hashimoto K, Obama K, Tsunoda S, Hisamori S, Nishigori T, Sakaguchi M, et al. Iatrogenic diaphragmatic hernia as a late complication of laparoscopic excisional biopsy of peritoneal nodules: a case report. *Int J Surg Case Rep.* 2020;67:169-72.
- Vertaldi S, Manigrasso M, D'Angelo S, Servillo G, De Palma GD, Milone M. Robotic repair of iatrogenic left diaphragmatic hernia. A case report. *Int J Surg Case Rep.* 2020;76:488-91.
- Alkadi H, Abbas MF, Abouramadan S, Askilany A. Iatrogenic diaphragmatic hernia after pulmonary artery banding operation through median sternotomy. *Indian J Thorac Cardiovasc Surg.* 2019;35:94-6.
- Diaz-Gutierrez I, Robbins AJ, Zhang B, Rao MV, Bhargava A, Andrade RS. Long-term results of diaphragmatic hernia repair after left ventricular assist device explantation. *Ann Thorac Surg.* 2021;112:874-9.
- Groth SS, Rueth NM, Kast T, D'Cunha J, Kelly RF, Maddaus MA, et al. Laparoscopic diaphragmatic plication for diaphragmatic paralysis and eventration: an objective evaluation of short-term and midterm results. *J Thorac Cardiovasc Surg.* 2010;139:1452-6.
- Kim JK, Desai A, Kunac A, Merchant AM, Lovoulos C. Robotic transthoracic repair of a right-sided traumatic diaphragmatic rupture. *Surg J (N Y).* 2020;6:e164-6.
- Nardini M, Jayakumar S, Elsaegh M, Dunning J. Left video-assisted thoracoscopic surgery for hemidiaphragm traumatic rupture repair. *Interact Cardiovasc Thorac Surg.* 2017;24:815-6.
- Furak J, Athanasiadi K. Diaphragm and transdiaphragmatic injuries. *J Thorac Dis.* 2019;11(Suppl 2):S152-7.
- Ties JS, Peschman JR, Moreno A, Mathiason MA, Kallies KJ, Martin RF, et al. Evolution in the management of traumatic diaphragmatic injuries: a multicenter review. *J Trauma Acute Care Surg.* 2014;76:1024-8.

Key Words: case series, chronic, delayed-presentation, diaphragm hernia, minimally invasive surgery