

Repair of deep tissue defects in the posterior talocrural region using a superficial temporal fascia free flap plus thin split-skin grafting in extensively burned patients

A retrospective case series

Xuekang Yang, MD, Hui Zhao, MS, Mengdong Liu, MD, Yue Zhang, MS, Qiaohua Chen, BCh, Zhiqiang Li, BCh, Juntao Han, PhD*, Dahai Hu, PhD*

Abstract

The aim of this study was to describe the scheme, surgical procedures, and clinical outcomes for the early repair of deep wounds of the posterior talocrural region in extensively burned patients with a method combining a superficial temporal fascia free flap with thin split-skin grafting.

From January 2013 to February 2016, 9 extensively burned patients with deep tissue defects of the posterior talocrural region were treated in our department (2 patients had bilateral deep tissue defects of the posterior talocrural region). All 11 wounds were repaired using a superficial temporal fascia free flap and thin split-skin grafting. After the operation, survival of the fascia flaps and grafted skin was observed, and the appearance and functional recovery of the grafts were evaluated. Follow-up information was reviewed, and complications were documented.

All 11 fascia flaps survived completely. Two cases of partial skin necrosis healed after the second application of skin grafts. The appearance and function of recipient sites were well restored in all patients over a follow-up period of 5 to 14 months.

Deep tissue defects of the posterior talocrural region can be effectively repaired with our method combining a superficial temporal fascia free flap with thin split-skin grafting. This method offers the advantages of a good appearance, strong resistance to infection, minimal damage at the donor site, short course of disease, and good prognosis.

Abbreviation: TBSA = total body surface area.

Keywords: burn, flap repair, free flap, skin graft, superficial temporal fascia flap

1. Introduction

In recent years, with improvements in burn wound care, the mortality rate of patients with extensive burns has decreased. Meanwhile, more attention has been paid to the clinical outcomes

of patients with extensive burns.^[1] The most effective way to improve the function of the wounded tissue is to close the wound and have the patients perform rehabilitation exercises as early as possible.^[2]

The posterior talocrural region has little subcutaneous tissue. Deep burn of this region often results in Achilles tendon exposure and medial malleolus and/or lateral malleolus bone exposure, which must be treated with flap repair.^[3] Commonly used flaps include a local flap, sural neurocutaneous flap, peroneal artery perforator flap, posterior tibial artery perforator flap, free skin flap, and others.^[4] However, the availability of tissue at the donor site can be limited.

An alternative repair approach involves the combination of a free muscle flap with a skin graft. However, patients with extensive burns likely have a higher bacterial count at the skin surface, and thus, harvesting of the deep muscle flap may result in bacterial infection in the donor site. Currently, a variety of artificial dermal matrices combined with skin grafting are available for the repair of deep wounds, but the infection risk is still questionable and the cost is very high.^[5,6]

Thus, the conventional treatment for deep damage in the posterior talocrural region in extensively burned patients usually involves long-term dressing changes until new granulation tissue forms, and then patients undergo dermatoplasty. This approach is simple and feasible, but has the disadvantages of a long treatment period and great patient suffering. Long-term wound exposure often leads to dry necrosis of tissue and bacterial

Editor: Somchai Amorniyotin.

XY, HZ, and ML contributed equally to this work.

Funding/support: This study was partly supported by the National Natural Science Foundation of China (81671910). The funders had no role in the study design, data collection and analysis, decision to publish, or preparation of the manuscript.

The authors report no conflicts of interest.

From the Department of Burns and Cutaneous Surgery, Xijing Hospital, Fourth Military Medical University, Xi'an, China.

* Correspondence: Dahai Hu and Juntao Han, Department of Burns and Cutaneous Surgery, Xijing Hospital, Fourth Military Medical University, 15 Changle Xi Road, Xi'an 710038, P.R. China (e-mails: burns@fmmu.edu.cn; hanjtrfmmu@163.com).

Copyright © 2018 the Author(s). Published by Wolters Kluwer Health, Inc. This is an open access article distributed under the terms of the Creative Commons Attribution-NonCommercial-ShareAlike 4.0 License, which allows others to remix, tweak, and build upon the work non-commercially, as long as the author is credited and the new creations are licensed under the identical terms.

Medicine (2018) 97:3(e9250)

Received: 23 May 2017 / Received in final form: 29 October 2017 / Accepted: 21 November 2017

<http://dx.doi.org/10.1097/MD.00000000000009250>

infection, which may cause a partial defect in the Achilles tendon and osteomyelitis of the medial and lateral malleolus bone. Moreover, scarring after wound healing often causes foot drop. All of these problems could seriously affect patients' quality of life.

To overcome these disadvantages, we applied a combination of a superficial temporal fascia free flap with a split thickness skin graft. Herein, we show that this method could achieve satisfactory repair effects, effectively shorten the wound healing time, and minimize the frequency of complications of these burns such as contracture, foot drop, and dysfunction.

2. Methods

2.1. Patients

From January 2013 to February 2016, a total of 9 patients with extensive burns (6 males and 3 females, age ranging from 14 to 65 years) causing a deep tissue defect of the posterior talocrural region were treated in our department. Each patient provided informed consent in accordance with the requirements of the Research Ethics Committee in Xijing Hospital (Permit Number: fmmu-13-0711).

2.2. Preoperative preparation

Before the operation, a Doppler blood flow survey or color Doppler ultrasound was used to probe and mark the blood vessels, measure vessel diameters, display vessel shapes and vascular origins, and conduct a hemodynamics examination. According to the location and size of the wound, the length of the vascular pedicle, the diameter of vessels and other factors at the recipient site, the posterior tibial artery and posterior tibial vein were selected. If necessary, the ipsilateral great saphenous vein could be selected.

2.3. Surgical procedure

The surgical process consisted of 4 steps. The first step was the preparation of the recipient area, including debridement of the wound and search for recipient vessels (posterior tibial artery and vein). The second step was the flap harvesting at the donor site. We planned a longitudinal incision about 2 cm in the anterosuperior part of the antilobium (the region of surface projection of the superficial temporal artery) and dissected the superficial temporal artery. Then, we judged whether the vessel condition met the requirements for vascular anastomosis. If the requirements were met, we lengthened the incision through the temporal area to the top region and then designed the "T"-shaped incision based on the size of the recipient site. After that, the scalp was separated from the subcutaneous fascia carefully and retracted to both sides. Then, the superficial temporal fascia was exposed. Next, we marked the superficial temporal fascia based on the 10% expanded size of the recipient site. After ligating and cutting the distal vessel, the superficial temporal fascia flap was carefully harvested from the distal end to the pedicle, and a fascial flap was formed that contained both the superficial temporal artery and vein. Then, the pedicle was cut after examination, and the incision at the donor site was sutured. The third step was the vascular anastomosis. Before performing the anastomosis, the fascia flap was transferred and fixed to the recipient site. Then, the end-to-end anastomosis of the superficial temporal vein and posterior tibial vein as well as the end-to-side anastomosis of the superficial temporal artery and posterior

tibial artery were performed under a microscope. When the steps described above were completed, we carefully checked and ensured that the anastomosis was unobstructed and the fascia flap blood circulation was good. After that, we ensured hemostasis, sutured and fixed the fascia flap, and inserted the indwelling rubber drainage strip. The fourth step involved skin grafting, harvesting the thin split-skin, and preparing the drainage holes. We then transplanted and fixed the skin onto the surface of the fascia flap, applied a bandage with moderate pressure, and arranged observation holes. Lastly, the affected limbs were immobilized in functional positions using braces.

2.4. Postoperative management

After the operation, the affected limb was elevated and kept warm. Medications including anticoagulant, antispasmodic, and vasodilator drugs were used systemically. At postoperative day 3, ultrasound Doppler was performed every 2 hours to confirm whether the anastomosis remained unobstructed. Then, the bandage was removed, and the dressing was changed on the 3rd day after the operation. The blood supply was observed every 4 to 8 hours until the 8th day after the operation. Once the wound had healed completely, patients were instructed to use anti-cicatricial drugs, wear a pressure garment, and gradually begin performing exercises involving joint activities.

3. Results

3.1. Patient and wound characteristics

Among the 9 extensively burned patients, 2 patients were scalded by a hot liquid, 4 patients were burned by alcohol, and 3 patients were burned by an electric arc. Seven cases had unilateral deep tissue defects, and 2 cases involved bilateral deep tissue defects of the posterior talocrural region. All these defects were complicated by Achilles tendon exposure and medial malleolus and/or lateral malleolus bone exposure. In addition, 1 case was further complicated by medial malleolus osteomyelitis. The size of the recipient area defects ranged from 3.6×5.3 to 5.2×11.7 cm. The detailed characteristics of the patients and wounds are listed in Table 1.

3.2. Treatment outcomes

All the 11 superficial temporal fascia free flaps survived completely in the 9 patients. One case of venous crisis was observed on the second day after operation, and the main clinical manifestations were discoloration of the flap and grafted skin to black. Through ultrasonic Doppler examination, a venous vascular blockage was found. After the emergency search for blood vessels, we reapplied vascular anastomosis and skin grafting. Another case of skin necrosis caused by local infection healed with regrafting and conventional dressing therapy.

The mean follow-up was 8 months (range, 2–23 months). After complete healing, the skin of the wound region was basically flat and smooth. All the patients achieved good functional recovery, and there were no abnormalities. The scars at the donor site were not obvious, and there was no case of alopecia, scarring, etc. Six months after the operation, all patients were satisfied with the treatment effects, especially the ankle function (average score, 89.6 ± 9.1 on the American Orthopaedic Foot and Ankle Society hind-foot scale) and appearance.

Table 1
Clinical data and treatment outcomes of patients.

Patient	Age, y	Gender	Burn area	Characteristics of wound	Defect size, cm ²	Characteristics of donor site	Survival condition of flap	Perioperative complications
1	42	Female	90%	Bilateral posterior talocrural region, left Achilles tendon exposure and medial malleolus bone exposure, right Achilles tendon exposure and lateral malleolus bone exposure	Left: 4.5 × 8.9 Right: 3.8 × 9.7	Second degree burn, healing after 13 d, skin was harvested 3 times	Survival	None
2	14	Male	85%	Left posterior talocrural region, left Achilles tendon exposure and medial malleolus bone exposure	4.1 × 9.2	Skin was harvested 3 times	Survival	Thrombosis of venous anastomosis on postoperative day 3, reanastomosis after vascular exploration, skin graft repeated once again
3	19	Male	70%	Left posterior talocrural region, left Achilles tendon exposure	3.6 × 5.3	None	Survival	None
4	36	Male	70%	Left posterior talocrural region, left Achilles tendon exposure and medial malleolus bone exposure	3.9 × 9.3	Second degree burn, healed after 17 d	Survival	Skin grafting was repeated
5	65	Female	75%	Bilateral posterior talocrural region, left Achilles tendon exposure and lateral malleolus bone exposure, right Achilles tendon exposure	left:4.1 × 8.6 right:3.8 × 5.7	Skin was harvested 4 times	Survival	None
6	48	Male	90%	Right posterior talocrural region, right Achilles tendon exposure and medial malleolus bone exposure	5.2 × 11.7	First degree burn, healed after 7 d, skin was harvested 4 times	Survival	None
7	25	Male	70%	Right posterior talocrural region, right Achilles tendon exposure and medial malleolus bone exposure	3.4 × 7.8	Harvesting skin 2 times	Survival	None
8	31	Female	85%	Left posterior talocrural region, left Achilles tendon exposure	4.6 × 6.4	None	Survival	None
9	27	Male	90%	Left posterior talocrural region, left Achilles tendon exposure	5.7 × 6.1	Skin was harvested 2 times	Survival	None

3.3. Typical case

A 25-year-old male patient with multiple electric arc burn wounds was admitted to our hospital at 7 hours after burn injury. The diagnosis on admission was electric arc burns with a 70% total burn surface area (TBSA). After administration of anti-shock and anti-infection medications, wound dressing, placement of multiple skin grafts, and other treatments, the patient’s condition was stable. Meanwhile, about 8% of the residual wound had not healed after 50 days of treatment. Importantly, much secretions and necrotic tissue were found in the right posterior talocrural region, and destruction of the medial malleolus bone was obvious. The results of secretion bacterial culture suggested Methicillin-resistant *Staphylococcus aureus* infection. The patient felt pain in the affected area and could not get out of bed or perform functional exercises. After surgical debridement, we found partial Achilles tendon exposure accompanied by necrosis, as well as exposure of the medial malleolus bone accompanied by osteomyelitis. The wound size was about 3.4 × 7.8 cm (Fig. 1). Then, we designed and obtained the superficial temporal fascia flap according to the wound size and sutured the incision at the donor site (Fig. 2). After that, we performed the vascular anastomosis, free flap transplantation, and thin split-skin grafting at the recipient site (Fig. 3). After surgery, the fascia flaps and grafted skin survived well (Fig. 4 A). At the 6- and 12-month follow-ups, the skin at the operated area was even, and the functional recovery was satisfactory (Fig. 4B).

4. Discussion

For extensively burned patients with deep damage in the posterior talocrural region, quick and high-quality repair of defects is difficult but necessary to maximize the functional

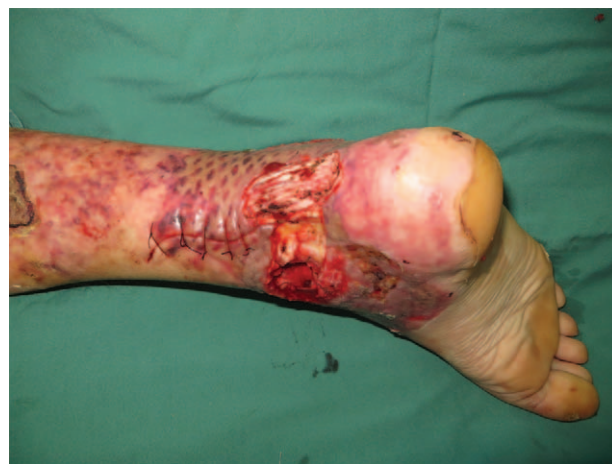

Figure 1. Characteristics of wounds of the posterior talocrural region. After surgical debridement, partial Achilles tendon exposure and malleolus bone exposure accompanied by osteomyelitis were observed. The total wound size was approximately 3.4 × 7.8 cm.

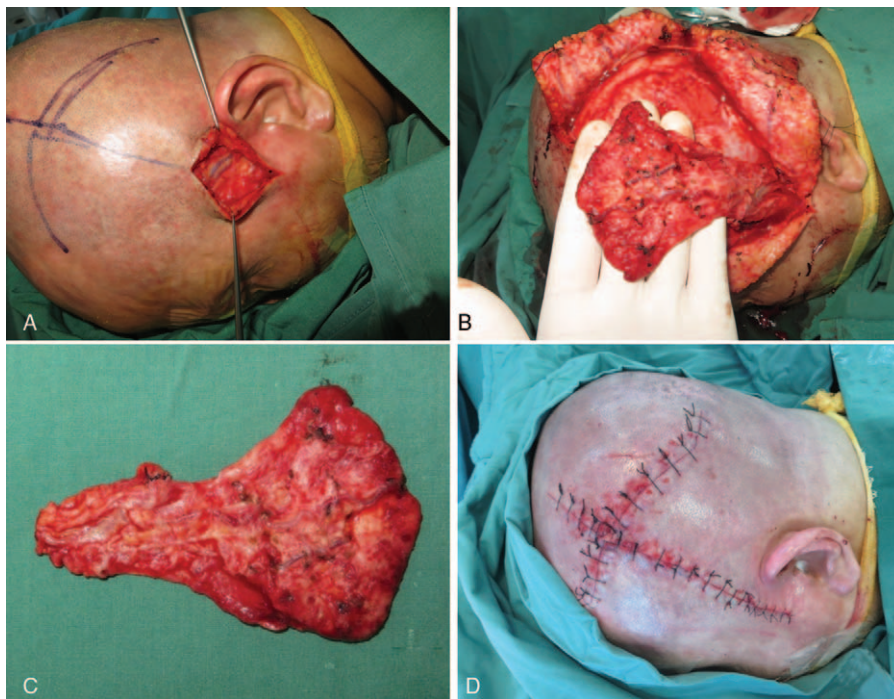


Figure 2. Harvesting of the superficial temporal fascia flap. (A) Designing a longitudinal incision about 2 cm in the anterosuperior part of the antilobium (the region of surface projection of superficial temporal artery); if the blood vessels were in good condition, a longer incision through the temporal area to the top region was made; designing the “T”-shaped incision based on the size of the recipient area. (B) Designing and separating the fascia flap according to the size of the wound. (C) Harvesting the fascia flap. (D) Suturing the incision at the donor site.

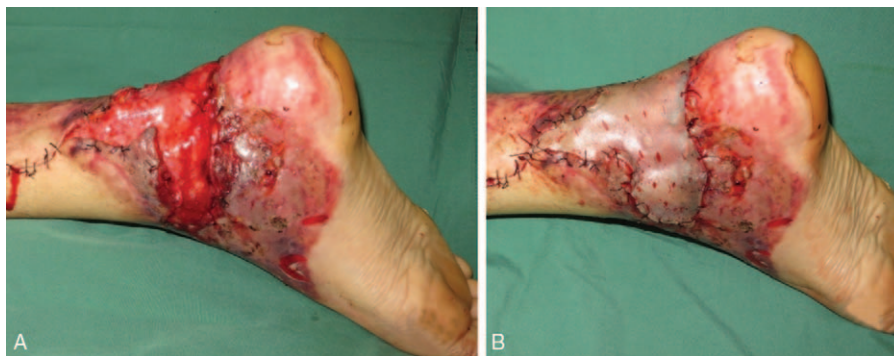

Figure 3. Superficial temporal fascia flap transplantation and skin grafting. (A) After transferring and fixing the fascia flap to the recipient site, we performed the end-to-end anastomosis of the superficial temporal vein and posterior tibial vein, as well as the end-to-side anastomosis of the superficial temporal artery and posterior tibial artery. (B) Grafting of thin split-skin.

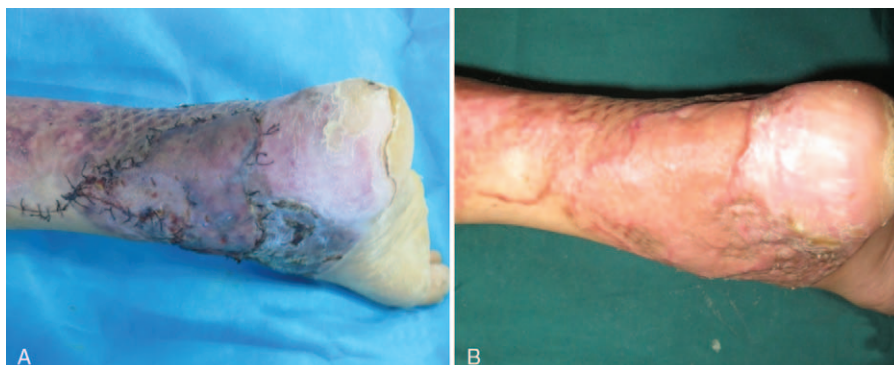

Figure 4. Treatment outcome and follow-up. (A) The fascia flap and grafted skin survived well at 1 week after operation. (B) At the 6-month follow-up, the grafted skin at the recipient site was even and without dysfunction. (C and D) Images taken at the 12-month postoperative follow-up.

recovery and improve patients' quality of life.^[7,8] In this study, we reported the design, surgical application, and clinical outcomes of a new method combining a superficial temporal fascia free flap with thin split-skin grafting for the repair of deep wounds of the posterior talocrural region in extensively burned patients.

The superficial temporal fascia flap is one of the most widely used flaps for the repair of burns and other wounds in the plastic surgery field, especially in maxillofacial surgery, based on the appropriate elasticity, extensibility, and tenacity of this flap.^[9–11] The blood supply of the superficial temporal fascia flap is derived from the superficial temporal vessels (superficial temporal artery and the superficial temporal vein), which are easy to dissect. The thickness of the superficial temporal fascia was approximately 2 to 5 mm, and thus, the function of a superficial temporal fascia flap combined with a skin graft was comparable to that of a thin skin flap. On the basis of these characteristics, the method of combining the superficial temporal fascia flap with skin grafting could be used in the repair of many types of wounds: wounds that are accompanied by joint, bone, and tendon exposure, but are not suitable for thick skin flap repair, including wounds on the palms, back, heel, instep, etc.; lower limb ulcers and dead space left by chronic osteomyelitis after debridement; defects created in facial reconstruction and other organ reconstruction that require filling material; and wounds that expose important organs or tissues, such as exposed brain tissue, vessels, nerves, etc.

The scalp has an abundant blood supply, a large number of hair follicles, and a large thickness, and can heal spontaneously even if burned or after repeated harvesting of skin.^[12,13] On the basis of these characteristics of the scalp and the limited donor site area in extensively burned patients, the method of combining the superficial temporal fascia free flap with thin split-skin grafting may be a practical way to repair a deep wound of the posterior talocrural region early in extensively burned patients. In recent years, we have successfully repaired severe defects of the posterior talocrural region in 11 cases using this method.

On the basis of our experiences, this method offers the following advantages. First, patient outcomes are better. Compared with the traditional dressing change, applying the superficial temporal fascia free flap can achieve earlier coverage of the wounds, which helps to reduce the risk of infection, alleviate the pain caused by long-term dressing change, and help patients to begin functional exercises as early as possible.^[8] In addition, the superficial temporal fascia is a dense connective tissue, and for a posterior talocrural region wound accompanied by partial Achilles tendon necrosis, it also could enhance the strength of the Achilles tendon and benefit the functional recovery of patients. Second, the location of the flap is convenient for harvesting. The superficial temporal fascia flap has an invariable anatomical relationship, and thus, harvesting the flap is not difficult. Third, the condition of the donor site is good. The options for donor sites in extensively burned patients are limited, and some donor sites (such as the anterior lateral thigh flap, dorsal broad flap, etc.) are associated with a high risk of infection.^[14] Fortunately, the superficial temporal fascia flap may be an option. Because the scalp is very thick and has an abundant blood supply, it can heal easily, even after a burn or repeated skin harvesting. In addition, harvesting the superficial temporal fascia flap rarely results in infection at the donor site because of the abundant blood supply in the head. Fourth, the appearance of the recipient site is good. Repairing the posterior talocrural region by the conventional flap often cause a bloated appearance, and thus, creates a need for multiple fat removing surgeries. By contrast, the

superficial temporal fascia flap is very thin, and so the appearance of the recipient area is satisfactory. Fifth, the superficial temporal fascia flap offers the advantage of good resistance to infection based on its rich blood supply, which also can support wound healing when a posterior talocrural region wound is complicated by bacterial infection or osteomyelitis.^[10]

However, our method has some limitations. First, the coverage area of the superficial temporal fascia flap is limited. The maximum flap size in our case series was about 5.2×11.7 cm, which was beyond the range of the superficial temporal fascia, and thus, in addition to the superficial temporal fascia, we also removed part of the galea aponeurotica. Second, vascular anastomosis presents some difficulty. The difficulty of vein anastomosis is mainly caused by the donor vein (superficial temporal vein). First, superficial temporal veins are single veins, and thus, we must ensure the patency of the anastomosis. Second, the superficial temporal vein is fine, and its vascular walls are very thin, which increases the difficulty of anastomosis. The superficial temporal vein should be stripped as close as possible to the tragus to increase the vein diameter, which will facilitate anastomosis. Third, postoperative observation of the blood circulation of the fascia flap was difficult. After free transplantation of the superficial temporal fascia free flap and thin split-skin grafting, the operated area should be wrapped with dressing, which makes it difficult to observe the blood circulation of the fascia flap with the naked eye. We propose that ultrasonic Doppler examination is necessary. Fourth, traditional pressure dressing after skin grafting is not suitable for the operation area in our present cases, which may affect the survival rate of the skin grafts.^[15] Fifth, the superficial temporal fascia flap plays an important role in the field of plastic surgery, as it can be used for eyebrow reconstruction, ear reconstruction, and so on.^[10,16] Therefore, we must weigh the advantages and disadvantages very carefully and conduct a comprehensive preoperative assessment. Furthermore, finding good recipient vessels may be challenging for patients who have suffered from electric burns, and we should make a full assessment of the vascular condition before surgery.

To best of our knowledge, several other donor sites can be chosen for free fascial flaps, including the radial forearm fascia, serratus anterior fascia, lateral arm fascia, scapular fascia, fascia lata flap, and others.^[17] Each fascial flap has its own advantages and disadvantages. Compared with the superficial temporal fascia flap, the other fascial flaps mentioned above may provide greater cutting area and better vascular anastomosis condition. However, for patients with extensive burns, harvesting of a subcutaneous fascial flap could lead to bacterial infection at the donor site, due to a higher bacterial count in the skin surface. In contrast, harvesting the superficial temporal fascia flap rarely results in infection at the donor site, due to the abundant blood supply in the head. Furthermore, harvesting the superficial temporal fascia flap may facilitate a concealed surgical incision that will be covered by new hair.

In conclusion, the method of combining the superficial temporal fascia free flap with thin split-skin grafting represents a satisfactory approach for the repair of deep damage in the posterior talocrural region in patients with extensive burns. This method has advantages such as the good appearance of the recipient site, strong resistance to infection, little damage at the donor site, short course of disease, and good outcomes. However, advanced microsurgical skills are necessary due to the difficulty of intraoperative vascular anastomosis and postoperative blood circulation observation.

References

- [1] Osborne CL, Meyer WJ 3rd, Ottenbacher KJ, et al. Burn patients' return to daily activities and participation as defined by the International Classification of Functioning, Disability and Health: a systematic review. *Burns* 2017;43:700–14.
- [2] Martin L, Byrnes M, McGarry S, et al. Posttraumatic growth after burn in adults: an integrative literature review. *Burns* 2017;43:459–70.
- [3] Carty MJ, Blazar PE. Complex flexor and extensor tendon injuries. *Hand Clin* 2013;29:283–93.
- [4] Orgill DP, Ogawa R. Current methods of burn reconstruction. *Plast Reconstr Surg* 2013;131:827e–36e.
- [5] Ellis CV, Kulber DA. Acellular dermal matrices in hand reconstruction. *Plast Reconstr Surg* 2012;130(5 Suppl 2):256S–69S.
- [6] Iorio ML, Shuck J, Attinger CE. Wound healing in the upper and lower extremities: a systematic review on the use of acellular dermal matrices. *Plast Reconstr Surg* 2012;130(5 Suppl 2):232S–41S.
- [7] Lin SY, Chang JK, Chen PC, et al. Hand function measures for burn patients: a literature review. *Burns* 2013;39:16–23.
- [8] Rowan MP, Cancio LC, Elster EA, et al. Burn wound healing and treatment: review and advancements. *Crit Care* 2015;19:243.
- [9] Sari E, Ozakpinar HR, Tellioglu AT. New autologous material for the frontalis suspension technique: superficial temporal fascia. *Int J Ophthalmol* 2016;9:315–7.
- [10] Zhou R, Wang C, Qian Y, et al. Combined flaps based on the superficial temporal vascular system for reconstruction of facial defects. *J Plast Reconstr Aesthet Surg* 2015;68:1235–41.
- [11] Tan O. Turnover superficial temporal fascia flap: a galeopericranial-based random flap for coverage of vertex defects on the scalp. *Dermatol Surg* 2013;39:658–60.
- [12] Roodbergen DT, Vloemans AF, Rashaan ZM, et al. The scalp as a donor site for skin grafting in burns: retrospective study on complications. *Burns Trauma* 2016;4:20.
- [13] Sosin M, Ceradini DJ, Levine JP, et al. Total face, eyelids, ears, scalp, and skeletal subunit transplant: a reconstructive solution for the full face and total scalp burn. *Plast Reconstr Surg* 2016;138:205–19.
- [14] Johnston BR, Ha AY, Kwan D. Surgical management of chronic wounds. *R I Med J* 2016;99:30–3.
- [15] Maver T, Maver U, Kleinschek KS, et al. Advanced therapies of skin injuries. *Wien Klinische Wochenschr* 2015;127(Suppl 5): S187–98.
- [16] Patel PA, Chen W, Wilkening MW, et al. Extended composite temporoparietal fascial flap: clinical implications for tissue engineering in mandibular reconstruction. *J Craniofac Surg* 2013;24: 273–7.
- [17] Ulrich D, Fuchs P, Bozkurt A, et al. Free serratus anterior fascia flap for reconstruction of hand and finger defects. *Arch Orthop Trauma Surg* 2010;130:217–22.