

# Postherpetic Comedones in Two Chinese Han Patients

Bo Wang<sup>1</sup>, Jie Zheng<sup>1</sup>, Hong-Wei Wang<sup>2</sup>

<sup>1</sup>Department of Dermatology, Ruijin Hospital, School of Medicine, Shanghai Jiaotong University, Shanghai 200025, China

<sup>2</sup>Department of Dermatology, Huadong Hospital, Shanghai Medical College, Fudan University, Shanghai 200040, China

**Key words:** Comedone; Herpes Zoster; Wolf's Postherpetic Isotopic Response

Wolf's postherpetic isotopic response (PHIR) describes the occurrence of a new lesion at the site of a healed herpetic lesion.<sup>[1]</sup> It is more commonly seen after infection by varicella-zoster virus (VZV) than herpes simplex virus.<sup>[2]</sup> Such postherpetic lesions present with a broad spectrum from inflammatory diseases to malignancies. Only 11 cases of comedones after VZV infections are reported by our literature review.<sup>[3]</sup> A rare case was reported in the Asian population. Here, we reported two cases of Chinese Han men with postherpetic comedones that were consistent with Wolf's PHIR.

A 76-year-old Chinese Han male patient presented with 2-week history of pigmented papules eruption on the left forehead. The patient also reported intense intermittent stabbing pain (visual analog scale = 8–9). Six weeks before, patient was admitted due to a herpes zoster infection involving the same area where he was treated with 2-week course of oral valacyclovir (0.3 g, bid). Previous lesions presented with erythema, small vesicles, erosion, and crusting. Intense pain occurred 1-week after lesion disappeared and new lesions of comedones erupted thereafter. Physical examination showed multiple dense comedones on top of yellow coalesced papules on the left forehead. The distribution of lesions is consistent with trigeminal ophthalmic branch dermatome [Figure 1a and 1b]. Few comedones were extracted and keratin-rich materials were yielded.

Another is a 55-year-old Chinese Han man presented with a 6-month history of papules with central pigmentation on the right side of the face. No additional self-recognizable symptom was reported. Medical history was significant for a herpes zoster infection involving the same lesion area 8-month before this manifestation. Previous lesions were treated with 2-week course of oral valacyclovir (0.3 g, tid). The patient reported no previous history of comedones and

acnes. Physical examination revealed 14 isolated comedones on the right side of the face, consistent with trigeminal mandibular branch dermatome [Figure 1c]. The contralateral side of the face was spared [Figure 1d].

Both cases are consistent with a clinical diagnosis of postherpetic comedones that can be explained by Wolf's PHIR. No biopsy was made because of the benign nature of this disorder. Differential diagnosis shall include (1) Favre-Racouchot syndrome (nodular elastosis with cysts and comedones) that tends to affect bilateral forehead and cheeks due to solar damage; (2) comedonal acne that often affects younger individuals with an increased inflammatory response; (3) nevus acneformis, which is a rare, congenital disorder affecting face, neck and chest with dark keratin plugs.

It is postulated that local decrease of nerve fibers by viral infections results in a dysregulation of neuro-immune homeostasis.<sup>[4]</sup> It is reported that the number of Langerhans cells, a key mediator in neuro-immune crosstalk, is significantly decreased in postherpetic lesions.<sup>[5]</sup> Such balanced neuro-immune regulation is key to the local immunity; any disturbance of such homeostasis might be involved in the pathogenesis of many skin inflammatory disorder and even malignancies. The exact molecular mechanism remains unknown; a careful immunoprofiling of postherpetic lesions might be the next step to further our understanding to such spectrum of disorders. To clinicians, a careful review of medical history will be very helpful to identify the underlying cause.

**Address for correspondence:** Dr. Hong-Wei Wang, Department of Dermatology, Huadong Hospital, Shanghai Medical College, Fudan University, 221 West Yan An Rd., Shanghai 200040, China  
E-Mail: hongweiwang2005@aliyun.com

This is an open access article distributed under the terms of the Creative Commons Attribution-NonCommercial-ShareAlike 3.0 License, which allows others to remix, tweak, and build upon the work non-commercially, as long as the author is credited and the new creations are licensed under the identical terms.

**For reprints contact:** reprints@medknow.com

© 2017 Chinese Medical Journal | Produced by Wolters Kluwer - Medknow

**Received:** 28-02-2017 **Edited by:** Peng Lyu  
**How to cite this article:** Wang B, Zheng J, Wang HW. Postherpetic Comedones in Two Chinese Han Patients. Chin Med J 2017;130:1615-6.

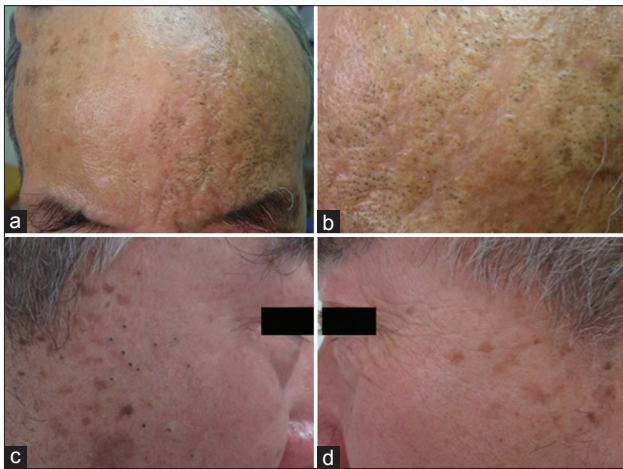
## Access this article online

### Quick Response Code:



**Website:**  
www.cmj.org

**DOI:**  
10.4103/0366-6999.208244



**Figure 1:** Clinical manifestations of two patients with postherpetic comedones. (a) A 76-year-old man with lesions on left trigeminal V1 dermatome. (b) A magnified image of lesions in Figure 1a. (c) A 55-year-old man with lesions on right trigeminal V3 dermatome. (d) Contralateral side of Figure 1c remained involvement.

### Declaration of patient consent

The authors certify that they have obtained all appropriate patient consent forms. In the form the patients have given their consent for their images and other clinical information to be reported in the journal. The patients understand that

their names and initials will not be published and due efforts will be made to conceal their identity, but anonymity cannot be guaranteed.

### Financial support and sponsorship

This work is supported by a grant from the National Natural Science Foundation of China (No. 81572671).

### Conflicts of interest

There are no conflicts of interest.

### REFERENCES

1. Wolf R, Wolf D, Ruocco E, Brunetti G, Ruocco V. Wolf's isotopic response. *Clin Dermatol* 2011;29:237-40. doi: 10.1016/j.clindermatol.2010.09.015.
2. Zhai XY, Cheng RY, Kong LT, Yang L, Li JL, Ding SJ, *et al.* A study on the connection between the incidence of postherpetic neuralgia and serum ionized calcium. *Chin Med J* 2015;128:3106-8. doi: 10.4103/0366-6999.169108.
3. Sanchez-Salas MP. Appearance of comedones at the site of healed herpes zoster: Wolf's isotopic response. *Int J Dermatol* 2011;50:633-4. doi: 10.1111/j.1365-4632.2009.04439.x.
4. Yin JJ, Hu XQ, Mao ZF, Bao J, Qiu W, Lu ZQ, *et al.* Neutralization of interleukin-9 decreasing mast cells infiltration in experimental autoimmune encephalomyelitis. *Chin Med J* 2017;130:964-71. doi: 10.4103/0366-6999.204110.
5. Oaklander AL, Stocks EA, Mouton PR. Number of Langerhans immune cells in painful and non-painful human skin after shingles. *Arch Dermatol Res* 2003;294:529-35. doi: 10.1007/s00403-002-0362-7.