

CASE REPORT

Hyperthyroidism secondary to a primary mediastinal goiter with normal functional cervical thyroid gland

Asma Kardi¹ | Ibtissem Oueslati¹  | Meriem Yazidi¹  | Mohamed Sadok Boudaya² | Nadia Znaidi³ | Melika Chihaoui¹ 

¹Department of Endocrinology, Faculty of Medicine, La Rabta University Hospital, University of Tunis-El Manar, Tunis, Tunisia

²Department of Surgery, Faculty of Medicine, Charles Nicolle University Hospital, University of Tunis-El Manar, Tunis, Tunisia

³Laboratory of Pathology, Faculty of Medicine, Charles Nicolle University Hospital, University of Tunis-El Manar, Tunis, Tunisia

Correspondence

Ibtissem Oueslati, Rue JbelLakhdar, La RabtaJebbari 1007, Tunis, Tunisia.
Email: ouesibtissem@gmail.com

Funding information

None

Abstract

Primary mediastinal goiter is extremely uncommon. The majority of primary mediastinal goiters were reported as incidental findings on chest imaging of asymptomatic patients. Symptoms related to compression of adjacent structures or hyperthyroidism were rarely described. Herein we report a case of hyperthyroidism secondary to a primary mediastinal goiter.

KEYWORDS

hyperthyroidism, primary mediastinal goiter, surgery, thyroid scintigraphy

1 | INTRODUCTION

Primary mediastinal goiter is an extremely uncommon entity. It is defined as an ectopic thyroid tissue resulting from abnormal migration of the developing thyroid from the thyroid anlage region to its definitive location during embryonic life. The majority of primary mediastinal goiters were reported as incidental findings on chest imaging of asymptomatic patients.¹ Symptoms related to compression of adjacent structures or hyperthyroidism were rarely described.

Herein, we report a case of subclinical hyperthyroidism secondary to a primary mediastinal goiter.

2 | CASE PRESENTATION

A 50-year-old woman was referred to our department in 2017 for subclinical hyperthyroidism. Her past medical history included a type 2 diabetes mellitus treated with insulin and metformin and a thyroid isthmusectomy in 2001 for a solitary isthmus nodule measuring 35 × 53 × 48 mm. The histopathological findings revealed a benign thyroid nodule.

The patient presented with palpitations and hand tremors for four months. Neither dysphagia nor dyspnea nor hoarseness were reported. She was not taking any drugs.

On physical examination, she had a body weight of 85 kg, a body height of 162 cm corresponding to a body mass index of 32.4 kg/m², a blood pressure of 130/80 mmHg, a heart rate of 95 beats/min, and a homogeneous normal thyroid gland. Other systemic and regional examinations did not show any abnormalities.

Thyroid function tests revealed subclinical hyperthyroidism with a thyroid-stimulating hormone (TSH) level of 0.04 mIU/L (normal range: 0.35–4.95) and a free thyroxine (FT4) level of 1 ng/dl (normal range: 0.7–1.5). Thyroid peroxidase antibodies and thyrotropin receptor antibodies were negative.

Thyroid ultrasound showed a normal-sized thyroid gland with a 7.5 mm nodule classified TI-RADS II and a voluminous anterior mediastinal mass of 75 mm, hyperechoic, heterogeneous with multiple calcifications. Cervico-thoracic computed tomography scan revealed a 120 × 70 × 128 mm anterior mediastinal mass independent from the thyroid gland, containing multiple calcifications, with a large tight contact with the aortic arch, the supra-aortic trunks, and the superior vena cava (Figure 1).

The patient was treated with methimazole 5 mg one tablet per day. A total median sternotomy was performed. Peroperative exploration evidenced a voluminous polycyclic highly vascularized mediastinal mass with a large size of 12 cm compressing adjacent structure without local invasion. The lower pole and the left side of the mass were firstly freed; then, careful dissection was performed with feeding vessels ligation enabling complete resection of the mass. There were no vascular or tissue connections between the mass and the thyroid gland. The feeding artery was dependent of intrathoracic vessels. Macroscopically, it was a voluminous mass with a colloid aspect measuring 130 × 100 × 50 mm. The histopathological findings revealed multinodular colloid hyperplasia with no signs of malignancy (Figure 2). There was no evidence of lymphocytic thyroiditis.

The patient had an uncomplicated recovery, and a persistent euthyroidism was obtained after surgery and anti-thyroid drug discontinuation.

3 | DISCUSSION

The development of the thyroid gland starts at the third week of gestation. The thyroid diverticulum, derived from endodermal cells of the primitive pharynx, migrates caudally along with the midline to its final destination in the neck in front of the trachea. Defective thyroid anlage migration results in an ectopic thyroid gland. Molecular and genetic mechanisms have been evoked in this pathologic condition that remains poorly explained.^{2,3}

Primary mediastinal goiter is considered according to the Rives classification as an aberrant goiter.⁴ It lacks connection with the cervical thyroid gland and receives its blood supply from mediastinal vessels; contrarily to secondary intrathoracic goiter which presents the extension of cervical thyroid to the mediastinum.⁵ Primary mediastinal goiter is extremely rare representing only 1% of substernal goiters.⁶

The majority of patients with primary mediastinal goiter are asymptomatic. The mediastinal mass is reported as an incidental finding of chest imaging. In some patients, compression of adjacent structures induces symptoms such as respiratory (eg, dyspnea, stridor, raspy cough, wheezing), vascular (eg, superior vena cava syndrome), or neurological manifestations (eg, hoarseness, Horner's syndrome), dysphagia, or voice changes. However, thyrotoxicosis as in our case is rarely reported.⁷ The restoration of euthyroidism after the complete resection of the mediastinal mass supports that this mass was the cause of hyperthyroidism.

In our patient, the cervical ultrasound revealed a mediastinal mass. However, its sensitivity in the evaluation of primary mediastinal goiter is poor. Thoracic computed tomography scan is the imaging modality of choice in evaluating mediastinal tumors.^{8,9} It defines the extent of the mass and its relationship with surrounding structures and evaluates its nature based on lesion composition, pointing toward its thyroid nature by recognizing the primary mediastinal goiter as a heterogeneous multicystic mass containing calcifications, with an intense enhancement following intravenous administration of iodine and independent from the cervical thyroid gland.⁷ Magnetic resonance imaging is indicated in patients with contraindications for contrast-enhanced computed tomography scan, such as severe contrast allergy, renal failure, and pregnancy. It can be used to better plan the surgical technique. Due to its superior resolution of soft tissue structures compared with computed tomography, it helps in case of diagnostic difficulties to distinguish thymic and other malignant tumors from benign lesions and to detect invasion of the adjacent structures.⁹

In our case, a computed tomography scan was sufficient to establish the diagnosis of primary mediastinal goiter and to define its extent. Thyroid scintigraphy is also useful for the diagnosis of primary mediastinal goiter, but it is not currently used in the diagnosis of mediastinal masses.⁷ Its accuracy in discerning primary mediastinal goiter from other masses is about 70%.¹⁰ If performed in our case, it would have confirmed the hyperfunction of the primary mediastinal goiter parenchyma. Nevertheless, the regression of hyperthyroidism after surgery is consistent with the diagnosis of hyperthyroidism secondary to the primary mediastinal multinodular goiter.

FIGURE 1 Axial CT scan section showing the anterior mediastinal mass

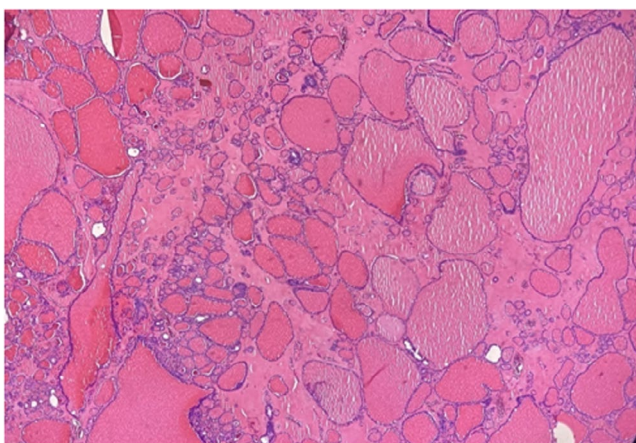
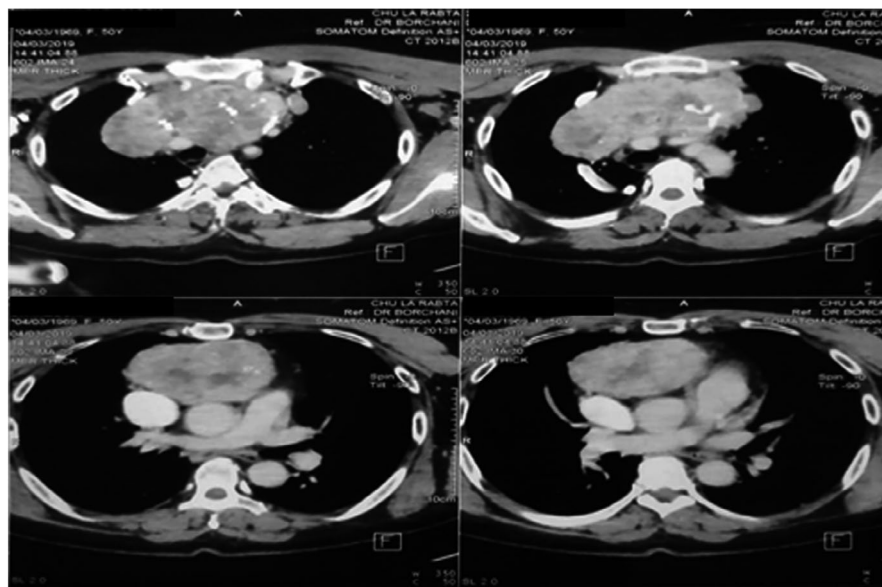


FIGURE 2 Histological examination of the mediastinal mass showing thyroid follicles

Surgery is largely indicated in primary mediastinal goiter even in asymptomatic patients.¹¹⁻¹⁴ These masses tend to grow and may present consequently life-threatening respiratory distress that could be avoided by early surgical intervention. In addition, it can be a malignant tumor. Charles et al¹⁵ proposed a 3-grade classification system of retrosternal goiters based on their relationship with the aortic arch and the right atrium, to provide a common standard for preoperative planning of surgery. Optimal teamwork among medical, radiological, anesthesiological, and surgical specialties is required.

Furthermore, the tumor excision should be performed by an experienced surgeon to avoid as much as possible surgical complications such as recurrent laryngeal nerve injury, infection, hemorrhage, injuries of trachea, esophagus, phrenic nerve, and even death.¹⁶

Radioiodine ablation can reduce the goiter volume by 30%,¹⁷ but its effect is unpredictable and it implies a possible acute reaction causing airway obstruction.^{18,19} This method is not recommended for the management of primary mediastinal goiter, but it remains the only alternative when there are medical contraindications to surgery.¹⁶⁻¹⁸

In our case, removal of the mediastinal mass required a median sternotomy due to its location and its close contact with adjacent structures. The mass was completely independent of the cervical thyroid gland. Neither preoperative nor postoperative complications were noted.

The precise histological diagnosis of primary mediastinal goiter is obtained after tumorectomy. In our patient, the histopathological findings revealed multinodular colloid hyperplasia with no signs of malignancy. In the literature, some authors reported that patients with retrosternal goiters are at increased risk for malignant transformation,²⁰ while others did not find any substantial data to show that the incidence of cancer is higher in substernal than in cervical goiters.¹³

4 | CONCLUSION

Primary mediastinal goiter is a rare condition. Hyperthyroidism induced by this ectopic thyroid tissue with a normal functional cervical thyroid gland was rarely reported. Scintigraphy enables the confirmation of its hyperfunctional pattern. Surgery is indicated in both symptomatic and asymptomatic patients with primary mediastinal goiter in view of the risks of compression of adjacent structures and malignant transformation.

ACKNOWLEDGMENT

None.

CONFLICTS OF INTEREST

The authors declare that they have no conflicts of interest.

AUTHOR CONTRIBUTIONS

IO and AK contributed to conception and design, acquisition and interpretation of data, and manuscript creation and drafting; MC contributed to the critical revision of the article for important intellectual content; all authors were involved in the management of this patient, the revision of the manuscript, and approved the final version.

ETHICAL APPROVAL

Ethical approval for this case report was not required.

CONSENT

A written informed consent was obtained from the patient for the publication of this report.

DATA AVAILABILITY STATEMENT

No data were available.

ORCID

Ibtissem Oueslati  <https://orcid.org/0000-0002-4278-9447>

Meriem Yazidi  <https://orcid.org/0000-0002-4239-5229>

Melika Chihaoui  <https://orcid.org/0000-0001-7991-9885>

REFERENCES

- Shah BC, Ravichand CS, Juluri S, et al. Ectopic thyroid cancer. *Ann Thorac Cardiovasc Surg.* 2007;13(2):122-124.
- Nettore IC, Cacace V, De Fusco C, et al. The molecular causes of thyroid dysgenesis: a systematic review. *J Endocrinol Invest.* 2013;36(8):654-664.
- De Felice M, Di Lauro R. Thyroid development and its disorders: genetics and molecular mechanisms. *Endocr Rev.* 2004;25(5):722-746.
- Rives JD. Mediastinal aberrant goiter. *Ann Surg.* 1947;126(5):797-810.
- Foroulis CN, Rammos KS, Sileli MN, et al. Primary intrathoracic goiter: a rare and potentially serious entity. *Thyroid.* 2009;19(3):213-218.
- Gamblin TC, Jennings GR, Christie DB, et al. Ectopic thyroid. *Ann Thorac Surg.* 2003;75(6):1952-1953.
- Oueriachi FE, Hammoumi MME, Arsalane A, et al. Primary Mediastinal Goiters. *Springerplus.* 2014;3:503.
- Gentili F, Pelini V, Lucii G, et al. Update in diagnostic imaging of the thymus and anterior mediastinal masses. *Gland Surgery.* 2019;8(3):S188.
- Parekh M, Balasubramanya R. Chest and Mediastinal Imaging. [Updated 2020 Oct 27]. In: StatPearls. Treasure Island (FL): StatPearls Publishing; 2021 Jan-. Available from: <https://www.ncbi.nlm.nih.gov/books/NBK559145/>
- Ignjatović M. Intratoraksne strume [Intrathoracic goiter]. *Vojnosanit Pregl.* 2001;58(1):47-63.
- Knobel M. An overview of retrosternal goiter. *J Endocrinol Invest.* 2021;44(4):679-691.
- Hashmi SM, Premachandra DJ, Bennett AMD, et al. Management of retrosternal goitres: results of early surgical intervention to prevent airway morbidity, and a review of the English literature. *J Laryngol Otol.* 2006;120(8):644-649.
- White ML, Doherty GM, Gauger PG. Evidence-based surgical management of substernal goiter. *World J Surg.* 2008;32(7):1285-1300.
- Landerholm K, Järhult J. Should asymptomatic retrosternal goitre be left untreated? A prospective single-centre study. *Scand J Surg.* 2015;104(2):92-95.
- Huins CT, Georgalas C, Mehrzad H, et al. A new classification system for retrosternal goitre based on a systematic review of its complications and management. *Int J Surg.* 2008;6(1):71-76.
- Simó R, Ij N, Vander Poorten V, et al. Surgical management of intrathoracic goiters. *Eur Arch Otorhinolaryngol.* 2019;276(2):305-314.
- Bonnema SJ, Knudsen DU, Bertelsen H, et al. Does radioiodine therapy have an equal effect on substernal and cervical goiter volumes? Evaluation by magnetic resonance imaging. *Thyroid.* 2002;12(4):313-317.
- Hegedüs L, Bonnema SJ. Approach to management of the patient with primary or secondary intrathoracic goiter. *J Clin Endocrinol Metab.* 2010;95(12):5155-5162.
- Hanson MA, Shaha AR, Wu JX. Surgical approach to the substernal goiter. *Best Pract Res Clin Endocrinol Metab.* 2019;33(4):101312.
- Hardy RG, Bliss RD, Lennard TJ. Retrosternal goiter: the case for operation in all patients. *Ann R Coll Surg Engl.* 2009;91:8-9.

How to cite this article: Kardi A, Oueslati I, Yazidi M, Sadok Boudaya M, Znaidi N, Chihaoui M. Hyperthyroidism secondary to a primary mediastinal goiter with normal functional cervical thyroid gland. *Clin Case Rep.* 2021;9:e05167. doi:[10.1002/ccr3.5167](https://doi.org/10.1002/ccr3.5167)