

Contents lists available at [ScienceDirect](http://www.sciencedirect.com)

International Journal of Surgery Case Reports

journal homepage: www.casereports.com

Transitional mesh repair for large incisional hernia in the elderly



Masahiko Kawaguchi*, Hiroshi Ueno, Yuki Takahashi, Toru Watanabe, Hideaki Kato, Osamu Hosokawa

Department of General Surgery, Yokohama Sakae Kyosai Hospital, 132 Katsuracho, Sakae, Yokohama, Kanagawa 247-8581, Japan

ARTICLE INFO

Article history:

Received 11 September 2014

Received in revised form

13 December 2014

Accepted 15 December 2014

Available online 6 January 2015

Keywords:

Incisional hernia

Prosthesis

Transitional repair

Hernioplasty

Component separation

Titanized coating mesh

ABSTRACT

INTRODUCTION: Large incisional hernias are difficult to repair, especially in elderly patients with thin abdominal walls. Although most such incisional hernias are simply observed, they do not spontaneously resolve. Previously reported procedures are inadequate for repair of all incisional hernias. We herein propose an innovative technique for repair of ventral incisional hernias.

PRESENTATION OF CASE: A 88-year-old woman had a large incisional hernia with bilateral inguinal hernias. Incisional hernioplasty was successfully performed for extraperitoneal reinforcement by combining underlay and onlay methods using one prosthesis with transitional sutures. Bilateral inguinal hernioplasty was performed simultaneously. Twelve months postoperatively, the patient is well, without hernia recurrence.

DISCUSSION: Elderly patients often have thin, attenuated abdominal walls, and large incisional hernia reinforcement may require a prosthesis. In such cases, a retrorectal prosthesis position is recommended. However, the prosthesis cannot be placed on the cranial side in the presence of a destroyed or adhered abdominal wall is present. In this case, one prosthesis was placed using an underlay method on the caudal side and using an onlay method on the cranial side. The abdominal layers were shifted and each transition point was covered by the other layers to secure the overlapping margins between the abdominal wall and prosthesis.

CONCLUSION: This transitional mesh repair was successfully performed for a large incisional hernia in an elderly patient. The procedure is a useful strategy for incisional hernia repair in patients with thin, destroyed abdominal walls. However, further studies are required for a more thorough evaluation of this technique.

© 2014 The Authors. Published by Elsevier Ltd. on behalf of Surgical Associates Ltd. This is an open access article under the CC BY-NC-SA license (<http://creativecommons.org/licenses/by-nc-sa/4.0/>).

1. Introduction

Ventral incisional hernias are common after complicated surgeries in patients with attenuated abdominal walls [1]. Repair of large incisional hernias is often difficult because most are caused by a combination both a vulnerable abdominal wall and high intra-abdominal pressure and thus have a high possibility of recurrence.

Various procedures for repair of abdominal incisional hernias have been developed. Among them, reinforcement with a prosthesis is favorable [1], and the Rives–Stoppa technique is thought to be the most standard open surgical procedure [2–4]. The component separation technique is another effective procedure. Although it is insufficient without a prosthesis [5], it may be very effective with the use of a prosthesis [6]. Finally, laparoscopic hernioplasty has also been developed and its use is increasing [7].

Candidates for incisional hernioplasty are usually patients with a high body mass index [3,4] and nonelderly patients [5,8]. Elderly

patients with a small body size may also develop incisional hernias; however, most elderly patients with a thin abdominal wall do not undergo repair; instead, their hernia is simply observed. The abdominal conditions of some of these patients have adapted to the incisional hernia, making it difficult to repair. Therefore, the above-mentioned procedures are not sufficient for all such elderly patients.

An incisional hernia will not cure spontaneously and will instead deteriorate with time. Therefore, an innovative procedure for such patients is urgently needed. In the present case, we successfully performed an open hernioplasty using a prosthesis with the transitional technique for repair of a large incisional hernia in an elderly patient.

2. Presentation of case

A 88-year-old woman presented to our hospital for evaluation of abdominal distension and pain. She had undergone a right inguinal hernioplasty (unknown details) at 81 years of age and an emergency surgical procedure for small bowel perforation at 82 years of age. She gradually developed an incisional hernia after the surgery.

* Corresponding author. Tel.: +81 45 891 2171; fax: +81 45 895 8351.
E-mail address: surgkw@gmail.com (M. Kawaguchi).

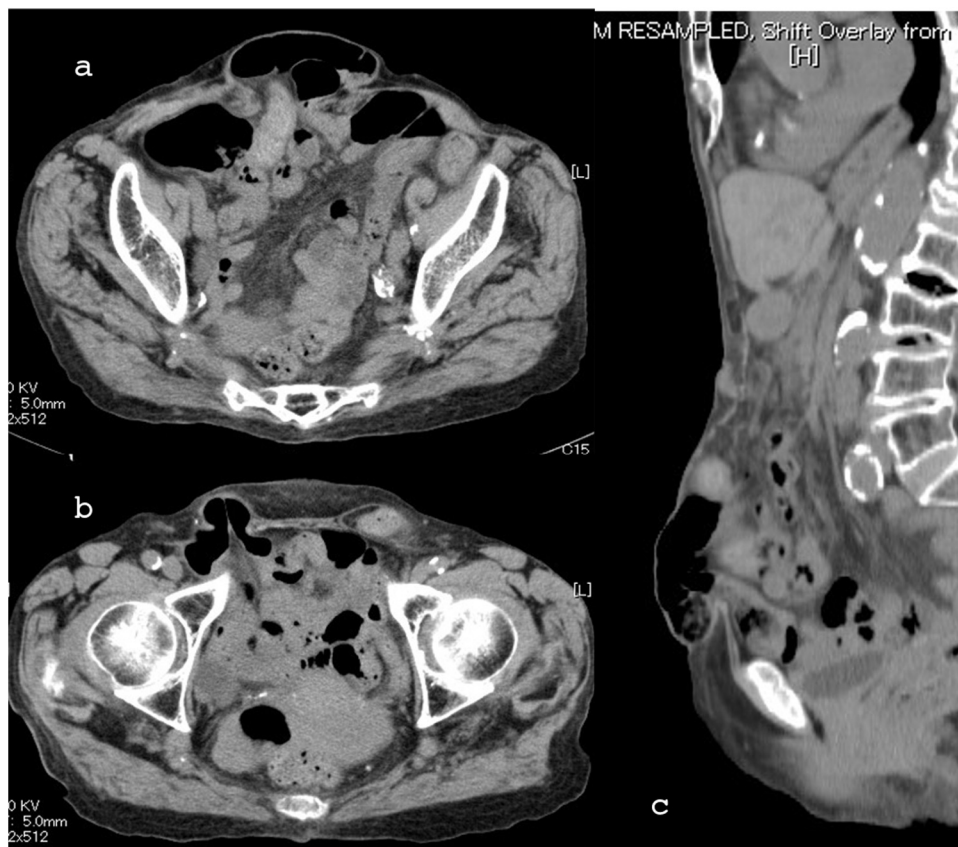

Fig. 1. Preoperative abdominal CT scan.

(a) Large incisional hernia in the lower abdomen. (b) Bilateral inguinal hernias in the inguinal plane. (c) Sagittal section at the center. The abdominal wall is thin and the hernia is hanging down.

However, the hernia was merely observed because of difficulty of repair. Because the incisional hernia was worsening with growth, she contacted our institute.

The patient was 140 cm in height and 42 kg in weight. She had an incisional scar and subumbilical abdominal distention. Computed tomography showed a large incisional hernia in the lower abdomen (Fig. 1). The abdominal wall defect and hernia sac were 10×3 cm and 15×8 cm in size, respectively. Bilateral inguinal hernias were also present. She was diagnosed with an incisional hernia with bilateral inguinal hernias, and open hernioplasty was performed.

With the patient in the supine position under general anesthesia, a central lower incision was made according to the previous scar to reveal the incisional hernia. Dissection of the preperitoneal space in the caudal abdomen was widely extended to the inguinal regions, and the bilateral inguinal hernias were repaired by an underlay method using titanized mesh.

Next, the preperitoneal dissection was extended toward the cranial side. However, the abdominal wall was destroyed and adhered, and the dissection could not be performed. The dissection layers were then shifted to the upper layers, such as posterior aspect of the rectus abdominis, the main region of the rectus abdominis, and the anterior sheath of the rectus abdominis. The hernia sac was resected and the peritoneum was closed by suturing it to the cranial side. Approximation of the rectus abdominis was performed as close as possible to the upper border. Titanized mesh (10×15 cm) was inserted into the preperitoneal space at a retrorectal position on the caudal side (Fig. 2d) and fixed to the rectus abdominis by 2–0 PDS. The rectus abdominis of the lower side was then closed (Fig. 3a).

Toward the cranial side, the mesh locations in the abdominal wall were arranged to shift the more superficial layers (Fig. 2a–c).

Finally, the upper side of the prosthesis was fixed using an onlay method (Fig. 3b).

A sump drain was placed in the subcutaneous cavity of the prosthesis for 3 days. The operating time was 120 min, and the blood loss volume was 100 ml. Although a seroma developed after drain removal, it spontaneously resolved without infection. Three months after the procedure, the patient was well without recurrence, and computed tomography confirmed the fixed ventral wall without recurrence of the hernias (Fig. 4). Twelve months after the surgery, the patient exhibited no clinical recurrence.

3. Discussion

The present case involved successful transitional mesh repair for a large incisional hernia in an elderly woman. The main feature of this procedure is the combination of both an onlay and underlay method using one prosthesis with transitional sutures.

The lower abdominal incisional hernia on the caudal side around the pubis readily formed secondary to abdominal pressure and gravity (Fig. 1c). Steady reinforcement was necessary [9]. Coverage of the suprapubic area with a sufficient margin for fixation was difficult using the onlay method. The underlay method in the retrorectal space is theoretically more appropriate for abdominal hernia repair [8,10] can provide enough preperitoneal space for treatment of both incisional and inguinal hernias (Fig. 2d). However, on the cranial side, the preperitoneal space between the peritoneum and the rectus abdominis was occasionally difficult to dissect because the rectus abdominis was often atrophic and the rectal sheath was destructed and adhered. Additionally, the abdominal wall was attenuated and tapered in many areas, and the upper border of the orifice was thus vague and undefined. Therefore, the

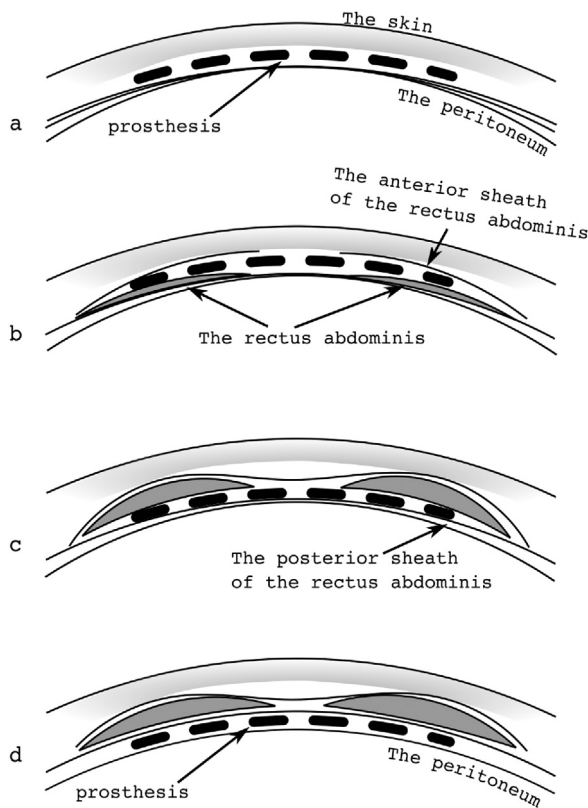


Fig. 2. Schema of horizontal sections of the transitional mesh repair. These sections show the location of the prosthesis (dotted line) in each section, which are ordered alphabetically from cranial to caudal. (a) The onlay mesh is placed on the anterior sheath of the rectus abdominis. (b) The prosthesis is placed on the rectus abdominis but is covered with the anterior sheath. (c) The prosthesis is placed between the rectus abdominis and the posterior sheath as in the Rives–Stoppa technique. (d) The prosthesis is placed in the preperitoneal space.

onlay method was appropriate for reinforcement of the wall on the cranial side (Fig. 2a).

How to use a prosthesis during hernioplasty using such methods may be problematic in some cases. The use of double mesh has been considered; however, double mesh might increase the mechanical vulnerability at the joint between the prostheses, and increasing the mesh volume could induce postoperative infection or discomfort. Hence, combined onlay and underlay incisional hernia repair using one prosthesis was performed in the present case.

Notably, when one prosthesis sheet is used in this procedure, the sheet must override the abdominal wall and have a transitional zone, which may serve as a vulnerable point. An overlapping margin is generally recommended for incisional hernia repair [1]. To resolve this problem, the abdominal wall at the transitional zone is shifted to the rectus abdominis and the anterior sheath (Fig. 2). The different transitional points are then overlapped by other layers, and each layer is approximated as shown in (Fig. 3). Through this procedure, the overlapped margins serve as the transitional zone.

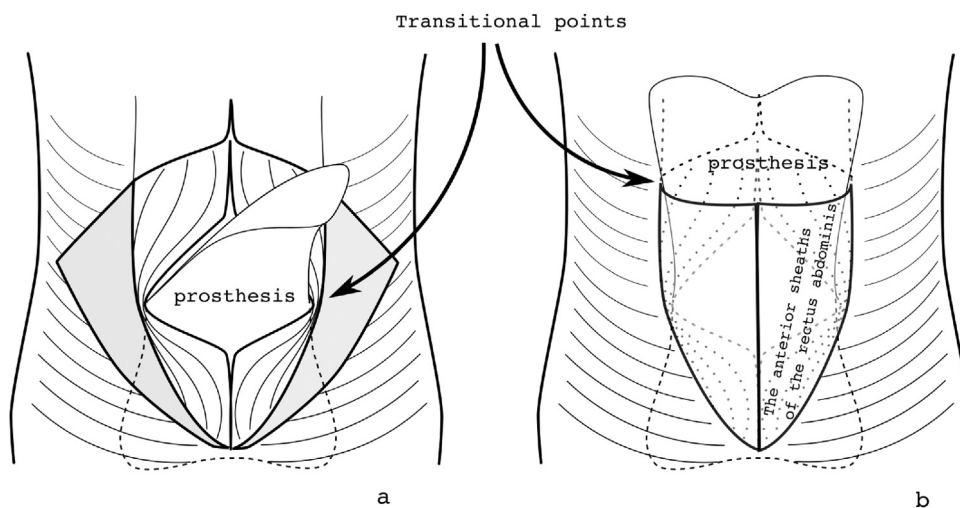


Fig. 3. Schema of frontal views of the transitional mesh repair. (a) Layer of the rectus abdominis and prosthesis. (b) Layer of the anterior sheath of the rectus abdominis and the prosthesis. Each transitional point is covered by other layers to secure the overlapping margins.

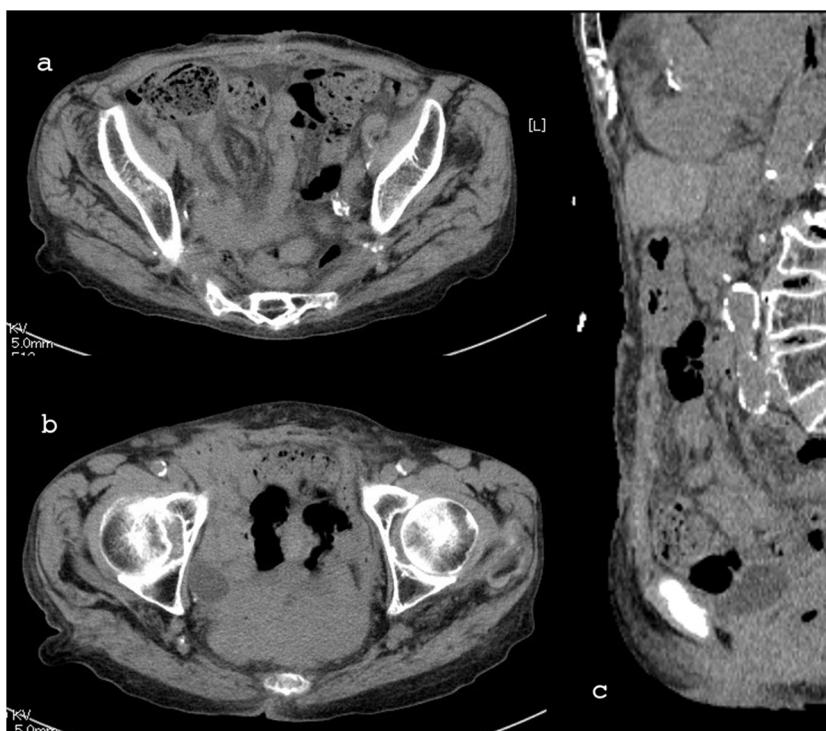


Fig. 4. Postoperative CT scan 3 months after the procedure shows complete repair of the abdominal wall. No hernial recurrence is evident in any area. (a) Fixation of the large incisional hernia. (b) Repair of the bilateral inguinal hernias. (c) Saggital section of the center.

4. Conclusion

Most incisional hernias are unique. Thus, a tailored procedure for each case is required under theoretical consideration. The herein-described transitional mesh repair was successfully performed for a large incisional hernia in an elderly patient. Although this procedure is a useful strategy for large incisional hernias in patients with a small body size and attenuated abdominal wall, higher numbers of patients and longer follow-up periods are required to fully evaluate the incidence and recurrence rates of incisional hernias.

Conflicts of interest

The authors declare that there is no conflict of interest.

Sources of funding

No funding source.

Ethical approval

No require ethical approval.

Consent

Written informed consent was obtained from the patient for publication of this case report and accompanying images. A copy of the written consent is available for review by the Editor-in-Chief of this journal on request.

Author contribution

Masahiko Kawaguchi contributed to the writing of this paper as a correspondence. Masahiko Kawaguchi and Hiroshi Ueno per-

formed this procedure. Yuki Takahashi and Toru Watanabe treated the patient as a team and reviewed the literature. Hideaki Kato corrected the manuscript. Osamu Hosokawa performed the critical revision and final proof of the article. All have authors read and approved submission of the final manuscript.

Guarantor

Masahiko Kawaguchi.

Key learning points

- Various forms of incisional hernias exist, and an appropriate procedure for each hernia should be selected after theoretical consideration.
- Transitional mesh repair is one open surgical strategy for treatment of incisional hernias.

References

- [1] Ventral Hernia Working Group, K. Breuing, C.E. Butler, S. Ferzoco, M. Franz, C.S. Hultman, et al., Incisional ventral hernias: review of the literature and recommendations regarding the grading and technique of repair, *Surgery* 148 (2010) 544–558.
- [2] V. Strâmbu, P. Radu, M. Brătucu, D. Garofil, C. Iorga, R. Iorga, et al., Rives technique, a gold standard for incisional hernias – our experience, *Chirurgia (Bucur)* 108 (2013) 46–50.
- [3] C.W. Iqbal, T.H. Pham, A. Joseph, J. Mai, G.B. Thompson, M.G. Sarr, Long-term outcome of 254 complex incisional hernia repairs using the modified Rives–Stoppa technique, *World J. Surg.* 31 (2007) 2398–2404.
- [4] M. Mehrabi, A. Jangjoo, H. Tavooosi, M. Kahrom, H. Kahrom, Long-term outcome of Rives–Stoppa technique in complex ventral incisional hernia repair, *World J. Surg.* 34 (2010) 1696–1701.
- [5] J.R.A. Skipworth, S. Vyas, L. Uppal, D. Floyd, A. Shankar, Improved outcomes in the management of high-risk incisional hernias utilizing biological mesh and soft-tissue reconstruction: a single center experience, *World J. Surg.* 38 (2014) 1026–1034.

- [6] N.J. Slater, H. van Goor, R.P. Bleichrodt, Large and complex ventral hernia repair using components separation technique without mesh results in a high recurrence rate, *Am. J. Surg.* (2014), <http://dx.doi.org/10.1016/j.amjsurg.2014.02.013> [Epub ahead of print].
- [7] H.M.A. Kaafarani, D. Kaufman, D. Reda, K.M.F. Itani, Predictors of surgical site infection in laparoscopic and open ventral incisional herniorrhaphy, *J. Surg. Res.* 163 (2010) 229–234.
- [8] D.M. Krpata, J.A. Blatnik, Y.W. Novitsky, M.J. Rosen, Evaluation of high-risk, comorbid patients undergoing open ventral hernia repair with synthetic mesh, *Surgery* 153 (2013) 120–125.
- [9] R. Bendavid, Incisional parapubic hernias, *Surgery* 108 (1990) 898–901.
- [10] V. Schumpelick, U. Klinge, K. Junge, M. Stumpf, Incisional abdominal hernia: the open mesh repair, *Langenbecks Arch. Surg.* 389 (2004) 1–5.

Open Access

This article is published Open Access at scimedirect.com. It is distributed under the [IJSCR Supplemental terms and conditions](#), which permits unrestricted non commercial use, distribution, and reproduction in any medium, provided the original authors and source are credited.