

Congenital duodenal diaphragm in eight children

Akhtar Nawaz*, MD, FRCSI; Hilal Matta*, MD, FCRS; Alic Jacobsz*, MD, FRCS; Omar Trad**, MD, MBBS; Ahmed H. Al Salem*, FRCSI, FACS, FICS

Background: Congenital duodenal obstruction (CDO) is a common and usually easy to diagnose cause of intestinal obstruction in the newborn, except when the cause of the obstruction is a duodenal diaphragm. We describe our experience with eight children who had intrinsic duodenal obstruction secondary to a duodenal diaphragm.

Methods: The medical records of 22 children with the diagnosis of congenital intrinsic duodenal obstruction were reviewed for age at diagnosis, sex, gestation, birth weight, clinical features, associated anomalies, method of diagnosis, treatment and outcome. Operative findings and procedures were obtained from the operative notes.

Results: Eight of the 22 children (36.4%) had congenital duodenal diaphragm (CDD). In all children, the diagnosis was made from plain abdominal X-ray, which showed the classic double-bubble appearance, and barium meal, which showed duodenal obstruction. Four patients had associated anomalies, including two with Down's syndrome. Intraoperatively, five patients were found to have duodenal diaphragm with a central hole, while the other three had complete duodenal diaphragms. Postoperatively, all patients did well. Six required total parenteral nutrition.

Conclusions: The 100% survival rate among these children is comparable to that in Western countries, and can be attributed to the lack of major associated abnormalities, good perioperative management, and the availability of total parenteral nutrition.

Key words: Congenital duodenal obstruction, congenital duodenal diaphragm, Oman

*From the *Department of Obstetrics and Gynaecology and **Department of Pathology, Aga Khan University Hospital Karachi, Pakistan.*

*Correspondence to :
Shahmaz Wasti, FRCOG
Department of Obstetrics and Gynaecology
Khoula Hospital
P.B.NO: 90, Post Code: 116,
Mina Al Fahal,
Sultanate of Oman*

Accepted for publication: July 2003

Ann Saudi Med 24(3):193-197

Congenital duodenal diaphragm (CDO) is one of the common causes of intestinal obstruction in the newborn, and as an isolated lesion, the diagnosis is usually not difficult. This is not the case, however, when the cause of obstruction is a duodenal diaphragm, which can be missed both preoperatively and intraoperatively. Preoperatively, the cause can be missed in patients with a duodenal diaphragm with a central aperture, where the diagnosis can sometimes be delayed until adult life; intraoperatively the cause can be missed in patients with a duodenal diaphragm without an external duodenal wall deformity or if there is a wind sock abnormality.^{1,2,3,4} We describe our experience with eight children who had intrinsic duodenal obstruction secondary to a duodenal diaphragm, with an emphasis toward an early diagnosis.

Methods

Between 1983 and 1998, 22 children with the diagnosis of congenital intrinsic duodenal obstruction were treated at our hospital. Eight were diagnosed with CDD. The medical records of these children were reviewed for age at diagnosis, sex, gestation, birth weight, clinical features, associated anomalies, method of diagnosis, treatment and outcome. The operative findings, including the site

and type of duodenal diaphragm as well as the operative procedures, were obtained from the operative notes.

Results

Of the 22 children with congenital duodenal obstruction (CDO), 8 (36.4%), 4 males and 4 females, had CDD (Table 1). All had a full-term normal vaginal delivery except one who had 30 weeks gestation. All presented with bile-stained vomiting. Six were newborns and all except one did not pass meconium. The one who passed meconium was found to have a CDO secondary to a diaphragm with a central hole. Three were jaundiced and three had upper abdominal distension. Three were dehydrated and one (patient No. 5, Table 1) had Klebsiella septicemia at the time of presentation, which necessitated treatment with antibiotics for 8 days prior to surgery. In all children, the diagnosis was made from plain abdominal X-ray, which showed the classic double-bubble appearance, and barium meal, which showed duodenal obstruction. In three children, the obstruction was complete (Figure 1), while in the other five the obstruction was incomplete, with gas present distally in the rest of the bowel and streaks of contrast material passed into the intestines (Figure 2). Four (50%) of our patients had associated anomalies, as shown in Table 1. Two (25%) had Down's syndrome.

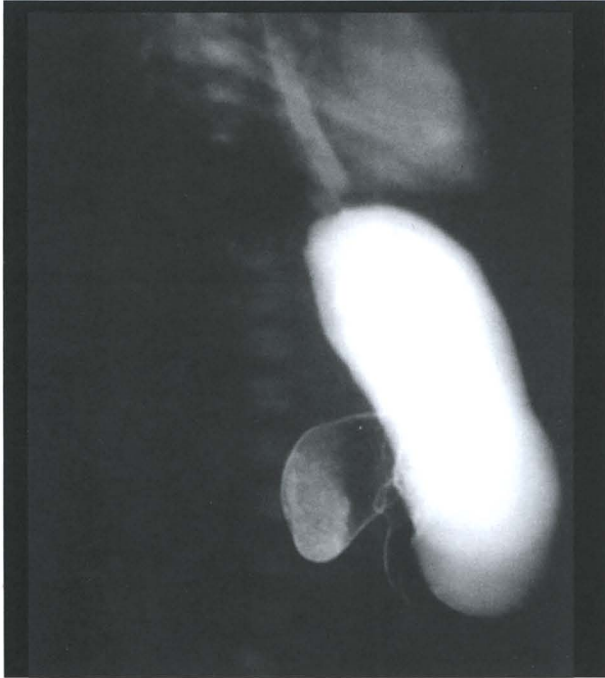

Figure 1. Upper gastrointestinal study showing duodenal obstruction secondary to a complete duodenal diaphragm.

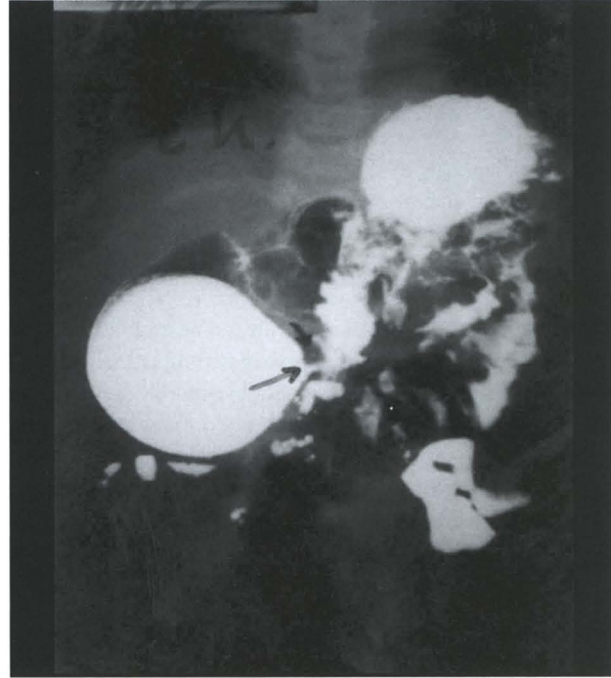


Figure 2. Upper gastrointestinal study showing incomplete duodenal obstruction with contrast material passing distally through a central hole in a duodenal diaphragm.

One patient was 3 1/2-years old at the time of presentation to our hospital. She had Down's syndrome and presented with vomiting, sometimes bile stained, and upper abdominal distension. She had a laparotomy at another hospital for intestinal obstruction one year prior to her presentation at our hospital. The causes of obstruction as well as type of treatment were not known. A plain abdominal X-ray showed a dilated stomach and duodenum with a double-bubble appearance, but air was present in the rest of the bowel. The barium meal showed incomplete duodenal obstruction, with streaks of contrast material passing into the intestine. She was operated on and found to have a duodenal obstruction in the second part of the duodenum secondary to a duodenal diaphragm, with a central hole (Figure 3), which was obstructed by date seeds (Figure 4).

Another patient presented at the age of 2 months with vomiting since birth. The vomiting was on and off and on many occasions non-bile stained. A plain abdominal X-ray and barium meal from another hospital were reported as normal. When repeated, the tests showed a classic double-bubble appearance indicative of duodenal obstruction, but there was gas in the rest of bowel. A barium meal showed incomplete duodenal obstruction with a small amount of barium passed into the intestines. Intraoperatively, she was found to have CDO in the second part of duodenum secondary to a duodenal diaphragm with a central hole.

All our patients were operated on, and intraoperatively, five were found to have duodenal diaphragm with a central hole,

while the other three had complete duodenal diaphragms. Six of our patients had the duodenal diaphragm in the second part of the duodenum and two had a duodenal diaphragm in the third part of the duodenum. None of our patients had a windsock abnormality. All except one had excision of the duodenal diaphragm and duodenoplasty by closing the longitudinal incision in the duodenum transversely. Because of the close proximity of the duodenal diaphragm to the ampulla of Vater, one patient had a dudeno-duodenostomy. Another, who had situs inversus, had apendicectomy as well. Four of our patients had silastic transanastomotic tubes. In one child, the tube recoiled into the stomach and was removed. This patient underwent a gastrostomy. In two patients, pieces of duodenal diaphragms were sent for histology. The samples revealed duodenal mucosa on both sides with stunted villi, crypts and Brunner's glands. In one sample, there were hemorrhages as well as an infiltrate of polymorphs, lymphocytes and plasma cells.

Postoperatively, all our patients did well. Six required total parenteral nutrition. There was no morbidity or mortality. Hospital stays ranged from 10 to 28 days (mean 20.3 days).

Discussion

The exact incidence of CDO is not known, but it is reported to occur in between 1:3,000 and 1:10,000 newborns.^{5,6} In recent years, the survival of neonates with

CDO has improved markedly as a result of early diagnosis, improved perioperative management, including advances in total parenteral nutrition, and appropriate surgical techniques. However, prematurity and associated major congenital anomalies still contribute to mortality.⁷

Early diagnosis of CDO based on prompt recognition of symptoms and accurate interpretation of radiological investigations is important, as delayed diagnosis is known to be associated with increased morbidity and a prolonged hospital stay.¹ The diagnosis of complete CDO is usually easy, and in the majority of cases this can be established with plain film radiographs and upper gastrointestinal barium studies.⁶ Although the classic double-bubble appearance with absent air distally on plain abdominal radiographs is pathognomonic of CDO, it is not specific, and is also seen in patients with small bowel volvulus, and sometimes in patients with tight duodenal stenosis.⁶ The importance of differentiating CDO from malrotation, with its risk of midgut volvulus and gangrene, needs to be emphasized. A barium meal is helpful in this regard if it shows the typical coil spring appearance of small bowel volvulus, or if the duodenojejunal junction is noted as low and to the right of midline, suggesting malrotation, which can be confirmed by barium enema.^{6,8,9} The presence of CDO with a doublebubble appearance and distal gastrointestinal air is one of the contributing factors for delayed diagnosis

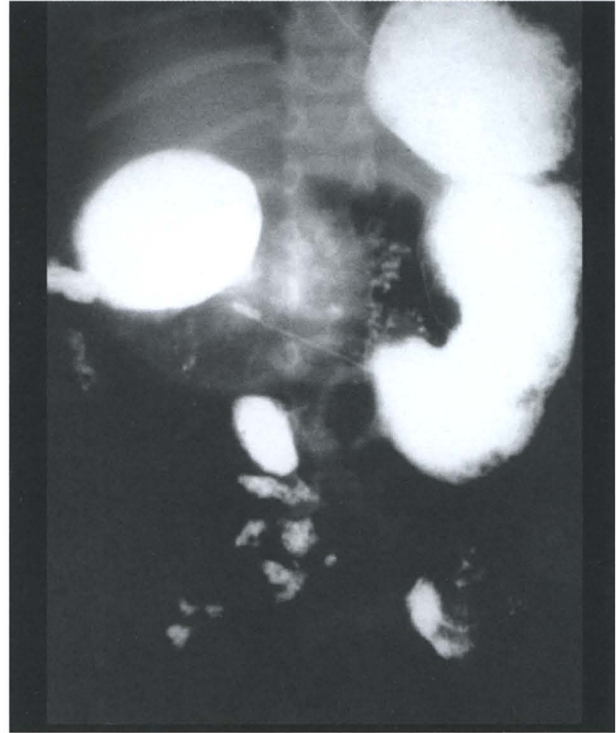

Figure 3. Upper gastrointestinal study showing a dilated duodenum that is incompletely obstructed, with contrast material passing distally through a central hole in a duodenal diaphragm.

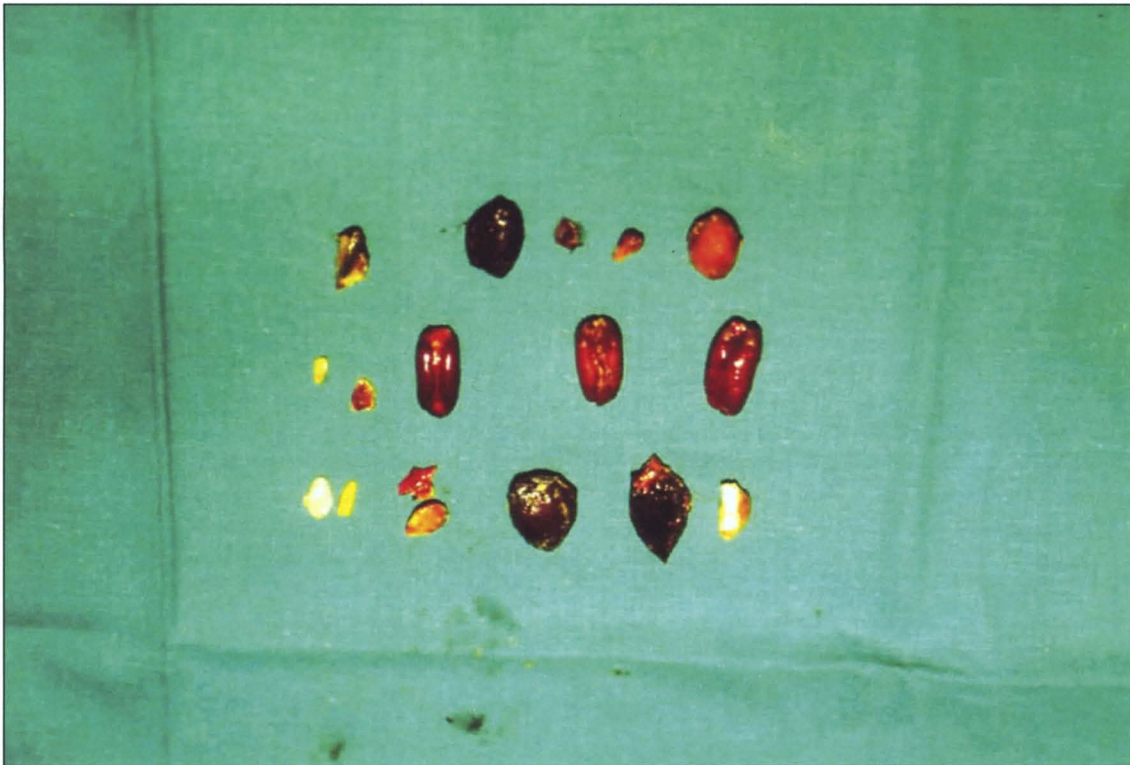

Figure 4. Operative photograph of the date seeds that caused obstruction of an aperture in a duodenal diaphragm in a 3-1/2-year-old girl with Down's syndrome.

Table 1. Demographic and clinical features of eight children with congenital duodenal diaphragm.

No	Age at diagnosis	Sex	Gestation	Birth weight (kg)	Clinical features	Associated anomalies	Site of diaphragm	Type of diaphragm	Treatment
1	2 days	M	36 weeks	2.28	Vomitting, failure to pass meconium, jaundice, dehydration	None	3rd part of duodenum	Complete diaphragm	Excision + Duodenoplasty + Gastronomy
2	1 day	M	37 weeks	1.57	Vomiting, upper abdominal distension, dehydration	None	2nd part of duodenum	Complete diaphragm	Excision + Duodenoplasty + Stent
3	2 months	F	38 weeks	2.44	Vomiting dehydration	None	2nd part of duodenum	Diaphragm with a central hole	Excision + Duodenoplasty + Stent
4	6 days	F	38 weeks	3.8	Vomiting	Situs inversus	2nd part of duodenum	Diaphragm with a central hole	Excision + Duodenoplasty + Stent + Appendectomy
5	39 weeks	F	39 weeks	3.0	Vomiting, jaundice, klebsiella septicemia	None	2nd part of duodenum	Diaphragm with a central hole	Excision + Duodenoplasty
6	8 days	M	38 weeks	2.29	Vomiting, upper abdominal distension, jaundice	Down's syndrome	2nd part of duodenum	Diaphragm with a central hole	Duodeno-Duodenoplasty
7	3 years	F	38 weeks	-	Vomiting, upper abdominal distension	Sickle cell trait, Down's syndrome	2nd part of duodenum	Diaphragm with a central hole	Excision + Duodenoplasty
8	2 days	F	30 weeks	1.44	Vomiting	Polydactyly, Meckel's diverticulum	3rd part of duodenum	Complete diaphragm	Excision + Duodenoplasty

as it may not be possible to differentiate between the various etiological factors, which include congenital duodenal stenosis secondary to annular pancreas or Ladd's bands,^{10,11} complete duodenal obstruction with the possibility of bifid pancreaticobiliary duct,^{12,13} duodenal diaphragm with a central aperture,⁴ and duodenal diaphragm with microperforations.¹⁴ This was the case in two of our patients with a diaphragm and a central hole where the diagnosis was delayed. In one patient, a previous contrast study prior to presentation at our hospital was reported as normal and the other patient, a 3-1/2-year-old, had undergone a negative laparotomy for intestinal obstruction one year prior to presentation. In addition, depending on the size of the aperture in the diaphragm, the symptomatology may not be specific or persistent, and not uncommonly, the patient will have non-bile stained vomiting. The diagnosis in some patients may be delayed until adult life.² To obviate this delay, the possibility of CDD with a central hole must always be kept in mind, especially in children with repeated attacks of vomiting even if not bile stained. An experienced radiologist should evaluate the radiograms.

CDD is a rare and variable cause of CDO. Eustace et al had only one duodenal diaphragm among 53 (1.9%) neonates

with CDO treated over a 4-year period, which formed 3.7% of patients with intrinsic duodenal obstruction.⁶ Al Salem et al treated five newborns with CDD among 19 (26.3%) with intrinsic CDO.⁵ Adeyemi treated six newborns with CDD among 30 (20%) with CDO, which were 28.6% of 21 with intrinsic CDO.¹⁵ We treated eight (36.4%) children with CDD among 22 with intrinsic CDO. The reason for the relatively high frequency of CDD in our series is not known.

The incidence of CDO and associated anomalies is also variable, ranging from 13%¹⁶ to as high as 78%.⁷ The association of CDO and Down's syndrome is well known, with an incidence of about 30% to 50%,^{5,17} but a low incidence of 11%¹⁸ and a high incidence of 70%⁷ were also reported. Two of our patients with CDD (25%) had Down's syndrome. Abdominal situs inversus is one of the rare but interesting anomalies associated with CDO.¹⁹ One of our patients who had duodenal diaphragm with a central hole diagnosed preoperatively on upper gastrointestinal study and proven intraoperatively, had abdominal situs inversus with partial duodenal obstruction.

Although preampullary diaphragms and diaphragms in the third part of duodenum have been reported, the

majority occur in the second part of the duodenum.^{1,20} Six of our patients had duodenal diaphragms in the second part of duodenum, while in the other two the duodenal diaphragm was located in the third part of duodenum. Like others, we advocate excision of the duodenal diaphragm and duodenoplasty.^{1,4} Intraoperatively, the site of the duodenal diaphragm can be defined by passing the nasogastric tube distally, which causes indentation of the duodenal wall caused by tenting of the diaphragm. This can also be demonstrated preoperatively by ultrasound where the tube pressing on an obstructing web will cause dimpling of the duodenal contour at the attachment point of the web to the duodenal wall.²¹ This is of great importance if a windsock abnormality is present. To prevent missing the diaphragm, the duodenum should be opened at the point of attachment of the diaphragm to the duodenal wall. Care should be taken during excision of the duodenal diaphragm. Excision of the duodenal diaphragm should proceed from the lateral wall due to its close proximity to the ampulla on the medial side, but if this proves difficult then duodeno-duodenostomy becomes the procedure of choice. For this reason, others have advocated simple incision of the diaphragm in its

lateral aspect only.²² Endoscopic excision of the duodenal diaphragm is also possible, yet is not widely practiced.

The value of gastrostomy and a transanastomotic stent in the management of CDO remains controversial. Only one of our patients early in the series had gastrostomy, and like others, we feel that gastrostomy adds no advantage to the operative management. A nasogastric tube is as effective in achieving adequate gastric decompression. Three of our patients had silastic transanastomotic nasojejunal tubes that were used for early postoperative enteral feeding. Although the use of trans-anastomotic feeding tubes is said to lead to earlier full preanastomotic feeding,²⁴ the tubes are not without complications, namely difficulty in manipulation at the time of insertion, recoiling as happened in one of our patients, and anastomatic breakdown.⁵ The likelihood of prolonged ileus in these patients calls for early total parenteral nutrition.

The survival rate of 100% in our patients is comparable to that reported from Western centres.^{7,25} We think the survival rate is attributable to the lack of major associated anomalies in our patients and good perioperative management, including the availability of total parenteral nutrition.

References

- Huang FC, Chuang JH, Shih CS. Congenital duodenal membrane: a ten-year review. *Acta paediatr. Taiwan.* 1999;40:70-74.
- Lehur PA, Poisson J, Lamontagne L, Haddad H. Congenital diaphragm of the duodenum in an adult: a case report. *Can J Surg.* 1983;26:559-560.
- Rowe MI, Buckner D, Clatworthy HW. Windsock web of the duodenum. *Am J Surg.* 1968;116:444-449.
- Horgan PG, Horgan AF, O'Donnell JA. The neonatal windsock web- a case report and description of a new technique for its operative excision. *Irish J Med Sci.* 1990;159:110.
- Al-Salem AH, Khawaja S, Grant C, Dawodu A. Congenital duodenal obstruction: Problems in the diagnosis and management. *J Pediatr Surg.* 1989;24:1247-1249.
- Eustace S, Connolly B, Blake N. Congenital duodenal obstruction: an approach to diagnosis. *Eur J Pediatr Surg.* 1993;3:267-270.
- Akhtar J, Guiney EJ. Congenital duodenal obstruction. *Br J Surg.* 1992;79:133-135.
- Siegel MJ, Shackleford GD, McAlister WH. Small bowel volvulus in children. Its appearance on the barium enema examination. *Paediatr Radiol.* 1980;10:91-93.
- Berdon WE, Baker DH, Ball S. Midgut malrotation and volvulus. Which films are most helpful? *Radiology.* 1970; 96: 375-383.
- Elliot GB, Kliman MR, Elliot KA. Pancreatic annulus: a sign or a cause of duodenal obstruction. *Can J Surg.* 1968;11:357-364.
- Lee FA, Mahour GH, Guinn JL. Roentgenographic aspects of intrinsic duodenal obstruction. *Ann Radiol.* 1978;21:133-142.
- Tashjian DB, Moriarty KP. Duodenal atresia with an anomalous common bile duct masquerading as a midgut volvulus. *J Pediatr Surg.* 2001;36: 956-957.
- Knechtle SJ, Filston HC. Anomalous biliary ducts associated with duodenal atresia. *J Pediatr Surg.* 1990;25: 1266-1269.
- Bickler SW, Harrison MW, Blank E, Campbell JR. Microperforation of a duodenal diaphragm as a cause of paradoxical gas in congenital duodenal obstruction. *J Pediatr Surg.* 1992;27: 747-749.
- Adeyemi SD. Duodenal obstruction in Nigerian newborns and infants. *Scand J Gastroenterol.* 1986;124:157-161.
- Gavopoulos S, Limas CH, Avtzoglou P, Tsikopoulos G, Vislaki A, Grigoriadis G et al. Operative and post operative management of congenital duodenal obstruction: a 10 year experience. *Pediatr Surg Int.* 1993;8:122-124.
- Young DG, Wilkinson AW. Abnormalities associated with neonatal duodenal obstruction. *Surgery.* 1968;63: 832-836.
- Bailey PV, Tracy TF JR, Connors RH, Mooney DP, Lewis JE, Weber TR. Congenital duodenal obstruction: A 32 year review. *J Pediatr Surg.* 1993;28: 92-95.
- Luchtman M, Golan Y, Heldenberg D, Kessler FB: Situs inversus abdominis in association with duodenal obstruction and internal hernia. *Am J Perinatol.* 1993;10: 255-257.
- Ganguly S, Chowdhury MM, Ganguly S, Chowdhury MM, Ganguly S, Chowdhury J, Mishra PK. Congenital duodenal diaphragms in the third part of duodenum. *Indian Pediatr.* 1995;32:1326-1327.
- Dwek JR, Teich S. The duodenal dimple: a specific fluoroscopic correlate to the duodenal web. *Pediatr Radiol.* 1999;29:462-468.
- Zial-ul Miraj M, Madden NP, Brereton RJ. Simple incision: A safe and definite procedure for congenital duodenal diaphragm. *J Pediatr Surg.* 1999;34:1021-1024.
- Ambjornsson E, Larsson M, Finkel Y, Karpe B. Transanastomotic feeding tube after an operation for duodenal atresia. *Eur J Pediatr Surg.* 2002;12:159-162.
- Grosfeld JL, Rescorla FJ. Duodenal atresia and stenosis: reassessment of treatment and outcome based on antenatal diagnosis, pathologic variance and long-term follow up. *World J Surg.* 1993;17:301-309.