

Received: 2017.03.22  
Accepted: 2017.05.31  
Published: 2017.09.11

ISSN 1941-5923  
© Am J Case Rep, 2017; 18: 975-979  
DOI: 10.12659/AJCR.904468

## Diffuse Idiopathic Pulmonary Neuroendocrine Cell Hyperplasia: A Case Report and Review of the Literature

Authors' Contribution:  
Study Design A  
Data Collection B  
Statistical Analysis C  
Data Interpretation D  
Manuscript Preparation E  
Literature Search F  
Funds Collection G

ABDEF 1 **Evangelos Koliakos**  
ABDEF 1 **Theodoros Thomopoulos**  
A 1 **Ziad Abbassi**  
A 2 **Christophe Duc**  
A 1 **Michel Christodoulou**

1 Department of General Surgery, Hospital of Valais (CHVR), Sion, Switzerland  
2 Department of Histopathology, Hospital of Valais (CHVR), Sion, Switzerland

**Corresponding Author:** Evangelos Koliakos, e-mail: [evangeloskoliakos@gmail.com](mailto:evangeloskoliakos@gmail.com)  
**Conflict of interest:** None declared

**Patient:** Female, 69  
**Final Diagnosis:** Diffuse idiopathic pulmonary neuroendocrine cell hyperplasia  
**Symptoms:** Occasional and mild shortness of breath • persistent nocturnal cough  
**Medication:** —  
**Clinical Procedure:** Surgical intervention: right middle lobectomy  
**Specialty:** Surgery

**Objective:** Rare disease





**Background:** Diffuse idiopathic pulmonary neuroendocrine cell hyperplasia (DIPNECH) is a rare pulmonary disorder that is characterized by diffuse hyperplasia of bronchiolar and bronchial pulmonary neuroendocrine cells. In this condition, when no other pathological pulmonary condition is detected, DIPNECH is considered to be an idiopathic lung disease. DIPNECH is a rare condition that can be difficult to distinguish from other forms of reactive pulmonary neuroendocrine cell hyperplasia (NECH). We present a case of DIPNECH and describe the approach to diagnosis of this rare condition.

**Case Report:** A 69-year-old woman with a past medical history of successfully treated lobular carcinoma of the breast, presented to our department with a respiratory tract infection. High-resolution computed tomography (HRCT) of the chest showed a suspicious pulmonary nodule, measuring 13 mm, in the right middle pulmonary lobe. Combined positron emission tomography (PET) and computed tomography (CT), showed a solid and metabolically active nodule. A transbronchial biopsy and histopathology confirmed a diagnosis of DIPNECH.

**Conclusions:** It is possible that DIPNECH is an under-diagnosed pulmonary condition because it is rarely associated with symptoms. At this time, there are no evidence-based management guidelines. While the majority of cases have stable clinical course, some cases can progress to cause airway obstruction. This case report highlights this rare, but potentially progressive condition, and the need for evidence-based management guidelines for DIPNECH.

**MeSH Keywords:** Carcinoid Tumor • Multiple Pulmonary Nodules • Neuroendocrine Cells • Synaptophysin

**Full-text PDF:** <https://www.amjcaserep.com/abstract/index/idArt/904468>

 1704   3  10



## Background

Neuroendocrine cells are present in the lung as part of the normal bronchiolar and bronchial anatomy and are present from the upper airways to the terminal respiratory unit. Reactive neuroendocrine cell hyperplasia (NECH) is believed to be a response to hypoxia, including dyspnea, and chronic obstructive pulmonary disease (COPD) [1,2]. Diffuse idiopathic pulmonary neuroendocrine cell hyperplasia (DIPNECH) is a rare pulmonary condition that is characterized by diffuse hyperplasia of bronchiolar and bronchial pulmonary neuroendocrine cells [3,4]. In DIPNECH, primary neuroendocrine cell proliferation occurs with no underlying pathology and is typically seen in non-smoking, middle-aged women, often in association with obliterative bronchiolitis [3,4]. The World Health Organization (WHO) currently recognize DIPNECH as a pre-invasive precursor lesion for bronchial carcinoid tumors and tumorlets [3].

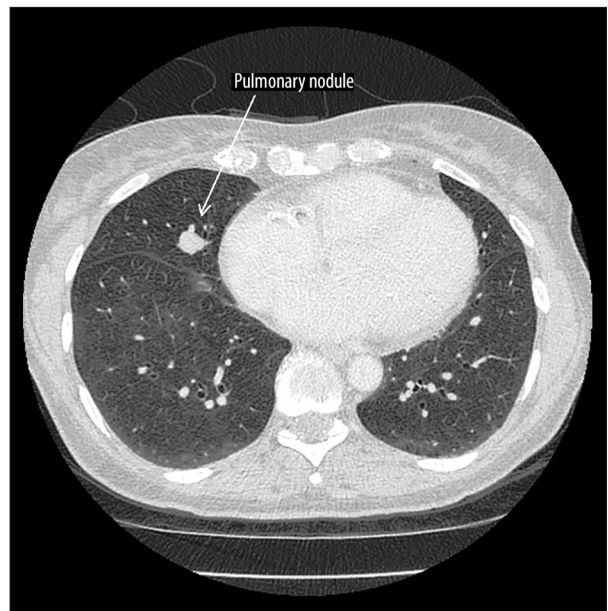
The aim of this case report is to highlight this rare, but potentially progressive condition, and the need for management guidelines for DIPNECH.

## Case report

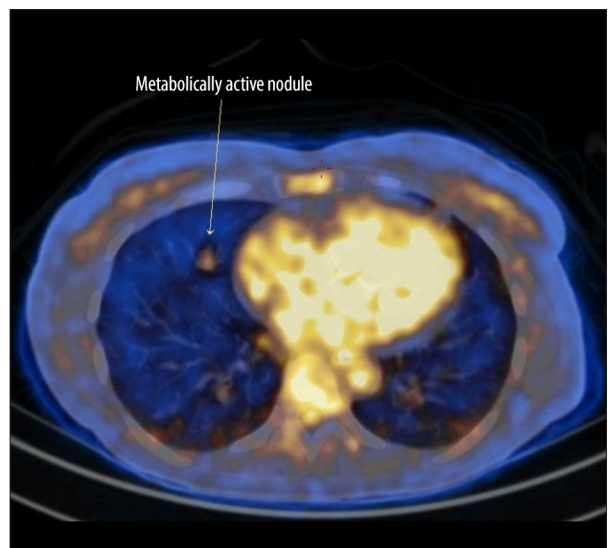A 69-year-old woman, who has never smoked, but who had a past medical history of a treated lobular carcinoma of the breast removed surgically in 2009, was investigated in our department for a respiratory tract infection. Following her breast surgery in 2009, she had been treated with post-operative radiotherapy and hormone therapy for five years, followed by complete remission.

Seven years following her breast surgery, she attended the emergency department of our hospital because of because of a persistent nocturnal cough, associated with occasional and mild shortness of breath. She had consulted her family physician and received treatment for a respiratory infection, but her symptoms persisted despite two weeks of antibiotic therapy. Because of this clinical history, on her admission to our hospital, a high-resolution computed tomography (HRCT) scan of the chest was performed, which showed a suspicious pulmonary nodule, measuring 13 mm in diameter, in the right middle pulmonary lobe, associated with enlarged axillary lymph nodes, but without other lesions in the other pulmonary lobes (Figure 1).

This initial pulmonary imaging finding led to further investigations that included combined positron emission tomography (PET) and computed tomography (CT) lung imaging, which confirmed the existence of a solid and metabolically active nodule in the right middle pulmonary lobe, with axillary and cervical lymph node enlargement (Figure 2). A transbronchial

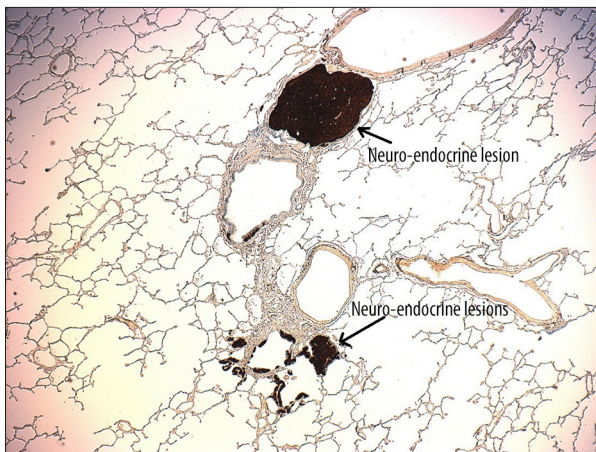


**Figure 1.** High-resolution computed tomography (HRCT) of the lung. A 13 mm nodule is seen in the right middle pulmonary lobe.



**Figure 2.** Combined positron emission tomography (PET) – computed tomography (CT) imaging of the lung. A metabolically active nodule in the right middle pulmonary lobe is shown.

ultrasound-guided biopsy of the suspicious nodule was performed. Following tissue biopsy fixation, processing, sectioning and routine histochemical staining, histological examination showed a well-differentiated neuroendocrine tumor with the initial diagnosis favoring typical or atypical carcinoid tumor. Fine-needle aspiration cytology of the patient's enlarged lymph nodes showed reactive lymphadenopathy with no evidence of malignancy.



**Figure 3.** Photomicrograph of the histology of the lung. Light microscopy shows multifocal neuroendocrine lesions in the peribronchial region, with positive immunostaining for synaptophysin. No carcinoid tumor or atypical cells or invasive cells are identified.

The multidisciplinary clinical team suggested an aggressive and radical surgical approach for both diagnostic and therapeutic purposes. Therefore, a right middle pulmonary lobectomy was undertaken, with para-oesophageal and inter-tracheobronchial lymph node dissection, as well as right axillary lymph node dissection. The operation was successful, without any perioperative or postoperative complications. The right middle pulmonary lobe, the para-oesophageal, inter-tracheobronchial, and right axillary lymph nodes were sent for histopathological analysis.

The histopathology report documented that at least 20 tumorlets were found in the peribronchial region, measuring between 0.1 cm and 0.3 cm, which were positive for synaptophysin on immunohistochemistry, supporting a diagnosis of diffuse idiopathic pulmonary neuroendocrine cell hyperplasia (DIPNECH) involving the right middle pulmonary lobe (Figure 3). No carcinoid tumor was identified. Examination of the lymph nodes showed benign reactive hyperplasia with no evidence of tumor or of neuroendocrine cells.

The post-operative chest HRCT showed no lung lesion. The patient had an uneventful recovery and was discharged from hospital ten days later. Our multidisciplinary team proposed a radiological follow-up, with a chest HRCT every six months for the first two years, followed by annual follow-up for at least three more years. After six months of follow-up, there is no radiological evidence of recurrence, and the patient has no pulmonary symptoms.

## Discussion

Neuroendocrine cells are part of normal pulmonary bronchial and bronchiolar anatomy and are thought to play an important role in lung development, as they are frequently found in the airways of fetal and neonatal lungs [2,3]. Neuroendocrine cells of the lung decrease in number with age and are only present focally in adult airways, where they represent approximately 1% of all epithelial cells in the adult lung [2,3].

Pulmonary neuroendocrine cell hyperplasia (NECH) can be either reactive or primary in nature. Reactive pulmonary NECH can occur as a result of a wide spectrum of chronic conditions that are usually associated with hypoxia, including pulmonary interstitial fibrosis, bronchopulmonary dysplasia (BPD), cystic fibrosis, asthma, bronchiectasis, chronic exposure to high altitude, exposure to tobacco smoke, and chronic obstructive pulmonary disease (COPD) [1,2]. A type of reactive pulmonary NECH is seen in the bronchiolar wall adjacent to carcinoid tumors, where it is considered as a possible pre-neoplastic condition [2–5]. The 2004 World Health Organization (WHO) classification of lung tumors recognized pulmonary NECH [4,5].

In the 2015 classification of lung tumors, the WHO now recognizes diffuse idiopathic pulmonary neuroendocrine cell hyperplasia (DIPNECH) as a pre-neoplastic lesion [3].

However, DIPNECH is also defined as being idiopathic and existing without any pre-existing chronic lung disease. The condition of DIPNECH was initially described in 1992 by Aguayo et al. [6] who reported on six non-smoking patients (mainly women) with cough, exertional dyspnea, and a mixed obstructive/restrictive defect on pulmonary function tests. The pulmonary histopathology from these patients showed diffuse hyperplasia of pulmonary neuroendocrine cells, multiple carcinoid tumorlets, and peribronchiolar fibrosis obliterating small airways [6].

There have now been more than 200 cases of DIPNECH described since the initial description by Aguayo et al., in the form of case reports or small case series, but no clear consensus has been established in the literature about the radiological or pathological diagnostic criteria or the management of this condition. The current definition of DIPNECH by the WHO is a histological and descriptive definition [3]. However, in the initial clinical description by Aguayo et al. described a clinical condition with respiratory symptoms as well as specific radiological and histological characteristics [6].

However, a recent paper by Marchevsky et al. reported on 70 consecutive surgical lung biopsies showing multifocal neuroendocrine proliferations, which had neither histological features of obliterative bronchiolitis nor had they been diagnosed with DIPNECH before histological examination, indicating that the

condition can be asymptomatic [7]. This study suggested that the presence of multifocal NECH combined with more than three tumorlets as the minimum pathological criteria for the diagnosis of DIPNECH, limiting the condition to a pathological entity [7]. Neuroendocrine cell proliferations with a diameter of less than 5 mm are considered to be tumorlets, while larger lesions are carcinoid tumors [3].

Wirtschafter and al. evaluated 30 cases of DIPNECH and systematically reviewed 169 cases reported in the English literature and concluded that only 55 (28%) had obliterative or constrictive bronchiolitis [8]. This same conclusion has been drawn by Davies and al., who suggest that even in cases with histological evidence of airway wall thickening, chronic inflammation, and constrictive obliterative bronchiolitis, the majority of patients did not have clinically important airflow obstruction [9].

With regard to symptomatic cases of DIPNECH, as in the case we have presented, the condition typically presents with a chronic, non-productive cough, exertional dyspnea, and frequent wheezing, with a clinical presentation predominantly in non-smoking middle-aged women (mean age, 58 years) [3,4,6,9,10]. The diagnosis of DIPNECH is often made several years after the onset of clinical symptoms, usually following the incidental discovery of a lung nodule on chest CT scan. The condition progresses slowly, although there have been cases reported of a rapidly progressive and more aggressive clinical course, which has required surgery and even lung transplantation [3,4,6,9,10]. In the majority of symptomatic cases of DIPNECH, lung function tests show an obstructive or mixed obstructive/restrictive ventilation defect [3,4,6,9,10].

Chest computed tomography (CT) scan is considered to be the initial examination of choice, with DIPNECH showing a mosaic lung pattern with air trapping, characterized by the presence of low attenuation lung interposed with normally ventilated higher attenuation lung [1,3,4,9,10]. However, the manifestation of neuroendocrine cell proliferation as nodules remains the predominant and often sole abnormality.

In the appropriate clinical and radiological setting, a transbronchial biopsy may be sufficient for the diagnosis of DIPNECH, although open surgical lung biopsy is considered optimum for diagnosis [1,3,4,9,10]. The histological and immunohistochemical features of DIPNECH include constrictive obliterative bronchiolitis characterized by chronic inflammation, bronchial wall thickening and fibrosis, believed to be the reason for progressive narrowing and/or complete obliteration of the bronchiolar

lumen in severe cases. Chromogranin A, synaptophysin, and CD56 are the most commonly expressed immunohistochemical markers, while p53, Ki67, and p16 may distinguish DIPNECH from reactive NECH [3].

Currently, the management and treatment options for DIPNECH have included clinical observation, oral and inhaled steroids, chemotherapy, surgical lung resection, and even lung transplantation [3,4,9,10]. Regarding our case, the patient presented with a rapid onset of symptoms, but it is unclear how these symptoms related to the underlying DIPNECH.

The patient profile and presentation in this case report fits the typical DIPNECH profile, that of a middle-aged non-smoking female presenting with exertional dyspnea, in association with the discovery of a lung nodule on chest CT [3,4]. In this case, the biopsy findings are those of the histological criteria for DIPNECH diagnosis as defined by the WHO and cited by Marchevsky et al. [3,7]. In our case report, neuroendocrine cell proliferation was primary without any underlying associated pathology. Therefore, we believe that this patient experienced the idiopathic form of the disease rather than a secondary condition associated with pulmonary interstitial fibrosis or carcinoid tumor.

## Conclusions

Diffuse idiopathic pulmonary neuroendocrine cell hyperplasia (DIPNECH) remains a rare pulmonary condition. While most patients experience a relatively uneventful clinical course, this condition may be associated with airway obstruction in some cases. Awareness of the condition, imaging, and histology are required to make the definitive diagnosis, and close follow-up is important in the more aggressive cases of DIPNECH. It is possible that DIPNECH is an under-diagnosed pulmonary condition because it is rarely associated with symptoms. At this time, there are no evidence-based management guidelines. While the majority of cases have stable clinical course, some cases can progress to cause airway obstruction. This case report has highlighted this rare, but potentially progressive condition and the need for evidence-based management guidelines for DIPNECH.

## Conflict of interest

None.



## References:

---

1. Benson RE, Rosado-de-Christenson ML, Martínez-Jiménez S et al: Spectrum of pulmonary neuroendocrine proliferations and neoplasms. *Radiographics*, 2013; 33: 1631–49
2. Cansız Ersöz C, Cangır AK, Dizbay Sak S: Diffuse neuroendocrine cell hyperplasia: Report of two cases. *Case Rep Pathol*, 2016; 2016: 3419725
3. Gosney JR, Austin JHM, Jett J et al: Diffuse pulmonary neuroendocrine cell hyperplasia. In: Travis WD, Brambilla E, Burke AP et al. (eds.), WHO classification of tumours of the lung, pleura, thymus and heart. Lyon, IARC Press, 2015; 78–79
4. Nassar AA, Jaroszewski DE, Helmers RA et al: Diffuse idiopathic pulmonary neuroendocrine cell hyperplasia: A systematic overview. *Am J Respir Crit Care Med*, 2011; 184: 8–16
5. Travis WD, Brambilla E, Müller-Hermelink HK, Harris CC: World Health Organization classification of tumours: pathology & genetics: Tumours of the lung, pleura, thymus and heart. Lyon, France: IARC Press, 2004.
6. Aguayo SM, Miller YE, Waldron JA Jr. et al: Brief report: Idiopathic diffuse hyperplasia of pulmonary neuroendocrine cells and airways disease. *N Engl J Med*, 1992; 327: 1285–88
7. Marchevsky AM, Wirtschafter E, Walts AE: The spectrum of changes in adults with multifocal pulmonary neuroendocrine proliferations: What is the minimum set of pathologic criteria to diagnose DIPNECH? *Hum Pathol*, 2015; 46: 176–81
8. Wirtschafter E, Walts AE, Liu ST et al: Diffuse idiopathic pulmonary neuroendocrine cell hyperplasia of the lung (DIPNECH): Current best evidence. *Lung*, 2015; 193: 659–67
9. Davies SJ, Gosney JR, Hansell DM et al: Diffuse idiopathic pulmonary neuroendocrine cell hyperplasia: An under-recognised spectrum of disease. *Thorax*, 2007; 62: 248–52
10. Carr LL, Chung JH, Achcar RD et al: The clinical course of diffuse idiopathic pulmonary neuroendocrine cell hyperplasia. *Chest*, 2015; 147: 415–22