



Early-onset epileptic encephalopathies and the diagnostic approach to underlying causes

Su-Kyeong Hwang, MD, PhD, Soonhak Kwon, MD

Department of Pediatrics, Kyungpook National University Children's Hospital, Daegu, Korea

Early-onset epileptic encephalopathies are one of the most severe early onset epilepsies that can lead to progressive psychomotor impairment. These syndromes result from identifiable primary causes, such as structural, neurodegenerative, metabolic, or genetic defects, and an increasing number of novel genetic causes continue to be uncovered. A typical diagnostic approach includes documentation of anamnesis, determination of seizure semiology, electroencephalography, and neuroimaging. If primary biochemical investigations exclude precipitating conditions, a trial with the administration of a vitaminic compound (pyridoxine, pyridoxal-5-phosphate, or folinic acid) can then be initiated regardless of presumptive seizure causes. Patients with unclear etiologies should be considered for a further workup, which should include an evaluation for inherited metabolic defects and genetic analyses. Targeted next-generation sequencing panels showed a high diagnostic yield in patients with epileptic encephalopathy. Mutations associated with the emergence of epileptic encephalopathies can be identified in a targeted fashion by sequencing the most likely candidate genes. Next-generation sequencing technologies offer hope to a large number of patients with cryptogenic encephalopathies and will eventually lead to new therapeutic strategies and more favorable long-term outcomes.

Key words: Epileptic encephalopathy, Early infantile, Genetics, Mutation, High throughput nucleotide sequencing

Corresponding author: Soonhak Kwon, MD
Department of Pediatrics, Kyungpook National University Children's Hospital, 807 Hoguk-ro, Buk-ku, Daegu 41404, Korea
Tel: +82-53-200-2746
Fax: +82-53-425-6683
E-mail: shkwon@knu.ac.kr

Received: 1 September, 2015

Accepted: 28 October, 2015

Introduction

Early-onset epileptic encephalopathies (EOEE) are one of the most devastating early onset epilepsies that contribute to progressive decline of cerebral function¹. Most patients show the three main features of EOEE: refractory seizures, severe electroencephalographic abnormalities, and developmental delay or intellectual disability². A tendency to be refractory to antiepileptic drugs often leads to severe cognitive and behavioral impairment³. Identifiable primary causes, such as known structural, neurodegenerative, metabolic, genetic, or chromosomal disorders, and an increasing number of novel genetic causes are being identified in EOEE^{3,4}. The most common causes are structural brain abnormalities and inborn metabolic defects⁵. If neuroimaging and biochemical examinations exclude common etiologies, the remaining fraction, comprising about one third of all EOEE cases, represents cryptogenic cases, where genetic factors are considered to have an important role^{6,7}. EOEE is a genetically heterogeneous disorder: over 100 genes have been suggested to be involved in the etiology of these syndromes⁸. Many EOEE cases are sporadic, occurring in patients with no family history of seizures or epilepsies⁹. Sporadic cases are commonly caused by autosomal dominant *de novo* mutations in genes encoding neuronal proteins. EOEE can also be inherited in an autosomal recessive or X-linked manner. Next-generation sequencing (NGS) technology has revolutionized our ability to sequence DNA at the whole exome or

Copyright © 2015 by The Korean Pediatric Society

This is an open-access article distributed under the terms of the Creative Commons Attribution Non-Commercial License (<http://creativecommons.org/licenses/by-nc/3.0/>) which permits unrestricted non-commercial use, distribution, and reproduction in any medium, provided the original work is properly cited.

whole genome level at an increasingly affordable price¹⁰. Whole exome sequencing now costs under \$1,000 per sample and numerous studies have successfully identified *de novo* mutations in individuals with various neurodevelopmental disorders^{11,12}. In epilepsy genetics, the focus has been almost exclusively on genes encoding membrane ion channel proteins. However, an increasing number of mutations in genes encoding proteins other than ion channels are now being identified by NGS². Epi4k, the international consortium for advanced genetic studies of epilepsy, has been making significant progress in epilepsy genetics by using NGS. The consortium was launched in 2011 in response to a National Institute of Neurological Disorders and Stroke (NINDS) Funding Opportunity Announcement soliciting applications for “Centers Without Walls for Collaborative Research in the Epilepsies: Genetics and Genomics of Human Epilepsies” and adopted the name “Epi4K: Gene Discovery in 4000 Genomes”^{10,13}. The first project of Epi4K focused on the discovery of *de novo* mutations in Lennox-Gastaut syndrome and infantile spasms. Over 300 *de novo* mutations in genes including *SCN1A*, *STXBP1*, *SCN8A*, *SCN2A*, *CDKL5*, *GABRB3*, *ALG13*, *CACNA1A*, *CHD2*, *FLNA*, *GABRA1*, *GRIN1*, *GRIN2B*, *HNRNPU*, *IQSEC2*, *MTOR*, and *NEDD4L* have been discovered. Statistical evidence of association between epileptic encephalopathy and mutations in *GABRB3* and *ALG13* was also identified^{9,10}. In this article, we will focus on the diagnostic strategies for EOEE, especially on NGS-based genetic analysis for cryptogenic EOEE cases.

Epileptic encephalopathy syndromes in infancy

1. Vitamin-responsive epileptic encephalopathies

Vitamin-responsive epileptic encephalopathies are rare but important causes of EOEE. They commonly result in refractory seizures with poor neurocognitive outcomes if specific treatment is

delayed. The type of seizures, etiologies, and treatments are summarized in Table 1. If seizures persist despite the use of two or more appropriate anticonvulsants at maximum tolerated doses, then add-on vitamin treatment should be considered. Pyridoxine-dependent epilepsy (PDE) and pyridoxal-5-phosphate-dependent epilepsy share similar clinical presentations as pyridoxal-5-phosphate is derived from pyridoxine¹⁴. In the early onset type, patients will typically develop abnormal movements soon after birth and electroencephalogram (EEG) can be either completely normal or exhibit a burst suppression pattern¹⁵. Prognosis is generally good with prompt treatment, but death or significant intellectual and motor disability may occur if treatment is delayed¹⁶. Pyridoxal-5-phosphate may be used as an initial treatment, which would be effective against both PDE and pyridoxal-5-phosphate dependent epilepsy. Pyridoxine could be introduced later, replacing pyridoxal-5-phosphate as a cheaper and similarly effective alternative, if PDE diagnosis is confirmed¹⁷. Folinic acid responsive epilepsies are caused by low concentration of 5-methyltetrahydrofolate (MTHF) in the cerebrospinal fluid (CSF), which is associated with various neurological conditions¹⁸. Genetic or autoimmune mechanisms cause cerebral folate deficiency and delayed treatment may lead to encephalopathy with severe learning disabilities. EEG may show abnormal background activity with multifocal spike-wave complexes, but typically has no diagnostic features. Neuroimaging results are also usually normal¹⁹. Patients either do not respond to pyridoxine at all or exhibit only a temporary improvement. However, such patients show a marked neurological recovery including cessation of seizures upon folinic acid treatment¹⁸. Biotinidase deficiency is a biotin-responsive metabolic disorder causing impairment of functions of multiple carboxylases and presenting with seizures, hypotonia, visual/auditory symptoms, eczema, and alopecia. Untreated children usually have neurocutaneous features between the ages of 2 and 5 months^{18,20}. Seventy percent of patients have various

Table 1. Summary of vitamin-responsive early onset epileptic encephalopathy

Disorder	Type of seizures	Etiology	Initial treatment	Long-term treatments
Pyridoxine dependent epilepsy	Focal or generalized, myoclonic, epileptic spasms	<i>ALDH7A1</i>	Pyridoxine 100 mg or 30 mg/kg	Pyridoxine 5–15 mg/kg daily (or add 3–5 mg/kg of folinic acid on pyridoxine)
Pyridoxal-5-phosphate dependent epilepsy	Multifocal myoclonic-tonic	<i>PNPO</i>	Pyridoxal-5-phosphate 30 mg/kg	Pyridoxal-5-phosphate 10–15 mg/kg daily
Folinic acid responsive seizures	Epileptic spasms, myoclonic/astatic, absence, generalized tonic clonic	<i>ALDH7A1</i> , <i>SLC46A1</i> , <i>FOLR1</i> , <i>MTHFR</i> , <i>MTHFS</i>	Folinic acid or 5-methyltetrahydrofolate 3–5 mg/kg	Folinic acid or 5-methyltetrahydrofolate 3–5 mg/kg daily
Biotinidase deficiency	Myoclonic, generalized tonic clonic, infantile spasms, partial seizures	<i>BTD</i>	Biotin 5–20 mg	Biotin 5–10 mg twice daily
Vitamin B12 deficiency	Epileptic spasms, focal or generalized	Dietary (maternal B12 deficiency), <i>TCN2</i> , <i>MMAA</i> , <i>MMAB</i> , <i>MMACHC</i> , <i>MMA DHC</i> , <i>MTRR</i> , <i>LMBRD1</i> , <i>MTR</i> , <i>ABCD4</i>	Hydroxocobalamin or cyanocobalamin 1 mg daily to weekly or methylcobalamin 1 mg daily	Hydroxocobalamin or cyanocobalamin 1 mg every 1–3 months or methylcobalamin 1 mg daily

type of seizures including infantile spasms²¹. Seizures and other symptoms improve often within a day of treatment with biotin. It has been suggested that similarly to pyridoxine trials, biotin treatment should be considered in any child with poorly controlled seizures²². Regardless of age or weight, a dose of 5- to 20-mg biotin daily has been found to be effective and needs to be continued for the rest of patient's life if it offers stable improvement^{23,24}. Vitamin B12 deficiency may lead to various neurologic symptoms including developmental delay or regression, irritability, weakness, hypotonia, and convulsions. Seizures are a rare presentation of vitamin B12 deficiency but they have been occasionally reported, especially in infants, including cases of West syndrome^{25,26}. Vitamin B12 deficiency caused by dietary preferences of mothers, who may be vegan, is the most common cause of such symptoms in breast-fed infants between 4 and 8 months, even when the mothers exhibit no hematological or neurological symptoms themselves^{26,27}. Serum levels of methylmalonic acid and total homocysteine have been shown to be markedly elevated in the majority of such patients. Vitamin B12 deficiency should be considered in all infants with developmental delay, hypotonia, or seizures for whom an alternate diagnosis cannot be made.

2. Ohtahara syndrome

Ohtahara syndrome is often defined as an early infantile epileptic encephalopathy with a characteristic EEG pattern, suppression-burst, during which higher-voltage bursts of slow waves mixed with multifocal spikes alternate with isoelectric suppression phase²⁸. EEG shows a continuous suppression-burst pattern in both waking and sleeping states. The onset is between neonatal period and early infancy, usually within the first 3 months of age, with some mothers reporting seizure-like movements of the fetus during pregnancy²⁹. Etiologically, structural brain lesions, such as diffuse subependymal band heterotopia or midbrain dysplasia, are the most probable causes of Ohtahara syndrome^{30,31}. Predominant seizures detected in Ohtahara syndrome patients are repetitive, frequent, tonic spasms occurring with or without series formation, although other seizure types can also be observed^{29,32}. Antiepileptic and immunomodulating drugs are generally ineffective in treating tonic spasms, although rare cases show improvement upon such treatment. In general, prognosis is extremely poor with chronic intractable seizures and severe psychomotor retardation. Seizure patterns usually change with time: frequently cases evolve to West syndrome and further to Lennox-Gastaut syndrome with age. Nearly 50% of affected children are likely to die in infancy or childhood^{32,33}.

3. Early myoclonic epileptic encephalopathy

Early myoclonic encephalopathy (EME) is characterized by fragmentary myoclonic jerks or violent myoclonic spasms, which

generally occur in the neonatal period or early infancy. Partial myoclonus and partial motor seizures are the main seizure types in EME, but generalized myoclonus can also be observed in some patients. Partial motor seizures are frequent. They occur shortly after erratic myoclonus and shift typically from one part of the body to another in a random, asynchronous pattern³⁴. The myoclonus usually involves the face or extremities, but may be restricted to some other part of the body. Typical interictal EEG shows a suppression-burst pattern similar to that seen in Ohtahara syndrome³⁵. Suppression-bursts become more apparent in sleep and may persist until late childhood after a transient evolution to hypsarrhythmia in the middle to late infancy³¹. The generalized myoclonic jerk typically is associated with a generalized or fragmentary burst of polyspike, spike, and slow wave discharges, but erratic myoclonia may or may not be related to the bursts³⁵. The etiology is variable and often remains unknown, but non-structural/metabolic disorders are most probable causes of EME. Vitamin responsive epilepsies, such as PDE, pyridoxal-5-phosphate-dependent epilepsy, or folic acid responsive epilepsy can show typical clinical and EEG features of EME. Other inborn metabolic deficiencies, such as nonketotic hyperglycinemia, methylmalonic acidemia, or propionic acidemia, can also demonstrate EME features. Concentrations of serum amino acids and urine organic acids, as well as amino acid content of the CSF should be analyzed in patients with EME^{34,36}. The prognosis for EME is also poor and there is no effective treatment except for vitamin responsive epilepsies. EME persists for long periods without evolution, except for the occasional transient phase of West syndrome, or changes into partial or severe epilepsy with multiple independent spike foci³¹.

4. Infantile spasms (West syndrome)

Infantile spasms or West syndrome is the most common epilepsy syndrome in infancy, which presents with a combination of the triad of infantile spasms, developmental deterioration, and hypsarrhythmic EEG pattern^{3,37}. Typically, the spasms involve brief symmetrical contractions of musculature of the neck, trunk, and extremities, which frequently occur in clusters^{38,39}. An individual spasm lasts for seconds (usual duration 1–2 seconds) and is often longer than typical myoclonus (duration up to 200 ms), though not as long as tonic seizures, which last for several seconds. Spasms are usually recurrent with a period of 5–30 seconds^{3,34}. The spasms may be subtle and isolated at onset, typically clustering with time. Patients typically exhibit several clusters per day, particularly during drowsiness^{37,40}. Hypsarrhythmia, a typical interictal EEG pattern observed in this condition, consists of a disorganized pattern with asynchronous, very high amplitude multifocal spike and sharp wave discharges. The etiology can be classified into symptomatic and cryptogenic cases. The fraction of symptomatic cases has been steadily increasing due to improved

diagnostic techniques, such as metabolic and genetic testing, as well as neuroimaging⁴¹. Symptomatic causes are found in nearly 60% of cases, which include cerebral malformations, infection, hemorrhage, hypoxic-ischemic injury, metabolic disorders, and genetic conditions^{40,42}. Tuberous sclerosis complex (TSC) is an important cause of infantile spasms and 75%–80% of individuals with TSC may develop epilepsy⁴¹. Outcomes are mostly dependent on the etiology; cryptogenic patients who are treated early have more favorable prognosis than patients with symptomatic varieties^{43,44}.

5. Malignant migrating partial epilepsy in infancy

Malignant migrating partial epilepsy in infancy (MMPEI) is characterized by neonatal or early infantile onset migrating partial seizures, which usually last a few weeks or months, and the frequency becomes nearly continuous with time. Patients show frequent partial seizures of multifocal onset with autonomic manifestations, such as apnea, flushing, or cyanosis⁴⁵. The interictal EEG shows multifocal epileptiform discharges with diffuse slowing of background activity. The multifocal discharges poorly activated by sleep in all cases and background activity slows down with fluctuating asymmetry between different recordings³⁴. Most cases have no clear etiology of structural or biochemical abnormalities suggesting contribution of genetic factors. However, genetic tests usually fail to detect mutations in *KCNQ2*, *KCNQ3*, *SCN1A*, *SCN2A*, or *CLCN2* genes in MMPEI⁴⁶. Seizures are often intractable and global developmental delay is common. Most patients develop an acquired microcephaly by the end of the first year of age and a number of patients die before that time or later, in the course of the follow-up period⁴⁵.

6. Myoclonic status in nonprogressive encephalopathies

Myoclonic status in nonprogressive encephalopathies (MSNE) is an early onset epileptic syndrome characterized by dulling of consciousness and responsiveness with or without jerks, which may last for hours, days, or weeks⁴⁷. Interictal EEG consists of multifocal epileptiform discharges and background slowing. Ictal EEG recording may demonstrate generalized slow spike and wave or an absence pattern, depending on the seizure type³⁴. A genetic cause, such as Angelman syndrome or 4p syndrome, is found in approximately half of the children. Other reported structural causes include hypoxic-ischemic injury and cortical dysplasia³⁴. Most children are resistant to different therapies, even to intravenous benzodiazepines, and the status may become a life-threatening event⁴⁷. Seizures often persist into adulthood and the final outcome is very poor with developmental regression and severe mental retardation, especially in patients with repeated episodes of myoclonic status^{48,49}.

7. Dravet syndrome (severe myoclonic epilepsy in infancy)

Dravet syndrome is a genetically determined severe epileptic encephalopathy, which begins in the first year of life in an otherwise normal infant. The epilepsy starts with seizures, which may not initially differ from those associated with febrile illnesses. Even mild fever is an important trigger factor, but some cases are provoked by a nonfebrile illness, immunization, or hot environment⁵⁰. It is not easy to differentiate these children from others with febrile convulsions, who will eventually get better and will not develop other types of seizures. During the second year of the life, seizures become more frequent, persistent, and often more lateralized. At that stage, seizures no longer occur only when a child has high temperature, but can happen at any time of the day³⁴. Seizures are complex febrile, afebrile generalized, unilateral clonic, or tonic-clonic. The condition evolves to other types, such as myoclonic, atypical absence, complex partial seizures, and frequent status epilepticus⁵⁰. EEG is usually normal at early stages of this condition. However, by the time a child is 2 years old, epileptic discharges with spike and wave or polyspikes are observed, which occur either as single events or in bursts. Prognosis is very poor, as this syndrome is associated with developmental delay, cognitive dysfunction, and behavioral problems.

Diagnostic approaches to underlying causes of EOEE

Diagnostic approaches to underlying causes of EOEE are summarized in Fig. 1. Assessments begin with the elucidation of the history and semiology of clinical seizures and analysis of EEG findings. When age onset, clinical manifestations, and EEG findings are consistent with EOEE, an evaluation of possible underlying etiologies should be performed. EOEE must be distinguished from acute symptomatic seizures occurring in infancy, for example, those caused by infection, hypoglycemia, or electrolyte disturbance³. If the primary investigations exclude precipitating conditions, a trial with the administration of a vitaminic compound (pyridoxine, pyridoxal-5-phosphate, or folic acid) should then be initiated^{51,52}. These new insights re-emphasize the importance of early treatment of neonatal seizures with vitamins, whatever the suspected cause. Pyridoxine, folic acid, and cyanocobalamin are still the most commonly prescribed treatments, largely due to their commercial availability and affordability. However, safer and more effective formulations can be obtained. Ideally, pyridoxal phosphate can be used instead of pyridoxine, but it is not licensed for sale or is not easily available in many countries. Direct purchasing biologically active vitamins overseas is possible through websites via internet searching. When importing 7 or more bottles of vitamins, import declaration and a medical prescription is necessary because vitamins are categorized as

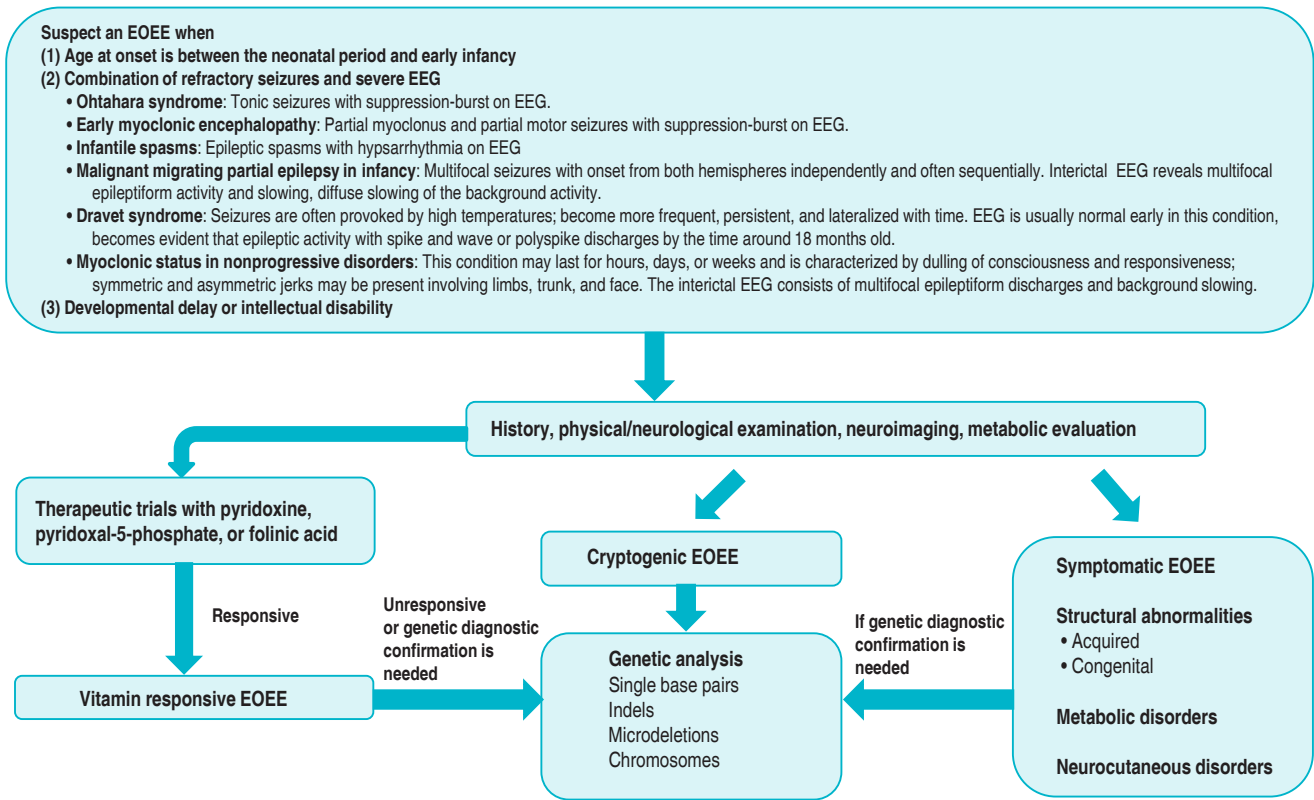


Fig. 1. Diagnostic approaches for the identification of the causes of early-onset epileptic encephalopathy. EOOE, early-onset epileptic encephalopathies; EEG, electroencephalogram.

health functional foods in Korea. In the case of purchasing less than 7 bottles of Korean Ministry of Food and Drug Safety unrestrained vitamins for personal use, however, it is possible to pass customs without any prescriptions or declaration. Older children presenting with recurrent febrile status epilepticus or intractable seizures should receive similar therapy and, in addition, biotin in order to exclude biotinidase deficiency. If the patient responds to treatment, suitable biochemical and genetic investigations should then be undertaken to define the cause⁵³. Clinicians should be aware that a poor response does not completely exclude diagnosis of vitamin dependent epilepsies^{51,54}.

During physical/neurological examinations, certain clinical parameters, such as the combination of dysmorphic features, neurologic deficits, or cutaneous lesions, may at that point suggest underlying etiology. Following the completion of anamnesis, physical/neurologic examinations, EEG analysis, and magnetic resonance imaging of the brain, approximately two-thirds of patients will have an established etiologic diagnosis without the need to conduct extensive metabolic testing⁴¹. The remaining patients with undetermined etiologies should be considered for further evaluation, which will depend on individual circumstances. Typical tests may include organic acids in urine, amino acids in serum, determination of biotinidase, analyses of neuro-

transmitters, lactic acid, amino acids, folate metabolites, and glucose in the CSF as well as other biochemical tests suggested by the patient's clinical course and study findings⁴¹. Although they are relatively rare, metabolic encephalopathies are important to be recognized. Patients with some of these syndromes can respond to specific treatments, but some antiepileptic drugs interfering with metabolic pathways may worsen the clinical condition, so specific genetic counseling should be provided in such cases⁵⁵. In a recent study, diagnostic genetic testing for childhood epileptic encephalopathy found genetic causes in 28% of the patients: 7% had inherited genetic metabolic disorders, while 21% had other genetic causes including genetic syndromes, pathogenic copy number variants (CNVs) revealed by comparative genomic hybridization arrays, and epileptic encephalopathy related to mutations in the *SCN1A*, *SCN2A*, *SCN8A*, *KCNQ2*, *STXBP1*, *PCDH19*, and *SLC9A6* genes⁵⁶. Genes mutated in early onset epileptic encephalopathy are summarized in Table 2. Targeted next-generation sequencing panels increased genetic diagnostic yield from less than 10% to over 25% in patients with epileptic encephalopathy⁵⁶. Identification of mutations underlying cryptogenic EOOE needs to be performed in a targeted fashion by sequencing the most likely candidate genes. Massive parallel sequencing approaches enabled obtaining sequence information directly, however, the abundance

Table 2. Summary of genes that are related to early onset epileptic encephalopathy

Types	Clinical manifestations	Genes	Locus	Protein function
EIEE1	Early infantile epileptic encephalopathy 1 (OMIM number 308350) X-linked myoclonic seizures, spasticity, and intellectual disability syndrome (OMIM number 308350) Idiopathic infantile epileptic-dyskinetic encephalopathy (OMIM number 308350) Ohtahara syndrome (OMIM number 308350)	<i>ARX</i>	Xp22.13	Transcriptional repressor and activator
EIEE2	Early infantile epileptic encephalopathy 2 (OMIM number 300672)	<i>CDKL5</i>	Xp22	Serine-threonine kinase
EIEE3	Ohtahara syndrome (OMIM number 308350) Early infantile epileptic encephalopathy 3 (OMIM number 609304)	<i>SLC25A22</i>	11p15.5	Mitochondrial glutamate/Hp symporter
EIEE4	Ohtahara syndrome (OMIM number 308350) Early infantile epileptic encephalopathy 4 (OMIM number 612164)	<i>STXBP1</i>	9q341	Modulator of synaptic vesicle release
EIEE5	Early infantile epileptic encephalopathy 5 (OMIM number 613477)	<i>SPTAN1</i>	9q33-q34	Cytoskeletal protein
EIEE6	Dravet syndrome (OMIM number 607208)	<i>SCN1A</i>	2q24.3	Subunit of a voltage-gated sodium channel
EIEE7	Early infantile epileptic encephalopathy 7 (OMIM number 613720) Benign familial neonatal seizures-1 (OMIM number 121200)	<i>KCNQ2</i>	20q13.3	
EIEE8	Early infantile epileptic encephalopathy 8 (OMIM number 300607)	<i>ARHGEF9</i>	Xq11.1	Rho-like GTPase to regulate CDC42 and other genes
EIEE9	Early infantile epileptic encephalopathy 9 (OMIM number 300088)	<i>PCDH19</i>	Xq22	Adhesion protein
EIEE10	Early infantile epileptic encephalopathy 10 (OMIM number 613402)	<i>PNKP</i>	19q13.33	Enzyme involved in DNA repair
EIEE11	Early infantile epileptic encephalopathy 11 (OMIM number 613721) Benign familial neonatal seizures-1 (OMIM number 607745)	<i>SCN2A</i>	2q24.3	Subunit of a voltage-gated sodium channel
EIEE12	Early infantile epileptic encephalopathy 12 (OMIM number 613722) Malignant migrating partial epilepsy in infancy	<i>PLCB1</i>	20p12	Plays an important role in the intracellular transduction of many extracellular signals
EIEE13	Early infantile epileptic encephalopathy 13 (OMIM number 614558) Malignant migrating partial epilepsy in infancy	<i>SCN8A</i>	12q13.1	Subunit of a voltage-gated sodium channel
EIEE14	Early infantile epileptic Encephalopathy 14 (OMIM number 614959) Malignant migrating partial epilepsy in infancy	<i>KCNT1</i>	9q34.3	Sodium-activated potassium channel subunit
EIEE15	Early infantile epileptic encephalopathy 15 (OMIM number 615006)	<i>ST3GAL3</i>	1p34.1	Catalyzes the transfer of sialic acid from CMP-sialic acid to galactose-containing substrates
EIEE16	Early infantile epileptic encephalopathy 16 (OMIM number 615338)	<i>TBC1D24</i>	16p13.3	Interacts with GTPases
EIEE17	Early infantile epileptic encephalopathy 17 (OMIM number 615473)	<i>GNAO1</i>	16q13	Modulators or transducers in various transmembrane signaling systems
EIEE18	Early infantile epileptic encephalopathy 18 (OMIM number 615476)	<i>SZT2</i>	1p34.2	Localized to the peroxisome, and is implicated in resistance to oxidative stress
EIEE19	Early infantile epileptic encephalopathy 19 (OMIM number 615744)	<i>GABRA1</i>	5q34	Encodes a gamma-aminobutyric acid (GABA) receptor

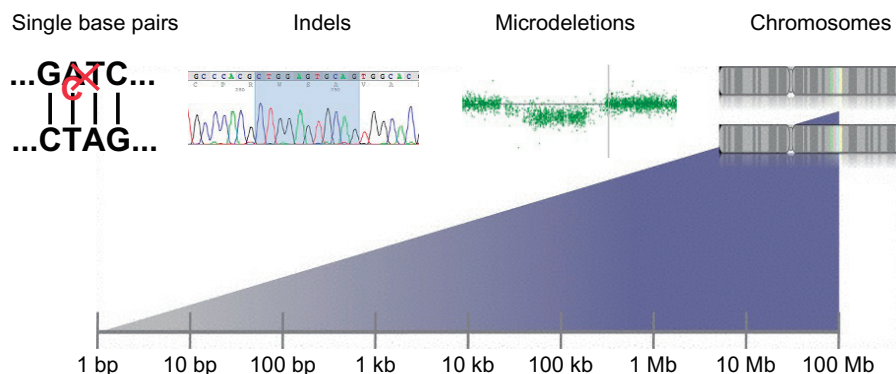


Fig. 2. The range of genome alterations in humans predisposing them to disease by size. Adapted from Helbig J. *Prog Brain Res* 2014;213:253-78⁵⁷, with permission of Elsevier B.V.

of novel data, be it on the level of common single nucleotide polymorphisms, CNVs, or overall sequence, has led to the identification of a vast amount of benign variation in the human genome (Fig. 2)⁵⁷. Massive parallel sequencing in epilepsy genetics can be divided into three different fields: family studies, gene panel studies, and patient-parents trio studies. Family studies are performed to identify the causal monogenic variant in families. Panel studies trade additional genetic information for deeper coverage outside the selected genes in contrast to exome sequencing studies. Patient-parent trio studies focus on the genome-wide identification of *de novo* mutations⁵⁷.

Conclusions

In conclusion, the diagnostic procedure for EOEE is still challenging, but early recognition and proper management have an important effect on its long-term outcomes. We believe that next-generation sequencing technologies are inspiring hope in a large number of children with cryptogenic encephalopathies and the use of these approaches will eventually lead to the development of new therapeutic strategies and, as a result, to more favorable long-term outcomes.

Acknowledgments

This study was supported by a grant of the Korea Health Technology R&D Project from the Korea Health Industry Development Institute (KHIDI) funded by the Ministry of Health & Welfare, Republic of Korea (grant number: HI14C1234).

References

- Engel J Jr; International League Against Epilepsy (ILAE). A proposed diagnostic scheme for people with epileptic seizures and with epilepsy: report of the ILAE Task Force on Classification and Terminology. *Epilepsia* 2001;42:796-803.
- Nieh SE, Sherr EH. Epileptic encephalopathies: new genes and new pathways. *Neurotherapeutics* 2014;11:796-806.
- Alam S, Lux AL. Epilepsies in infancy. *Arch Dis Child* 2012;97:985-92.
- Nabbout R, Dulac O. Epileptic syndromes in infancy and childhood. *Curr Opin Neurol* 2008;21:161-6.
- Sharma S, Prasad AN. Genetic testing of epileptic encephalopathies of infancy: an approach. *Can J Neurol Sci* 2013;40:10-6.
- Guerrini R. Epilepsy in children. *Lancet* 2006;367:499-524.
- Nabbout R, Dulac O. Epileptic encephalopathies: a brief overview. *J Clin Neurophysiol* 2003;20:393-7.
- Lemke JR, Riesch E, Scheurenbrand T, Schubach M, Wilhelm C, Steiner I, et al. Targeted next generation sequencing as a diagnostic tool in epileptic disorders. *Epilepsia* 2012;53:1387-98.
- Epi4K Consortium; Epilepsy Phenome/Genome Project, Allen AS, Berkovic SF, Cossette P, Delanty N, et al. De novo mutations in epileptic encephalopathies. *Nature* 2013;501:217-21.
- Kearney JA. Epi4K phase I: gene discovery in epileptic encephalopathies by exome sequencing. *Epilepsy Curr* 2014;14:208-10.
- Sanders SJ, Murtha MT, Gupta AR, Murdoch JD, Raubeson MJ, Willsey AJ, et al. De novo mutations revealed by whole-exome sequencing are strongly associated with autism. *Nature* 2012;485:237-41.
- Rauch A, Wieczorek D, Graf E, Wieland T, Ende S, Schwarzmayr T, et al. Range of genetic mutations associated with severe non-syndromic sporadic intellectual disability: an exome sequencing study. *Lancet* 2012;380:1674-82.
- Epi4K Consortium. Epi4K: gene discovery in 4,000 genomes. *Epilepsia* 2012;53:1457-67.
- Baxter P. Recent insights into pre- and postnatal pyridoxal phosphate deficiency, a treatable metabolic encephalopathy. *Dev Med Child Neurol* 2010;52:597-8.
- Schmitt B, Baumgartner M, Mills PB, Clayton PT, Jakobs C, Keller E, et al. Seizures and paroxysmal events: symptoms pointing to the diagnosis of pyridoxine-dependent epilepsy and pyridoxine phosphate oxidase deficiency. *Dev Med Child Neurol* 2010;52:e133-42.
- Baxter P. Pyridoxine-dependent and pyridoxine-responsive seizures. *Dev Med Child Neurol* 2001;43:416-20.
- Baxter P. Pyridoxine or pyridoxal phosphate for intractable seizures? *Arch Dis Child* 2005;90:441-2.
- Agadi S, Quach MM, Haneef Z. Vitamin-responsive epileptic encephalopathies in children. *Epilepsy Res Treat* 2013;2013:510529.
- Surtees R, Wolf N. Treatable neonatal epilepsy. *Arch Dis Child* 2007;92:659-61.
- Wolf B, Heard GS, Weissbecker KA, McVoy JR, Grier RE, Leshner RT. Biotinidase deficiency: initial clinical features and rapid diagnosis. *Ann Neurol* 1985;18:614-7.
- Salbert BA, Pellock JM, Wolf B. Characterization of seizures associated with biotinidase deficiency. *Neurology* 1993;43:1351-5.
- Wolf B. The neurology of biotinidase deficiency. *Mol Genet Metab* 2011;104:27-34.
- Wolf B. Clinical issues and frequent questions about biotinidase deficiency. *Mol Genet Metab* 2010;100:6-13.
- Joshi SN, Fathalla M, Koul R, Maney MA, Bayoumi R. Biotin responsive seizures and encephalopathy due to biotinidase deficiency. *Neurol India* 2010;58:323-4.
- Lundgren J, Blennow G. Vitamin B12 deficiency may cause benign familial infantile convulsions: a case report. *Acta Paediatr* 1999;88:1158-60.
- Erol I, Alehan F, Gumus A. West syndrome in an infant with vitamin B12 deficiency in the absence of macrocytic anaemia. *Dev Med Child Neurol* 2007;49:774-6.
- Rasmussen SA, Fernhoff PM, Scanlon KS. Vitamin B12 deficiency in children and adolescents. *J Pediatr* 2001;138:10-7.
- Ohtahara S, Yamatogi Y. Epileptic encephalopathies in early infancy with suppression-burst. *J Clin Neurophysiol* 2003;20:398-407.
- Zupanc ML. Clinical evaluation and diagnosis of severe epilepsy syndromes of early childhood. *J Child Neurol* 2009;24(8 Suppl):6S-14S.
- Ohtahara S, Ohtsuka Y, Yamatogi Y, Oka E. The early-infantile epileptic encephalopathy with suppression-burst: developmental aspects. *Brain Dev* 1987;9:371-6.
- Ohtahara S, Yamatogi Y. Ohtahara syndrome: with special reference to its developmental aspects for differentiating from early

- myoclonic encephalopathy. *Epilepsy Res* 2006;70 Suppl 1:S58-67.
32. Murakami N, Ohtsuka Y, Ohtahara S. Early infantile epileptic syndromes with suppression-bursts: early myoclonic encephalopathy vs. Ohtahara syndrome. *Jpn J Psychiatry Neurol* 1993;47:197-200.
 33. Fusco L, Pachatz C, Di Capua M, Vigeveno F. Video/EEG aspects of early-infantile epileptic encephalopathy with suppression-bursts (Ohtahara syndrome). *Brain Dev* 2001;23:708-14.
 34. Khan S, Al Baradie R. Epileptic encephalopathies: an overview. *Epilepsy Res Treat* 2012;2012:403592.
 35. Lombroso CT. Early myoclonic encephalopathy, early infantile epileptic encephalopathy, and benign and severe infantile myoclonic epilepsies: a critical review and personal contributions. *J Clin Neurophysiol* 1990;7:380-408.
 36. Dalla Bernardina B, Dulac O, Fejerman N, Dravet C, Capovilla G, Bondavalli S, et al. Early myoclonic epileptic encephalopathy (E.M.E.E.). *Eur J Pediatr* 1983;140:248-52.
 37. Mackay MT, Weiss SK, Adams-Webber T, Ashwal S, Stephens D, Ballaban-Gill K, et al. Practice parameter: medical treatment of infantile spasms: report of the American Academy of Neurology and the Child Neurology Society. *Neurology* 2004;62:1668-81.
 38. Wong M, Trevathan E. Infantile spasms. *Pediatr Neurol* 2001;24:89-98.
 39. Trevathan E, Murphy CC, Yeargin-Allsopp M. The descriptive epidemiology of infantile spasms among Atlanta children. *Epilepsia* 1999;40:748-51.
 40. Caraballo R, Vaccarezza M, Cersosimo R, Rios V, Soraru A, Arroyo H, et al. Long-term follow-up of the ketogenic diet for refractory epilepsy: multicenter Argentinean experience in 216 pediatric patients. *Seizure* 2011;20:640-5.
 41. Pellock JM, Hrachovy R, Shinnar S, Baram TZ, Bettis D, Dlugos DJ, et al. Infantile spasms: a U.S. consensus report. *Epilepsia* 2010;51:2175-89.
 42. Vigeveno F, Fusco L, Cusmai R, Claps D, Ricci S, Milani L. The idiopathic form of West syndrome. *Epilepsia* 1993;34:743-6.
 43. Lúthvígsson P, Olafsson E, Sigurthardottir S, Hauser WA. Epidemiologic features of infantile spasms in Iceland. *Epilepsia* 1994;35:802-5.
 44. Kivity S, Lerman P, Ariel R, Danziger Y, Mimouni M, Shinnar S. Long-term cognitive outcomes of a cohort of children with cryptogenic infantile spasms treated with high-dose adrenocorticotrophic hormone. *Epilepsia* 2004;45:255-62.
 45. Coppola G. Malignant migrating partial seizures in infancy: an epilepsy syndrome of unknown etiology. *Epilepsia* 2009;50 Suppl 5:49-51.
 46. Coppola G, Veggiotti P, Del Giudice EM, Bellini G, Longaretti F, Tagliatalata M, et al. Mutational scanning of potassium, sodium and chloride ion channels in malignant migrating partial seizures in infancy. *Brain Dev* 2006;28:76-9.
 47. Elia M. Myoclonic status in nonprogressive encephalopathies: an update. *Epilepsia* 2009;50 Suppl 5:41-4.
 48. Dalla Bernardina B, Fontana E, Darra F. Myoclonic status in nonprogressive encephalopathies. *Adv Neurol* 2005;95:59-70.
 49. Caraballo RH, Cersosimo RO, Espeche A, Arroyo HA, Fejerman N. Myoclonic status in nonprogressive encephalopathies: study of 29 cases. *Epilepsia* 2007;48:107-13.
 50. Covanis A. Update on Dravet syndrome. *Dev Med Child Neurol* 2011;53 Suppl 2:v-vi.
 51. Bok LA, Maurits NM, Willemsen MA, Jakobs C, Teune LK, Poll-The BT, et al. The EEG response to pyridoxine-IV neither identifies nor excludes pyridoxine-dependent epilepsy. *Epilepsia* 2010;51:2406-11.
 52. Bahi-Buisson N, Mention K, Leger PL, Valayanopoulos V, Nabbout R, Kaminska A, et al. Neonatal epilepsy and inborn errors of metabolism. *Arch Pediatr* 2006;13:284-92.
 53. Hoffmann GF, Schmitt B, Windfuhr M, Wagner N, Strehl H, Bagci S, et al. Pyridoxal 5'-phosphate may be curative in early-onset epileptic encephalopathy. *J Inherit Metab Dis* 2007;30:96-9.
 54. Mills PB, Footitt EJ, Mills KA, Tuschl K, Aylett S, Varadkar S, et al. Genotypic and phenotypic spectrum of pyridoxine-dependent epilepsy (ALDH7A1 deficiency). *Brain* 2010;133(Pt 7):2148-59.
 55. Sedel F, Gourfinkel-An I, Lyon-Caen O, Baulac M, Saudubray JM, Navarro V. Epilepsy and inborn errors of metabolism in adults: a diagnostic approach. *J Inherit Metab Dis* 2007;30:846-54.
 56. Mercimek-Mahmutoglu S, Patel J, Cordeiro D, Hewson S, Callen D, Donner EJ, et al. Diagnostic yield of genetic testing in epileptic encephalopathy in childhood. *Epilepsia* 2015;56:707-16.
 57. Helbig I. New technologies in molecular genetics: the impact on epilepsy research. *Prog Brain Res* 2014;213:253-78.