

The Modified Eden-Lange Tendon Transfer for Lateral Scapular Winging Secondary to Spinal Accessory Nerve Injury



Michael Gustin, MD, Nathan Olszewski, MD, Robert L. Parisien, MD, and Xinning Li, MD

Abstract: Trapezius paralysis following injury to the spinal accessory nerve can be a debilitating complication resulting from lymph node biopsy, radical neck dissection, or penetrating trauma in the region of the posterior cervical triangle. Disruption of the delicate muscular balance in the shoulder girdle may result in lateral scapular winging, ipsilateral upper extremity radiculopathy, and limited shoulder function and range of motion. Spontaneous recovery with nonoperative management is possible in some patients, and restoration of function after reparative neural procedures has been observed in patients undergoing timely repair. However, extended delays from the time of injury to surgery are common and may necessitate various muscle transfers to reestablish the complex biomechanics and balance of the shoulder girdle. We describe a modification to the classic Eden-Lange procedure with lateral transfer of the levator scapulae and rhomboid minor to the scapula spine and rhomboid major transfer with a small wafer of bone to the scapula body for chronic lateral winging of the scapula following injury to the spinal accessory nerve as the result of a cervical lymph node biopsy.

Trapezius paralysis following injury to the spinal accessory nerve can be a debilitating complication resulting from cervical lymph node biopsy, radical neck dissection, or penetrating trauma in the region of the posterior cervical triangle. The spinal accessory nerve is particularly vulnerable in this anatomic region given its superficial path, thus predisposing the nerve to neuropraxic, axonotmetic, or neurotmetic injury.¹⁻³ The loss of trapezius innervation disrupts the intricate muscular balance around the shoulder that serves as the basis for scapulohumeral rhythm and the symmetrical suspension of the shoulder girdle.³⁻⁶ The manifestations of such imbalance can be functionally debilitating for

patients, who may exhibit a shoulder droop on physical examination and lateral winging of the scapula, while exhibiting profound limitations in forward flexion and abduction; they may also experience neuropraxia in the ipsilateral upper extremity as a result of brachial plexus traction and impingement.³⁻⁵

When surgical intervention is indicated, there is a narrow window of time in which neurolysis, nerve graft, or end-to-end repair of the spinal accessory nerve can achieve acceptable levels of pain-free function and return to previous activities.⁷⁻¹⁰ Although recent evidence indicates an emerging role for direct nerve transfer in those who are not candidates for primary nerve repair, these techniques are technically demanding, and long-term results are lacking.^{11,12} Also, delayed nerve transfers do not always return the function of the entire trapezius muscle, leading to continued imbalance of the scapula.¹² In young, active patients, those with a delayed interval from initial injury to presentation, an irrecoverable nerve stump, or idiopathic palsy may be present and preclude the possibility of successful primary neural surgery. The Eden-Lange muscle transfer can alleviate pain, improve range of motion, and restore the functional capacity and balance of the shoulder girdle.^{5,13-22}

The primary goal of the procedure is to mimic the balanced force normally exerted by a functional trapezius muscle via transfer of the levator scapulae, rhomboid

From Boston University School of Medicine, Boston, Massachusetts, U.S.A. (M.G., N.O., X.L.); and Harvard Medical School, Boston, Massachusetts, U.S.A. (R.L.P.)

The authors report the following potential conflicts of interest or sources of funding: X.L. reports other from FH Ortho. Full ICMJE author disclosure forms are available for this article online, as [supplementary material](#).

Received April 8, 2020; accepted June 17, 2020.

Address correspondence to Xinning Li, MD, Department of Orthopaedic Surgery, Boston University School of Medicine, Boston, MA. 02118, U.S.A. E-mail: xinning.li@gmail.com

© 2020 by the Arthroscopy Association of North America. Published by Elsevier. This is an open access article under the CC BY-NC-ND license (<http://creativecommons.org/licenses/by-nc-nd/4.0/>).

2212-6287/20601

<https://doi.org/10.1016/j.eats.2020.06.026>

major, and rhomboid minor lateral to their usual anatomic insertion on the scapula.^{5,6} First described by Eden and later corroborated by Lange, the Eden-Lange transfer produces good to excellent outcomes in 57% to 75% of patients.^{18,23,24} The Eden-Lange procedure has undergone multiple modifications since first being described in 1924, differing in the final placement of the rhomboid major, rhomboid minor, or levator scapulae muscles, with excellent results reported in 59% to 95% of patients.^{13,15} Recent technical advances have shown good to excellent outcomes in case reports and small case series.^{16,18-21}

In this technical report, we describe a modification to the classic Eden-Lange tendon transfer in a woman with chronic lateral scapular winging secondary to spinal accessory nerve injury from a cervical lymph node dissection 9 years prior (Figure 1A, B). In our modified technique, the levator scapulae muscle is transferred along with the rhomboid minor muscle laterally to the scapular spine while the rhomboid major is transferred laterally to the scapular body with a small wafer of bone.

Technique

Patient Position and Setup

Table 1 shows the critical steps of our procedure. The patient is intubated while supine on a stretcher and then transferred into the prone position on the operating room table (Figure 2A; Video). The operative side of the patient is prepped from the midline along the

spine laterally to the axilla and superiorly from the base of the neck to ~10 cm inferior to the inferior border of the scapula to include the entire scapula. The ipsilateral arm is likewise prepped to facilitate easy intraoperative manipulation and positioning and for reduction of the scapula during the muscle transfer (Figure 2A). Landmarks including the acromion, the scapular spine, the superior and inferior angles, and the medial border of the scapula are palpated and drawn in with a sterile marking pen, along with the planned incision, ~2 to 3 cm medial to the medial border of the scapula (Figure 2B).

Harvesting the Muscles for Transfer

An vertical incision is made 2 to 3 cm medial to the medial border of the scapula along its entire length (Figure 2B). The soft tissue dissection is carried through the fascia with electrocautery, and the fascia is tagged with #2 braided sutures. The dissection is then continued with the electrocautery device until the atrophic trapezius muscle can be identified. The atrophic trapezius is incised laterally along the medial border of the scapula to prevent damage to the underlying rhomboids, splitting it into medial and lateral flaps, which are tagged and reflected back with #2 braided sutures (Figure 3A). The superior and medial border of the scapula is then identified along with the insertion of the levator scapulae, rhomboid minor, and rhomboid major muscles. While harvesting these muscles, great care is taken to avoid injury to the dorsal scapular nerve, which runs along the deep aspect of

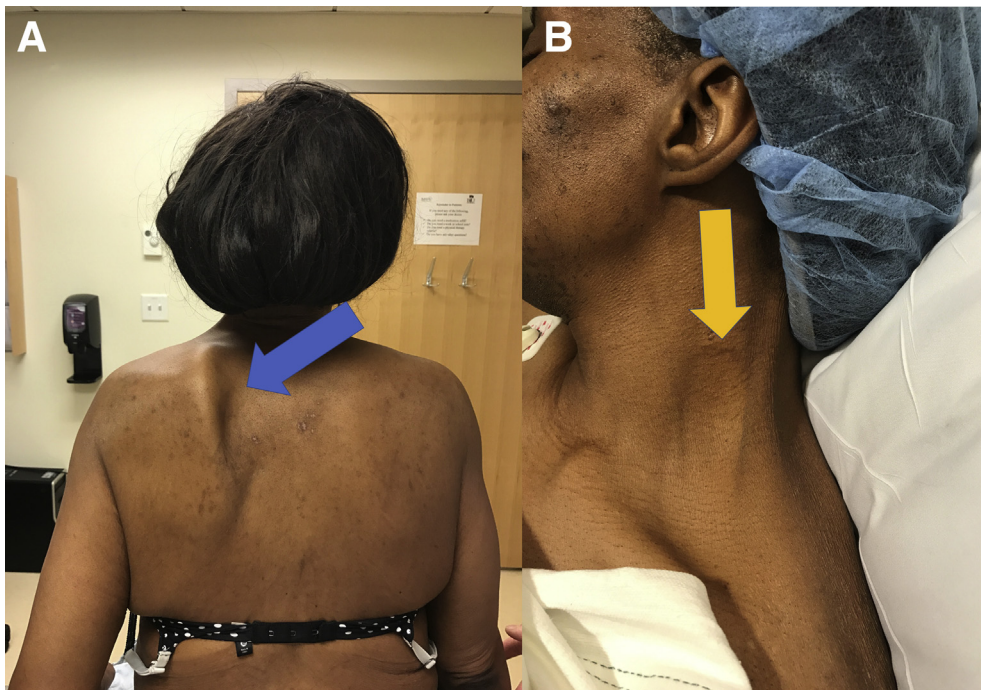

Figure 1. Patient before the procedure (A), exhibiting left lateral scapular winging (blue arrow) secondary to complete trapezius palsy after iatrogenic injury (B) to the left spinal accessory nerve in the posterior triangle during cervical lymph node dissection (scar denoted by yellow arrow), one of the most common causes of spinal accessory nerve palsy.

Table 1. The Critical Surgical Steps to the Modified Eden-Lange Technique

1. The patient is intubated while supine on the stretcher and then transferred to the prone position on the operating table.
2. The operative side is prepped leaving the entire scapula exposed, prepping as far superiorly and anteriorly as the anterior trapezius and acromion and as far medially as the spine. The arm should be prepped in for positioning purposes.
3. Palpate major surgical landmarks including the acromion, the spine of the scapula, the superior angle of the scapula, the medial border, and the inferior angle of the scapula and draw them in with a sterile marking pen.
4. Make an incision 2-3 cm medial to the medial border of the scapula along its entire length.
5. Dissect down the soft tissue until the atrophied trapezius is identified. Open the trapezius with a bovie to create medial and lateral flaps, which are tagged with #2 braided suture and reflected back.
6. Identify the superior angle and medial border of the scapula, along with the insertion sites of the levator scapulae and the rhomboid minor and major.
7. Dissect out the levator scapulae and rhomboid minor from their insertions to ~4 cm proximally. Be aware that the dorsal scapular nerve runs medial and deep to the medial border of the scapula on the deep side of these muscles and be sure not to injure it. Use a blunt instrument to pass a penrose around the levator scapulae and rhomboid minor and tag the muscle-tendon unit with a #2 braided suture. Using the suture to tension the muscle-tendon unit, harvest the levator scapulae and rhomboid minor as 1 muscle tendon unit at their insertion site using electrocautery.
8. Dissect and mobilize the rhomboid major from its insertion along the medial border of the scapula. Using a sagittal saw, harvest the rhomboid major along with a small wafer of bone from the medial border of the scapula, and tag with #2 suture.
9. Elevate the infraspinatus and subscapularis muscles medially to laterally off the body of the scapula ~5 to 6 cm from the medial border of the scapula.
10. Drill 4 holes along the length of the body of the scapula in the exposed infraspinatus fossa ~4 to 5 cm from the medial border using a 2-mm drill bur. These should be drilled far enough apart to shuttle sutures between them. Using the needle from a #2 FiberWire suture, shuttle 4 sutures across the drill holes, resulting in 8 suture limbs with which to affix the rhomboid major transfer. The scapular body is very thin, and the tip of the needle will pass through; thus drilling 4 holes will allow passage of the needles with 8 suture limbs. Then pass each suture needle through the rhomboid major and bone wafer along its length in preparation for transfer later.
11. Make a 3-cm incision 4-5 cm medial to the lateral edge of the acromion, parallel and just superior to the spine of the scapula. Dissect down through the soft tissue, stripping away the deltoid and trapezius, exposing bone. Drill 2 holes using a 2-mm bur in the cephalad-to-caudad direction through the spine of the scapula, and shuttle a #2 Fiberwire through the drill holes. (Alternatively, suture anchors can also be used for this step)
12. Using blunt dissection, create a soft tissue tunnel from the spine of the scapula at the site of the drill holes through which the levator scapulae and rhomboid minor muscle-tendon unit can be passed.
13. Using a large Kelly placed through the soft tissue tunnel, grasp the braided suture tag of the levator scapulae and rhomboid minor muscle-tendon unit and pull them through the tunnel. Using the shuttled #2 FiberWire in the spine of the scapula, affix the muscle-tendon unit in place using Mason-Allen Stitches. Make sure the scapula is reduced medially to help with the transfer.
14. Keep the scapula reduced medially into neutral anatomic position to facilitate close approximation of the bone wafer to the scapular body. Using the previously passed #2 FiberWire sutures in the body of the scapula and along the distal rhomboid major and bone wafer, affix the rhomboid major to its new lateralized position using simple interrupted sutures. Reinforce these sutures by tying them to one another.
15. Reinforce the infraspinatus muscle over and onto the rhomboid major transfer with #2 braided sutures.
16. After irrigating both wounds, restore the atrophic trapezius using #2 braided sutures.
17. Close both wounds with 2-0 Monocryl and 3-0 running Monocryl along with Dermabond.
18. The patient is placed in a sling with an abduction bump after being returned to supine position.

these muscles and medially to the medial border of the scapula. The levator scapulae and rhomboid minor muscles are carefully separated and mobilized from their insertions on the superior angle and superomedial border of the scapula. Passing a penrose drain around them with a blunt instrument helps separate them as a unit from the rhomboid major. Before harvesting, both muscles (levator scapulae and rhomboid minor) are tagged with a #2 braided suture (Figure 3B). Using the braided suture to tension the 2-muscle/tendon unit, the levator scapulae and rhomboid minor are harvested together and released from the superomedial border of the scapula using electrocautery (Figure 4A, blue arrow). The rhomboid major is then dissected out and harvested with a small wafer of bone taken from the medial border of the scapula using a sagittal saw (Figure 4A, yellow star). The rhomboid major is tagged with #2 braided sutures around the wafer of bone to help with the mobilization and transfer.

Preparation of the Scapula for Rhomboid Major Transfer

Attention is then turned to the infraspinatus muscle, which is lifted from the infraspinatus fossa of the scapula ~5 to 6 cm medially to laterally using an electrocautery device and a Cobb elevator. The subscapularis muscle is similarly lifted off the anterior or deep surface of the body of the scapula approximately the same distance. An electrocautery pen is used to mark the location on the scapular body for the rhomboid major and bone wafer transfer. A 2-mm drill bur is used to make 4 drill holes spaced out about 1.5 cm apart along the length of the scapula in the infraspinatus fossa ~4 to 5 cm lateral to the medial border of the scapula and far enough apart to allow for shuttling suture across the holes (Figure 4B; Video). The needle from four #2 braided sutures (FiberWire; Arthrex, Naples, FL) are shuttled across adjacent drill holes, resulting in 8 total suture ends in preparation for the transfer

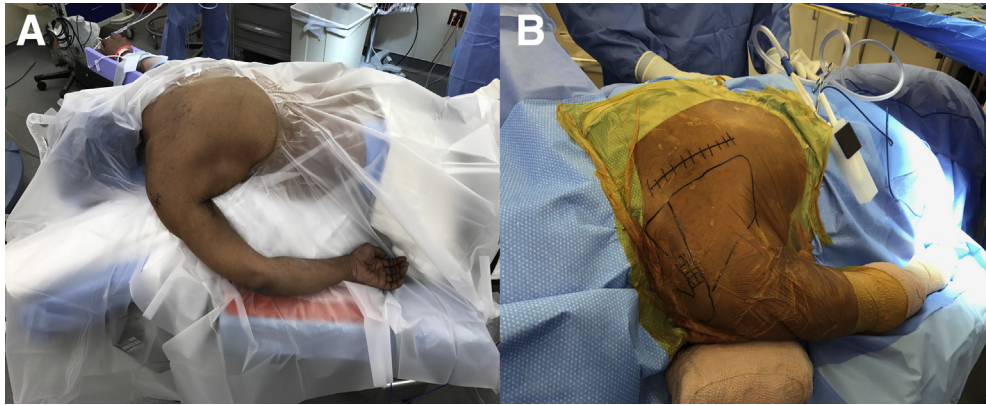


Figure 2. Intraoperative images of the left shoulder with the patient in prone position, with the head of the bed at the left of the images. (A) The patient should be placed in prone position after intubation and prepped widely to include the arm, which should be accessible to positioning. (B) With anatomic landmarks clearly marked, an incision is made 2 to 3 cm medial to the medial border of the scapula along its entire length.

(Figure 5A). If unable to shuttle the needle effectively through the drill holes, a heavy #2 needle will often be able to pass through the thin bone of the scapular body. The suture needle is then passed through the rhomboid major and wafer of bone in preparation to be tied down after fixation of the levator scapulae and rhomboid minor muscle/tendon unit to the spine of the scapula.

Preparation of the Scapular Spine for the Levator Scapulae and Rhomboid Minor Transfer

A small 3- to 4-cm incision is then made ~4 to 5 cm medial to the lateral edge of the acromion, parallel to the scapular spine, and the soft tissue is dissected down. The trapezius and deltoid muscles are stripped anteriorly and posteriorly, respectively, exposing the scapular

spine (Figure 5B). Two drill holes are then fashioned through the exposed spine of the scapula in a cephalad-to-caudad direction using a 2-mm bur (Figure 5B). No. 2 sutures are passed into the drill holes for the transfer. Avoid drilling the transfer target too laterally, as this can result in a web-neck deformity and may endanger the suprascapular nerve and artery. Alternatively, metal suture anchors can also be used to affix the muscle/tendon unit to the scapular spine.

Muscle Transfer of the Levator Scapulae and Rhomboid Minor Muscle

A soft tissue tunnel is fashioned laterally to medially toward the superior angle of the scapula using blunt dissection through which the levator scapulae and

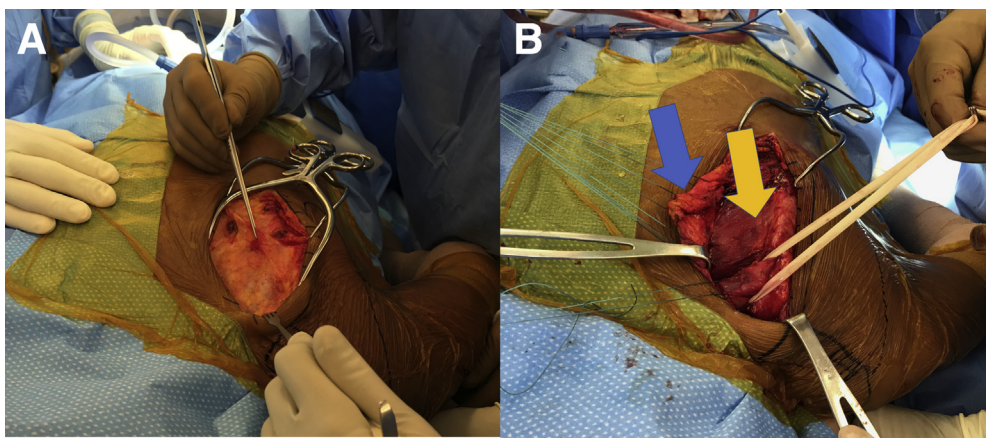


Figure 3. Intraoperative images of the left shoulder with the patient in prone position as viewed from the head of the bed. (A) The soft tissue is dissected down, with the fascia opened and tagged until the trapezius muscle can be identified. The trapezius will appear grossly atrophic with fatty infiltration. (B) The medial border of the scapula is identified, and the trapezius is detached laterally to avoid injury to the rhomboid muscles and reflected medially (blue arrow), revealing the insertion of the rhomboid major and minor and the levator scapula (yellow arrow). A penrose drain is placed around the levator scapulae and the rhomboid minor muscle, and these are tagged with a #2 braided suture, which will be used to tension the muscles, allowing for easy harvesting as a single muscle-tendon unit.

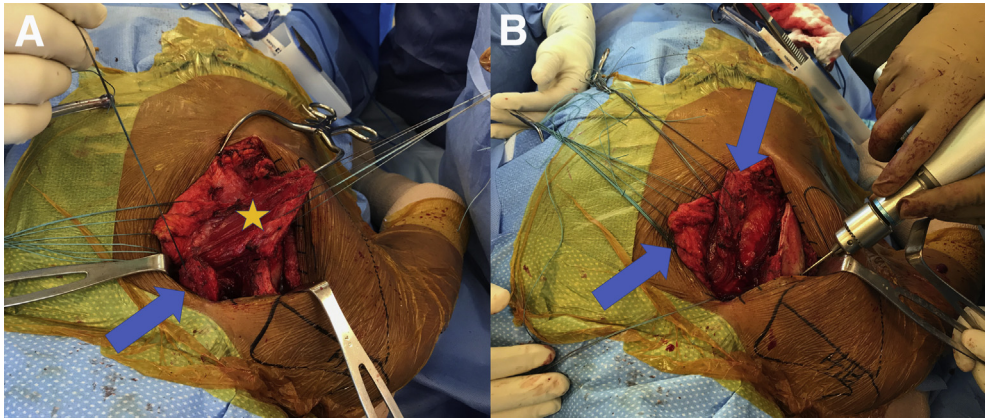


Figure 4. Intraoperative images of the left shoulder with the patient in prone position as viewed from the head of the bed. (A) The rhomboid major is dissected out and harvested with a small wafer of bone (yellow star) from the medial border of the scapula, which will allow for stronger fixation and promote bone-to-bone healing. The wafer of bone is tagged with #2 braided sutures. The levator scapulae and rhomboid minor are identified from the superior medial border of the scapula, dissected out, and tagged with braided sutures (blue arrow), which will allow the structures to be easily passed through the soft tissue tunnel to the scapular spine. (B) With the tagged trapezius and rhomboid major muscles reflected medially (blue arrows) and the infraspinatus and subscapularis muscles lifted from the body of the scapula, a 2-mm drill bur is used to make 4 to 5 drill holes 4 to 5 cm lateral to the medial border of the scapula in the infraspinatus fossa. These will serve as the site of fixation for the transferred rhomboid major with the bone wafer, in an attempt to emulate the line of pull of the lower trapezius fibers.

rhomboid minor may be passed. Using a large Kelly clamp, the braided #2 suture tagging the levator scapulae and rhomboid minor is used to shuttle the 2-muscle/tendon unit through the soft tissue tunnel. The levator scapulae and the rhomboid minor are then affixed to the spine of the scapula using Mason-Allen stitches through the 2 drill holes via the previously placed #2 FiberWire sutures (Figure 6A). Alternatively, large free needles can be used to shuttle the #2 sutures from the muscle/tendon unit into these 2 drill holes to

fix down the transfer. Reduction of the scapula medially will help facilitate the muscle transfer.

Muscle Transfer of the Rhomboid Major and Bone Wafer

Next, the scapula is kept reduced in neutral anatomic position in preparation for the transfer of the rhomboid major and wafer of bone to ensure medialization of the scapula to restore muscular balance. Using the sutures in the infraspinatus fossa,

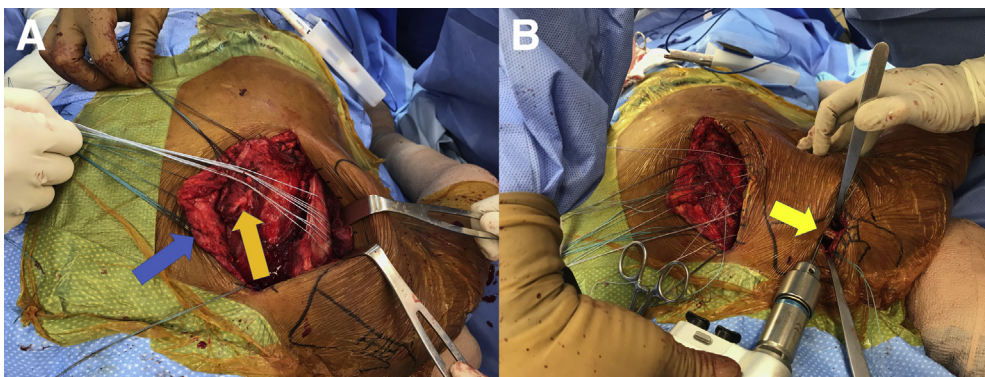


Figure 5. Intraoperative images of the left shoulder with the patient in prone position as viewed from the head of the bed. (A) With the trapezius (blue arrow) and rhomboid major (yellow arrow) reflected medially, braided sutures are shuttled across the adjacent drill holes in the body of the scapula, resulting in 8 total suture limbs, which will be used to affix the rhomboid major laterally with the bone wafer. Drill holes should be spaced far enough apart to be able to easily pass a suture between adjacent holes. (B) A small incision is made ~4 to 5 cm medial to the lateral aspect of the acromion, and the soft tissue is dissected down to the spine. Two drill holes are made in the spine of the scapula, through which a #2 braided suture will be shuttled after the muscle has been stripped away using a 2-mm bur (yellow arrow). These holes should once again be spaced to allow for easy suture shuttling.

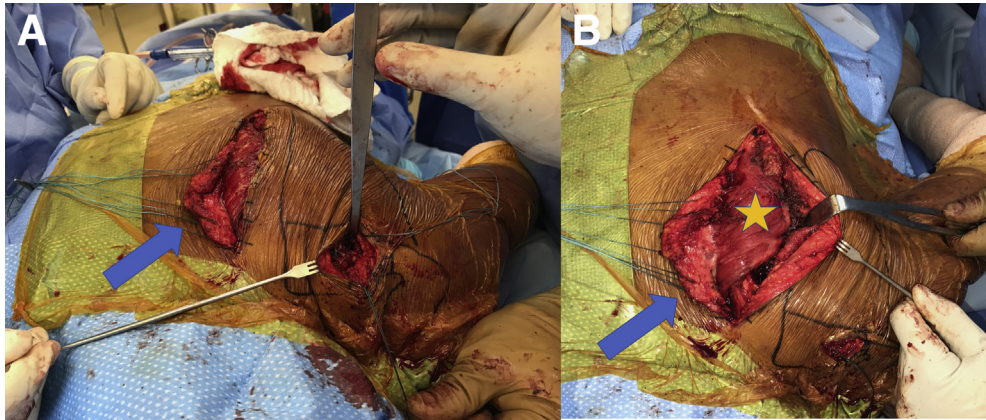


Figure 6. Intraoperative images of the left shoulder with the patient in prone position as viewed from the head of the bed. (A) The levator scapulae and the rhomboid minor are passed through the soft tissue tunnel and affixed to the spine of the scapula using Mason-Allen stitches through the previously drilled holes. This transosseous technique is preferable; alternatively, suture anchors can be used to fix down the transfer. (B) The scapula should be reduced to neutral anatomic position with a shoulder bump and proper arm positioning to closely appose the transfer site on the scapular body with the rhomboid major and bone wafer. With the trapezius reflected medially (blue arrow), the rhomboid major along with the bone wafer are tied down using the sutures in the infraspinatus fossa (yellow star). These are further reinforced to each other with the residual sutures.

the rhomboid major and bone wafer are tied down to the infraspinatus fossa via 4 simple interrupted sutures (Figure 6B). The sutures are then reinforced or tied to each other, and the infraspinatus muscle is reinforced onto the muscle transfer with #2 braided sutures.

Wound Closure

The wound is copiously irrigated, and the medial and lateral flap of the atrophic trapezius muscle is restored with #2 Ethibond suture in an interrupted fashion (Figure 7A). Both wounds are closed with 2-0 Monocryl and 3-0 running Monocryl along with Dermabond (Johnson & Johnson, New Brunswick, NJ) (Figure 7B). The patient is returned to the supine position and placed in a shoulder sling with an abduction bump sling (UltraSling; DJO Global, Lew- erville, TX).

Postoperative Rehabilitation

The patient is admitted for overnight observation and pain control, with 23 hours of intravenous antibiotics. The UltraSling with the arm abducted is used for 6 weeks. Gentle passive range of motion (ROM) of the shoulder is started 4 weeks after surgery in the supine position to keep the scapula stabilized. Transition to upright shoulder ROM occurs 6 to 8 weeks after surgery; when the patient is able to lift the arm, active assisted ROM starts. We allow the patient to start gentle strengthening at ~4 months after surgery and to return to full activities 9 to 12 months from the time of surgery, depending on the progression.

Discussion

Older, sedentary, lower-demand patients as well as those suffering from traction neurapraxia may achieve an acceptable outcome with physical therapy and pain

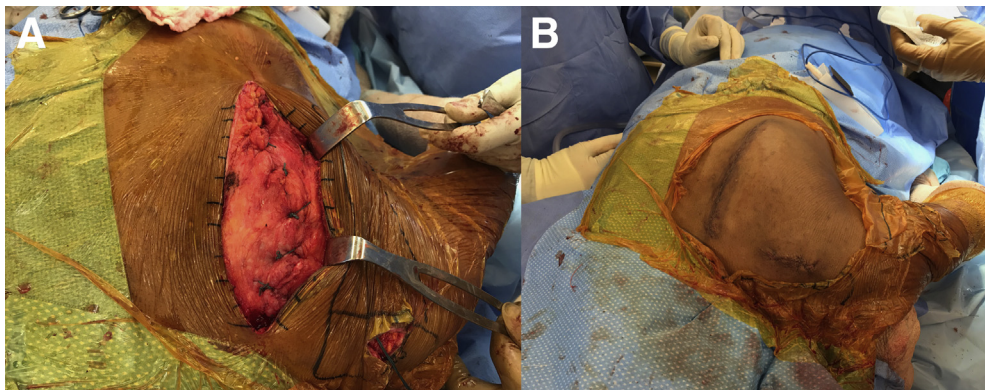


Figure 7. Intraoperative images of the left shoulder with the patient in prone position as viewed from the head of the bed. (A) The tagged trapezius layer is easily reattached with interrupted sutures using #2 Ethibond. (B) Both wounds are closed with 2-0 Vicryl, 2-0 Monocryl, 3-0 running Monocryl, and Dermabond.

Table 2. Advantages and Disadvantages of the Modified Eden-Lange Technique

Advantages
1. Properly executed dynamic muscle transfers do not carry the same risk of graft failure as fascial slings and are not subject to the high rate of complications and severe range of motion defects associated with scapulothoracic arthrodesis.
2. Young and healthy patients are able to return to previous activities at or near preoperative level.
3. In patients with chronic pain and difficulty lifting their arms due to the lateral scapular winging, a properly done muscle transfer can help alleviate pain and improve shoulder function.
4. Transferring both the levator scapulae and rhomboid minor muscle to the scapular spine better re-creates the upper and middle trapezius muscle.
5. Using a wafer of bone with the rhomboid major muscle may have better healing potential (bone to bone) versus all soft tissue transfer.
Disadvantages
1. The procedure is technically challenging and time intensive.
2. Requires slow rehabilitation, and the patient must be compliant with the postoperative protocol.
3. Very few bailout options exist for patients who fail the primary muscle transfer.
4. Final outcome may not completely restore shoulder function and provide complete pain relief. It is important to talk with patients about expectations before surgery.

management after lateral scapular winging secondary to spinal accessory nerve insult.^{3,14} However, the inability to raise the arm above the shoulder, involvement of the dominant arm, and scapular winging portend poor outcomes in patients managed conservatively, with evidence demonstrating limited functional status.^{18,25} Before surgery, our patient complained of persistent pain and exhibited profound lateral scapular winging for almost 9 years, along with significantly limited shoulder function with active forward flexion of only 50°, abduction of 40°, and external rotation of 30°, but demonstrated preserved passive ROM. These are the classic surgical indications for an Eden-Lange muscle transfer.

Although the precise window of opportunity for recovery of trapezius function after nerve repair, neurolysis, or nerve grafting is still up for debate, delay of >1 to 2 years has been shown to result in worse outcomes.^{9,11,13-15,17,18} Teboul et al.^{23,24} reported on a cohort of 27 patients with trapezius palsy. They performed neurolysis or surgical repair in 20 patients an average of 7 months after injury and performed an Eden-Lange procedure in the remaining 7 patients an average of 28 months after injury. They reported good to excellent outcomes in 80% of patients (16 of 20) treated with neurolysis or repair and 57% of patients (4 of 7) who underwent the Eden-Lange procedure.²⁴ The authors concluded that good results can be obtained from neurolysis or repair of the spinal accessory nerve if performed within 20 months of injury. They further recommend Eden-Lange muscle transfer for failed

neurolysis or repair as well as for patients who are >20 months out from injury. Conversely, Camp and Birch⁷ did not find an association of delay to nerve surgery and recovery, as they reported good to excellent outcomes in 49 of 71 patients ≤3.5 years after injury. In the patient described here, her symptoms started after a cervical lymph node biopsy 9 years ago. Given the chronicity of her injury, she was indicated for a modified Eden-Lange muscle transfer.

The Eden-Lange procedure has become the procedure of choice in dynamic stabilization of the scapula in active, young patients with trapezius paralysis and lateral scapular winging >1 year after injury and has yielded consistently good results in its many iterations.^{1,3,7,9,13,15,16,18,19,24} The classic Eden-Lange procedure attempts to restore proper scapular kinematics and scapulohumeral rhythm. In the absence of normal trapezial force vectors, the unopposed activity of the serratus anterior, deltoid, and rotator cuff musculature results in characteristic lateral scapular winging and abnormal glenohumeral biomechanics.^{5,6} Therefore, the transfer of the levator scapulae along the spine of the scapula is intended to recreate the force vector of the upper portion of the trapezius, resulting in proper elevation and upward rotation of the scapula. Similarly, the transfer of the rhomboid major and minor along the infraspinatus fossa, lateral to the medial border of the scapula, attempts to recreate the force vector of the middle and lower trapezius, resulting in retraction and rotation of the scapula to provide the stabilizing forces. Using this technique, Teboul et al.^{23,24} reported 3 excellent, 1 good, and 3 poor outcomes in 7 patients, and Romero and Gerber¹⁸ described 9 excellent, 2 fair, and 1 poor outcome in a series of 12 patients at a mean of 32 years' follow-up. Alternative approaches to stabilization with use of fascial slings²⁶ and scapulothoracic arthrodesis²⁷ have also been used; however, graft failure, poor ROM, and high complication rates limit their utility.

In our technique, we modified the classic Eden-Lange procedure by transferring both the levator scapulae and the rhomboid minor as a unit to the scapular spine and the rhomboid major with a small wafer of bone to the scapular body to manage trapezius paralysis and chronic lateral scapular winging, which resulted from iatrogenic injury to the spinal accessory nerve during a cervical lymph node dissection 9 years prior. The reason for the double tendon transfer of both the levator scapulae and rhomboid minor to the scapular spine is to better recreate the upper and middle trapezius muscle strength and line of pull. Specifically, transfer of the rhomboid minor to the spine of the scapula creates a more medial-lateral line of pull that mimics the middle trapezius, rather than a transfer to the infraspinatus fossa, as in the classic Eden-Lange technique, which creates an oblique line of pull parallel to that of levator scapulae, which can promote downward scapular

Table 3. Pearls and Pitfalls

Pearls

1. In the prone position, the entire scapula and the upper superior medial border must be prepped in the sterile field.
2. Use of 2 incisions, as opposed to 1, and a long-curved incision allows for a more aesthetically pleasing incision.
3. The first layer encountered is the atrophic trapezius musculature and must be separated out from the rhomboid major and minor muscle underneath. Using a #2 suture to tag the medial flap of the trapezius will help with the mobilization of the muscle.
4. Isolate both the levator scapulae and the rhomboid minor muscle with a penrose drain, then tag them with #2 sutures before harvesting. Take care to avoid damage to the dorsal scapular nerve.
5. Harvesting the rhomboid major with a small wafer of bone may result in better healing potential and also make it easier to tie down to the scapula body for the transfer.
6. Carefully plan drill holes in the scapula body to allow for shuttling of sutures. Two holes can be drilled parallel to each other for a double row suture repair of the transfer.
7. Use a curved needle with #2 braided sutures to help with passing the sutures through the scapula body. The tip of the needle will go through the thin scapular body very easily to allow passage. If 4 needles are used, drilling 4 holes spaced out is adequate.
8. Transfer the levator scapulae and rhomboid minor through the soft tissue tunnel onto the spine of the scapula approximately 4 to 5 cm from the lateral edge of the acromion with drill holes and use #2 sutures to tie down the tendons. Suture anchors can also be used for this step instead of the drill holes and #2 sutures.
9. The scapula must be reduced medially to its anatomic location before fixing down the muscle transfers.
10. Suture the infraspinatus muscle directly onto the rhomboid major to reinforce the transfer.
11. Close the trapezius muscle flap with #2 sutures.
12. Use running absorbable suture and dermabond to close the incision. No drain is needed.

Pitfalls

1. Improperly placed drill holes make suture shuttling difficult.
2. Drill holes placed too close together may carry a risk of fracture of the scapula body.
3. The procedure is likely inadequate in treating spinal accessory nerve palsy using the muscle transfer technique in patients with concomitant long thoracic nerve palsy.
4. Very few bailout options are available if the transfer fails or fracture of the scapular body occurs.
5. If there is fracture of the scapula spine, the bailout would be to use metal suture anchors to assist in the transfer of the levator and rhomboid minor.
6. Postoperative rehabilitation is very time consuming and intensive. Patients must be committed to the postoperative protocol.

rotation.²² The rhomboid major is transferred to its traditional position in the infraspinatus fossa to recreate the lower trapezius muscle. [Tables 2 and 3](#) describe the advantages, disadvantages, pearls, and pitfalls of our procedure.

Multiple modifications to the Eden-Lange procedure have been published. A popular modification in which the rhomboid minor is transferred more superiorly to the supraspinous fossa was proposed by Bigliani et al. in 1996.¹³ In their series, 13 of 22 patients undergoing the modified Eden-Lange muscle transfer reportedly achieved good to excellent results. Twelve patients resumed normal activities in a variety of sports, 6 achieved satisfactory results, and 3 were reported to have poor results.¹³ This modification has been used with some success demonstrated in case reports and small case series.^{13,16,19,20} More recently, Elhassan and Wagner¹⁵ modified the procedure, transferring all 3 muscles along the spine of the scapula in a “triple tendon transfer,” with the levator scapulae most lateral and the rhomboid major most medial with the rhomboid minor in between. In this series of 22 patients, 21 patients achieved significant improvement in functional status and pain and were able to return to full activities without limitation.¹⁵ The triple tendon transfer attempts to improve on the original Eden-Lange technique by more accurately recreating the anatomic vector created by the orientation of the trapezius muscle fibers with respect to its origin in the middle and

lower portions, consequently restoring a more natural scapulothoracic rhythm.

A recent follow-up cadaveric biomechanical study examining the merit of this technique in restoring native motion showed that the triple tendon transfer indeed produced a degree of upward scapular rotation significantly more congruent to native motion than the classic Eden-Lange procedure.²² This study, however, did not examine upward rotation in the commonly used Bigliani modification or any of the additional motions of the scapula; also, the researchers did not load the serratus anterior, which contributes to upward rotation of the scapula and could feasibly play a important role in the setting of trapezius palsy with tendon transfer. Although the study results are impressive, these shortcomings leave a few important questions unanswered in determining its superiority over other modified techniques, and the triple tendon transfer adds an additional level of complexity to an already challenging and complex procedure. By way of example, a recent series by Amroodi and Salariyeh²¹ using a single-incision classic Eden-Lange technique in 11 patients produced similarly excellent results; however, surgical intervention in the patients occurred at a significantly earlier time point after injury and the indications were poorly defined.

Although modified techniques have demonstrated excellent outcomes in small case series, it is important to note that many of the fair and poor outcomes of the

original technique were seen in the elderly patient population or in patients with concomitant long thoracic nerve palsy, which we now recognize represents a contraindication to Eden-Lange tendon transfer and was thus excluded from Elhassan and Wagner's triple tendon transfer cohort.¹⁵ Additionally, in the study by Bigliani et al.,¹³ patients underwent much earlier mobilization with a more aggressive rehabilitation protocol, which may contribute to the outcome discrepancy in comparison to the Elhassan and Wagner study.¹⁵

It is important to recognize and diagnose patients who present with lateral scapular winging in the setting of spinal accessory nerve injury. Primary nerve repair may be an option for patients if performed during the early phase of injury (within 1 year). In the small subset of patients who have persistent chronic functional deficit after a prolonged course of physical therapy, both the classic Eden-Lange and modified techniques can provide significant benefit to patients and improve outcomes.

References

- Gooding BW, Geoghegan JM, Wallace WA, Manning PA. Scapular winging. *Shoulder Elbow* 2014;6:4-11.
- Kelley MJ, Kane TE, Leggin BG. Spinal accessory nerve palsy: Associated signs and symptoms. *J Orthop Sports Phys Ther* 2008;38:78-86.
- Wiater JM, LU Bigliani. Spinal accessory nerve injury. *Clin Orthop Relat Res* 1999;368:5-16.
- Inman VT, Saunders JB, Abbott LC. Observations of the function of the shoulder joint. 1944. *Clin Orthop Relat Res* 1996;(330):3-12.
- Didesch JT, Tang P. Anatomy, etiology, and management of scapular winging. *J Hand Surg Am* 2019;44:321-330.
- Lee S, Savin DD, Shah NR, Bronsnick D, Goldberg B. Scapular winging: Evaluation and treatment. AAOS Exhibit Selection. *J Bone Joint Surg Am* 2015;97:1708-1716.
- Camp SJ, Birch R. Injuries to the spinal accessory nerve: A lesson to surgeons. *J Bone Joint Surg Br* 2011;93:62-67.
- Donner TR, Kline DG. Extracranial spinal accessory nerve injury. *Neurosurgery* 1993;32:907-910.
- Goransson H, Leppanen OV, Vastamaki M. Patient outcome after surgical management of the spinal accessory nerve injury: A long-term follow-up study. *SAGE Open Med* 2016;4. 2050312116645731.
- Novak CB, Mackinnon SE. Patient outcome after surgical management of an accessory nerve injury. *Otolaryngol Head Neck Surg* 2002;127:221-224.
- Cambon-Binder A, Preure L, Dubert-Khalifa H, Marcheix PS, Belkheyar Z. Spinal accessory nerve repair using a direct nerve transfer from the upper trunk: Results with 2 years follow-up. *J Hand Surg Eur Vol* 2018;43:589-595.
- Mayer JA, Hruby LA, Salminger S, Bodner G, Aszmann OC. Reconstruction of the spinal accessory nerve with selective fascicular nerve transfer of the upper trunk. *J Neurosurg Spine* 2019;31:133-138.
- Bigliani LU, Compito CA, Duralde XA, Wolfe IN. Transfer of the levator scapulae, rhomboid major, and rhomboid minor for paralysis of the trapezius. *J Bone Joint Surg Am* 1996;78:1534-1540.
- Bigliani LU, Perez-Sanz JR, Wolfe IN. Treatment of trapezius paralysis. *J Bone Joint Surg Am* 1985;67:871-877.
- Elhassan BT, Wagner ER. Outcome of triple-tendon transfer, an Eden-Lange variant, to reconstruct trapezius paralysis. *J Shoulder Elbow Surg* 2015;24:1307-1313.
- Galano GJ, Bigliani LU, Ahmad CS, Levine WN. Surgical treatment of winged scapula. *Clin Orthop Relat Res* 2008;466:652-660.
- Guettler JH, Basamania CJ. Muscle transfers involving the shoulder. *J Surg Orthop Adv* 2006;15:27-37.
- Romero J, Gerber C. Levator scapulae and rhomboid transfer for paralysis of trapezius. The Eden-Lange procedure. *J Bone Joint Surg Br* 2003;85:1141-1145.
- Skedros JG, Kiser CJ. Modified Eden-Lange procedure for trapezius paralysis with ipsilateral rotator cuff-tear arthropathy: A case report. *J Bone Joint Surg Am* 2011;93(1-5):e131.
- Skedros JG, Knight AN. Treatment of scapular winging with modified Eden-Lange procedure in patient with pre-existing glenohumeral instability. *J Shoulder Elbow Surg* 2012;21:e10-e13.
- Amroodi MN, Salariyeh M. Single-incision Eden-Lange procedure in trapezius muscle paralysis: A report of 11 cases. *Acta Orthop Traumatol Turc* 2018;52:115-119.
- Werthel JD, Wagner ER, Sperling JW, Elhassan B. Tendon transfer options for trapezius paralysis: A biomechanical study. *J Am Acad Orthop Surg* 2019;27:e235-e241.
- Teboul F, Bizot P, Kakkar R, Sedel L. Surgical management of trapezius palsy. *J Bone Joint Surg Am* 2004;86:1884-1890.
- Teboul F, Bizot P, Kakkar R, Sedel L. Surgical management of trapezius palsy. *J Bone Joint Surg Am* 2005;87:285-291 (suppl 1, pt 2).
- Friedenberg SM, Zimprich T, Harper CM. The natural history of long thoracic and spinal accessory neuropathies. *Muscle Nerve* 2002;25:535-539.
- Dewar FP, Harris RI. Restoration of function of the shoulder following paralysis of the trapezius by fascial sling fixation and transplantation of the levator scapulae. *Ann Surg* 1950;132:1111-1115.
- Goel DP, Romanowski JR, Shi LL, Warner JJ. Scapulothoracic fusion: Outcomes and complications. *J Shoulder Elbow Surg* 2014;23:542-547.