

# Prophylaxis With a Middle East Respiratory Syndrome Coronavirus (MERS-CoV)–Specific Human Monoclonal Antibody Protects Rabbits From MERS-CoV Infection

Katherine V. Houser,<sup>1</sup> Lisa Gretebeck,<sup>1</sup> Tianlei Ying,<sup>4</sup> Yanping Wang,<sup>3</sup> Leatrice Vogel,<sup>1</sup> Elaine W. Lamirande,<sup>1</sup> Kevin W. Bock,<sup>2</sup> Ian N. Moore,<sup>2</sup> Dimitar S. Dimitrov,<sup>3</sup> and Kanta Subbarao<sup>1</sup>

<sup>1</sup>Laboratory of Infectious Diseases, <sup>2</sup>Comparative Medicine Branch, Infectious Disease Pathogenesis Section, National Institute of Allergy and Infectious Disease, National Institutes of Health (NIH), Bethesda, and <sup>3</sup>Protein Interactions Section, Cancer and Inflammation Program, Center for Cancer Research, National Cancer Institute, NIH, Frederick, Maryland; and <sup>4</sup>Key Laboratory of Medical Molecular Virology of Ministries of Education and Health, Shanghai Medical College, Fudan University, China

With >1600 documented human infections with Middle East respiratory syndrome coronavirus (MERS-CoV) and a case fatality rate of approximately 36%, medical countermeasures are needed to prevent and limit the disease. We examined the *in vivo* efficacy of the human monoclonal antibody m336, which has high neutralizing activity against MERS-CoV *in vitro*. m336 was administered to rabbits intravenously or intranasally before infection with MERS-CoV. Prophylaxis with m336 resulted in a reduction of pulmonary viral RNA titers by 40–9000-fold, compared with an irrelevant control antibody with little to no inflammation or viral antigen detected. This protection in rabbits supports further clinical development of m336.

**Keywords.** MERS-CoV; prophylaxis; m336; rabbits; human mAb.

Middle East respiratory syndrome coronavirus (MERS-CoV) was first detected in humans in 2012. As of 16 February 2016, there have been 1638 confirmed infections and 587 associated deaths globally [1]. Disease severity appears to vary on the basis of comorbidities and age of infected individuals [2, 3]. Severe infection with MERS-CoV can result in acute respiratory distress syndrome, renal failure, and death, while younger patients without preexisting conditions typically display milder disease.

Human-to-human transmission of MERS-CoV has been identified on several occasions [4, 5]. These transmission chains have been self-limiting in nature and occurred predominantly in hospital settings. However, a notable large outbreak occurred in South Korea, where spread from one infected traveler resulted in 186 cases and 36 deaths [1]. While human infections have been sporadic, repeated reintroductions from an animal reservoir in the Middle East suggest that outbreaks will continue.

Several animal models have been developed for MERS-CoV [6]. In brief, nonhuman primates have been explored, with rhesus macaques displaying mild infection and marmosets displaying more severe disease. While mice are not naturally susceptible to experimental infection with MERS-CoV, several models have been generated expressing the human dipeptidyl peptidase 4 (DPP4) receptor. New Zealand white rabbits have also been experimentally infected with MERS-CoV, resulting in asymptomatic infection that may represent mild human disease [7]. Rabbits naturally display a DPP4 molecule that allows for attachment and infection by MERS-CoV. Infection leads to pulmonary disease characterized by mild perivascular and peribronchiolar inflammation, with viral titers peaking about 3 days after inoculation. Because MERS-CoV infection in the rabbit model can be monitored by pathologic analysis and viral replication, we evaluated this model for testing a potential medical countermeasure.

Although human MERS infections have been documented since 2012, approved MERS-specific vaccines or antiviral therapeutics are not yet available [6]. Several vaccine candidates are under development, but only a limited number of treatment options have been tested *in vivo*. Monoclonal antibodies and convalescent sera have been evaluated in mice. Two recently reported monoclonal antibodies, REGN3051 and REGN3048, resulted in a 100-fold reduction in virus titer following administration in a transgenic mouse model [8].

A human monoclonal antibody (hmAb), m336, isolated from a large phage-display library interacts with the receptor-binding domain of the MERS-CoV spike protein and shows exceptionally potent neutralizing activity against MERS-CoV *in vitro* [9]. Here, we evaluated the *in vivo* efficacy of m336, using the rabbit model.

## METHODS

### Virus and Cells

MERS-CoV isolate HCoV-EMC/2012 (Erasmus Medical Center, Netherlands) was grown in Vero81 cells with Opti-MEM (Gibco) plus 5% fetal bovine serum (HyClone), and stored at  $-80^{\circ}\text{C}$ . The 50% tissue culture infective dose (TCID<sub>50</sub>) per milliliter was determined on Vero81 cells and calculated using the Reed–Muench method [10].

Received 6 November 2015; accepted 19 February 2016; published online 3 March 2016.

Presented in part: International Society for Influenza and Other Respiratory Virus Diseases, Austin, Texas, June 2015; American Society for Virology, London, Canada, July 2015. Abstract W5-5.

Correspondence: K. Subbarao, Bldg 33, Rm 3E13C.1, 33 North Dr, MSC 3203 Bethesda, MD 20892-3203 (ksubbarao@niaid.nih.gov).

The Journal of Infectious Diseases® 2016;213:1557–61

Published by Oxford University Press for the Infectious Diseases Society of America 2016. This work is written by (a) US Government employee(s) and is in the public domain in the US. DOI: 10.1093/infdis/jiw080

### Rabbit Infection Studies

Female New Zealand white rabbits (Covance, Princeton, New Jersey) aged 5–7 months were anesthetized with intramuscular dexmedetomidine and inhalational isoflurane, with sedation reversed with subcutaneous administration of atipamezole. The rabbits were infected intranasally with 1 mL of  $10^5$  TCID<sub>50</sub> of EMC/2012 in Leibovitz-15 (L15) (Gibco). Serum samples were collected 1 day after antibody administration and at necropsy. Animals were euthanized at days 1 or 3 after infection, and lung tissues were collected. All animal studies were conducted in biosafety level 3 laboratories at the National Institutes of Health (NIH), and all protocols were approved by the NIH Animal Care and Use Committee.

### Antibodies

Antibodies were generated as previously described [9]. Rabbits were given 0.2–2 mL of m336 at 1 mg/kg or 10 mg/kg intravenously or intranasally, respectively, in both prophylaxis and treatment studies 1 day before or 1 day after MERS-CoV infection. Rabbits in the control group were given 10 mg/kg of an irrelevant control hmAb, m102.4, that is specific for Hendra virus [9].

### Quantitative Real Time Polymerase Chain Reaction (qRT-PCR)

#### Analysis of Viral RNA

Lung tissues were stored at  $-80^{\circ}\text{C}$  until processing. Tissues were homogenized in L15 containing antibiotic-antimycotic (Invitrogen) to a final 10% wt/vol and centrifuged for 10 minutes at 1500 rpm with a swinging bucket rotor (Sorvall 75006445). Viral RNA was isolated using the QIAmp viral RNA mini kit (Qiagen). qRT-PCR analysis was run in duplicate, using 200 ng of RNA per reaction with MERS-CoV nucleoprotein (N3) primers [11] and the SuperScript III Platinum One-Step qRT-PCR kit (Life Technologies). Samples were run with serial dilutions of virus stock. Viral titers were expressed in  $\log_{10}$  TCID<sub>50</sub> equivalents/gram of tissue. Statistical significance was determined using 1-way analysis of variance with the Tukey multiple comparisons test.

### Histopathologic Analysis

Lung tissue samples from all lobes were resected from formalin-fixed tissue. Tissue was embedded in paraffin, divided into 5- $\mu\text{m}$  sections, and stained with hematoxylin and eosin (Histoserv, Germantown, Maryland). Sections were examined by light microscopy, using an Olympus BX51 microscope, and photomicrographs were taken using an Olympus DP73 camera.

### Immunohistochemical (IHC) Analysis

Lung sections were baked at  $60^{\circ}\text{C}$  for 1 hour then deparaffinized with xylene and rehydrated with alcohol-graded washes. Sections were microwaved with Antigen Unmasking Solution (Vector Laboratories). After exposure to protein block (Dako) for 30 minutes, mouse anti-MERS nucleocapsid antibody (Biorbyt) was added at a dilution of 1:100, followed by biotinylated horse anti-mouse immunoglobulin G (IgG; Vector Laboratories) at a dilution of 1:200. Sections were incubated for 30 minutes with Vectastain

ABC-AP reagent (Vector Laboratories) and for 25 minutes with Vulcan Fast Red chromogen (Biocare Medical) and were counterstained with hematoxylin.

### Microneutralization Assay

Serial 2-fold dilutions of rabbit sera were prepared, and equal volumes of virus and sera were combined and incubated for 1 hour at room temperature. The mixture was added in quadruplicate to Vero81 cells. The neutralization titer is the reciprocal of the highest serum dilution that neutralized the infectivity of 100 TCID<sub>50</sub> of virus, read as the absence of cytopathic effect on day 4 after infection.

## RESULTS

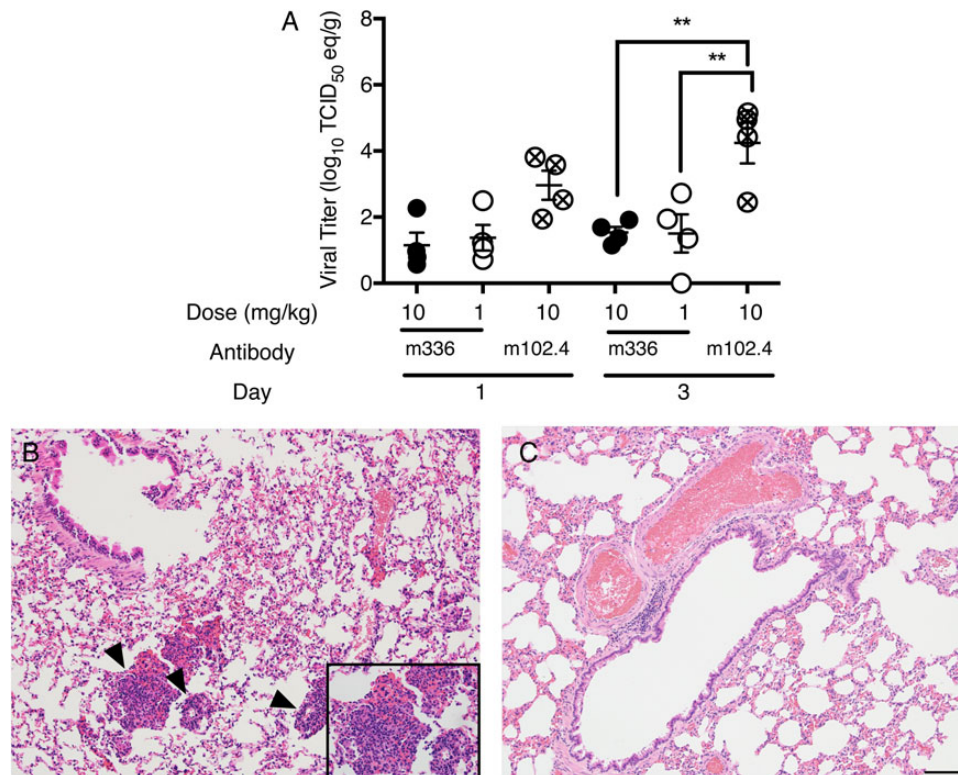
### Prophylaxis With hmAb m336 Is Effective in Reducing MERS-CoV RNA Titers

The hmAb IgG1m336 was administered to rabbits intravenously at 1 mg/kg or 10 mg/kg. Additional rabbits received a Hendra virus-specific hmAb (m102.4) as an isotype control. One day later, the rabbits were infected intranasally with  $10^5$  TCID<sub>50</sub> of MERS-CoV EMC/2012. A 40-fold and 65-fold reduction in viral RNA titers was observed 1 day after infection in rabbits that received 1 mg/kg and 10 mg/kg m336, respectively, compared with the control group (Figure 1A). The reduction in viral RNA titers was significant in both m336 groups on day 3 after infection, with a >500-fold reduction.

The neutralizing MERS-specific antibody titers in the sera of the rabbits that received 1 mg/kg of m336 ranged from 10 to 32 immediately before infection and remained in the range of 10 to 25 on day 3 after infection (Supplementary Table 1). The group that received 10 mg/kg of m336 had serum titers ranging from 113 to 320 before virus inoculation and from 101 to 320 on day 3 after infection. The control group of rabbits did not develop detectable neutralizing antibody against EMC/2012.

Rabbits that were administered the control antibody intravenously showed mild perivascular, peribronchiolar, and, to a lesser extent, alveolar interstitial inflammation, characterized by a predominantly eosinophilic and histiocytic infiltrate (Figure 1B). IHC evaluation revealed that MERS-CoV antigen was distributed in a perivascular and peribronchiolar pattern (Supplementary Figure 1A). Rabbits that received m336 at either dose had no evidence of inflammation or virus antigen (Figure 1C and Supplementary Figure 1B).

To test an alternative route of antibody administration, the hmAb m336 was also administered to rabbits intranasally. One day later, the rabbits were infected intranasally with EMC/2012. Within 1 day, rabbits that received 1 mg/kg of m336 had a >1000-fold reduction, and rabbits that received 10 mg/kg had a >9000-fold reduction in viral RNA titers, compared with controls (Figure 2A). By day 3 after infection, the majority of m336-treated rabbits had cleared MERS-CoV RNA. MERS-CoV-specific neutralizing antibody was not detected in the sera of rabbits following intranasal administration of m336 (data not shown).



**Figure 1.** Viral titers in rabbit lungs following intravenous prophylaxis with neutralizing monoclonal antibody. Rabbits received Middle East respiratory syndrome coronavirus (MERS-CoV)–specific human monoclonal antibody (hmAb) m336 or irrelevant control hmAb m102.4 intravenously 24 hours before intranasal infection with  $10^5$  50% tissue culture infective doses (TCID<sub>50</sub>) of EMC/2012. *A*, Lungs were collected on days 1 and 3 after infection, and viral titers were quantified by quantitative real time polymerase chain reaction analysis. *B* and *C*, Images of hematoxylin-eosin–stained sections from a rabbit treated with the control antibody (*B*) or 10 mg/kg of m336 (*C*). Data are from 4 rabbits per group. Arrowheads and inset highlight areas of intense perivascular inflammation. All images were taken on day 3 after infection at 10× original magnification, with the inset at 40× original magnification. The black bar is equivalent to 100 μm on images 10× original magnification. \*\* $P < .005$  and \*\*\* $P < .001$  by 1-way analysis of variance, with the Tukey multiple comparisons test. Abbreviation: eq, equivalents.

Rabbits that received the control antibody intranasally showed mild perivascular and peribronchiolar inflammation, characterized by a mixture of eosinophils and histiocytes (Figure 2*B*). IHC evaluation revealed that MERS-CoV antigen was often distributed in a perivascular and peribronchiolar pattern, and, to a lesser extent, within the alveolar interstitium (Supplementary Figure 1*C*). Rabbits that received m336 at either dose had minimal inflammation and no evidence of virus antigen (Figure 2*C* and Supplementary Figure 1*D*).

#### Treatment With m336 Does Not Lead to a Significant Reduction in Viral RNA Titers

Having established that preexposure prophylaxis with m336 is highly effective, we sought to assess its usefulness for postexposure treatment in MERS-CoV–infected rabbits. The antibody was administered to rabbits intravenously or intranasally 1 day after infection and lung tissue was collected at day 3 after infection.

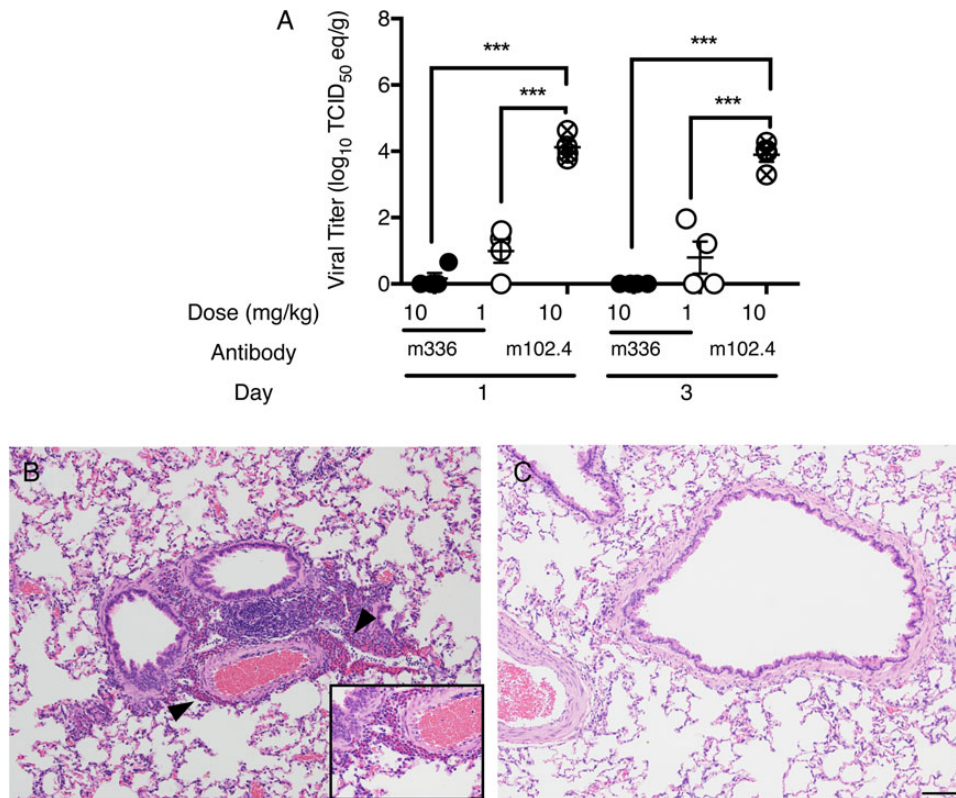
Serum neutralizing antibody titers were detected the day following administration, ranging from 25 to 40 in the 1 mg/kg group and from 201 to 640 in the 10 mg/kg group, with similar

titers at necropsy (Supplementary Table 1). Similar to observations in the prophylaxis study, neutralizing antibody was not detected in the sera of rabbits that received m336 antibody intranasally (data not shown). Although the serum neutralizing antibody titers achieved in the treatment study were comparable to those found in the prophylaxis study, m336 antibody treatment by the intravenous or intranasal route was not effective in reducing viral RNA titers (Supplementary Figure 2*A* and *B*).

Rabbits that received either hmAb m336 or 102.4 following infection showed similar histological changes in the lungs, characterized by mild perivascular and peribronchiolar accumulations of eosinophils and histiocytes (Supplementary Figure 2*C–F*). In addition, the distribution of virus antigen was found in close proximity to blood vessels and small airways in all rabbits.

#### DISCUSSION

Neutralizing monoclonal antibodies have proven useful for treatment of several viral infections in humans and have also demonstrated effectiveness in animal models against SARS-CoV [12, 13]. In these studies, we found that prophylaxis with



**Figure 2.** Viral titers in rabbit lungs following intranasal prophylaxis with neutralizing monoclonal antibody. Rabbits received Middle East respiratory syndrome coronavirus (MERS-CoV)-specific human monoclonal antibody (hmAb) m336 or irrelevant control hmAb m102.4 intranasally 24 hours before intranasal infection with  $10^5$  50% tissue culture infective doses (TCID<sub>50</sub>) of EMC/2012. *A*, Lungs were collected on days 1 and 3 after infection, and viral titers were quantified by quantitative real time polymerase chain reaction analysis. *B* and *C*, Images of hematoxylin-eosin-stained sections from a rabbit treated with the control antibody (*B*) or 10 mg/kg of m336 (*C*). Data are from 4 rabbits per group. Arrowheads and inset highlight areas of intense perivascular inflammation. All images were taken on day 3 after infection at 10× original magnification, with the inset at 40× original magnification. The black bar is equivalent to 100 μm. \*\* $P < .005$  and \*\*\* $P < .001$  by 1-way analysis of variance, with the Tukey multiple comparisons test. Abbreviation: eq, equivalents.

hmAb m336 resulted in significant reduction of viral RNA titers and virus-related pathology in the lungs of rabbits. Although low amounts of viral RNA were detected in some m336-treated rabbits (Figure 1A), almost no viral antigen was identified by IHC analysis, indicating that infection of the lower respiratory tract was prevented. Intravenous administration of m336 resulted in neutralizing antibody titers in the serum for several days (Supplementary Table 1), but intranasal administration of antibody did not result in detectable titers. This implies that the topically administered antibody remained in the respiratory tract and could account for the greater efficacy of the antibody administered intranasally versus intravenously [14].

MERS-CoV-infected rabbits develop a disease that may be representative of mild and asymptomatic human infections. We observed somewhat more severe lung inflammation than previously reported [7], likely due to differences in route or volume of virus administration. Inflammation was present in more areas of the lung when antibody was administered intranasally as compared to intravenously, although the severity was comparable (Supplementary Tables 2 and 3). This could be the result

of the additional volume delivered intranasally to achieve a dose of 10 mg/kg of m336. However, since 1 mg/kg treatment was as effective, large inoculum volumes should not be required in future studies.

Postinfection therapy with hmAb m336 through either route did not result in a reduction in viral RNA titers as measured by qRT-PCR. It is possible that the high viral inoculum infected susceptible cells in the respiratory tract before m336 administration and that the hmAb could not prevent replication of virus in already infected cells. Alternatively, because qRT-PCR measures both viable and nonviable viral particles, this measurement may not be an accurate reflection of infectious virus. Recent data with other mAbs support the notion that the fold-reduction in titer of infectious virus with antibody treatment is greater than the reduction in viral RNA levels [8]. Therefore, the evaluation of its potential for therapy requires further studies of its effect on infectious virus.

The hmAb m336 has high specificity and neutralizing activity against MERS-CoV in vitro [9]. Here we demonstrate in vivo efficacy in the rabbit. Significant reduction in viral RNA titers

was demonstrated in the lungs following prophylaxis with m336 by 2 routes. Within 1 day of infection, we observed a 40 to 9000-fold reduction in pulmonary viral RNA load, with minimal inflammation and viral antigen present. These results indicate that m336 antibody, when administered before exposure, is able to prevent MERS-CoV infection and warrants further development as a medical countermeasure against MERS-CoV infection.

### Supplementary Data

Supplementary materials are available at <http://jid.oxfordjournals.org>. Consisting of data provided by the author to benefit the reader, the posted materials are not copyedited and are the sole responsibility of the author, so questions or comments should be addressed to the author.

### Notes

**Financial support.** This work was supported by the Division of Intramural Research, National Institute of Allergy and Infectious Diseases, National Institutes of Health (NIH), and by the National Cancer Institute, NIH.

**Potential conflicts of interest.** All authors: No reported conflicts. All authors have submitted the ICMJE Form for Disclosure of Potential Conflicts of Interest. Conflicts that the editors consider relevant to the content of the manuscript have been disclosed.

### References

1. WHO. Middle East respiratory syndrome coronavirus (MERS-CoV). <http://www.who.int/emergencies/mers-cov/en/>. Accessed 17 February 2016.

2. Assiri A, Al-Tawfiq JA, Al-Rabeeh AA, et al. Epidemiological, demographic, and clinical characteristics of 47 cases of Middle East respiratory syndrome coronavirus disease from Saudi Arabia: a descriptive study. *Lancet Infect Dis* **2013**; 13:752–61.
3. Saad M, Omrani AS, Baig K, et al. Clinical aspects and outcomes of 70 patients with Middle East respiratory syndrome coronavirus infection: a single-center experience in Saudi Arabia. *Int J Infect Dis* **2014**; 29:301–6.
4. Assiri A, McGeer A, Perl TM, et al. Hospital outbreak of Middle East respiratory syndrome coronavirus. *N Engl J Med* **2013**; 369:407–16.
5. Al-Abdallat MM, Payne DC, Alqasrawi S, et al. Hospital-associated outbreak of Middle East respiratory syndrome coronavirus: a serologic, epidemiologic, and clinical description. *Clin Infect Dis* **2014**; 59:1225–33.
6. van Doremalen N, Munster VJ. Animal models of Middle East respiratory syndrome coronavirus infection. *Antiviral Res* **2015**; 122:28–38.
7. Haagmans BL, van den Brand JM, Provacia LB, et al. Asymptomatic Middle East respiratory syndrome coronavirus infection in rabbits. *J Virol* **2015**; 89:6131–5.
8. Pascal KE, Coleman CM, Mujica AO, et al. Pre- and postexposure efficacy of fully human antibodies against Spike protein in a novel humanized mouse model of MERS-CoV infection. *Proc Natl Acad Sci U S A* **2015**; 112:8738–43.
9. Ying T, Du L, Ju TW, et al. Exceptionally potent neutralization of Middle East respiratory syndrome coronavirus by human monoclonal antibodies. *J Virol* **2014**; 88:7796–805.
10. Reed LJ, Muench H. A simple method of estimation fifty per cent endpoints. *American Journal of Hygiene* **1938**; 27:493–7.
11. Lu X, Whitaker B, Sakhivel SK, et al. Real-time reverse transcription-PCR assay panel for Middle East respiratory syndrome coronavirus. *J Clin Microbiol* **2014**; 52:67–75.
12. Marasco WA, Sui J. The growth and potential of human antiviral monoclonal antibody therapeutics. *Nat Biotechnol* **2007**; 25:1421–34.
13. Zhu Z, Chakraborti S, He Y, et al. Potent cross-reactive neutralization of SARS coronavirus isolates by human monoclonal antibodies. *Proc Natl Acad Sci U S A* **2007**; 104:12123–8.
14. Leyva-Grado VH, Tan GS, Leon PE, Yondola M, Palese P. Direct administration in the respiratory tract improves efficacy of broadly neutralizing anti-influenza virus monoclonal antibodies. *Antimicrob Agents Chemother* **2015**; 59:4162–72.