

## Letter to the Editor

### Giant Solitary Fibrous Tumor: A Rare Case Report

DOI: 10.4103/sajc.sajc\_204\_18

Dear Editor,

Solitary fibrous tumour of pleura (SFTP) is a very rare benign spindle cell mesenchymal tumour, first described in 1931.<sup>[1]</sup> Most commonly originates from pleura and represents 5% of tumors of pleura.<sup>[1-4]</sup> However, 10%–20% of these tumors are locally aggressive or malignant.<sup>[2,3]</sup> Complete en bloc surgical resection with free resection margins is the treatment of both benign and malignant types of SFTP.<sup>[1-3,5]</sup>

A 56-year-old man, nonsmoker with no comorbidities presented with a cough for 5 months and left-sided heaviness and dyspnea for 1 month. He had no other positive history, and his general examination was normal. Examination of lungs revealed decreased breath sounds throughout the left chest. Chest X-ray [Figure 1] showed a large, left hemithorax mass with no visible lung parenchyma and shift of mediastinum to the right. Contrast-enhanced computed tomography (CECT) scan of the thorax [Figure 2] confirmed the presence of a large lobulated heterogeneous pleural-based mass measuring approximately 20 cm × 20 cm × 10 cm within left pleural space with gross pleural effusion resulting in complete collapse of left lung toward the hilum. Laboratory investigations were within normal limits other than low hemoglobin of 10 g/dl. His pulmonary function test showed poor forced expiratory volume 1 values (39%) and forced vital capacity (34%). CT-guided tru-cut biopsy of the mass revealed spindle cell neoplasm with low mitotic index and mild cytologic atypia. Immunohistochemistry (IHC) showed positivity for Vimentin, BCL2, CD99, and MIB (16%) confirming low-grade spindle cell sarcoma pleuropulmonary origin.

The patient underwent left posterolateral thoracotomy with vertical extension of the incision transecting three ribs. En mass excision of the tumor (measuring 32 cm × 26 cm, weighing 3.8 kg) was done with a small sliver of the lung [Figure 3]. Lung was found to be normal though collapsed intraoperatively hence was conserved. Post-operative recovery was uneventful other than delayed removal of the intercostal drainage tube to allow complete expansion of lung. The patient was discharged on the 10<sup>th</sup> postoperative day. Chest X-ray at discharge showed a fairly expanded left lung with shift of mediastinum to normal position [Figure 4].

First described in 1931 by Klemperer and Rabin,<sup>[1]</sup> SFTP is a very rare benign spindle cell mesenchymal tumor most commonly originating from the pleura and it represents 5% of the tumors of the pleura.<sup>[1-4]</sup>

The peak incidence of diagnosis of SFTPs is the fifth and sixth decades of life with equal sex predilection.<sup>[1,2,4]</sup>

Our patient was a 56-year-old man with no comorbidities.

SFTPs are usually asymptomatic, diagnosed incidentally and clinical course of the disease is unpredictable.<sup>[1,2,4]</sup> However, patient can present with various respiratory symptoms such as a cough, chest pain, and dyspnea.<sup>[2,4]</sup> This tumor is usually benign, but up to 20% of cases can be malignant.<sup>[1]</sup> Patients with benign tumors are symptomatic in 54%–67% of the cases, whereas malignant tumors are symptomatic in around 75% of cases.<sup>[4]</sup>

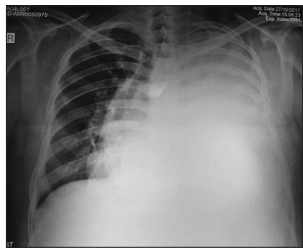
Our patient had symptoms of a cough and breathlessness since few months.

Preoperative diagnosis of the tumor is a difficult challenge. Chest X-ray is the first modality of the investigation. However, CECT of the thorax is considered to be the most important examination.<sup>[1,2,4]</sup> CT scans usually demonstrate a well-defined and occasionally lobulated mass with soft tissue attenuation appearing on the pleural surface, and displacement of the surrounding structures.<sup>[4]</sup> On CT, SFTP can be detected to arise from the parietal pleura, lung fissure or visceral pleura. As per literature size of SFTPs range from a few millimeters to tens of centimeters (0.8–26 cm).<sup>[4]</sup> Signs which may lead to the suspicion of a tumor malignancy can be the existence of clinical symptoms, mean tumor diameter >10 cm, fibrous adhesences, pleural effusion and positive histology for Ki67 10% or greater.<sup>[2]</sup>

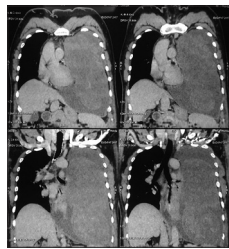Image-guided tru-cut biopsy is useful for the preoperative diagnosis.<sup>[2,4,5]</sup> IHC plays a key role regarding the distinction of SFTP from mesotheliomas and sarcomas.<sup>[2]</sup> Both benign and malignant varieties of SFTP are CD34, CD99, Vimentin, and BCL-2-positive.<sup>[1-4]</sup>

CECT Scan of our patient showed the left hemithorax completely occupied by tumor (20 cm × 20 cm × 10 cm) with the complete collapse of the left lung and mediastinal shift to the right. Tru-cut biopsy showed it to be spindle cell neoplasm and IHC showed positivity for Vimentin, bcl-2, CD99, and MIB (16%) confirming low-grade spindle cell sarcoma of pleuropulmonary origin.

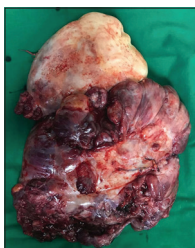Majority of SFTs of the thorax are benign, whereas 10%–20% are locally aggressive or malignant.<sup>[2,3]</sup> Complete en bloc



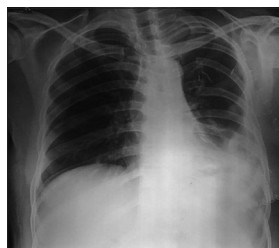
**Figure 1: Large mass left hemithorax with complete collapse of left lung and mediastinal shift to the right**



**Figure 2: Contrast enhanced computed tomography thorax: Large lobulated mass in left hemithorax with pleural effusion and mediastinal shift to right**



**Figure 3: En Toto excision of mass with sliver of lung tissue (32 cm × 26 cm) weighing 3.8 kg**



**Figure 4: Postoperative day 7 Chest X-ray showing fairly expanded lung with mediastinum in normal position**

surgical resection with free resection margins is the treatment of both benign and malignant types of SFTP.<sup>[1-3,5]</sup> As these tumors are not primary lung tumors, lung parenchyma resection should be kept as minimal as possible with clear margins for oncological safety. A lobectomy or pneumonectomy could be carried out in larger tumors or in intraparenchymal tumors. If the tumor arises from the parietal pleura, a thoracic wall resection could be considered for complete curative resection.<sup>[2]</sup>

Our patient underwent in toto excision of a large parietal pleural based tumor weighing around 3.8 kg and measuring 32 cm × 26 cm with a small sliver of the lung.

Definitive diagnosis of SFTP is histologically made after the surgical resection of the tumor. Risk of recurrence after

complete surgical resection can range from <2% in benign SFTP to 63% in malignant forms.<sup>[5]</sup>

Final histopathology and IHC in our report confirmed it to be solitary fibrous tumor.

Adjuvant chemotherapy is usually not a part of the management of SFTP. However, it could be used in incompletely resected tumors, malignant sessile SFTPs or in cases of chest wall invasion and concurrent pleural effusion.<sup>[2]</sup> Treatment for recurrence after surgical treatment is resurgery.<sup>[2]</sup>

Metastases from SFTP have been observed to bones, brain, lungs, and intra-abdominal lymph nodes.<sup>[2,4]</sup> Malignant and larger SFTP are more likely to develop metastases mandating a long-term follow-up in these patients.

We report here a rare giant SFTP with complete curative excision of the tumor and complete reexpansion of the lung alleviating the patient's symptoms completely. Patient has been asymptomatic at the end of 6 months follow-up.

To the best of our knowledge, an SFTP of these dimensions and weight has not been reported in the literature.

#### **Declaration of patient consent**

The authors certify that they have obtained all appropriate patient consent forms. In the form the patient(s) has/have given his/her/their consent for his/her/their images and other clinical information to be reported in the journal. The patients understand that their names and initials will not be published and due efforts will be made to conceal their identity, but anonymity cannot be guaranteed.

#### **Financial support and sponsorship**

Nil.

#### **Conflicts of interest**

There are no conflicts of interest.

**Sanjay Sharma, Prriya Eshpuniyani, Kirti Bhushan, Kanishka Gautam Siddharth, Sameer Pathan<sup>1</sup>**

Department of Surgical Oncology, <sup>1</sup>Department of Pathology, Asian Cancer Institute, Sion, Mumbai, Maharashtra, India  
**Correspondence to:** Dr. Prriya Eshpuniyani,  
 E-mail: drprriya@gmail.com

## References

1. Supakul R, Sodhi A, Tamashiro CY, Azmi SS, Kadaria D. Solitary fibrous tumor of the pleura: A Rare cause of pleural mass. *Am J Case Rep* 2015;16:854-7.
2. Hohenforst-Schmidt W, Grapatsas K, Dahm M, Zarogoulidis P, Leivaditis V, Kotoulas C, *et al.* Solitary fibrous tumor: A center's experience and an overview of the symptomatology, the diagnostic and therapeutic procedures of this rare tumor. *Respir Med Case Rep* 2017;21:99-104.
3. Czimbalmos C, Csecs I, Polos M, Bartha E, Szucs N, Toth A, *et al.* Uncommon presentation of a rare tumour – Incidental finding in an asymptomatic patient: Case report and comprehensive review of the literature on intrapericardial solitary fibrous tumours. *BMC Cancer* 2017; 17:612.
4. Vejvodova S, Spidlen V, Mukensnabl P, Krakorova G, Molacek J, Vodicka J, *et al.* Solitary fibrous tumor – Less common neoplasms of the pleural cavity. *Ann Thorac Cardiovasc Surg* 2017;23: 12-8.
5. Tan JH, Hsu AA. Challenges in diagnosis and management of giant solitary fibrous tumour of pleura: A case report. *BMC Pulm Med* 2016;16: 114.

---

This is an open access journal, and articles are distributed under the terms of the Creative Commons Attribution-NonCommercial-ShareAlike 4.0 License, which allows others to remix, tweak, and build upon the work non-commercially, as long as appropriate credit is given and the new creations are licensed under the identical terms.

**How to cite this article:** Sharma S, Eshpuniyani P, Bhushan K, Siddharth KG, Pathan S. Giant solitary fibrous tumor: A rare case report. *South Asian J Cancer* 2019;8:17.

© 2018 The South Asian Journal of Cancer | Published by Wolters Kluwer - Medknow