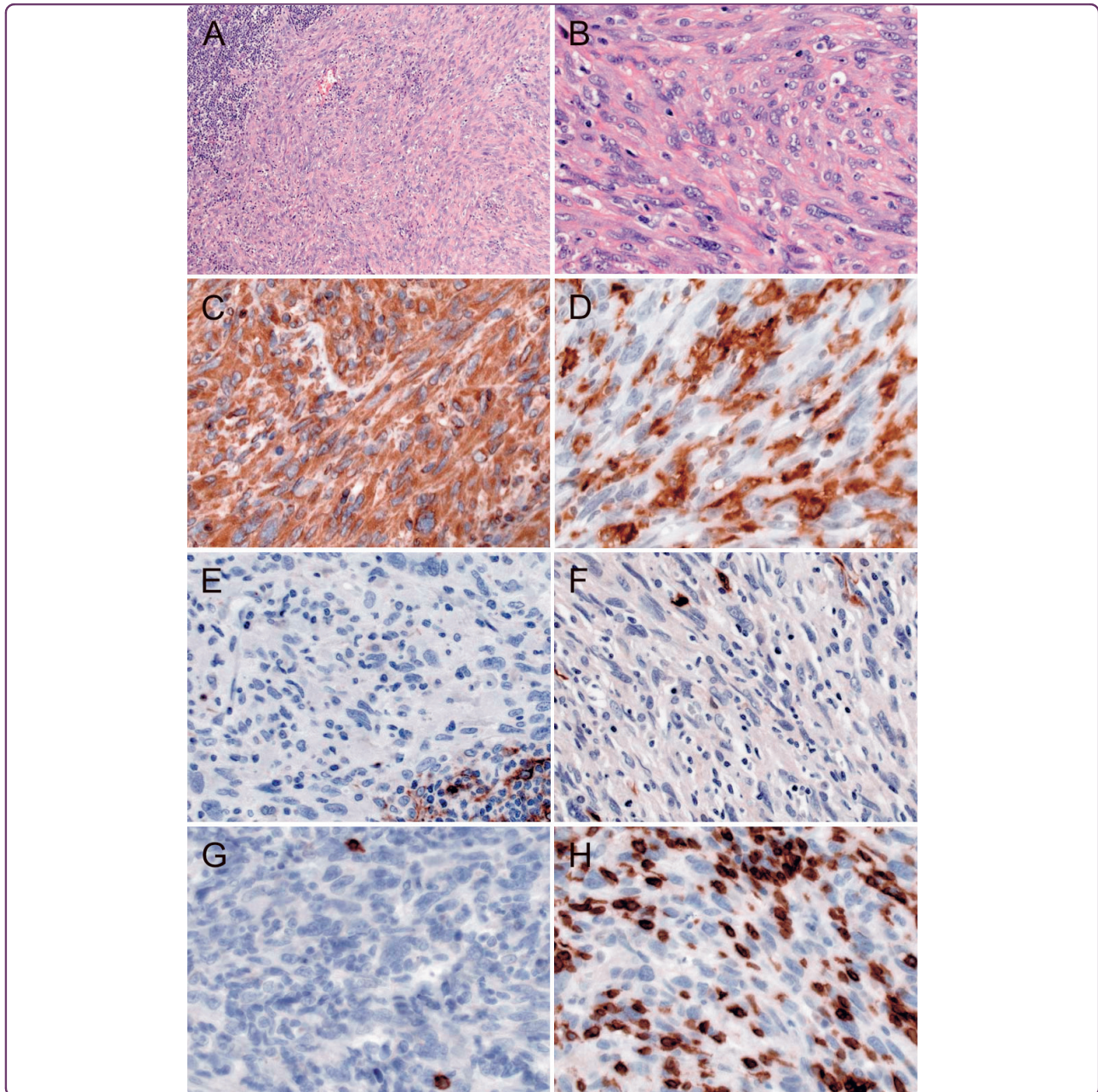

Dendritic cell tumor in a salivary gland lymph node: a rare differential diagnosis of salivary gland neoplasms

Schraven *et al.*



CASE REPORT

Open Access

Dendritic cell tumor in a salivary gland lymph node: a rare differential diagnosis of salivary gland neoplasms

Sebastian P Schraven^{1,5*}, Stefan K Plontke², Roland Syha³, Falko Fend⁴, Hartwig Wolburg⁴ and Patrick Adam⁴

Abstract

Dendritic cell tumors are extremely rare neoplasms arising from antigen-presenting cells of the immune system. We report a case of a 69-year-old man with an unremarkable medical history who presented with a 2-months history of a gradually enlarging painless, firm, mobile, 2 × 2-cm swelling at the caudal pole of the left parotid gland without systemic symptoms. Histologically, the tumor consisted of a spindle cell proliferation in an intraparotideal lymph node. Based on the histopathologic, immunohistochemical and electron microscopic findings, a dendritic cell tumor, not otherwise specified (NOS) in an intraparotideal lymph node was diagnosed. The patient underwent complete tumor resection, and is currently free of disease, 2 years after surgery. These extremely rare tumors must be distinguished from other more common tumors in the salivary glands. Awareness that dendritic cell tumors may occur in this localization, careful histologic evaluation and ancillary immunohistochemical and electron microscopical analyses should allow for recognition of this entity.

Keywords: Dendritic cell tumor, salivary gland lymph node

Background

Dendritic cell sarcomas (DCS) are exceedingly rare entities, arising from antigen-presenting cells of the immune system. DCS are subclassified into the better characterized follicular (FDCS) [1] and interdigitating (IDCS) [2] dendritic cell sarcomas and other rare and less well classifiable dendritic cell tumors like fibroblastic reticular cell tumors, indeterminate dendritic cell tumors and dendritic cell tumors, not otherwise specified (DCT, NOS) [2]. DCS was first described in 1986 by Monda et al. [3]. Since then, nearly 300 cases, most of them FDCS, have been described in the literature. Although most DCS evolve in cervical, mediastinal, axillary and inguinal lymph nodes, also extranodal manifestations have been described [4]. The clinical behaviour of DCS is similar to that of low-grade soft tissue sarcoma, with an approximately 30% overall risk for developing local recurrences and metastases [5]. Because of the rareness of the disease a standardized treatment is lacking.

We herein report a case of a dendritic cell tumor, NOS of an intraparotideal lymph node, emphasizing the important role of ancillary immunohistochemical and molecular studies in establishing this extraordinarily rare diagnosis.

Case report

A 69-year-old man presented with a 2-months history of a gradually enlarging painless, firm, mobile, 2 × 2 × 2 cm swelling at the caudal pole of the left parotid gland without systemic symptoms. His medical history was unremarkable.

Magnet resonance imaging (MRI) showed a 2 × 2 × 2 cm mass with hyperintense signal on T2-weighted images and hypointense signal on T1-weighted sequences and a contrast enhancement which bordered directly to the lateral part of left sternocleidomastoid muscle and displaced the external jugular vein dorsally. Cranially there was no clear demarcation to the left parotid gland (Figure 1). The patient underwent surgical excision of the swelling by a partial left parotidectomy with preservation of the facial nerve. Because of insecure R0-status a follow-up resection with extended partial

* Correspondence: schraven_s@klinik.uni-wuerzburg.de

¹Department of Otolaryngology, Head and Neck Surgery, University of Tübingen, Elfriede-Aulhorn-Straße 5, D-72076 Tübingen, Germany
Full list of author information is available at the end of the article

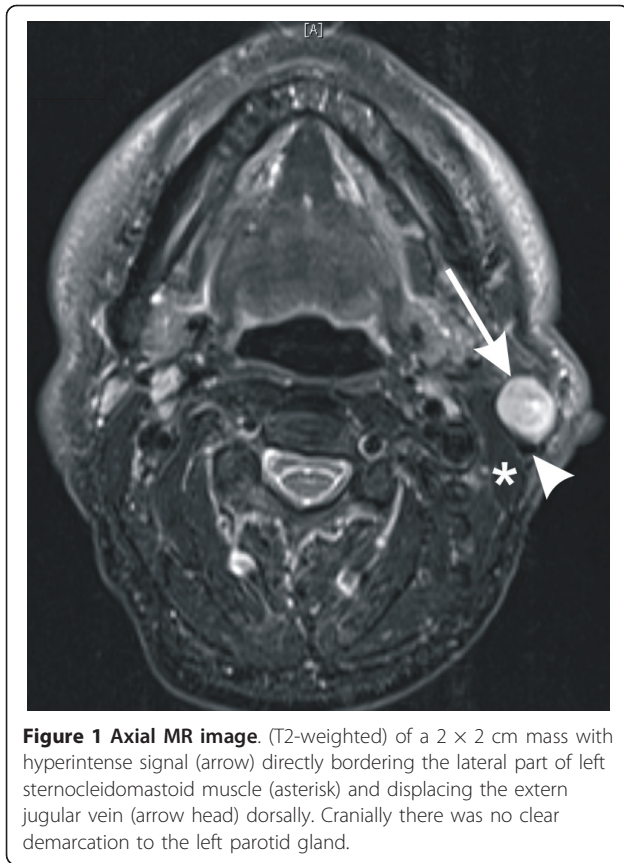


Figure 1 Axial MR image. (T2-weighted) of a 2 × 2 cm mass with hyperintense signal (arrow) directly bordering the lateral part of left sternocleidomastoid muscle (asterisk) and displacing the external jugular vein (arrow head) dorsally. Cranially there was no clear demarcation to the left parotid gland.

parotidectomy and ipsilateral selective neck dissection (levels II and III) was conducted. A primary tumor of the upper aerodigestive tract was excluded by panendoscopy. Subsequent total body positron emission tomography with 18-F-fluorodesoxyglucose and computed tomography scan 6 months after surgery were unremarkable. The patient is currently disease free, 2 years after surgery.

Material and methods

The specimen was fixed in 10% buffered formalin, paraffin-embedded, and histologic sections were obtained. Sections were routinely stained with hematoxylin and eosin. Immunohistochemical staining was performed on formalin-fixed, paraffin-embedded tissue sections on an automated immunostainer (Ventana Medical Systems®, Tucson AZ) following the manufacturer's protocols. The monoclonal antibodies used are listed in Table 1.

For electron microscopical (EM) evaluation, small pieces of tissue were dissected out of the paraffin bloc, rehydrated stepwise and postfixed in 1% OsO₄ in 0.1 M cacodylate buffer (pH 7.4) and then again dehydrated in an ethanol series (50, 70, 96, 100%). The 70% ethanol was saturated with uranyl acetate for contrast enhancement. Dehydration was completed in propylene

Table 1 List of antibodies and staining results.

Antibody	Company	Dilution	Tumor cells
Vimentin	DAKO	1:1000	positive
HLA-DR	DAKO	1:200	part.positive
Fascin	Abcam	1:100	positive
Langerin	eBioscience	1:50	negative
Lysozym	DAKO	1:400	negative
S100	DAKO	1:5000	negative
AE1/3	DAKO	1:100	negative
HMB45	DAKO	1:50	negative
MITF	Zytomed	1:100	negative
PMZ	Zytomed	1:50	negative
LCA	DAKO	1:500	negative
Calponin	DAKO	1:200	negative
Caldesmon	DAKO	1:50	negative
Clusterin	Menarini	1:30	negative
EMA	DAKO	1:100	negative
SMA	DAKO	1:500	negative
CK5/6	DAKO	1:100	negative
CK8/18	Zytomed	1:100	negative
OSCAR	Zytomed	1:200	negative
Synaptophysin	DCS	1:200	negative
Chromogranin	DAKO	1:500	negative
Factor XIIIa	DCS	1:100	negative
CD1a	DAKO	1:50	negative
CD3	Santa Cruz	1:200	negative
CD4	Zytomed	1:200	negative
CD20	DAKO	1:500	negative
CD21	Zytomed	1:50	negative
CD23	Novocastra	1:30	negative
CD30	DAKO	1:50	negative
CD31	DAKO	1:100	negative
CD34	DAKO	1:50	negative
CD35	Novocastra	1:50	negative
CD56	Cell Marque	1:100	negative
CD68 (PG-M1)	DAKO	1:200	negative
CD117	DAKO	1:200	negative
CD123	BD Pharmingen	1:50	negative
Mib1	DAKO	1:200	40-50%

oxide. The specimens were embedded in Araldite (Serva®, Heidelberg, Germany). Ultrathin sections were produced on a FCR Reichert Ultracut ultramicrotome (Leica®, Bensheim, Germany), mounted on pialoform-coated copper grids, contrasted with lead citrate and analyzed and documented with an EM10A electron microscope (Carl Zeiss®, Oberkochen, Germany). The pictures were digitized and processed with Adobe Photoshop.

Results

Gross and histological findings

The specimen consisted of parotid gland tissue containing a single firm, nodule 2.3 cm in diameter. The cut surface was soft and homogeneous light-grey. Microscopic examination revealed a spindle cell neoplasia in an intraparotid lymph node. Tumor cells featured moderate nuclear pleomorphism, bulked chromatin and

a clearly perceptible nucleolus (Figure 2A, B). Furthermore an elevated mitotic rate (up to 27 mitoses per 10 high power fields) was found.

Immunohistochemical Findings

To further characterize the histogenesis of this tumor, immunohistochemical stainings were performed. The tumor cells were positive for vimentin, fascin and HLA-

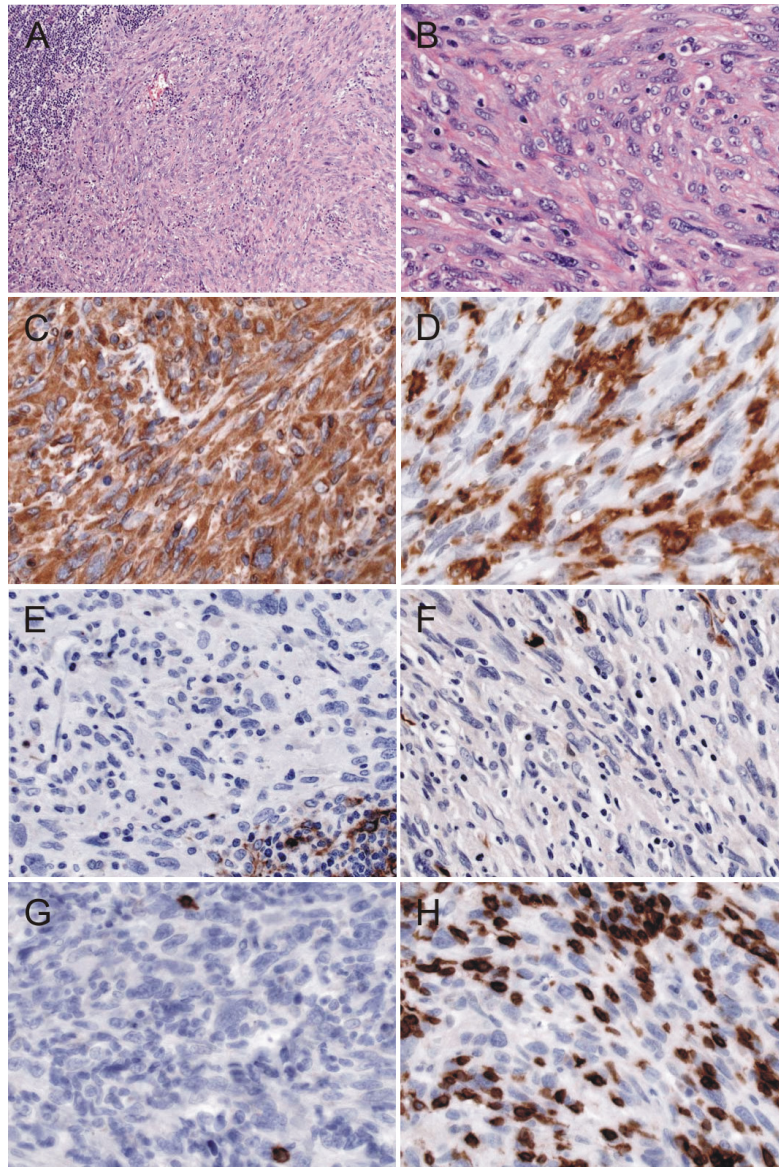


Figure 2 Morphology and immunohistochemical stainings: (A) H&E (original magnification 100x) and (B) H&E (original magnification 400x) show a spindle cell proliferation in an intraparotid lymph node with moderate cellular pleomorphism (C) Vimentin (original magnification 400x) and (D) HLA-DR (original magnification 400x) were strongly expressed by the tumor cells. (E) Clusterin (original magnification 400x) and (F) S100 protein (original magnification 400x) were negative in the tumor cells. (G) CD20 showed only very few reactive small B-cells (original magnification 400x) and (H) CD3 some reactive T-lymphocytes (original magnification 400x). Virtual Slides: <http://diagnosticpathology.slidepath.com/dih/webViewer.php?snapshotId=1316777507>, <http://diagnosticpathology.slidepath.com/dih/webViewer.php?snapshotId=1316777681>, <http://diagnosticpathology.slidepath.com/dih/webViewer.php?snapshotId=1316777716>, <http://diagnosticpathology.slidepath.com/dih/webViewer.php?snapshotId=1316777754>, <http://diagnosticpathology.slidepath.com/dih/webViewer.php?snapshotId=1316777781>

DR (Figure 2B, D). In contrast, the neoplastic cells were negative for all epithelial, melanocytic, lymphoid, histiocytic and follicular dendritic cell markers used. The proliferation, as assessed by Mib1 index was 40-50%. The results of the immunohistochemical stainings are shown in table 1.

Electron Microscopic Findings

The electron microscopical aspect of the tissue was characterized by cells which were devoid of characteristic structures as desmosomes or Birbeck granules. There was a certain heterogeneity of nuclei concerning their amount of heterochromatin. However, the cytoplasm of the cells (size, content of mitochondria or endoplasmatic reticulum) was less well differentiated (Figure 3A). The most prominent finding was the large number of slender long-spacing collagen fibers dividing the tissue in many compartments (Figure 3A). Fibrous long-spacing collagen the period length of which was in the order of 200 nm in this case (Figure 3B), is not described in the literature to be specific for any disease, but has been found in a variety of normal and pathological tissues. Therefore, it cannot be used as a pathognomonic marker here.

In summary, the morphological and immunophenotypic features were consistent with a dendritic cell tumor, not otherwise specified (NOS) originating in an intraparotidial lymph node. A differentiation towards a

follicular or interdigitating dendritic cell sarcoma could not be demonstrated.

Conclusions

Dendritic cell sarcomas (DCS) are rare neoplasms arising from antigen-presenting cells of the immune system [2]. DCS are being recognized with an increasing frequency. These tumors can occur, where dendritic cells are located. One of the most common manifestation sites are the head and neck region. Under-recognition of this entity may contribute to its rarity. The WHO subclassifies DCS into five groups [2]: Langerhans cell histiocytosis, Langerhans cell sarcoma, interdigitating dendritic cell sarcoma (IDCS), follicular dendritic cell sarcoma (FDCS) and other rare and less well classifiable dendritic cell tumors like fibroblastic reticular cell tumors, indeterminate dendritic cell tumors and dendritic cell tumors, not otherwise specified (DCT, NOS) [2]. FDCS is the most common subtype followed by IDCS.

The clinical course of this neoplasia is similar to that of soft tissue sarcomas [3,6]. Since only 306 cases of DCS have been reported worldwide (table 2), there is no general consensus on the treatment of this rare disease. Surgery has remained the gold standard in localized disease, but a recurrence rate up to 50% has been reported [5]. Alternatively some DCS have also been treated additionally by radiotherapy and or chemotherapy [7]. For our patient we chose the option of surgical therapy and

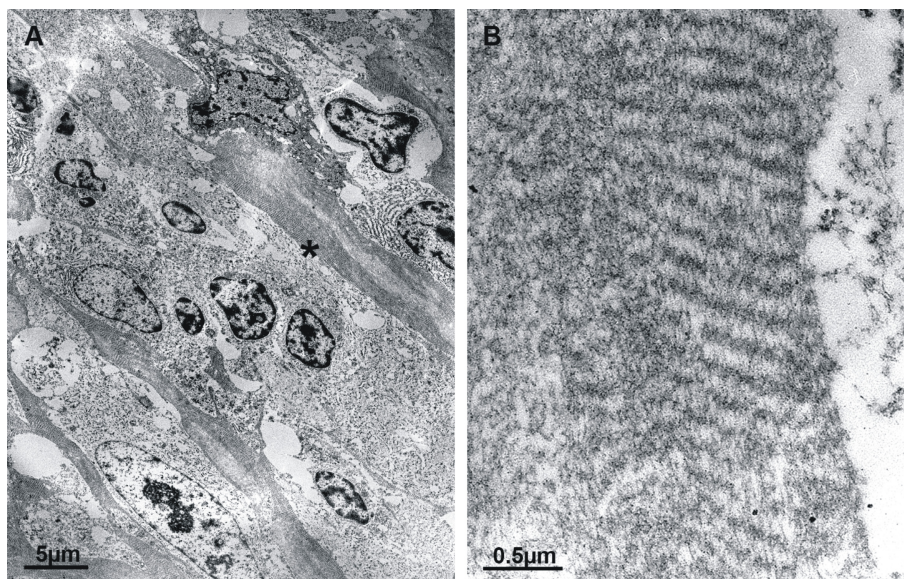


Figure 3 Electron microscopy (EM): Most prominent feature was the large number of slender long-spacing collagen fibers dividing the tissue in many compartments (A). Fibrous long-spacing collagen the period length of which was in the order of 200 nm in this case (B), is not described in the literature to be specific for any disease, but has been found in a variety of normal and pathological tissues. Well-formed desmosomes or Birbeck granules were not found in this case.

Table 2 Overview of dendritic cell sarcoma case reports.

	FDCS	IDCS	
1986 - 4/2007 *			
Nodal	77	33	110
Extranodal	52	22	74
5/2007 - 08/2011 [5,7,10-86]			
Nodal	68	14	82
Extranodal	33	7	40
	230	76	306

FDCS, follicular dendritic cell sarcoma; IDCS, interdigitating cell sarcoma. * Modified from [5]. A total of 145 nodal FDCS cases, 85 extranodal FDCS cases, 47 nodal IDCS cases and 29 extranodal cases have been reported until 08/2011. 2 cases FDCS and 2 cases of IDCS occurred in the parotid gland.

he is well and free of disease for 2 years after surgery now.

For establishing the diagnosis a large number of immunohistochemical stainings and ultrastructural analyses has been performed. Other rare differential diagnosis of salivary glands, like lipomatous pleomorphic adenoma [8] or sebaceous adenoma [9], were excluded. Despite this extensive work-up a definite assignation to an established entity of dendritic cell tumors could not be achieved. Therefore a diagnosis of dendritic cell tumor, NOS was made.

In summary, we report on the clinical, pathologic, and immunohistochemical features of a dendritic cell tumor, NOS in an intraparotid lymph node. Metastatic disease was ruled out by PET- and CT imaging. Recognition of this extremely rare tumor, and its distinction from more common malignant tumors of lymph nodes and salivary glands largely depends on judicious application of immunohistochemical and ultrastructural techniques. The precise histogenesis of these extraordinarily rare tumors remains to be established.

Consent

Written informed consent was obtained from the patient for publication of this Case Report and any accompanying images. A copy of the written consent is available for review by the Editor-in-Chief of this journal.

Acknowledgements

This publication was funded by the German Research Foundation (DFG) and the University of Würzburg in the funding programme Open Access Publishing.

Author details

¹Department of Otolaryngology, Head and Neck Surgery, University of Tübingen, Elfriede-Aulhorn-Straße 5, D-72076 Tübingen, Germany.

²Department of Otolaryngology, Head and Neck Surgery, University of Halle-Wittenberg, Magdeburger Straße 12, D-06112 Halle (Saale), Germany.

³Department of Diagnostic and Interventional Radiology, University of Tübingen, Hoppe-Seyler-Straße 3, D-72076 Tübingen, Germany. ⁴Institute of Pathology and Comprehensive Cancer Center (CCC), University of Tübingen, Liebermeisterstraße 8, D-72076 Tübingen, Germany. ⁵University of Würzburg,

Department of Otolaryngology, Head and Neck Surgery, Josef-Schneider-Strasse 11, 97080 Würzburg, Germany.

Authors' contributions

SPS SKP and RS designed the study, collected the clinical data and drafted the manuscript. HW carried out the electron microscopic analyses. FF and PA performed the histopathologic and immunohistochemical analyses and helped to draft the manuscript. All authors read and approved the final manuscript.

Competing interests

The authors declare that they have no competing interests.

Received: 3 August 2011 Accepted: 30 September 2011

Published: 30 September 2011

References

- Chan JKC: Follicular dendritic cell sarcoma. *WHO Classification of tumors of haematopoietic and lymphoid tissue* WHO; 2008, 363-364.
- Weiss LMG, T M, Chan JKC: Interdigitating dendritic cell sarcoma. 2008.
- Monda L, Warnke R, Rosai J: A primary lymph node malignancy with features suggestive of dendritic reticulum cell differentiation. A report of 4 cases. *Am J Pathol* 1986, **122**(3):562-572.
- Li L, Shi YH, Guo ZJ, Qiu T, Guo L, Yang HY, Zhang X, Zhao XM, Su Q: Clinicopathological features and prognosis assessment of extranodal follicular dendritic cell sarcoma. *World J Gastroenterol* 2010, **16**(20):2504-2519.
- De Pas T, Spitaleri G, Pruneri G, Curigliano G, Noberasco C, Luini A, Andreoni B, Testori A, de Braud F: Dendritic cell sarcoma: an analytic overview of the literature and presentation of original five cases. *Crit Rev Oncol Hematol* 2008, **65**(1):1-7.
- Perez-Ordóñez B, Erlandson RA, Rosai J: Follicular dendritic cell tumor: report of 13 additional cases of a distinctive entity. *Am J Surg Pathol* 1996, **20**(8):944-955.
- Efune G, Sumer BD, Sarode VR, Wang HY, Myers LL: Interdigitating dendritic cell sarcoma of the parotid gland: case report and literature review. *Am J Otolaryngol* 2009, **30**(4):264-268.
- Kondo T: A case of lipomatous pleomorphic adenoma in the parotid gland: a case report. *Diagn Pathol* 2009, **4**:16.
- Bersch C, Back W: Primary sebaceous adenoma of the salivary glands - a rare differential diagnosis: report of a case. *Diagn Pathol* 2007, **2**(Suppl 1):16.
- Aboujaoude R, Alvarez JR, Alvarez M, Al-Khan A: Follicular dendritic cell sarcoma in pregnancy: case report and review of the literature. *Am J Perinatol* 2006, **23**(8):459-461.
- Amiri-Kordestani L, Priebe D, Chia SH: Follicular dendritic cell sarcoma of the neck: case report and review of current diagnostic and management strategies. *Ear Nose Throat J* 2010, **89**(7):E14-17.
- Androulaki A, Liapis G, Alexandrou P, Lazaris AC: Retroperitoneal follicular dendritic cell sarcoma. *Int J Hematol* 2006, **84**(1):2.
- Aydin E, Ozluoglu LN, Demirhan B, Arkan U: Follicular dendritic cell sarcoma of the tonsil: case report. *Eur Arch Otorhinolaryngol* 2006, **263**(12):1155-1157.
- Azim HA, Elsedewy E, Azim HA Jr: Imatinib in the treatment of follicular dendritic sarcoma: a case report and review of literature. *Onkologie* 2007, **30**(7):381-384.
- Boldin I, Brix-Grunwald G, Scarpatetti MM, Beham-Schmid C, Klein A: Interdigitating dendritic cell sarcoma of the eyelid with a rapidly fatal course. *Arch Ophthalmol* 2008, **126**(5):738-740.
- Cano JR, Cerezo F, Gonzalez A, Marchal T, Salvatierra A: [Follicular dendritic cell tumour in the anterior mediastinum]. *Cir Esp* 2009, **85**(4):254-256.
- Chera BS, Orlando C, Villaret DB, Mendenhall WM: Follicular dendritic cell sarcoma of the head and neck: case report and literature review. *Laryngoscope* 2008, **118**(9):1607-1612.
- Choi JW, Lee JH, Kim A, Kim CH, Chae YS, Kim I: Follicular dendritic cell sarcoma arising in the dura mater of the spine. *Arch Pathol Lab Med* 2006, **130**(11):1718-1721.
- Choi BS, Baek JH, Shin YM, Kim JH, Kim HW, Lee SJ, Cha HJ: Follicular dendritic cell sarcoma: a case report and review of the literature. *Cancer Res Treat* 2010, **42**(2):121-124.

20. Clement P, Saint-Blancard P, Minvielle F, Le Page P, Kossowski M: **Follicular dendritic cell sarcoma of the tonsil: a case report.** *Am J Otolaryngol* 2006, **27**(3):207-210.
21. Cossa A, Deiana A, Lissia A, Dedola MF, Cocco L, Palmieri G, Tanda F: **Synchronous interdigitating dendritic cell sarcoma and B-cell small lymphocytic lymphoma in a lymph node.** *Arch Pathol Lab Med* 2006, **130**(4):544-547.
22. Cyriac S, Praveenkumar D, Majhi U, Sagar TG: **Follicular dendritic cell sarcoma of the neck with an aggressive and fatal course.** *J Cancer Res Ther* 2010, **6**(1):114-116.
23. Denning KL, Olson PR, Maley RH Jr, Flati VR, Myers JL, Silverman JF: **Primary pulmonary follicular dendritic cell neoplasm: a case report and review of the literature.** *Arch Pathol Lab Med* 2009, **133**(4):643-647.
24. Diaz de Liano A, Garde C, Artieda C, Yarnoz C, Flores L, Ortiz H: **Intra-abdominal follicular dendritic cell sarcoma.** *Clin Transl Oncol* 2006, **8**(11):837-838.
25. Duan GJ, Wu F, Zhu J, Guo DY, Zhang R, Shen LL, Wang SH, Li Q, Xiao HL, Mou JH, et al: **Extranodal follicular dendritic cell sarcoma of the pharyngeal region: a potential diagnostic pitfall, with literature review.** *Am J Clin Pathol* 2009, **133**(1):49-58.
26. Encabo RS, McHugh J, Carrau RL, Kassam A, Heron D: **Follicular dendritic cell sarcoma of the nasopharynx.** *Am J Otolaryngol* 2008, **29**(4):262-264.
27. Eun YG, Kim SW, Kwon KH: **Follicular dendritic cell sarcoma of the tonsil.** *Yonsei Med J* 2010, **51**(4):602-604.
28. Fan YS, Ng WK, Chan A, Chan GS, Tsang J, Chim CS, Ip P: **Fine needle aspiration cytology in follicular dendritic cell sarcoma: a report of two cases.** *Acta Cytol* 2007, **51**(4):642-647.
29. Fraser CR, Wang W, Gomez M, Zhang T, Mathew S, Furman RR, Knowles DM, Orazi A, Tam W: **Transformation of chronic lymphocytic leukemia/small lymphocytic lymphoma to interdigitating dendritic cell sarcoma: evidence for transdifferentiation of the lymphoma clone.** *Am J Clin Pathol* 2009, **132**(6):928-939.
30. Gach JE, Carr RA, Charles-Holmes R: **Nodal follicular dendritic cell sarcoma of the axilla presenting as cellulitis.** *Br J Dermatol* 2006, **154**(1):177-178.
31. Gong QX, Fan QH, Zhou ZS, Zhang ZH, Yu MN, Wang Z, Wang C, Zhang WM: **[Inflammatory pseudotumor-like follicular dendritic cell tumor of spleen].** *Zhonghua Bing Li Xue Za Zhi* 2008, **37**(1):40-44.
32. Gordon MK, Kraus M, van Besien K: **Interdigitating dendritic cell tumors in two patients exposed to topical calcineurin inhibitors.** *Leuk Lymphoma* 2007, **48**(4):816-818.
33. Granados R, Aramburu JA, Rodriguez JM, Nieto MA: **Cytopathology of a primary follicular dendritic cell sarcoma of the liver of the inflammatory pseudotumor-like type.** *Diagn Cytopathol* 2008, **36**(1):42-46.
34. Han HS, Lee OJ, Lim SN, An JY, Lee KM, Choe KH, Lee KH, Kim ST: **Extranodal interdigitating dendritic cell sarcoma presenting in the pleura: a case report.** *J Korean Med Sci* 2011, **26**(2):304-307.
35. Hartert M, Strobel P, Dahm M, Nix W, Marx A, Vahl CF: **A follicular dendritic cell sarcoma of the mediastinum with immature T cells and association with myasthenia gravis.** *Am J Surg Pathol* 2010, **34**(5):742-745.
36. Hollingsworth J, Cooper WA, Nicoll KD, Wills EJ, Thiruvilangam V, Lee CS, Scolyer RA: **Follicular dendritic cell sarcoma of the lung: a report of two cases highlighting its pathological features and diagnostic pitfalls.** *Pathology* 2011, **43**(1):67-70.
37. Ishihara S, Honda Y, Asato T, Nonaka M, Nakagawa S, Hirashima K, Hayashi N, Baba H, Iyama K: **Interdigitating dendritic cell sarcoma of the ileum recurred in multiple lymph nodes and duodenum three years after operation without chemotherapy.** *Pathol Res Pract* 2010, **206**(7):514-518.
38. Jiang L, Admirand JH, Moran C, Ford RJ, Bueso-Ramos CE: **Mediastinal follicular dendritic cell sarcoma involving bone marrow: a case report and review of the literature.** *Ann Diagn Pathol* 2006, **10**(6):357-362.
39. Jo S, Babb MJ, Hilsinger RL Jr: **Interdigitating dendritic cell sarcoma of cervical lymph nodes.** *Arch Otolaryngol Head Neck Surg* 2006, **132**(11):1257-1259.
40. Kanaan H, Al-Maghrabi J, Linjawi A, Al-Abbassi A, Dandan A, Haider AR: **Interdigitating dendritic cell sarcoma of the duodenum with rapidly fatal course: a case report and review of the literature.** *Arch Pathol Lab Med* 2006, **130**(2):205-208.
41. Kapucuoglu N, Percineli S, Ventura T, Lang R, Al-Daraji W, Eusebi V: **Dendritic cell sarcomas/tumours of the breast: report of two cases.** *Virchows Arch* 2009, **454**(3):333-339.
42. Karaman E, Saritzali G, Kilic E, Korkut N, Enver O: **Follicular dendritic cell sarcoma of the parotid gland recurring 6 times within 12 years.** *J Craniofac Surg* 2009, **20**(6):2171-2172.
43. Khalid S, Yaqoob N, Pervez S: **Follicular dendritic cell sarcoma of lymph node—a rare entity.** *J Pak Med Assoc* 2006, **56**(3):137-139.
44. Kim SY, Kang JH, Chun SH, Chang MH, Kim YS, Lee SN, Kim MS, Kang CS: **Interdigitating dendritic cell sarcoma of the tonsil.** *Asia Pac J Clin Oncol* 2010, **6**(3):144-148.
45. Kim H, Park CM, Jeon YK, Yoo IR, Song SW, Goo JM, Lee HJ: **Computed Tomography and 18F-fluoro-2-deoxyglucose Positron Emission Tomography Findings of Primary Pulmonary Follicular Dendritic Cell Sarcoma: Case Report and a Literature Review.** *J Thorac Imaging* 2011.
46. Kovacs RB, Sattar HA, Krausz T, Kas J, Berta M, Sapi Z: **Primary follicular dendritic cell sarcoma of the lung.** *Histopathology* 2006, **49**(4):431-433.
47. Kure K, Khader SN, Suhlrand MJ, Ratech H, Grossberg R, Oktay MH: **Fine needle aspiration of follicular dendritic cell sarcoma in an HIV-positive man: a case report.** *Acta Cytol* 2010, **54**(5):707-711.
48. Leipsic JA, McAdams HP, Sporn TA: **Follicular dendritic cell sarcoma of the mediastinum.** *AJR Am J Roentgenol* 2007, **188**(6):W554-556.
49. Li J, Duan MH, Han B, Zhang W, Zhou DB, Zhao YQ, Shen T: **[Dendritic cell sarcoma: 4 cases report with literature review].** *Zhonghua Xue Ye Xue Za Zhi* 2008, **29**(4):263-266.
50. Liu X, Deng Y, Zhang X, Mukherjee R, Huang W, Zhang G, Wang H, Li X: **Interdigitating dendritic cell sarcoma following adult liver transplantation: case report and literature review.** *Pathol Oncol Res* 2011, **17**(2):397-402.
51. Long-Hua Q, Qin X, Ya-Jia G, Jian W, Xiao-Yuan F: **Imaging findings of follicular dendritic cell sarcoma: report of four cases.** *Korean J Radiol* 2011, **12**(1):122-128.
52. Low SE, Menasce LP, Manson CM: **Follicular dendritic cell sarcoma: a rare tumor presenting as an abdominal mass.** *Int J Surg Pathol* 2007, **15**(3):315-317.
53. Ludwig A: **[Extranodal follicular dendritic cell sarcoma of the tonsils].** *Hno* 2006, **54**(9):701-704.
54. Majhi U, Shirley S, Murhekar K: **Follicular dendritic cell sarcoma of oral cavity: report of 2 cases.** *Indian J Pathol Microbiol* 2007, **50**(3):545-547.
55. Martins PN, Reddy S, Martins AB, Facciuto M: **Follicular dendritic cell sarcoma of the liver: unusual presentation of a rare tumor and literature review.** *Hepatobiliary Pancreat Dis Int* 2011, **10**(4):443-445.
56. Miyagi T, Nagasaki A, Shinzato O, Ohshima K, Takasu N: **[Interdigitating dendritic cell sarcoma/tumor—a case report].** *Gan To Kagaku Ryoho* 2007, **34**(3):469-471.
57. Padilla-Rodriguez AL, Bembassat M, Lazaro M, Ortiz-Hidalgo C: **Intra-abdominal follicular dendritic cell sarcoma with marked pleomorphic features and aberrant expression of neuroendocrine markers: report of a case with immunohistochemical analysis.** *Appl Immunohistochem Mol Morphol* 2007, **15**(3):346-352.
58. Pailloor J, Iyengar KR, Chan KS, Sumithra S: **Follicular dendritic cell sarcoma of inguinal lymph node—a case report.** *Malays J Pathol* 2008, **30**(2):115-119.
59. Pisani F, Marino M, Sentinelli S, Petti MC: **Follicular dendritic cell sarcoma of the neck: report of a case treated by surgical excision and COP plus (PEG)-liposomal doxorubicin.** *J Exp Clin Cancer Res* 2008, **27**:33.
60. Pizzi M, Ludwig K, Palazzolo G, Busatto G, Rettore C, Altavilla G: **Cervical follicular dendritic cell sarcoma: a case report and review of the literature.** *Int J Immunopathol Pharmacol* 2011, **24**(2):539-544.
61. Romero-Guadarrama MB, Reyes-Posada O, Hernandez-Gonzalez MM, Duran-Padilla MA: **Follicular dendritic cell sarcoma/tumor: 2 cases of a rare tumor of difficult clinical and pathological diagnosis.** *Ann Diagn Pathol* 2009, **13**(4):257-262.
62. Sander B, Middel P, Gunawan B, Schulten HJ, Baum F, Golas MM, Schulze F, Grabbe E, Parwaresch R, Fuzesi L: **Follicular dendritic cell sarcoma of the spleen.** *Hum Pathol* 2007, **38**(4):668-672.
63. Shen SC, Wu CC, Ng KF, Wu RC, Chen HM, Chen TC: **Follicular dendritic cell sarcoma mimicking giant cell carcinoma of the pancreas.** *Pathol Int* 2006, **56**(8):466-470.
64. Shen DP, Ni XZ, Yin XL, Wu ZY: **Clinical and pathological features of follicular dendritic cell sarcoma of appendix: a case report.** *Chin Med J (Engl)* 2009, **122**(13):1595-1597.
65. Silver AL, Faquin WC, Caruso PA, Deschler DG: **Follicular dendritic cell sarcoma presenting in the submandibular region in an 11 year-old.** *Laryngoscope* 2011, **120**(Suppl 4):S183.

66. Soriano AO, Thompson MA, Admirand JH, Fayad LE, Rodriguez AM, Romaguera JE, Hagemester FB, Pro B: **Follicular dendritic cell sarcoma: a report of 14 cases and a review of the literature.** *Am J Hematol* 2007, **82**(8):725-728.
67. Suhail Z, Musani MA, Afaq S, Zafar A, Ahmed Ashrafi SK: **Follicular dendritic cell sarcoma of tonsil.** *J Coll Physicians Surg Pak* 2010, **20**(1):55-56.
68. Suzuki N, Katsusihma H, Takeuchi K, Nakamura S, Ishizawa K, Ishii S, Moriya T, DeCoteau JF, Miura I, Ichinohasama R: **Cytogenetic abnormality 46, XX, add(21)(q11.2) in a patient with follicular dendritic cell sarcoma.** *Cancer Genet Cytogenet* 2008, **186**(1):54-57.
69. Tokyol C, Yilmaz MD, Ekici O, Aktepe F: **Follicular dendritic cell sarcoma: a case report.** *Acta Cytol* 2008, **52**(2):235-239.
70. Tu XY, Sheng WQ, Lu HF, Wang J: **[Clinicopathologic study of intraabdominal extranodal follicular dendritic cell sarcoma].** *Zhonghua Bing Li Xue Za Zhi* 2007, **36**(10):660-665.
71. Vaideeswar P, George SM, Kane SV, Chaturvedi RA, Pandit SP: **Extranodal follicular dendritic cell sarcoma of the tonsil - case report of an epithelioid cell variant with osteoclastic giant cells.** *Pathol Res Pract* 2009, **205**(2):149-153.
72. Vives S, Fernandez MT, Lopez de Castro PE, Ribera JM: **[Interdigitating dendritic cell sarcoma with localization to the lung].** *Med Clin (Barc)* 2006, **126**(14):559.
73. Voigt LP, Hmidi A, Pastores SM, Maki RG, Carlson DL, Bains MS, Halpern NA: **Management dilemmas due to a paratracheal follicular dendritic cell tumor.** *Ann Thorac Surg* 2006, **82**(5):1898-1900.
74. Wang LF, Wang RF, Wang ZC, Han W, Mei HL, Liu M: **[Follicular dendritic cell sarcoma of stomach: report of a case].** *Zhonghua Bing Li Xue Za Zhi* 2008, **37**(3):210-211.
75. Wang Xi, Zhang S, Thomas JO, Adegboyega PA: **Cytomorphology, ultrastructural, and cytogenetic findings in follicular dendritic cell sarcoma: a case report.** *Acta Cytol* 2010, **54**(5 Suppl):759-763.
76. Wang H, Su Z, Hu Z, Wen J, Liu B: **Follicular dendritic cell sarcoma: a report of six cases and a review of the Chinese literature.** *Diagn Pathol* 2010, **5**:67.
77. Wang Q, An L, Cui N, Sha J, Zhu D: **[Follicular dendritic cell sarcoma: a case report and review of literature].** *Lin Chung Er Bi Yan Hou Tou Jing Wai Ke Za Zhi* 2011, **25**(3):100-102.
78. Wu Q, Liu C, Lei L, Yan X, Wang B, Liu X, Yv L, Lv Y: **Interdigitating dendritic cell sarcoma involving bone marrow in a liver transplant recipient.** *Transplant Proc* 2010, **42**(5):1963-1966.
79. Yakushijin Y, Shikata H, Kito K, Ohshima K, Kojima K, Hato T, Hasegawa H, Yasukawa M: **Follicular dendritic cell tumor as an unknown primary tumor.** *Int J Clin Oncol* 2007, **12**(1):56-58.
80. Yamada Y, Haga H, Hernandez M, Kubota KC, Orii F, Nagashima K, Matsuno Y: **Follicular dendritic cell sarcoma of small intestine with aberrant T-cell marker expression.** *Pathol Int* 2009, **59**(11):809-812.
81. Yang GC, Wang J, Yee HT: **Interwoven dendritic processes of follicular dendritic cell sarcoma demonstrated on ultrafast papanicolaou-stained smears: a case report.** *Acta Cytol* 2006, **50**(5):534-538.
82. Yu L, Yang SJ: **Primary Follicular Dendritic Cell Sarcoma of the Thyroid Gland Coexisting With Hashimoto's Thyroiditis.** *Int J Surg Pathol* 2009.
83. Zhang ZX, Cheng J, Shi QL, Ma J, Zhou XJ, Zhou HB, Ma HH: **[Follicular dendritic cell sarcoma: a clinicopathologic study of 8 cases].** *Zhonghua Bing Li Xue Za Zhi* 2008, **37**(6):395-399.
84. Zhong GP, Sun WY, Gan MF, Yuan MC: **[Follicular dendritic cell sarcoma: a clinicopathologic study of five cases].** *Zhonghua Bing Li Xue Za Zhi* 2006, **35**(10):612-615.
85. Zhou ZY, Sun RC, Yang SD, Liang JB, Rui J, Pan MH: **Interdigitating dendritic cell tumor of the lymph node in the right submaxillary region: a case report and review of the literature.** *Int J Surg Pathol* 2011, **19**(1):88-92.
86. Zivkovic V, Basic M, Gligorijevic J, Pavlovic V, Lazarevic V, Petrovic A: **Follicular dendritic cell sarcoma in the lymph nodes of the neck.** *Bratisl Lek Listy* 2007, **108**(8):368-370.

doi:10.1186/1746-1596-6-94

Cite this article as: Schraven et al.: Dendritic cell tumor in a salivary gland lymph node: a rare differential diagnosis of salivary gland neoplasms. *Diagnostic Pathology* 2011 **6**:94.

Submit your next manuscript to BioMed Central and take full advantage of:

- Convenient online submission
- Thorough peer review
- No space constraints or color figure charges
- Immediate publication on acceptance
- Inclusion in PubMed, CAS, Scopus and Google Scholar
- Research which is freely available for redistribution

Submit your manuscript at
www.biomedcentral.com/submit

