

# Gas Tamponade Improved Cilio-Choroidal Effusion Induced by an Ab Interno Trabeculotomy with a Microhook: Two Cases

Mitsuya Otsuka, Naoki Tojo , Shuichiro Yanagisawa, Atsushi Hayashi 

Department of Ophthalmology, Graduate School of Medicine and Pharmaceutical Sciences, University of Toyama, Toyama, Japan

Correspondence: Atsushi Hayashi, Department of Ophthalmology, Graduate School of Medicine and Pharmaceutical Sciences, University of Toyama, 2630 Sugitani, Toyama, 930-0194, Japan, Tel +81-76-434-7363, Fax +81-76-434-5037, Email ahayashi@med.u-toyama.ac.jp

**Purpose:** We treated two patients with ciliary detachment due to an ab interno trabeculotomy. The ciliary detachment was improved by the use of sulfur hexafluoride (SF<sub>6</sub>) gas or octafluoro propane (C<sub>3</sub>F<sub>8</sub>) tamponade.

**Patients and Methods:** Patient 1 was a 52-year-old Brazilian man with primary open angle glaucoma (POAG). His preoperative intraocular pressure (IOP) was 29 mmHg. Patient 2 was a 57-year-old Japanese woman with POAG. Her preoperative IOP was 35 mmHg. Both patients underwent an ab interno trabeculotomy with a microhook. They caused ciliary detachment as a postoperative complication. We could observe their ciliary detachment with anterior segment optical coherence tomography (AS-OCT). Hypotony persisted for 2 months and the patients' ciliary detachment had not improved. They each underwent a pars plana vitrectomy (PPV) with simultaneous 20% SF<sub>6</sub> filling.

**Results:** In Patient 1, the use of the SF<sub>6</sub> gas tamponade successfully attached the ciliary body. His IOP was increased to 30 mmHg after this resolution of the ciliary detachment. He underwent additional tube shunt surgery. For Patient 2, the SF<sub>6</sub> gas tamponade improved the ciliary detachment but the ciliary body could not be attached. We injected 0.6 cc of 100% C<sub>3</sub>F<sub>8</sub> gas into the vitreous cavity, and this gas tamponade was able to attach the ciliary body.

**Conclusion:** AS-OCT is very useful to evaluate ciliary detachment. PPV+Gas tamponade can be a treatment option for ciliary detachment.

**Keywords:** ab interno trabeculotomy, ciliary detachment, cyclodialysis, tamponade, microhook

## Introduction

Microhook ab interno trabeculotomy (hereafter, “microhook”) is a minimally invasive glaucoma surgery (MIGS). Tanito et al were the first to describe microhook surgery as a treatment for patients with thin sclera, and they reported that the use of a microhook decreased such patients' intraocular pressure (IOP) from  $16.4 \pm 2.9$  mmHg to  $11.8 \pm 4.5$  mmHg.<sup>1</sup>

MIGS has some complications, one of which is ciliary detachment.<sup>2,3</sup> Some cases of ciliary body detachment may improve naturally.<sup>4,5</sup> If ciliary detachment continues over a long period of time, it might lead to hypotensive maculopathy due to low IOP.<sup>6</sup> Chronic hypotensive maculopathy results in permanent vision loss.<sup>7</sup> There are few reports of treatment methods for post-MIGS ciliary body detachment.<sup>2,3</sup> Treatment for ciliary body detachment after trabeculectomy includes methods to increase IOP, such as suturing a scleral flap. On the other hand, there is no consensus regarding the best treatment for ciliary body detachment due to MIGS such as microhooks. We have treated two patients whose ciliary detachment was improved by gas tamponade.

## Patients and Methods

We experienced two cases of ciliary body detachment as a postoperative complication of an interno trabeculotomy with a microhook. All examinations and surgeries were performed at the University of Toyama. We used SC-1600Pola

(Nidek, Nagoya, Japan) for examination for best-corrected visual acuity (BCVA). IOP was measured with Goldmann applanation tonometer. Central corneal thickness and the morphology of the ciliary body were measured with anterior segment optical coherence tomography (AS-OCT) (CASIA; Tomey, Nagoya, Japan).

## Patient 1

A 52-year-old Brazilian man presented with primary open-angle glaucoma (POAG) in the left eye. He had no history of eye surgery. At first visit, his IOP was elevated  $>21$  mmHg despite the use of four topical antiglaucoma medications (latanoprost, carteolol, brimonidine, and brinzolamide). His BCVA was (0.7xS-1.5Dcyl-1.25DA85°). He underwent microhook surgery on December 20, 2018.

Ab interno trabeculotomy with microhook was performed by a glaucoma specialist (N.T). The microhook surgical procedure was as follows: Retrobulbar anesthesia was administered with 2% lidocaine. An approx. 1.5-mm temporal clear corneal incision was made using a straight knife (Mani, Utsunomiya, Japan). Viscoelastic material (Opegan Hi, Santen Pharmaceutical, Osaka, Japan) was injected into the anterior chamber. Under visualization using a Swan-Jacob gonioscope lens (Ocular Instruments, Bellevue, WA, USA), the tip of the microhook was then inserted into Schlemm's canal and moved at an approx. 120° arc of the trabecular meshwork at only the nasal quadrant. The bleeding and the viscoelastic substance in the anterior chamber were aspirated using irrigation and aspiration (IA), and dexamethasone sodium phosphate was injected into the conjunctiva.

The day after the surgery, the patient's postoperative IOP was 3 mmHg, and we observed hyphema and a shallow anterior chamber. One week postsurgery his IOP was 1 mmHg and the hyphema had improved, and our use of AS-OCT and ultrasound biomicroscopy (UMB) (UD-8000; Tomey, Nagoya, Japan) revealed a ciliary detachment.

The postoperative treatment protocol was as follows: The postoperative treatments consisted of topical steroids, antibiotics, and non-steroidal anti-inflammatory drugs (NSAIDs). The antibiotics and steroids were applied for 4 weeks. The NSAID doses were reduced over the 12 weeks period. The glaucoma medications that had been used before surgery were continued after surgery. In this case, we had discontinued the patient's glaucoma medications after the surgery due to hypotony. The steroid was used for 12 weeks. At 1 month postsurgery the patient's IOP was 1 mmHg, and at 2 months it was 2 mmHg. The shallow anterior chamber and ciliary detachment did not improve (Figure 1). There was no choroidal detachment. The patient's BCVA was (0.2S+2.5D).

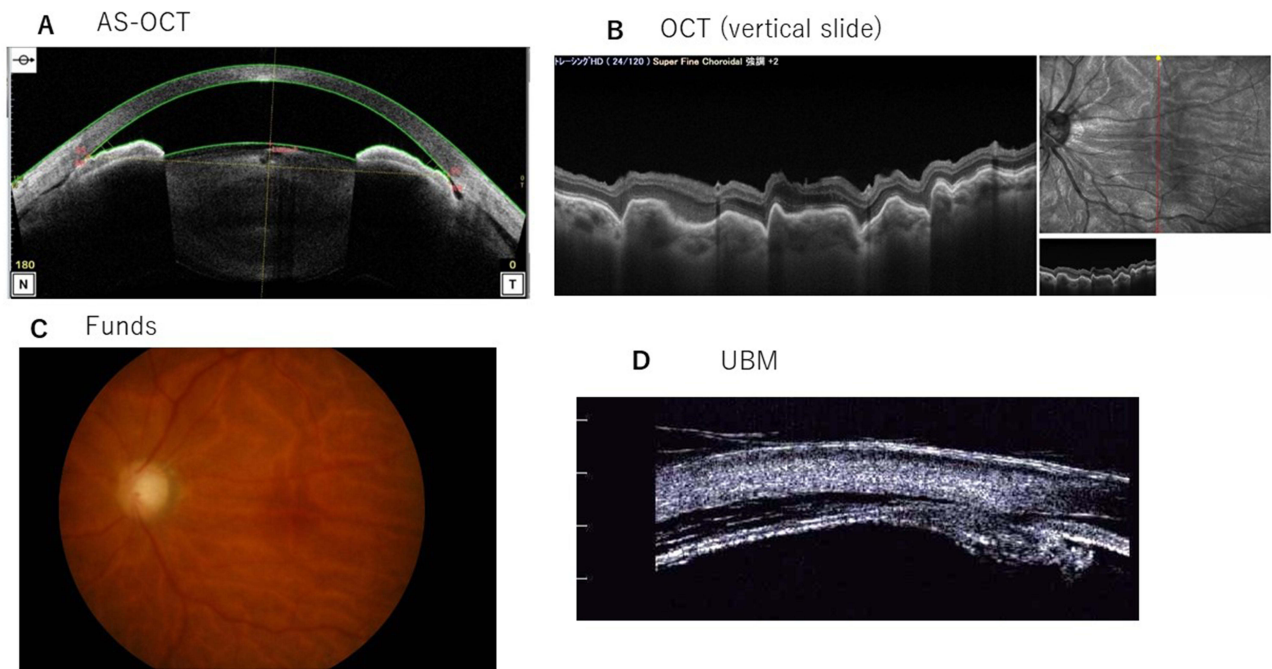
On March 19, 2019 (89 days postsurgery), the patient's IOP was 3 mmHg and the shallow anterior chamber and ciliary detachment had not improved. We then inserted Healon® V Ophthalmic Viscoelastic Substance (Johnson & Johnson Vision, Santa Ana, CA) into the anterior chamber. At 3 hr later, the patient's IOP was 48 mmHg. Acute high IOP causes headache and nausea. The Healon® V was thus removed quickly on the same day. Seven days after the removal of the Healon V, the patient's IOP was 2 mmHg and the shallow anterior chamber and ciliary detachment had not improved.

On April 11 (112 days postsurgery), we performed a pars plana vitrectomy (PPV), cataract surgery, and sulfur hexafluoride (SF<sub>6</sub>) gas tamponade. Retrobulbar anesthesia was administered with 2% lidocaine. We performed combined phacoemulsification and intraocular lens implantation simultaneously, considering the possibility of an after-gas cataract. The cataract surgery and PPV were performed with an EVA system (Dorc, Scheijdelweg, and the Netherlands) by a practiced surgeon (Y.S). The vitreous cavity was replaced with 20% SF<sub>6</sub> gas (Alcon Japan, Tokyo). With AS-OCT, we observed that the ciliary body was attached (Figure 2) at 26 days after the SF<sub>6</sub> tamponade treatment.

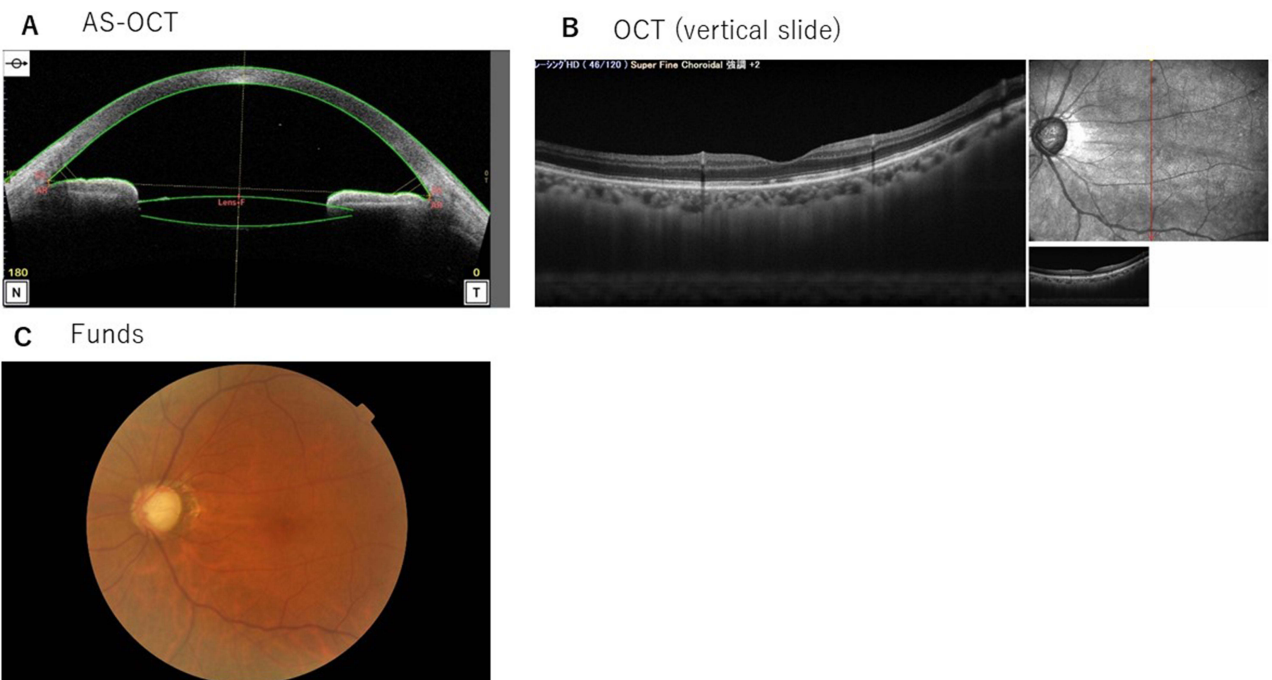
## Patient 2

A 57-year-old Japanese woman presented with POAG in the left eye. She had undergone selective laser trabeculoplasty (SLT) eye surgery on July 4, 2018. At first visit (on Dec. 5, 2018), her IOP was elevated  $>41$  mmHg despite the use of two topical antiglaucoma medications (tafluprost and carteolol). Her BCVA was 0.9xS-6.5Dcyl-0.5DA 70°.

She underwent microhook and cataract surgery on December 27, 2018. Ab interno trabeculotomy with microhook and cataract surgery was performed by a glaucoma specialist (N.T). The microhook surgical technique described above was used. After the microhook, cataract surgery was performed, and an intraocular lens (IOL) was implanted from clear temporal cornea. The cataract surgery was performed with a WhiteStar Signature system (Johnson & Johnson, New Brunswick, NJ). One week later, her IOP was 8 mmHg and her BCVA was 1.2S-3.0Dcyl-0.75DA140, and there were no postoperative complications.



**Figure 1** Patient 1's AS-OCT, OCT, and Fundus results at 92 days after microhook surgery. **(A)** The AS-OCT revealed ciliary detachment on both the nasal and temporal sides. The temporal ciliary detachment was larger. The anterior chamber was very narrow. **(B)** The OCT sliced vertically on the macular area. Retinal folds were observed. **(C)** Fundus results: retinal folds due to low IOP were observed. **(D)** Ultrasound biomicroscopy (UBM) revealed ciliary detachment on both the nasal and temporal sides.



**Figure 2** Patient 1's AS-OCT, OCT, and Fundus results at 36 days after SF<sub>6</sub> gas tamponade treatment. **(A)** The AS-OCT demonstrated that the ciliary body was attached. **(B)** As shown by OCT, retinal folds were improved. **(C)** The Fundus results revealed that the retinal folds were improved.

On February 1 (35 days postsurgery), the patient's IOP was 4 mmHg and her BCVA was 0.1 S-3.0D. We observed a ciliary detachment with AS-OCT (Figure 3). We stopped the patient's glaucoma medications, and we ordered steroids to be continued for 12 weeks. We waited for the ciliary detachment to improve naturally. At 2 and 3 months later, the patient's IOP values were 4 mmHg and 3 mmHg, respectively. As shown in Figure 3C, hypotonic maculopathy characterized by chorioretinal folds was caused. We did not observe other hypotonic complications such as a shallow anterior chamber or choroidal detachment.

On April 18 (112 days postsurgery), a practiced surgery (Y.S.) performed a PPV and the vitreous cavity was replaced with 20% SF<sub>6</sub>.

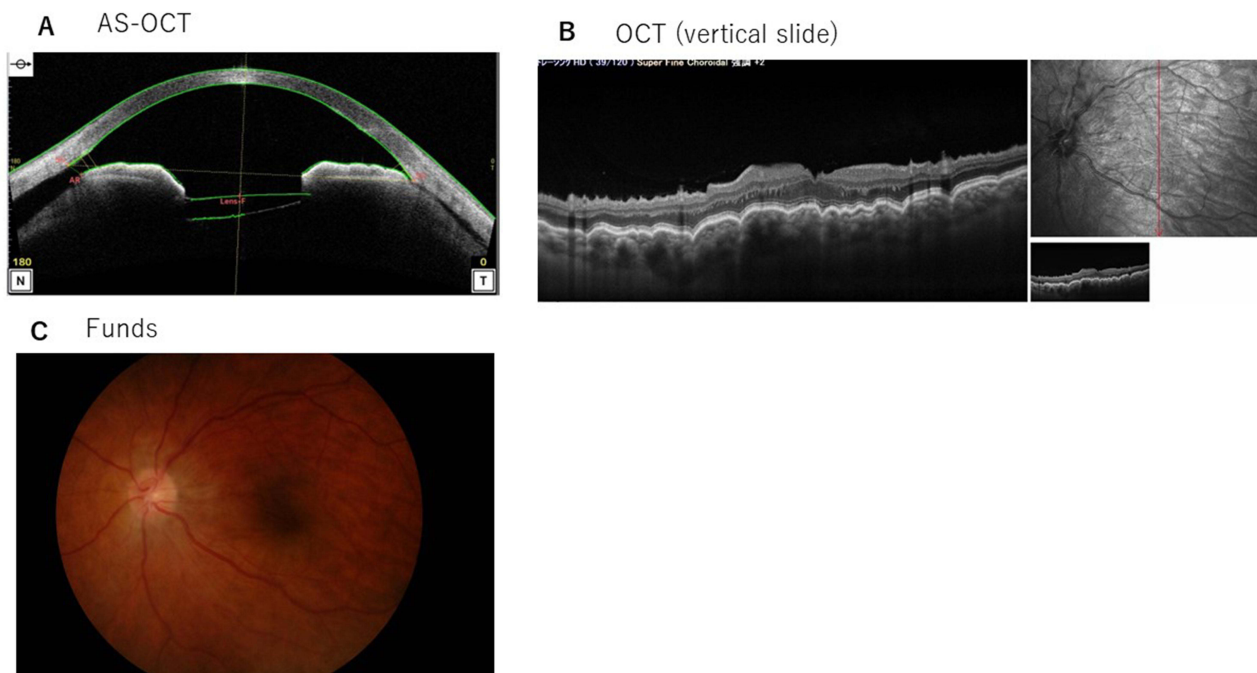
## Results

### Patient 1

The progress of Patient 1 is summarized in Table 1. Using AS-OCT, we observed ciliary body attachment. On May 7, 2018, the patient's IOP was 25 mmHg and his BCVA was 0.08xS-2.0Dcyl-1.5DA160°. His IOP was rising and was 29 mmHg on May 19, 2018. We performed additional Baerveldt glaucoma implant surgery on May 20, 2018, and on July 7, the patient's IOP had dropped to 8 mmHg. At his final visit (Nov. 19, 2018) his IOP was 8 mmHg without glaucoma medications, and his BCVA was 0.15xS-3.0Dcyl-2.25DA155°.

### Patient 2

Patient 2's progress is summarized in Table 2. We observed that the patient's ciliary detachment was improved, but her ciliary body did not attach (Figure 4). We inserted 0.6 cc of 100% octafluoro propane (C<sub>3</sub>F<sub>8</sub>) into the vitreous cavity. We observed that the ciliary body had attached after 11 days (Figure 5). At the patient's final visit (March 18, 2020), her IOP was 17 mmHg with two glaucoma medications, and her BCVA was 0.7xS-2.5D.



**Figure 3** Patient 2's AS-OCT, OCT, and Fundus results at 41 days after microhook surgery. (A) As shown by AS-OCT, ciliary detachment was present on both the nasal and temporal sides. The nasal ciliary detachment was larger. (B) OCT sliced vertically on the macular area. Radial folds around the fovea as hypotonic maculopathy were observed. (C) Fundus results: chorioretinal folds characteristic of hypotonic maculopathy were observed.



**Table 1** Summary of Patient 1

2018/12/20	0 day	Microhook surgery Figure 1 (2019/3/12)
2019/3/19	89 days	Inserted hylonV <sup>®</sup> into anterior chamber Removed hylon V <sup>®</sup> due to high IOP
2019/4/11	112 days	PEA+IOL+PPV+20%SF <sub>6</sub> Figure 2 (2019/5/7)
2019/5/20	151 days	Baerveldt glaucoma implant surgery

**Abbreviations:** IOP, intraocular pressure; PEA, Phacoemulsification and aspiration; IOL, intraocular lens; SF<sub>6</sub>, sulfur hexafluoride.

**Table 2** Summary of Patient 2

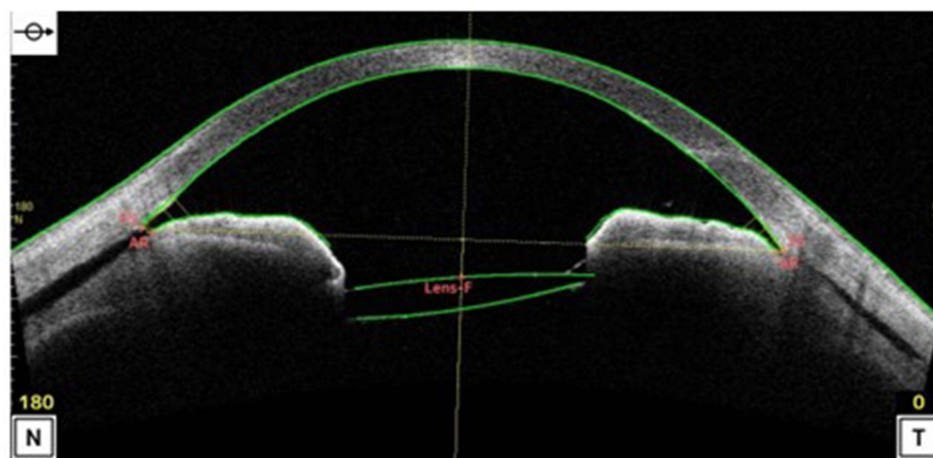
2018/12/27	0 day	PEA+IOL+microhook Figure 3 (2019/2/6)
2019/4/18	112 days	PPV+20%SF <sub>6</sub> Figure 4 (2019/5/7)
2019/5/9	131 days	100% C <sub>3</sub> F <sub>8</sub> (0.6cc) injection
		Figure 5A–C, (2019/5/20) (2019/7/3)

**Abbreviation:** C<sub>3</sub>F<sub>8</sub>, octafluoro propane.

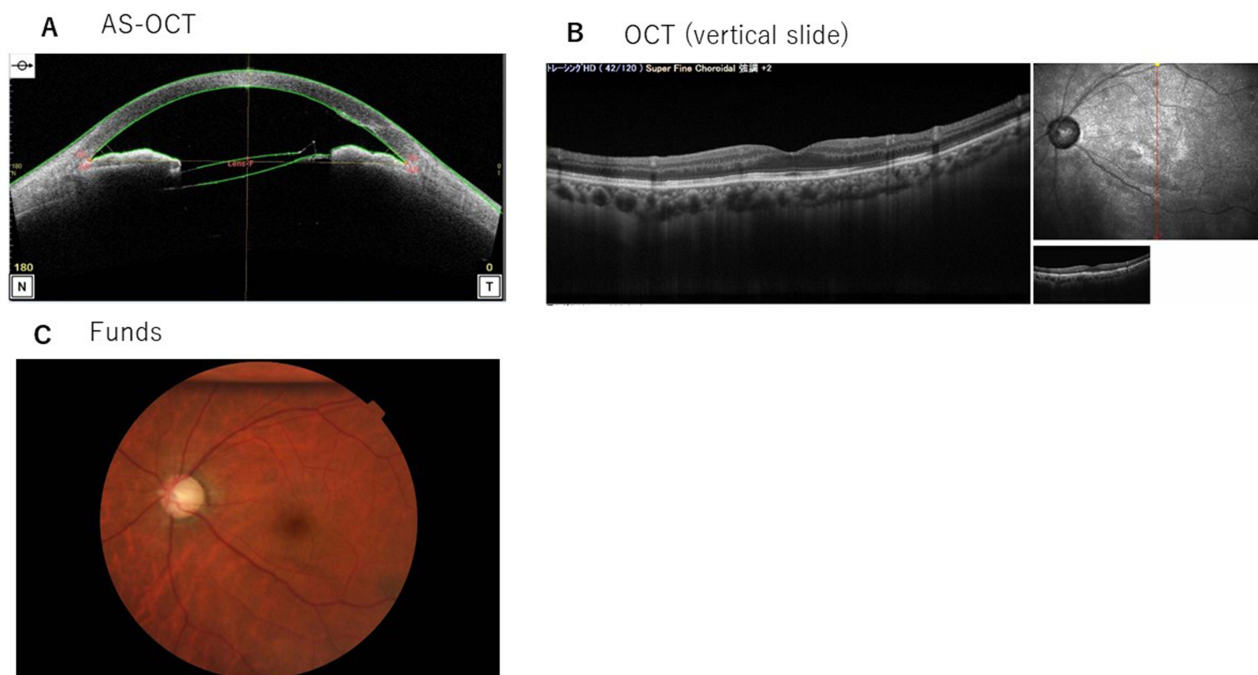
## Discussion

Hypotony maculopathy was reported first by Dellaporta in 1954. Hypotony causes papilloedema, vascular tortuosity, and chorioretinal folds.<sup>6</sup> If hypotony continues over a long period of time, it can lead to hypotensive maculopathy, resulting in permanent vision loss.<sup>7,8</sup> It is not known how long a period of hypotony could lead to vision loss.<sup>9</sup> The reported rate of chronic hypotony caused by trabeculectomy is 1%–18%.<sup>10,11</sup> Yun et al stated that spontaneous recovery from hypotony occurred in 32.4% of a series of eyes with hypotony.<sup>5</sup> It remains very difficult to estimate the optimal timing of treatment for hypotony.

## AS-OCT



**Figure 4** Patient 2's AS-OCT results at 19 days after SF<sub>6</sub> gas tamponade treatment. The ciliary detachment had improved, but the ciliary body did not attach.



**Figure 5** Patient 2's AS-OCT results at 11 days after  $C_3F_8$  gas tamponade treatment. **(A)** The AS-OCT demonstrated that the ciliary body was attached. **(B and C)** OCT and Fundus results at 55 days after the  $C_3F_8$  gas tamponade treatment. **(B)** OCT showed that the retinal folds were improved. **(C)** Fundus results: approx. 20% of the  $C_3F_8$  gas remained in the vitreous cavity. The retinal folds were improved.

Ciliary detachment causes complications due to hypotony, and thus an examination using AS-OCT is useful. In our cases, the reason for the hypotony might not have been known without AS-OCT. Burés-Jelstrup et al reported that AS-OCT was useful for the detection of ciliary detachment.<sup>12</sup> UBM testing can also provide information on ciliary body detachment.<sup>13</sup> AS-OCT is non-contact, so it is advantageous for patients with ciliary body detachment.

What is important from the experience that we have described herein is that there is a risk of ciliary detachment with not only a trabeculectomy but also with an ab interno trabeculotomy. There were several reports of ciliary body detachment occurring even after surgery other than trabeculectomy. Regarding treatment for ciliary body detachment, there were reports of (1) cycloplegic drops, (2) steroid medication, (3) laser treatment, (4) encircling scleral buckling, (5) intra-vitreous gas injection, (6) trans-scleral cryopexy and (7) silicon oil tamponade.<sup>3,14–17</sup> In our case, hypotony did not respond to medical therapy with steroid medications. Kokame et al reported that when ciliary body detachment did not respond to medical therapy with cycloplegic drops and steroid medications, then an intra-vitreous gas injection could rapidly resolve these complications.<sup>14</sup> For patients with glaucoma, it is desirable to preserve the conjunctiva, and scleral buckling is unlikely to be an option.

When using microhooks, we should be careful not to pull too hard on the trabecular meshwork. There are few reports of complications of hypotony caused by an ab interno trabeculotomy, and there are also few reports on its treatment.<sup>2</sup> Shue et al described a case in which cyclodialysis caused by a Kahook dual blade goniotomy was successfully treated with multiple sessions of argon laser photocoagulation.<sup>3</sup> If we had chosen cycloplegic drops or laser treatment, the results might have been different.

## Conclusion

In cases who persists hypotony after glaucoma surgery, ciliary body detachment might be caused. AS-OCT was useful for the detection of ciliary detachment. In this study, we were able to diagnose ciliary body detachment and observe the healing process using AS-OCT. We experienced two cases where PPV and gas tamponade were able to improve ciliary

detachment. We thus note that the use of a gas tamponade can be a treatment option for chronic hypotony due to ciliary detachment.

## Abbreviations

MIGS, minimally invasive glaucoma surgery; IOP, intraocular pressure; BCVA, best-corrected visual acuity; AS-OCT, anterior segment optical coherence tomography; UMB, ultrasound biomicroscopy; NSAIDs, non-steroidal anti-inflammatory drugs; PPV, pars plana vitrectomy; SF<sub>6</sub>, sulfur hexafluoride; SLT, selective laser trabeculoplasty; IOL, intraocular lens; C<sub>3</sub>F<sub>8</sub>, octafluoro propane.

## Data Sharing Statement

The datasets in our study are available from the corresponding author on reasonable request.

## Ethics Approval and Informed Consent

All procedures were performed in accordance with the 1964 Helsinki Declaration and its later amendments or comparable ethical standards. Ethical approval is not required for this case report in accordance with national guidelines. A written informed consent form was obtained from the patient to publish these data and images.

## Consent for Publication

We consent to publication.

## Author Contributions

M.O, H.A and N.T wrote this paper and made figures. N.T and S.Y performed the surgeries. All authors made a significant contribution to the work reported, whether that is in the conception, study design, execution, acquisition of data, analysis and interpretation, or in all these areas; took part in drafting, revising or critically reviewing the article; gave final approval of the version to be published; have agreed on the journal to which the article has been submitted; and agree to be accountable for all aspects of the work.

## Funding

No funding was received.

## Disclosure

No potential conflict of interest was reported by the authors.

---

## References

1. Tanito M, Ikeda Y, Fujihara E. Effectiveness and safety of combined cataract surgery and microhook ab interno trabeculotomy in Japanese eyes with glaucoma: report of an initial case series. *Jpn J Ophthalmol.* 2017;61(6):457–464. doi:10.1007/s10384-017-0531-z
2. Garweg RA, Pfister IB, Schild C, et al. IOP-lowering and drug-sparing effects of trabectome surgery with or without cyclodialysis ab interno. *Graefes Arch Clin Exp Ophthalmol.* 2023;261(10):2917–2925. doi:10.1007/s00417-023-06063-8
3. Shue A, Levine RM, Gallousis GM, Teng CC. Cyclodialysis cleft associated with Kahook dual blade goniotomy. *J Curr Glaucoma Pract.* 2019;13(2):74–76. doi:10.5005/jp-journals-10078-1255
4. Sato T, Kawaji T, Hirata A. Transient ciliochoroidal detachment after 360-degree suture trabeculotomy ab interno for open-angle glaucoma: 12-month follow-up. *Eye.* 2019;33(7):1081–1089. doi:10.1038/s41433-019-0375-5
5. Yun S, Chua B, Clement CI. Does chronic hypotony following trabeculectomy represent treatment failure? *J Curr Glaucoma Pract.* 2015;9(1):12–15. doi:10.5005/jp-journals-10008-1176
6. Costa VP, Arcieri ES. Hypotony maculopathy. *Acta Ophthalmol Scand.* 2007;85(6):586–597. doi:10.1111/j.1600-0420.2007.00910.x
7. Tunc Y, Tetikoglu M, Kara N, Sagdik HM, Ozarpaci S, Elcioglu MN. Management of hypotony and flat anterior chamber associated with glaucoma filtration surgery. *Int J Ophthalmol.* 2015;8(5):950–953. doi:10.3980/j.issn.2222-3959.2015.05.17
8. Seah SK, Prata JA, Minckler DS, Baerveldt G, Lee PP, Heuer DK. Hypotony following trabeculectomy. *J Glaucoma.* 1995;4(2):73–79. doi:10.1097/00061198-199504000-00002
9. Cohen SM, Flynn HW, Palmberg PF, Gass JD, Grajewski AL, Parrish RK. Treatment of hypotony maculopathy after trabeculectomy. *Ophthalmic Surg Lasers.* 1995;26(5):435–441. doi:10.3928/1542-8877-19950901-11

10. Kosior-Jarecka E, Wrobel-Dudzinska D, Swiech A, Zarnowski T. Bleb compressive sutures in the management of hypotony maculopathy after glaucoma surgery. *J Clin Med.* 2021;10(11):1.
11. Eha J, Hoffmann EM, Pfeiffer N. Long-term results after transconjunctival resuturing of the scleral flap in hypotony following trabeculectomy. *Am J Ophthalmol.* 2013;155(5):864–869. doi:10.1016/j.ajo.2012.12.004
12. Bures-Jelstrup A, Navarro R, Mateo C, Adan A, Corcostegui B. Detection of ciliary body detachment with anterior segment optical coherence tomography. *Acta Ophthalmol.* 2008;86(7):810–811. doi:10.1111/j.1600-0420.2007.01130.x
13. Chen WL, Yang CM, Chen YF, et al. Ciliary detachment after pars plana vitrectomy: an ultrasound biomicroscopic study. *Retina.* 2002;22(1):53–58. doi:10.1097/00006982-200202000-00010
14. Kokame GT, Card K, Yim MC. Treatment of hypotony with an intravitreal gas bubble. *Retin Cases Brief Rep.* 2023;17(6):737–738. doi:10.1097/ICB.0000000000001284
15. Cisiecki S, Bonińska K, Bednarski M. Encircling scleral buckling surgery for severe hypotony with ciliary body detachment on anterior segment swept-source optical coherence tomography: a case series. *J Clin Med.* 2022;11(16):4647. doi:10.3390/jcm11164647
16. Gross JB, Davis GH, Bell NP, Feldman RM, Blieden LS. Surgical repair of large cyclodialysis clefts. *Eur J Ophthalmol.* 2017;27(3):382–385. doi:10.5301/ejo.5000868
17. Savastano A, Carlà MM, Gambini G, et al. Spontaneous ciliary body detachment in a Marfan patient: a case of personalized management. *Am J Ophthalmol Case Rep.* 2023;30:101840. doi:10.1016/j.ajoc.2023.101840

### International Medical Case Reports Journal

Dovepress

### Publish your work in this journal

The International Medical Case Reports Journal is an international, peer-reviewed open-access journal publishing original case reports from all medical specialties. Previously unpublished medical posters are also accepted relating to any area of clinical or preclinical science. Submissions should not normally exceed 2,000 words or 4 published pages including figures, diagrams and references. The manuscript management system is completely online and includes a very quick and fair peer-review system, which is all easy to use. Visit <http://www.dovepress.com/testimonials.php> to read real quotes from published authors.

Submit your manuscript here: <https://www.dovepress.com/international-medical-case-reports-journal-journal>