

Closed Reduction for Developmental Dysplasia of the Hip: Early-term Results From a Prospective, Multicenter Cohort

Wudbhav N. Sankar, MD,* Alex L. Gornitzky, BS,* Nicholas M.P. Clarke, MD,†
 José A. Herrera-Soto, MD,‡ Simon P. Kelley, MD,§ Travis Matheny, MD,||
 Kishore Mulpuri, MBBS, MS (Ortho), MHSc,¶## Emily K. Schaeffer, PhD,¶##
 Vidyadhar V. Upasani, MD,** Nicole Williams, MD,††‡‡ Charles T. Price, MD,‡ and
 International Hip Dysplasia Institute

Background: Closed reduction (CR) is a common treatment for infantile developmental dysplasia of the hip. The purpose of this observational, prospective, multicenter study was to determine the early outcomes following CR.

Methods: Prospectively collected data from an international multicenter study group was analyzed for patients treated from 2010 to 2014. Baseline demographics, clinical exam, radiographic/ultrasonographic data, and history of previous orthotic treatment were assessed. At minimum 1-year follow-up, failure was defined as an IHDI grade 3 or 4 hip and/or need for open reduction. The incidence of avascular necrosis (AVN), residual dysplasia, and need for further surgery was assessed.

Results: A total of 78 patients undergoing CR for 87 hips were evaluated with a median age at initial reduction of 8 months (range, 1 to 20 mo). Of these, 8 hips (9%) were unable to be closed reduced initially. At most recent follow-up (median 22 mo; range, 12 to 36 mo), 72/79 initially successful CRs (91%) remained stable. The likelihood of failure was unaffected by initial clinical reducibility of the hip ($P = 0.434$), age at initial

CR ($P = 0.897$), or previous treatment in brace ($P = 0.222$). Excluding those hips that failed initial CR, 18/72 hips (25%) developed AVN, and the risk of osteonecrosis was unaffected by prereduction reducibility of the hip ($P = 0.586$), age at CR ($P = 0.745$), presence of an ossific nucleus ($P = 0.496$), or previous treatment in brace ($P = 0.662$). Mean acetabular index on most recent radiographs was 25 degrees (± 6 degrees), and was also unaffected by any of the above variables. During the follow-up period, 8/72 successfully closed reduced hips (11%) underwent acetabular and/or femoral osteotomy for residual dysplasia.

Conclusions: Following an initially successful CR, 9% of hips failed reduction and 25% developed radiographic AVN at early-term follow-up. History of femoral head reducibility, previous orthotic bracing, and age at CR did not correlate with success or chances of developing AVN. Further follow-up of this prospective, multicenter cohort will be necessary to establish definitive success and complication rates following CR for infantile developmental dysplasia of the hip.

Level of Evidence: Level II—prospective observational cohort.

Key Words: developmental dysplasia of the hip, DDH, closed reduction, avascular necrosis, AVN, hip dysplasia

(*J Pediatr Orthop* 2019;39:111–118)

From the *Division of Orthopaedics, Children's Hospital of Philadelphia, Philadelphia, PA; †University Hospital Southampton NHS Foundation Trust, University of Southampton, Southampton, UK; ‡Arnold Palmer Medical Center, Orlando, FL; §Hospital for Sick Children, Toronto, ON; ¶British Columbia Children's Hospital; #Department of Orthopaedics, University of British Columbia, Vancouver, BC, Canada; ||Boston Children's Hospital, Boston, MA; **Rady Children's Hospital, San Diego, CA; ††Women's and Children's Hospital, North Adelaide; and ‡‡Centre for Orthopaedic and Trauma Research, University of Adelaide, Adelaide, SA, Australia.

Funding was received from the International Hip Dysplasia Institute for research support and study coordination.

The authors declare no conflicts of interest.

Reprints: Wudbhav N. Sankar, MD, Division of Orthopaedic Surgery, The Children's Hospital of Philadelphia, 34th and Civic Center Building, Wood Building, 2nd Floor, Philadelphia, PA 19104. E-mail: sankarw@email.chop.edu.

Supplemental Digital Content is available for this article. Direct URL citations appear in the printed text and are provided in the HTML and PDF versions of this article on the journal's Website, www.pedorthopaedics.com.

Copyright © 2016 The Author(s). Published by Wolters Kluwer Health, Inc. This is an open-access article distributed under the terms of the Creative Commons Attribution-Non Commercial-No Derivatives License 4.0 (CCBY-NC-ND), where it is permissible to download and share the work provided it is properly cited. The work cannot be changed in any way or used commercially without permission from the journal.

DOI: 10.1097/BPO.0000000000000895

Encompassing a spectrum from mild dysplasia to frank dislocation, developmental dysplasia of the hip (DDH) is one of the most common developmental deformities of the lower extremities and one of the leading causes of future osteoarthritis and hip arthroplasty.^{1,2} The goal of treatment is to achieve a stable, concentric reduction to facilitate normal femoral head development and continued acetabular growth and remodeling.²⁻⁴ For those infants who fail initial nonsurgical management, or those who present late, treatment often involves closed reduction (CR) and spica casting.^{2,5} Although this procedure is generally successful,² concerns persist about the risk for iatrogenic avascular necrosis (AVN) of the femoral head and its associated impact on long-term outcomes and function.^{3,6-8} Other adverse outcomes may include redislocation and the need for further corrective surgery to address residual dysplasia.^{2,5}

Although a variety of demographic and baseline characteristics have been proposed to influence outcomes,

conflicting reports have often been described for each. Because of the mixed results following a failure of reduction, as well as the long-term negative impact of AVN, the role of CR in the management of DDH is increasingly being questioned. There is, however, a relative dearth of prospectively collected data guiding such decision-making. Therefore, the purpose of this multicenter study group was to establish a representative cohort of dislocated hips that may be followed prospectively to ascertain accurate long-term success and complications rates following CR for infantile DDH. For this investigation, the authors sought to determine early-term outcomes following CR, as well as potential risk factors for failure of therapy and the future development of AVN.

METHODS

The data for this study were queried from a prospectively collected database of a multicenter, international study group [International Hip Dysplasia Institute (IHDI)]. Institutional review board approval was obtained by all sites before patient enrollment. At each encounter, contributing surgeons collected and uploaded all relevant patient information and pertinent clinical details to a central database, including most recent hip radiographs. This deidentified database was then queried between 2009 and December 2014 to identify all patients below 18 months of age at initial diagnosis who were treated with CR for DDH. All hips were frankly dislocated by ultrasound ($\leq 35\%$ femoral head coverage)^{9,10} and/or radiograph (IHDI grade ≥ 3)¹¹ at the time of CR. Bilateral hips were counted separately. Fourteen hips were excluded for <12 months radiographic follow-up postreduction. As demonstrated in Figure 1, patients treated with open reduction at any time following the index CR were noted and separated from the final cohort

The database was designed to collect patient information and clinical details for each included hip from the time of initial consultation through most recent follow-up. All radiographic measurements, except AVN, were utilized as originally entered by the treating surgeon. The presence or absence of AVN by most recent follow-up was determined by independent, blinded assessment of follow-up radiographs by 3 authors from 3 different institutions (W.N.S., K.M., C.T.P.); group consensus was reached for any discrepancies. Each reviewer based their designations on the Salter criteria,^{12–14} but for the purposes of this manuscript each hip was only classified with a simple “yes” versus “no” for radiographic evidence of AVN to reduce subtype variability (Figs. 2A–C). Secondary outcomes included residual dysplasia (acetabular index and IHDI grade¹¹), redislocation rate, and the need for further corrective surgery. Failure of CR was defined as either an open reduction at any time following the index reduction and/or an IHDI grade 3 or 4 hip at most recent radiographic follow-up.

Statistical Analysis

Comparative analyses were performed using the Fisher exact/ χ^2 tests, Student *t* tests/Mann-Whitney *U*

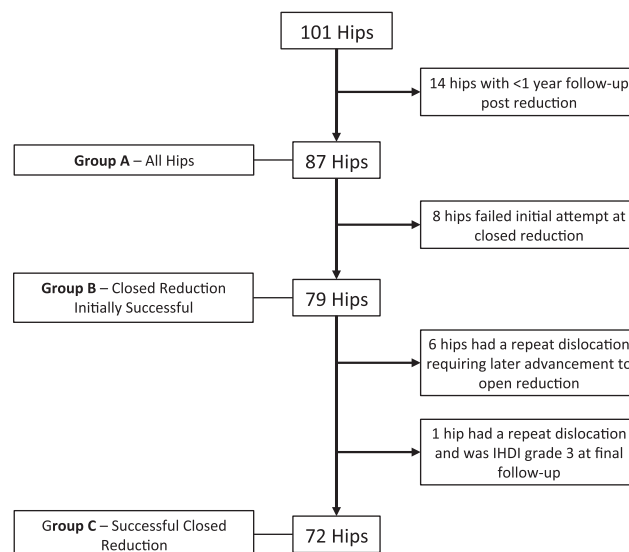


FIGURE 1. CONSORT (Consolidated Standards of Reporting Trials) diagram showing patients evaluated, excluded, and enrolled by stage, along with primary and secondary outcomes at latest radiographic follow-up.

test, or ANOVA. Multivariate regression was used to assess outcomes when controlling for given patient characteristics and/or clinical details. Categorical variables are reported as frequency and percentage; continuous variables are presented with a measure of central tendency (mean or median) and spread (SD or range). All comparative analyses were 2-tailed with α set at 0.05. Statistical analysis was performed using Stata (StataCorp, College Station, TX).

RESULTS

A total of 78 patients (87 hips) across 7 institutions were evaluated. Median age at initial CR was 8 months (range, 1 to 20 mo; Fig. 1). Of these, 8 hips (9%) could not be successfully closed reduced on initial attempt. Hips that were irreducible on clinical and/or ultrasonographic exam were more likely to have an unsuccessful initial CR. We found no other significant differences between those that were and were not able to be successfully closed reduced (Table 1).

Among infants with an initially successful CR ($n = 79$; 91%), 34% were previously treated in brace (Pavlik harness and/or rigid abduction orthosis) for a median of 3 weeks (range, 1 to 25 wk). An adductor tenotomy was performed in 85% of infants, a psoas release in 14%, and prereduction traction in 13%. When used, prereduction traction was for an average duration of 1 week. For those with preoperative ultrasound ($n = 32$, 41%), median femoral head coverage was 10% (range, 0% to 40%), and median α angle was 48 degrees (range, 22 to 60 degrees). For those with preoperative radiographs ($n = 57$, 72%), the proportion of infants with a prereduction IHDI grade of 1, 2, 3, or 4 was 0%, 12%,

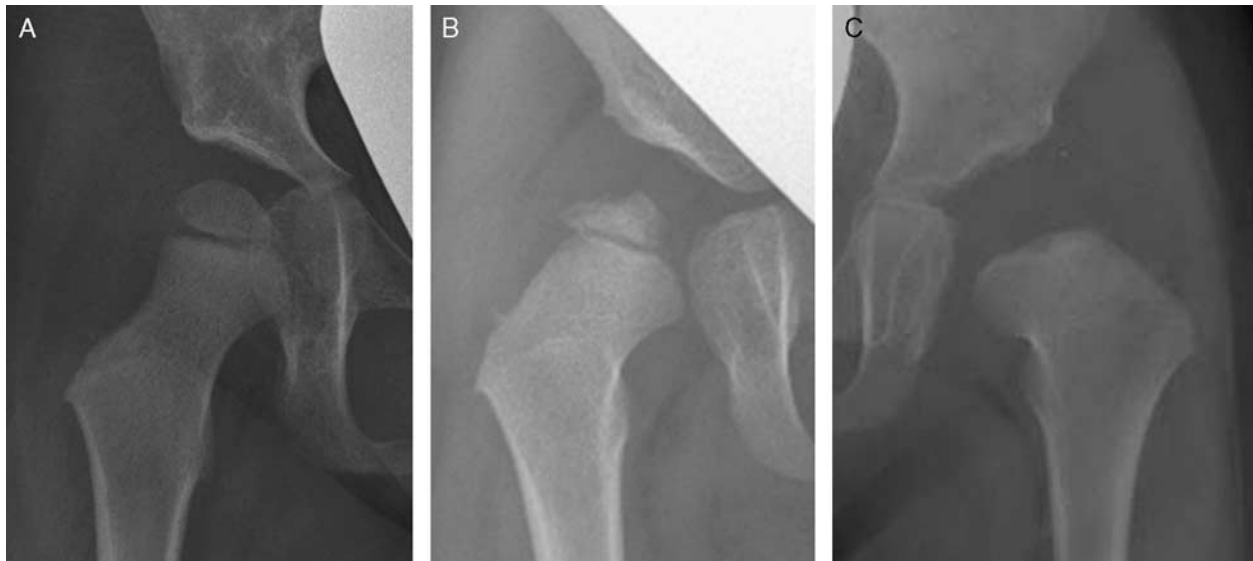

FIGURE 2. A, AP view of the right hip demonstrating a normal-appearing hip 36 months following closed reduction. B, AP view of the right hip demonstrating epiphyseal fragmentation 23 months following closed reduction, which was classified as AVN. C, AP view of the left hip 18 months following closed reduction demonstrating absence of the ossific nucleus and broadening of the femoral neck, which was also classified as AVN. AP indicates anteroposterior; AVN, avascular necrosis.

TABLE 1. Baseline Characteristics and Details of Initial Operative Management

	Failed Initial Closed Reduction	Successful Initial Closed Reduction*	P†
Patients [n (%)]	8 (10)	70 (90)	
Hips [n (%)]	8 (9)	79 (91)	
Baseline characteristics			
Age at baseline exam, median (mo)	8 (0-18)	7 (0-17)	0.763
Sex (no. females)	6/8 (75)	69/79 (87)	0.304
Laterality (no. left hips)	3/8 (38)	43/79 (54)	0.467
Bilateral disease at baseline	0/8 (0)	26/79 (33)	0.099
Breech position	2/8 (25)	12/74 (16)	0.619
Family history of DDH (immediate and/or extended)	4/7 (57)	22/77 (29)	0.195
History of swaddling	5/7 (71)	37/77 (48)	0.433
History of clubfoot, torticollis, and/or other congenital foot disease	0/8 (0)	7/79 (9)	1.000
Prereduction reducibility of affected hip (ultrasound and/or clinical exam)	0/8 (0)	41/79 (52)	0.006
Initial operative management			
Age at initial closed reduction			
Median (mo)	9 (2-20)	8 (1-19)	0.786
Age categories			1.000
< 6 mo old	2/8 (25)	24/79 (30)	
6 mo to < 12 mo old	4/8 (50)	32/79 (41)	
≥ 12 mo old	2/8 (25)	23/79 (29)	
Ossific nucleus present	5/8 (63)	42/75 (56)	1.000
Previous treatment in brace (Pavlik and/or rigid abduction orthosis)	2/8 (25)	27/79 (34)	0.713
Length of time in prereduction immobilization, median (wk)	4 (2-6)	3 (1-25)	0.931
Traction before CR	3/8 (38)	10/79 (13)	0.094
Adductor tenotomy	6/7 (86)	62/73 (85)	1.000
Psoas release	0/8 (0)	11/79 (14)	0.588
Arthrogram at CR	5/8 (63)	55/79 (69)	0.699
Tonnis grade at rest, mean grade	3.4 (± 0.9) for 5	3.0 (± 1.0) for 54	0.337
Reduction grade, mean grade	2.6 (± 0.9) for 5	1.1 (± 0.4) for 55	< 0.001
Stability grade with hip at 90 degrees' flexion, mean grade	2.0 (± 1.2) for 4	1.5 (± 0.8) for 52	0.255

Data presented as numerator/denominator (%), median (range), or mean (± SD).

Statistically significant P-values are bolded.

*Includes patients who failed closed reduction at a later date due to delayed femoral head redislocation.

†P-values correspond to intergroup differences based on the Fisher exact/ χ^2 test for categorical variables and the Mann-Whitney U test for continuous variables.

CR indicates closed reduction and spica casting; DDH, developmental dysplasia of the hip.

TABLE 2. Failure Following an Initially Successful Closed Reduction

Variables	Redislocation*	No Redislocation	P†
No. hips [n (%)]	7 (9)	72 (91)	
Length of time to redislocation, median (mo)	4 (1-6)		
Baseline characteristics			
Age at baseline, median (mo)	8 (0-16)	7 (0-17)	0.750
Sex (no. females)	6/7 (86)	63/72 (88)	1.000
Laterality (no. left hips)	3/7 (43)	40/72 (56)	0.696
Bilateral disease at baseline	2/7 (29)	24/72 (33)	1.000
Breech position	2/7 (29)	10/67 (15)	0.317
Family history of DDH (immediate and/or extended)	1/6 (17)	21/71 (30)	0.668
History of clubfoot, torticollis, or other congenital foot disease	0/7 (0)	7/72 (10)	1.000
Prereduction reducibility of affected hip (ultrasound and/or clinical exam)	5/7 (71)	36/72 (50)	0.434
Prereduction radiographic details			
IHDI grade			0.577
2	0/6 (0)	7/51 (14)	
3	3/6 (50)	29/51 (57)	
4	3/6 (50)	15/51 (29)	
Initial operative management			
Age at initial closed reduction			
Median (mo)	9 (3-16)	8 (1-19)	0.897
Age categories			0.361
< 6 mo old	3/7 (43)	21/72 (29)	
6 mo to < 12 mo old	1/7 (14)	31/72 (43)	
≥ 12 mo old	3/7 (43)	20/72 (28)	
Previous treatment in brace (Pavlik and/or rigid abduction orthosis)	4/7 (57)	23/72 (32)	0.222
Length of brace treatment	5 (1-5)	3 (1-25)	0.810
Traction before CR	1/7 (14)	9/72 (13)	1.000
Adductor tenotomy	4/7 (57)	58/66 (88)	0.065
Psoas release	0/7 (0)	11/72 (15)	0.585
Arthrogram at CR	6/7 (86)	49/72 (68)	0.669
Tonnis grade at rest, mean grade	3.5 (± 0.8)	2.9 (± 1.0)	0.152
Reduction grade, mean grade	1.2 (± 0.4)	1.1 (± 0.4)	0.879
Stability grade with hip at 90 degrees' flexion, mean grade	1.5 (± 0.5)	1.5 (± 0.8)	0.950
Length of postreduction spica casting	12 (7-21)	12 (4-30)	0.729

Data presented as frequency (%), median (range), or mean (± SD).

*Includes 6 patients (8%) with a redislocation requiring later open reduction and 1 patient (1%) with a repeat dislocation and an IHDI grade 3 at final follow-up.

†P-values correspond to intergroup differences based on the Fisher exact/ χ^2 test for categorical variables and the Mann-Whitney *U* test for continuous variables.

CR indicates closed reduction and spica casting; DDH, developmental dysplasia of the hip; IHDI, international hip dysplasia institute.

56%, and 32%, respectively. An ossific nucleus was present in 56% of hips. Following the initially successful CR, 90% of hips were placed into a hip spica cast (median 12 wk; range, 4 to 30 wk), and 10% were placed directly into a Denis Browne splint (median 26 wk; range, 9 to 53 wk). Of those treated with spica casting, 68% of hips were treated to some extent with a postcasting abduction orthosis (eg, Rhino cruiser, broomsticks, Denis Browne splint, etc.).

At most recent follow-up (median 22 mo; range, 12 to 36 mo), 7/79 initially successful CRs (9%) went on to fail (6 requiring open reduction; 1 with an IHDI grade of 3) (Table 2). The failures occurred at a median of 4 months (range, 1 to 6 mo) following the index reduction. Within our limited numbers, the likelihood of failure was unaffected by initial clinical reducibility of the hip ($P = 0.434$), age at initial CR ($P = 0.897$), or previous treatment in brace ($P = 0.222$). There was a nonsignificant trend toward fewer adductor releases (57% vs. 88%, $P = 0.065$) and higher initial IHDI grades in hips that failed initial reduction.

At most recent follow-up, 67/72 (93%) hips were IHDI grade 1 and 5/72 (7%) were grade 2. According to consensus review of the radiographs, 18/72 (25%) of hips developed radiographic evidence of AVN (Table 3). The risk of osteonecrosis was unaffected by prereduction reducibility of the hip ($P = 0.586$), age at CR ($P = 0.745$), presence of an ossific nucleus at the time of reduction ($P = 0.496$), previous treatment in brace ($P = 0.662$), or prereduction traction ($P = 1.000$). Hips that developed AVN had a significantly longer duration of postreduction spica casting (median 15 wk vs. 12 wk, $P = 0.011$). There was a nonsignificant trend toward increased AVN with higher initial IHDI grade.

At latest follow-up, mean acetabular index was 25 degrees (± 6 degrees), and was unaffected by any baseline characteristics or treatment details, including the presence of AVN on final radiographs ($P = 0.220$). The Spearman correlations revealed no statistically significant linear association between age at CR and final acetabular index ($P = 0.553$). During the follow-up period, 8/72 successfully reduced hips (11%) underwent acetabular and/or

TABLE 3. Presence of Radiographic AVN for All Hips With Successful CR at Final Follow-up

Variables	AVN Present	AVN Absent	P*
AVN on final radiographic follow-up	18/72 (25)	54/72 (75)	
Baseline characteristics			
Age at baseline, median (mo)	8 (1-17)	7 (0-17)	0.528
Sex (no. females)	15/18 (83)	48/54 (89)	0.682
Laterality (no. left hips)	11/18 (61)	29/54 (54)	0.584
Bilateral disease at baseline	8/18 (44)	16/54 (30)	0.248
Breech position	3/17 (18)	7/50 (14)	0.706
Family history of DDH (immediate and/or extended)	4/18 (22)	17/53 (32)	0.429
History of clubfoot, torticollis, or other congenital foot disease	0/18 (0)	7/54 (13)	0.181
Prereduction reducibility of affected hip (ultrasound and/or clinical exam)	8/18 (44)	28/54 (52)	0.586
Prereduction radiographic details			
IHDI grade			0.373
Grade 2	1/10 (10)	6/41 (15)	
Grade 3	4/10 (40)	25/41 (61)	
Grade 4	5/10 (50)	10/41 (24)	
Initial operative management			
Age at initial CR			
Median (mo)	9 (4-17)	8 (1-19)	0.745
Age categories			0.119
< 6 mo old	7/18 (39)	14/54 (26)	
6 mo to < 12 mo old	4/18 (22)	27/54 (50)	
≥ 12 mo old	7/18 (39)	13/54 (24)	
Ossific nucleus present at time of reduction	8/16 (50)	31/52 (60)	0.496
Previous treatment in brace (Pavlik and/or rigid abduction orthosis)	5/18 (28)	18/54 (33)	0.662
Length of bracing, median (wk)	3 (1-4)	3 (1-25)	0.475
Traction before CR	2/18 (11)	7/54 (13)	1.000
Adductor tenotomy	16/16 (100)	42/50 (84)	0.183
Psoas release	4/18 (22)	7/54 (13)	0.450
Length of postreduction spica casting, median (wk)	15 (7-26)	12 (4-30)	0.011
Radiographic details at final follow-up			
Length of final follow-up, median (mo)	21 (17-27)	22 (12-36)	0.320
Age at final follow-up, median (mo)	32 (22-39)	32 (12-40)	0.785
Intact Shenton's line	15/18 (83)	51/54 (94)	0.161
IHDI grade			0.322
Grade 1	18/18 (100)	49/54 (91)	
Grade 2	0/18 (0)	5/54 (9)	
Acetabular index (mean ± SD) (deg.)	27 (± 5)	25 (± 6)	0.220

Data presented as numerator/denominator (%) or median (range).

Statistically significant *P*-values are bolded.

**P* values correspond to intergroup differences based on the Fisher exact/ χ^2 test or the Mann-Whitney *U* test for continuous variables.

AVN indicates avascular necrosis; CR, closed reduction; DDH, developmental dysplasia of the hip; IHDI, international hip dysplasia institute.

femoral osteotomy for residual dysplasia (Supplementary Table 1, Supplemental Digital Content 1, <http://links.lww.com/BPO/A87>). Hips treated with further corrective surgery were older at the time of CR (median 14 mo vs. 8 mo, *P* = 0.003), more likely to have an ossific nucleus present (100% vs. 52%, *P* = 0.017), and less likely to have been treated with a prereduction brace (0% vs. 36%, *P* = 0.049). Hips with AVN were not more likely to undergo further corrective surgery (*P* = 1.000). Increasing severity of initial disease as measured by IHDI grade did not appear to affect the rate of further corrective surgery for residual dysplasia (*P* = 0.362).

DISCUSSION

As one of the primary treatment options for infants with DDH, CR typically includes examination under anesthesia, arthrogram with/without an adductor tenotomy, and postreduction immobilization of the affected

hip (eg, spica cast). Although largely successful, CR may also lead to a number of adverse complications, including AVN and loss of reduction. Most outcome data for CRs, however, are based on retrospective series. Specifically, a systematic review by Novais et al¹⁵ evaluating both open and closed management of DDH noted that “the majority of studies included were rated as being of poor methodologic quality” and that “higher quality evidence is needed to better understand” the potential risk factors for future AVN.

In addition to establishing a representative multicenter cohort that can be followed prospectively, the purpose of this investigation was to report early outcomes following CR for DDH. At early-term follow-up (median 22 mo; range, 12 to 36 mo), our cohort had a 91% initial success rate with a 25% incidence of AVN, a 9% incidence of redislocation following an initially successful CR, and an 11% incidence of further corrective surgery. Interestingly, the likelihood of either loss of reduction or

the development of AVN was unaffected by a number of characteristics frequently cited to negatively influence early outcomes, including femoral head reducibility before CR, previous orthotic bracing, age, or presence of the ossific nucleus at the time of reduction. Conversely, infants that were older at the time of CR were more likely to need further corrective surgery. Importantly, this study's multicenter design and primary analysis by investigators not affiliated with the treating institutions limited the publication bias inherent to any single-center, self-authored cohort.

Osteonecrosis is one of the most concerning complications following CR. In recent studies (published since 2000), the incidence of AVN following CR varies widely between 2% and 36%,^{4,5,13,14,16-27} with Cooper et al² noting that this disparity is "largely caused by differences in the definitions of AVN and the timing of follow-up." Comparing closed versus open treatment, Novais et al¹⁵ reported in their recent meta-analysis an incidence of significant AVN (grade ≥ 2) of 8% following CR versus 19% following OR, with Clarke et al¹⁹ reporting a similar pattern of 7% and 14%, respectively. Here, our reported incidence of AVN was 25% at a median follow-up of approximately 2 years. Although some have suggested that prolonged follow-up for 10 to 12 years is necessary to ascertain the true incidence of AVN,^{3,6,7} others argue that follow-up beyond 2 years will not identify additional cases.^{14,28-30} A variety of classification criteria have also been used, and many authors differentially include low-grade changes.² This variation in AVN definitions and lengths of follow-up highlight the importance of establishing a prospective cohort that can be followed longitudinally to determine accurate data.

Multiple potential risk factors for AVN have been reported, with the presence of the ossific nucleus at the time of reduction remaining one of the most controversial. Although some authors argue that the ossific nucleus is protective against AVN,^{17,19,27,31} others note no such effect.^{18,23,24,26,29} Relatedly, whereas some have linked older age at reduction to a higher incidence of AVN but a lower rate of severe disease,^{3,7,18,32} others have noted that age at reduction has no effect on AVN risk.^{4,6,15,24,29,31} In this cohort, neither age at reduction nor the presence of an ossific nucleus was associated with the presence of AVN. Consistent with prior studies, sex, bilateral disease, family history, previous treatment with Pavlik harness/abduction orthosis, and the performance of an adductor tenotomy also did not impact disease frequency.^{3,6,13,17,21,29,31} Although a trend was appreciated, the limited number of patients with prereduction radiographs may have constrained our findings regarding the severity of initial dislocation (as measured by IHDI grade), which prior reports suggest may influence AVN risk.^{3,18,32} We did note an increased length of spica cast immobilization following CR in those who developed AVN versus those who did not. Whereas this difference was statistically significant, its clinical significance is unclear. It is possible that longer periods of casting were an indirect reflection of greater disease severity, or that there

is an intrinsic ill effect on perfusion from prolonged immobilization of an infantile hip.

Achieving, and maintaining, a concentric reduction of the hip is one of the primary drivers of future acetabular growth and development.^{4,33,34} Although potential overlap is likely, rates of failed initial reduction across the literature vary between 6% and 25%,^{2,13,16,20,25,35,36} and rates of loss of reduction from 0% to 18%.^{5,13,16,20,23-25,35-37} In this cohort, 91% of hips were successfully reduced on the initial attempt, with 9% going on to fail CR at latest follow-up. Importantly, however, rates of failed initial reduction are likely to vary considerably based upon the treating surgeon's threshold for proceeding directly to open reduction. Nevertheless, our results fall within the lower half of the previously reported ranges, suggesting reasonable success may be achieved following CR.

Several factors have been proposed to increase risk of residual dysplasia following CR. In this study, we chose to measure residual dysplasia in 2 ways: objective acetabular measurements (acetabular index and IHDI grade) and the incidence of further corrective surgery. Regarding the former, no patient-specific factors in this cohort were predictive of worsened acetabular index, including prereduction IHDI grade, age at reduction, or final AVN status. Regarding the latter, 11% of hips in this study were treated with a subsequent acetabuloplasty and/or femoral osteotomy, although that rate will likely rise with continued follow-up. In comparison, rates of further corrective surgery across the literature range as high as 57% to 100%,^{19,22,38} with the majority of published studies identifying a frequency $\leq 35\%$.^{5,16,21,23,25,36,37,39} In contrast to the acetabular index, we did observe that increased age at the time of CR predicted a higher rate of further corrective surgery, which is consistent with Luhmann et al's³⁷ observation that delaying CR may increase the need for later intervention.

This study has a number of limitations. First, longer follow-up may lead to different values for AVN, acetabular dysplasia, and further corrective surgery. The purpose of this study was to report early results from a prospective cohort of infants undergoing CR. Certainly, we aim to follow this cohort longitudinally to provide long-term success and complication rates. Second, AVN is difficult to unilaterally define, as there are a variety of different classification systems in use across the literature. Given the potential for these variations to impact the reported frequency of AVN within our database, we chose to retrospectively assess AVN using a blinded panel of surgeons each applying the Salter criteria in a yes/no manner, a step the authors felt was imperative to improve the accuracy and consistency of our findings. Third, due to the large number of surgeons contributing to the database, there is considerable variation in treatment practices. Regardless, the authors view this heterogeneity as a strength in that it more accurately reflects real-world practice. Fourth, given the smaller number of hips with certain conditions and/or outcomes, the *P*-values in our tables should be interpreted with caution. Fifth, we did

not measure abduction angle in postreduction immobilization, which has been suggested to influence AVN rates,^{26,40} as practice variation in postoperative imaging and treatment limited the availability of such data. Finally, the quality of our results is dependent on the completeness and accuracy of data reporting by the individual centers, which is a limitation of any multicenter database study.

In conclusion, this prospective, multicenter cohort of infants undergoing CR for DDH demonstrated a 9% failure rate after initially successful reduction and a 25% rate of AVN at early-term follow-up. In this study, older age at the time of CR and longer immobilization in a spica cast were predictive of needing further corrective surgery for residual dysplasia and developing osteonecrosis, respectively. No other patient-specific factors related to history, treatment, or outcome were associated with the future development of either AVN, residual dysplasia, or failed reduction. Further follow-up of this cohort will be necessary to establish accurate long-term success and complication rates following CR for infantile DDH.

REFERENCES

- Shipman SA, Helfand M, Moyer VA, et al. Screening for developmental dysplasia of the hip: a systematic literature review for the US Preventive Services Task Force. *Pediatrics*. 2006;117:e557–e576.
- Cooper AP, Doddabasappa SN, Mulpuri K. Evidence-based management of developmental dysplasia of the hip. *Orthop Clin North Am*. 2014;45:341–354.
- Malvitz TA, Weinstein SL. Closed reduction for congenital dysplasia of the hip. Functional and radiographic results after an average of thirty years. *J Bone Joint Surg Am*. 1994;76:1777–1792.
- Li Y, Xu H, Li J, et al. Early predictors of acetabular growth after closed reduction in late detected developmental dysplasia of the hip. *J Pediatr Orthop B*. 2015;24:35–39.
- Murray T, Cooperman DR, Thompson GH, et al. Closed reduction for treatment of development dysplasia of the hip in children. *Am J Orthop (Belle Mead NJ)*. 2007;36:82–84.
- Brougham DI, Broughton NS, Cole WG, et al. Avascular necrosis following closed reduction of congenital dislocation of the hip. Review of influencing factors and long-term follow-up. *J Bone Joint Surg Br*. 1990;72:557–562.
- Kalamchi A, MacEwen GD. Avascular necrosis following treatment of congenital dislocation of the hip. *J Bone Joint Surg Am*. 1980;62:876–888.
- Roposch A, Liu LQ, Offiah AC, et al. Functional outcomes in children with osteonecrosis secondary to treatment of developmental dysplasia of the hip. *J Bone Joint Surg Am*. 2011;93:e145.
- Terjesen T, Bredland T, Berg V. Ultrasound for hip assessment in the newborn. *J Bone Joint Surg Br*. 1989;71:767–773.
- Gunay C, Atalar H, Dogruel H, et al. Correlation of femoral head coverage and Graf alpha angle in infants being screened for developmental dysplasia of the hip. *Int Orthop*. 2009;33:761–764.
- Narayanan U, Mulpuri K, Sankar WN, et al. Reliability of a new radiographic classification for developmental dysplasia of the hip. *J Pediatr Orthop*. 2014;35:478–484.
- Salter RB, Kostuik J, Dallas S. Avascular necrosis of the femoral head as a complication of treatment for congenital dislocation of the hip in young children: a clinical and experimental investigation. *Can J Surg*. 1969;12:44–61.
- Gornitzky AL, Georgiadis AG, Seeley MA, et al. Does perfusion MRI after closed reduction of developmental dysplasia of the hip reduce the incidence of avascular necrosis? *Clin Orthop Relat Res*. 2015;474:1153–1165.
- Tiderius C, Jaramillo D, Connolly S, et al. Post-closed reduction perfusion magnetic resonance imaging as a predictor of avascular necrosis in developmental hip dysplasia: a preliminary report. *J Pediatr Orthop*. 2009;29:14–20.
- Novais EN, Hill MK, Carry PM, et al. Is age or surgical approach associated with osteonecrosis in patients with developmental dysplasia of the hip? A meta-analysis. *Clin Orthop Relat Res*. 2015;474:1166–1177.
- Yamada N, Maeda S, Fujii G, et al. Closed reduction of developmental dislocation of the hip by prolonged traction. *J Bone Joint Surg Br*. 2003;85:1173–1177.
- Carney BT, Clark D, Minter CL. Is the absence of the ossific nucleus prognostic for avascular necrosis after closed reduction of developmental dysplasia of the hip? *J Surg Orthop Adv*. 2004;13:24–29.
- Sibinski M, Synder M, Domzalski M, et al. Risk factors for avascular necrosis after closed hip reduction in developmental dysplasia of the hip. *Orthop Traumatol Rehabil*. 2004;6:60–66.
- Clarke NM, Jowett AJ, Parker L. The surgical treatment of established congenital dislocation of the hip: results of surgery after planned delayed intervention following the appearance of the capital femoral ossific nucleus. *J Pediatr Orthop*. 2005;25:434–439.
- Senaran H, Bowen JR, Harcke HT. Avascular necrosis rate in early reduction after failed Pavlik harness treatment of developmental dysplasia of the hip. *J Pediatr Orthop*. 2007;27:192–197.
- Alsiddiky AM, Bakarman KA, Alzain KO, et al. The early detection and management of unstable concentric closed reduction of DDH with percutaneous K-wire fixation in infants 6 to 12 months of age. *J Pediatr Orthop*. 2012;32:64–69.
- Bolland BJ, Wahed A, Al-Hallao S, et al. Late reduction in congenital dislocation of the hip and the need for secondary surgery: radiologic predictors and confounding variables. *J Pediatr Orthop*. 2010;30:676–682.
- Cooke SJ, Rees R, Edwards DL, et al. Ossification of the femoral head at closed reduction for developmental dysplasia of the hip and its influence on the long-term outcome. *J Pediatr Orthop B*. 2010;19:22–26.
- Roposch A, Odeh O, Doria AS, et al. The presence of an ossific nucleus does not protect against osteonecrosis after treatment of developmental dysplasia of the hip. *Clin Orthop Relat Res*. 2011;469:2838–2845.
- Pospischill R, Weninger J, Ganger R, et al. Does open reduction of the developmental dislocated hip increase the risk of osteonecrosis? *Clin Orthop Relat Res*. 2012;470:250–260.
- Madhu TS, Akula M, Scott BW, et al. Treatment of developmental dislocation of hip: does changing the hip abduction angle in the hip spica affect the rate of avascular necrosis of the femoral head? *J Pediatr Orthop B*. 2013;22:184–188.
- Morbi AH, Carsi B, Gorianinov V, et al. Adverse outcomes in infantile bilateral developmental dysplasia of the hip. *J Pediatr Orthop*. 2015;35:490–495.
- Buchanan JR, Greer RB III, Cotler JM. Management strategy for prevention of avascular necrosis during treatment of congenital dislocation of the hip. *J Bone Joint Surg Am*. 1981;63:140–146.
- Luhmann SJ, Schoenecker PL, Anderson AM, et al. The prognostic importance of the ossific nucleus in the treatment of congenital dysplasia of the hip. *J Bone Joint Surg Am*. 1998;80:1719–1727.
- Thomas CL, Gage JR, Ogden JA. Treatment concepts for proximal femoral ischemic necrosis complicating congenital hip disease. *J Bone Joint Surg Am*. 1982;64:817–828.
- Segal LS, Boal DK, Borthwick L, et al. Avascular necrosis after treatment of DDH: the protective influence of the ossific nucleus. *J Pediatr Orthop*. 1999;19:177–184.
- Kruczynski J. Avascular necrosis of the proximal femur in developmental dislocation of the hip. Incidence, risk factors, sequelae and MR imaging for diagnosis and prognosis. *Acta Orthop Scand Suppl*. 1996;268:1–48.

33. Brougham DI, Broughton NS, Cole WG, et al. The predictability of acetabular development after closed reduction for congenital dislocation of the hip. *J Bone Joint Surg Br.* 1988;70:733–736.
34. Harris NH. Acetabular growth potential in congenital dislocation of the hip and some factors upon which it may depend. *Clin Orthop Relat Res.* 1976;119:99–106.
35. Zions LE, MacEwen GD. Treatment of congenital dislocation of the hip in children between the ages of one and three years. *J Bone Joint Surg Am.* 1986;68:829–846.
36. Tang HC, Lee WC, Kao HK, et al. Surgical outcomes of developmental dysplasia of the hip with or without prior failed closed reduction. *J Pediatr Orthop.* 2015;35:703–707.
37. Luhmann SJ, Bassett GS, Gordon JE, et al. Reduction of a dislocation of the hip due to developmental dysplasia. Implications for the need for future surgery. *J Bone Joint Surg Am.* 2003;85-A2:239–243.
38. Terjesen T, Halvorsen V. Long-term results after closed reduction of late detected hip dislocation: 60 patients followed up to skeletal maturity. *Acta Orthop.* 2007;78:236–246.
39. Zamzam MM, Kremli MK, Khoshhal KI, et al. Acetabular cartilaginous angle: a new method for predicting acetabular development in developmental dysplasia of the hip in children between 2 and 18 months of age. *J Pediatr Orthop.* 2008;28:518–523.
40. Schoenecker PL, Bitz M, Witeside LA. The acute effect of position of immobilization on capital femoral epiphyseal blood flow. A quantitative study using the hydrogen washout technique. *J Bone Joint Surg Am.* 1978;60:899–904.