



# XEN® implantation: an effective strategy to stop glaucoma progression despite prior minimally invasive glaucoma surgery

Anja-Maria Davids<sup>1</sup> · Milena Pahlitzsch<sup>1</sup> · Eckart Bertelmann<sup>1</sup> · Anna-Karina Maier<sup>1</sup> · Sibylle Winterhalter<sup>1</sup>

Received: 26 May 2022 / Revised: 2 October 2022 / Accepted: 10 October 2022  
© The Author(s), under exclusive licence to Springer-Verlag GmbH Germany, part of Springer Nature 2022

## Abstract

**Purpose** The aim of this study was to evaluate whether XEN® implantation is a reasonable and safe method to lower the intraocular pressure (IOP) and amount of medication for adult primary open-angle glaucoma (POAG) over a 3-year period. The influence of the type of anesthesia, previous glaucoma surgery, and postoperative interventions on the outcome were examined.

**Methods** In this retrospective study, 96 eyes were included. XEN® implantation was performed as sole procedure under general ( $n=86$ ) or local anesthesia ( $n=10$ ). IOP and number of glaucoma medication were assessed preoperatively: day 1, week 6, month 3, 6, 12, 24, and 36. Further outcome parameters were Kaplan–Meier success rates, secondary intervention, and complication rates.

**Results** IOP decreased from  $20.7 \pm 5.1$  to  $12.8 \pm 2.5$  mmHg at the 36-month follow-up ( $p < 0.001$ ) and glaucoma therapy was reduced from  $3.3 \pm 0.8$  to  $1.2 \pm 1.6$  (36 months,  $p < 0.001$ ). Transient postoperative hypotony was documented in 26 eyes (27.1%). General anesthesia resulted in a significant improvement of the survival rate compared to local anesthesia (77% vs. 50%,  $p = 0.044$ ). Prior iStent inject®, Trabectome®, or SLT laser had no significant impact, such as filter bleb revision. The number of postoperative needlings had a significantly negative influence ( $p = 0.012$ ).

**Conclusion** XEN® implantation effectively and significantly lowers the IOP and number of glaucoma therapy in POAG in the 36-month follow-up with a favorable profile of side effects and few complications. In case of IOP, general anesthesia has a significant positive influence on the survival rate, whereas prior SLT or MIGS does not have significant impact.

**Keywords** Glaucoma · XEN® gel implant · POAG · MIGS

## Key messages

- The XEN® implantation is an effective and safe strategy to significantly lower the IOP and number of glaucoma therapy in POAG in the long-term follow-up of 36 months. Additionally, we could demonstrate that prior minimally invasive glaucoma surgery (MIGS) does not have a significant impact on the IOP outcome, whereas general anesthesia has a significant positive influence on the survival rate.

Davids Anja-Maria and Pahlitzsch Milena shared first authorship.

✉ Anja-Maria Davids  
anja.radon@hotmail.de

<sup>1</sup> Department of Ophthalmology, Charité – Universitätsmedizin Berlin, Freie Universität Berlin, Humboldt-Universität Zu Berlin and Berlin Institute of Health, Campus Virchow Klinikum, Augustenburger Platz 1, 13353 Berlin, Germany

## Introduction

Glaucoma is one of the leading causes for irreversible visual impairment worldwide. It is a progressive optic neuropathy associated with characteristic functional visual field loss and structural optic disk damage [1]. An estimated 76 million people worldwide are living with the disease in 2020 and the number is anticipated to increase to 111.8 million by 2040 [2]. Generally, glaucoma is classified based on the

appearance of the draining apparatus (anterior chamber angle) into open-angle and angle closure glaucoma with further subclassification of primary and secondary causes. The most common type is primary open-angle glaucoma (POAG), which accounts for 74% of all cases reported [3]. However, the true number of people with POAG still remains uncertain due to geographical variations in underlying POAG prevalence and geographical representation of surveys to ascertain prevalence as well as differences in study methods of case ascertainment [3].

Glaucoma is multifactorial in origin; however, the only modifiable risk factor is the elevated intraocular pressure (IOP) [4]. It has been shown that lowering IOP by 20–40% can reduce the rate of progressive visual field loss by 50% [5, 6]. Thus, treatments in glaucoma are mainly focused on lowering IOP. The clinical options for reducing IOP are topical/systemic drugs—aiming to increase aqueous humor outflow or to decrease its production—laser therapy that targets the trabecular meshwork and ciliary body, and incisional surgery [7]. The mode and level of treatment are determined by several factors, including glaucoma subtype, estimated life expectancy, prognosis of visual acuity/field, and ocular and systemic comorbidities [8]. In case of open-angle glaucoma (OAG), trabeculectomy is considered to be the standard procedure for lowering IOP [9–12]. This technique creates an alternative route for the *drainage of aqueous humor* from the anterior chamber to the *subconjunctival space*. The long-term success rate has varied from 35 to 97%, depending on the follow-up time, the criteria used to define successful outcome, and the population studied [13–19]. Despite its effectiveness, trabeculectomy is frequently accompanied by short- and long-term complications such as hypotony [20, 21], bleb leaks [22–25], accelerated cataract progression [26], choroidal effusion and hemorrhaging [27], and prolonged or permanent visual impairment due to hypotonic maculopathy [28]. Considering this fact, new novel devices and surgical techniques, described as minimally invasive glaucoma surgery (MIGS), have been developed. In this regard, our department of ophthalmology has already gained valuable experience with iStent inject®, Trabectome®, and canaloplasty ab interno (ABiC) [29–31]. XEN® gel (Allergan Inc., CA, USA) implantation is a further, recently developed alternative filtering glaucoma surgical procedure. The device is a 6-mm hydrophilic tube [32] composed of collagen-derived gelatin cross-linked with glutaraldehyde, which is implanted ab interno through the anterior chamber into the irido-corneal angle to optimize aqueous drainage to the subconjunctival space [33]. Compared to traditional filtering surgeries, XEN® has the potential benefits of increased safety and faster visual recovery due to its minimally invasive approach [34]. XEN® gel implant received a CE mark in 2013 and was approved by the FDA in 2016. The surgery can be performed alone or in combination with a cataract

surgery. Previous studies have highlighted the efficacy and safety of the XEN® gel implantation in decreasing the IOP and medication burden [35–37]. The mean IOP reduction at the 1-year follow-up ranges from 22.7 to 60.4% [38].

In this study, we aim to evaluate the outcome after XEN® gel implantation with respect to the IOP as well as the number of glaucoma medication—and if this outcome can be preserved over a longer period of time. Subsequently, the influence of the type of anesthesia, prior MIGS and postoperative interventions on the outcome, is analyzed.

## Material and methods

This retrospective study is based on the data of 96 eyes of 67 patients (mean age  $69.9 \pm 12.4$  years, range 37–87 years, 47 men, 49 women) with the diagnosis of POAG receiving a XEN® gel implantation in the time period from November 2017 to January 2019. The data were collected in the MIGS database of the department of ophthalmology of the Charité—University Medicine Berlin. The study complied with the ethical standards of the Declaration of Helsinki and followed the regulations of the Good Clinical Practice (GCP) guidelines. The ethics committee of the Charité—University Medicine Berlin has given its approval (EA4/047/20).

## Subjects

Only patients suffering from POAG were included in this study. Consequently, all patients had a sufficiently visible trabecular meshwork, detected by gonioscopy (Shaffer III–IV). Further inclusion criteria were a best-corrected visual acuity of at least 0.1 LogMAR and informed patient consent for surgery. The indication for glaucoma surgery complied with the guidelines of the European glaucoma society (EGS, 5th edition, 2021). The main indication was an IOP above the target pressure, following already exhausted local therapy or it could not be intensified due to allergies. The severity of the glaucoma was determined using the cup to disk ratio (CDR), visual field examination (static perimetry; Aulhorn–Karmeyer staging), and measurement of the retinal nerve fiber layer using optical coherence tomography (average thickness in  $\mu\text{m}$ ; Spectralis OCT, Heidelberg Engineering, Germany). In accordance with the EGS guidelines, the target pressure was defined individually, depending on the severity of the POAG. In most cases, a target pressure below 16 mmHg was ideal.

The exclusion criteria entailed active inflammation in the anterior as well as posterior chamber or corneal infections. Additional criteria for exclusion were also considered in patients who underwent intraocular surgery less than three months before XEN® gel implantation.

Basic data, such as age, gender, glaucoma therapy, best-corrected visual acuity (BCVA), cup to disk ratio (CDR), and lens status, was collected and analyzed. Furthermore, previous laser and glaucoma surgery like selective laser trabeculoplasty (SLT), Trabectome®, or iStent inject® were recorded.

With regard to surgery itself, it was recorded whether the intervention was performed under local anesthesia (peribulbar or local anesthesia) or general anesthesia (intubation anesthesia). The number of glaucoma therapy and the IOP level, recorded by using the Goldmann applanation tonometry, was measured before the surgery and compared with the results after 1 day, 6 weeks (range = 35–49 days), 3 months (range = 77–106 days), 6 months (range = 161–204 days), 12 months (range = 334–387 days), 24 months (range = 670–788 days), and 36 months (range = 1042–1130 days).

As a matter of course, peri- and postoperative complications (postoperative hypotony, IOP spikes, bleeding complications, choroidal effusion or hemorrhage, conjunctival perforation, stent dislocation, infection), postoperative interventions (bleb needling or revisions), and secondary glaucoma surgery (trabeculectomy, Ahmed valve, cyclophotocoagulation) were documented.

## Surgical technique

After informed consent was provided, the surgery was performed by one of two experienced surgeons using the same surgical protocol under local or general anesthesia.

The XEN® gel implantation was performed as a stand-alone procedure. First Suprarenin® (synthetic epinephrine, Sanofi Germany GmbH) was used at the side of XEN® gel implantation to reduce bleeding. Then, a 3-mm limbus distance was marked in this area. After this, 0.1 ml mitomycin C was injected in a concentration of 0.1 mg/ml with a 30-gauge needle and massaged peripheral. Following a 1.8-mm micro-incision, an ophthalmic viscosurgical device was injected into the anterior chamber for stabilization. The XEN® gel microstent is a 6-mm hydrophilic tube [32], which is implanted through the anterior chamber under gonioscopic view into the irido-corneal angle to optimize aqueous drainage to the subconjunctival space. Optimal positioning of the XEN® gel microstent is defined as 1 mm in the anterior chamber, 2 mm in the sclera, and 3 mm below the tenon. After implantation, the position of the XEN® gel microstent was controlled and a primary needling was conducted if the part of the XEN® gel microstent below the tenon was not freely movable. Subsequently, the ophthalmic viscosurgical device was washed out with a balanced salt solution. During this procedure, the filling of the bleb was observed.

Postoperative treatment included a topical combination of steroids and antibiotics that were reduced over 4 to 6 weeks following the surgery.

## Data analysis

The Shapiro–Wilk test and the Levene test were used to evaluate the normal distribution of the variables and the equality of variances. The paired sample *t*-test was performed to compare normally distributed data. In case of not normally distributed variables, non-parametric tests were used: the Wilcoxon test for two dependent variables, the Mann–Whitney–*U* test for two independent variables, the Friedmann test for multiple dependent variables, and the Kruskal–Wallis test for multiple independent variables. As post hoc test, the Bonferroni test was performed. *P*-values lower than 0.05 were determined to be significant. In case of missing data, a pairwise deletion was made. Furthermore, the success rate of the procedure was assessed with the help of the Kaplan–Meier analysis. According to the World Glaucoma Association (WGA) criteria, qualified success was defined as IOP ≤ 18 mmHg and ≥ 20% reduction in IOP with or without medication compared with baseline values. If the target criteria were not reached on two consecutive visits or additional glaucoma surgery (e.g., trabeculectomy, aqueous shunt, cyclophotocoagulation) was necessary, then the surgery is defined as failure [39]. The data analysis was performed with the program SPSS Statistics (Version 23.0 for Mac).

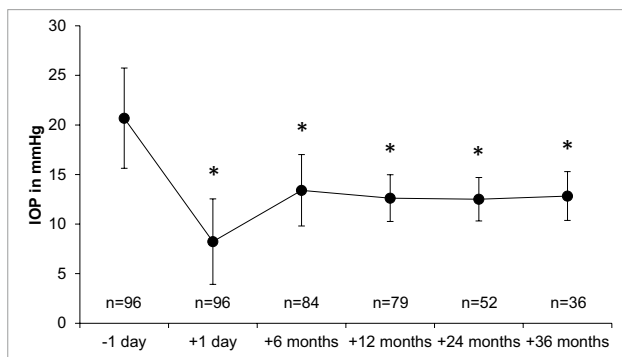
## Results

A total of 96 eyes from 67 patients (mean age  $69.9 \pm 12.4$  years with a range of 37–87 years; 47 men, 49 women) were included in this study. The mean BCVA was  $0.25 \pm 0.27$  LogMAR (range: 0.1–1.3) and the mean CDR was  $0.83 \pm 0.16$  (range: 0.3–0.95). On the Aulhorn–Karmeyer scale, an average value of  $2.83 \pm 1.4$  (range: 1–4) was achieved, whereas the average thickness of the retinal nerve fiber layer was  $62.25 \pm 13.9$  μm (healthy RNFL: > 90 μm).

XEN® gel implantation was performed on phakic eyes in 23 cases of the cohort. A total of 50 eyes had already received minimally invasive glaucoma surgery in the past (SLT: *n* = 18, Trabectome®: *n* = 14, iStent inject®: *n* = 18). General anesthesia was performed on 86 eyes (89.6%) and local anesthesia on 10 eyes (10.4%). After 36 months, 36 eyes were still available for analysis (*n* = 79 after 12 months, *n* = 52 after 24 months). The baseline data of the study cohort is summarized in Table 1.

**Table 1** Baseline descriptive data of the study cohort

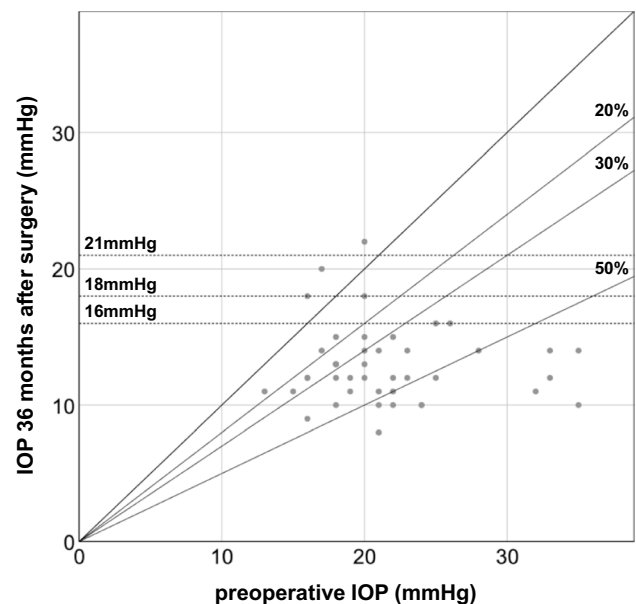
Characteristics	Value	
Number (eyes, right:left)	96 (51:45)	
Gender (female:male)	49 (51%):47 (49%)	
Age (years, mean $\pm$ SD)	69.9 $\pm$ 12.4 (37–87 y)	
Lens status (phacic:pseudophacic)	23 (24%):73 (76%)	
CDR (mean $\pm$ SD)	0.83 $\pm$ 0.16 (0.3–0.95)	
Preoperative IOP (mean $\pm$ SD)	20.68 $\pm$ 5.1	
Preoperative BCVA (mean $\pm$ SD); LogMAR chart	0.25 $\pm$ 0.27	
Preoperative no. of IOP-lowering medication (mean $\pm$ SD)	3.26 $\pm$ 0.84	
Preoperative antiglaucoma procedures	SLT Trabectome iStent Canaloplasty	18 (18.75%) 14 (14.58%) 18 (18.75%) 3 (2.1%)
Type of anesthesia (local:intubation)	10 (10.4%):86 (89.6%)	

**Fig. 1** Change in intraocular pressure (IOP) as a timeline graph after XEN® gel implantation, \* $p < 0.001$ 

### Development of intraocular pressure and glaucoma therapy

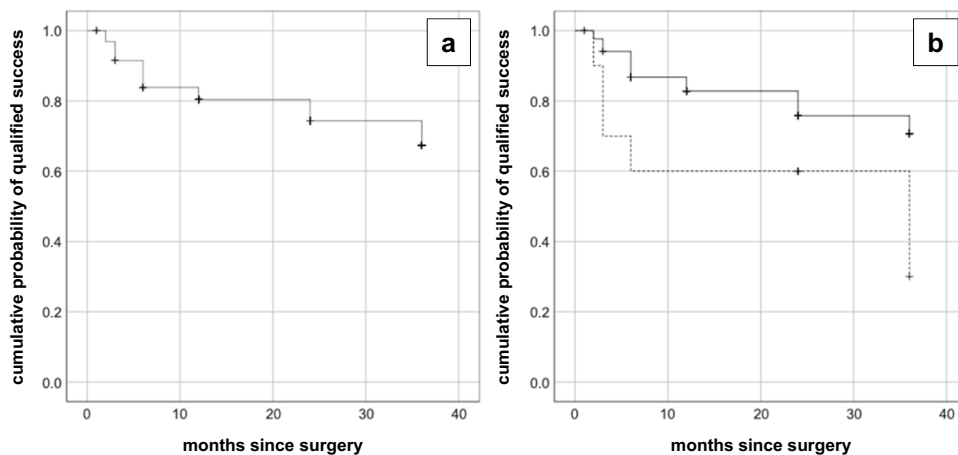
IOP was reduced from preoperative values of  $20.7 \pm 5.1$  to  $12.6 \pm 2.4$  mmHg at the 12 months postoperative follow-up,  $12.5 \pm 2.2$  mmHg at 24 months, and  $12.8 \pm 2.5$  mmHg at 36 months. In Fig. 1, the mean pre- and postoperative IOP level in total is illustrated. It shows a statistically significant decrease of the IOP level during the whole follow-up period (1 day  $p < 0.001$ ; 6 months  $p < 0.001$ ; 12 months  $p < 0.001$ ; 24 months  $p < 0.001$ ; 36 months  $p < 0.001$ ). The scatterplot in Fig. 2 demonstrates the relation between the preoperative IOP and the IOP 36 months after surgery.

Using the definition of success as stated previously, the Kaplan–Meier graph shows an estimated survival rate of 79.2% after 12 months and 74% in total after 36 months (Figs. 3 and 4). The type of anesthesia had a significant influence on the qualified success ( $p = 0.044$ ; after 12 months:  $p = 0.0043$ ). Intubation anesthesia resulted in a significant improvement of the survival rate (77%; after

**Fig. 2** Scatterplot: each point represents one eye showing the preoperative IOP value on the abscissa, and the postoperative IOP values on the ordinate, respectively. The oblique line indicates no change, whether the diagonal lines illustrate the percentage reductions (20%, 30%, and 50%). Different IOP targets (21, 18, and 16 mmHg) are represented by the horizontal lines

12 months: 81%) compared to local anesthesia (50%; after 12 months: 60%).

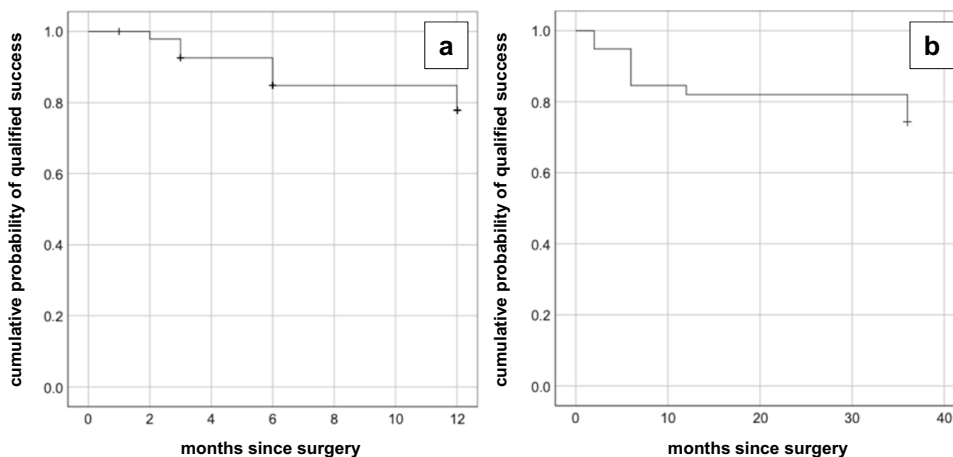
Lens status and preoperative laser such as SLT ( $p \geq 0.05$ ) or glaucoma surgical interventions such as iStent® inject and Trabectome® had no significant influence on the qualified success 12 and 36 months after surgery (respectively  $p \geq 0.05$ ). However, iStent® inject tended to have an unfavorable influence with a survival rate of 67% (Trabectome®: 79%, SLT: 72%) at the 36-month follow-up.



**Fig. 3** Kaplan–Meier graph for the probability of qualified success. **a** All cases in total. **b** intubation anesthesia: solid, black line; local anesthesia: dotted, black line. The endpoints were defined according to the following success criteria: IOP  $\leq 18$  mmHg and  $\geq 20\%$  reduc-

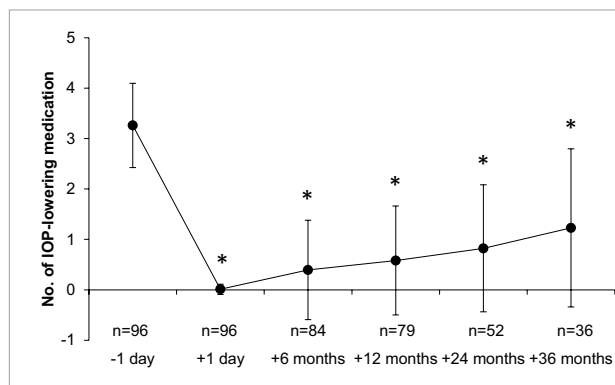
tion in IOP compared with baseline values. Failure was assumed if the target criteria were not reached on 2 consecutive visits. General anesthesia has a significant effect on the qualified success ( $p=0.044$ , Breslow (generalized Wilcoxon))

**Fig. 4** Kaplan–Meier graph for probability of qualified success. **a** All cases in total 12 months following surgery. **b** All cases with complete follow-up until 36 months postoperatively. The endpoints were defined according to the following success criteria: IOP  $\leq 18$  mmHg and  $\geq 20\%$  reduction in IOP compared with baseline values. Failure was assumed if the target criteria were not reached on 2 consecutive visits



In order to support the validity of the entire data despite the high loss to follow-up after 36 months, the data of the patient cohort who participated in all follow-up visits over the course of all 3 years (complete follow-up cohort) was also analyzed in addition to the evaluation of the 1-year data. The corresponding data showed that the results of the entire study cohort did not differ significantly from the results of the complete follow-up cohort after 36 months. The overall survival rate was 74.4%. Intubation anesthesia had a significant positive influence on the survival rate ( $p=0.048$ ), whereas preceded iStent® inject tended to have an unfavorable influence with a survival rate of 62.5% compared to Trabectome® with a survival rate of 80% at the 36-month follow-up.

The number of glaucoma medication changed over time and is illustrated in Fig. 5. Compared to the preoperative value of  $3.3 \pm 0.8$ , it was significantly reduced at each



**Fig. 5** Change in glaucoma medication as a time line graph after XEN® gel implantation,  $*p < 0.001$

examination during the follow-up period. After 12 months, the number of glaucoma medication was  $0.6 \pm 1.1$ , after 24 months  $0.8 \pm 1.3$  and after 36 months  $1.2 \pm 1.6$  (1 day  $p < 0.001$ ; 6 months  $p < 0.001$ ; 12 months  $p < 0.001$ ; 24 months  $p < 0.001$ ; 36 months  $p < 0.001$ ).

## Complications

The most common complication was a transient postoperative hypotony with an IOP  $< 6$  mmHg, which occurred in 26 eyes (27.1%). In case of two subjects (2.1%), Healon® was placed in the anterior chamber for stabilization. Six weeks postoperatively, only two eyes had an IOP of 5 mmHg and at the 3-month follow-up, all eyes had an IOP of 6 mmHg or higher. IOP spikes or bleeding complications such as a significant intraoperative bleeding or postoperative hyphema were not observed. The same applied to choroidal effusion or hemorrhage. The conjunctiva was perforated by the XEN® gel implant in three cases (3.1%), two of whom needed an oral mucosal transplantation. In the further course, one subject developed an endophthalmitis, which was successfully treated with intravitreal injections of antibiotics. Three more subjects (3.1%) experienced a dislocation of the XEN® gel implant into the anterior chamber (Tables 2 and 3).

## Postoperative interventions

In order to support the development of an effective filter bleb or to maintain its functionality, needlings or bleb revisions were carried out in 58 eyes (60.4%) in the further postoperative period. In the case of a needling, adhesions are loosened with a 30-gauge needle or a bleb knife. As part of a

**Table 3** Data of peri- and postoperative complications and subsequent glaucoma interventions

Characteristics	Value	
Transient hypotony	26 (27.1%)	
Conjunctival perforation	3 (3.1%)	
	Oral mucosal transplantation	2 (2.1%)
Dislocation of the XEN® gel implant	3 (3.1%)	
Needlings	53 (55.2%)	
	Once	24 (25%)
	Twice	20 (20.8%)
	Three times	6 (6.2%)
	Four times	3 (3.1%)
Bleb revisions	18 (18.8%)	
Post XEN® gel glaucoma surgery	Total	8 (8.3%)
	CPC	1 (12.5%)
	TE	3 (37.5%)
	Re-XEN	3 (37.5%)
	Ahmed valve	1 (12.5%)

filter bleb revision, the conjunctiva was opened to such an extent that a suture was necessary afterwards. Needling was performed in 53 (55.2%) eyes (once:  $n = 24$ , twice:  $n = 20$ , three times:  $n = 6$ , four times:  $n = 3$ ), a bleb revision was performed in 18 (18.8%) eyes. Table 3 provides an overview of the complications and postoperative interventions.

With the aid of a Kaplan–Maier analysis, we analyzed whether the postoperative IOP, a filter bleb revision and the number of needlings had an influence on the qualified success of an XEN® gel implantation. With regard to the

**Table 2** Drop out data of the study cohort

Characteristics	Value	
No. of needlings	$1.43 \pm 0.79$	
No. of bleb revisions	$0.43 \pm 0.79$	
Post XEN® gel implant interventions	Total	8 (8.3%)
	CPC	1 (12.5%)
	TE	3 (37.5%)
	Re-XEN	3 (37.5%)
	Ahmed valve	1 (12.5%)
Number (eyes, right:left)	8 (6:2)	
Gender (female:male)	3 (37.5%):5 (62.5%)	
Age (years, mean $\pm$ SD)	$70 \pm 14.7$ (47–85 y)	
Lens status (phacic:pseudophacic)	1 (12.5%):7 (87.5%)	
CDR (mean $\pm$ SD)	$0.88 \pm 0.07$ (0.7–0.9)	
Preoperative IOP (mean $\pm$ SD)	$20.63 \pm 7.2$	
Preoperative BCVA (mean $\pm$ SD); LogMAR chart	$0.35 \pm 0.27$	
Preoperative no. of IOP-lowering medication (mean $\pm$ SD)	$3.38 \pm 0.74$	
Preoperative iStent	1 (12.5%)	
Preoperative SLT	3 (37.5%)	

postoperative IOP, it seemed to be that a lower IOP tends to be more favorable regarding the survival rate (81% vs. 71%; after 12 months: 81% vs. 79%; complete follow-up cohort: 83% vs 70%). However, this effect was not significant (respectively  $p > 0.05$ ). A filter bleb revision had no effect (72% vs. 74%; after 12 months: 72% vs 81%; complete follow-up cohort: 71% vs 75%; respectively  $p > 0.05$ ) in this study cohort. The number of postoperative needlings, however, showed a significantly negative influence on the qualified success ( $p = 0.012$ ). The more often a needling had to be performed, the lower the survival rate was (no needling: 88%, one needling: 71%, two needlings: 60%, three needlings: 50%, four needlings: 33%). Comparable results were obtained at the 12-month follow-up (no needling: 93%, one needling: 71%, two needlings: 70%, three needlings: 67%, four needlings: 33%;  $p = 0.018$ ) and with the complete follow-up cohort at the 36-month follow-up (no needling: 86.7%, one needling: 78%, two needlings: 67%, three needlings: 67%, four needlings: 33%;  $p = 0.044$ ). With the aim of maintaining clarity and comprehensibility, only the results of the entire study cohort are listed below or in the discussion.

### Drop out

To date, a subsequent glaucoma surgery was necessary for 8 subjects because the target pressure was not reached or could not be met in the follow-up period (failure rate: 8.3%, mean duration: 10.9 months; range: 3–24 months). In three cases, a trabeculectomy was performed, whereas in one case both a cyclophotocoagulation and an implantation of an Ahmed Valve was carried out. A second XEN® gel implantation was attempted in a further 3 cases. Table 2 displays the characteristics of the dropout cases cohort.

### Discussion

The XEN® gel microstent is an ab interno approach without conjunctival incision, aiming to provide a safer and less invasive IOP-lowering surgery in glaucoma patients compared to traditional filtering surgery.

In the present study, we observed a mean IOP reduction of 40% 36 months after surgery. The number of medications at the 36-month follow-up was reduced by 62% compared to the initial respectively baseline value. Our results 3 years following XEN® gel implantation meet the corresponding data published so far. Furthermore, the results emphasize the conclusion that XEN® gel implantation is an effective procedure for the long-term in lowering the IOP and reducing glaucoma medication. Previous studies on the XEN® gel stent have shown promising results in reducing IOP and medication primarily for patients with primary open-angle

glaucoma in a period of up to 4 years. In a follow-up of 8.5 months, Widder et al. reported a 30% reduction of IOP and a decrease of 92% of glaucoma medication [37]. Several studies published resulted with a follow-up of 12 months, with IOP and medication reduction from 22 to 54% and from 37 to 96% versus the baseline, respectively [35, 40–45]. In addition, S. Grover et al. [46] reported of 75% of patients with  $\geq 20\%$  IOP lowering in combination with 51% reduction of glaucoma medication. Kalina et al. [47] reported of 68% of patients with  $\geq 20\%$  IOP lowering from baseline without medication or any secondary glaucoma intervention. Moreover, the gel implant was effective over 2 years, reducing both IOP and medication needs [48–50], while during the first 3 years, IOP changes between 22 and 19.5% were reported, respectively [51]. After a 4-year follow-up, Lenzhofer et al. showed a postoperative drop in IOP of about 40% [52].

Analyzing to what extent the XEN® gel implantation can be used as part in a gradual therapeutically scheme of glaucoma surgery (e.g., following an iStent® inject implantation), we investigated the influence of previous minimally invasive glaucoma surgical procedures, typically performed at an early stage in glaucoma disease, on the effectiveness of XEN® gel implantation—which is usually carried out in more advanced glaucoma cases. We could not observe any significant influence of preoperative, minimally invasive interventions on the outcome of the XEN® gel implantation. Preoperative glaucoma interventions such as selective laser trabeculoplasty (SLT) laser and MIGS (iStent® inject and Trabectome®) had no significant influence on the qualified success. However, iStent® inject tended to have an unfavorable influence on the qualified success.

In their publication, Lewczuk et al. retrospectively examined the influence of various glaucoma surgical interventions on the outcome two years after XEN® gel implantation [53]. In contrast to our study, however, eyes with different primary and secondary glaucoma diagnoses were included and prior procedures involved mainly trabeculectomy (69%), sclerectomy (55%), and cyclodestructive procedures (41%). The Kaplan–Meier cumulative incidence rate of qualified success (defined as 20% decrease in IOP or IOP 18 mmHg with up to two glaucoma medications) after 24 months was 76.5% for the naïve group and 68.7% for the group with prior glaucoma surgeries. However, there was no significant difference in qualified success between both groups. Although it is not truly comparable to ours, the study of Lewczuk et al. yet indicates that the surgical success rate after XEN® gel implantation as an initial procedure did not differ from that in patients with previous glaucoma surgeries [53]. Consequently, XEN® gel implantation can be considered as an alternative approach in cases of failed previous laser or glaucoma surgical interventions if the conjunctiva scarring is minimal.

With regard to previous MIGS, a publication about the impact of prior Trabectome® surgery on the outcome of XEN® by Kiessling et al. provides a first more differentiated analysis [54]. Even though they included eyes with exfoliative glaucoma in addition to POAG, this study is more comparable to ours. The mean follow-up was  $22 \pm 12$  months and the mean IOP reduction 38% with a postoperative IOP of  $14.5 \pm 5.0$  mmHg and a postoperative medication score of  $0.4 \pm 0.8$ . In total, 42% of their patients underwent an open conjunctival revision surgery and 12% needed a repeated surgery. As conclusion, Kiessling et al. stated that a failed Trabectome® surgery does not affect the postoperative IOP, medication score, revision rate, repeated surgery rate, and success rate of a subsequent XEN® gel implantation [54].

In case of this study, the XEN® gel implantation was carried out as a stand-alone procedure, either in pseudophakic or phakic patients. The lens status did not have a significant influence on the survival rate. In other literature, however, pseudophakic eyes showed a better primary success rate compared to phakic eyes in the XEN® alone group and both in XEN® alone group compared to the combined surgery [37, 49, 55].

Among the documented complications of this study, postoperative ocular hypotension was the most common, with a necessary treatment only being needed in few cases. In general, however, postoperative ocular hypotension seemed to have a favorable, but not significant, effect on the success rate.

Furthermore, documented complications after XEN® implant included XEN dislocation into the anterior chamber and perforation of the conjunctiva. As also found in other literature, a low rate of intra- or postoperative complications or unexpected postoperative ocular adverse events were reported using XEN® gel stent minimal surgery [37, 46, 56], not considering needling of a scarring filtering bleb as a complication. Galal et al. [40] reported one case of a dislocated stent; the situation was managed by applying conjunctival sutures and relocation of the implant in the subconjunctival space. Widder et al. estimated that 34% of patients that could not achieve an adequate IOP without postoperative medication required revisional surgery defined as removal of scar tissue [37].

In case of scarring, depending on the extent, needling and open revision of the filtering bleb have been established as an effective part of the follow-up treatment. In our study cohort, 60.4% of the eyes required at least one further intervention in the area of the filtering bleb in order to maintain the target pressure. A higher needling rate, resulted in a lower success rate, whereas filter pad revisions had no negative effect. Our results are in line with the findings in literature. Steiner et al. published an interesting analysis regarding needling and open filtering bleb revision after XEN® gel implantation [57]. Comparable to our

study, they reported as well transient hypotension in 30.2% of the eyes after primary surgery, which lasted longer than 30 days in 4 patients. In addition, a total of 49.6% of the eyes required at least one postoperative secondary intervention. In summary, their data appear to indicate that open filtering bleb revision might have beneficial outcomes in terms of Kaplan–Meier success rates, and the reintervention rate compared to the needling procedure [57].

The effect of local anesthetic regimens on the increase of IOP—being that local anesthesia is the commonly chosen procedure for glaucoma surgeries—is still part of recent research [58, 59]. Studies showed IOP values did not differ between peribulbar and retrobulbar anesthesia [59] or between topical and retrobulbar [60], and no significant differences were found in terms of pain or supplemental anesthesia requirement under topical or retrobulbar anesthesia [60, 61]. In case of this study, we compared the effect of general and local anesthesia on the outcome. As result, there was a significant and positive influence of general anesthesia on the survival rate (77% vs. 50%,  $p = 0.44$ ), which corresponds to the available literature. Gedar et al. found that general anesthesia may have advantages for glaucoma surgery in terms of (i) relaxation of the patient; (ii) more control of the IOP; and (iii) fixation of the operated eye [62].

Our study has a number of limitations which have to be addressed. The main study limitation is the retrospective design including real-life clinical data with the data variability across the different follow-ups. This may increase a possible bias of the study. The effects of the Covid-19 pandemic are also not negligible. Some patients failed to attend the follow-up visits, due to national health system rules to reduce the risk of infection. Furthermore, due to emergency surgeries, non-urgent appointments were canceled and the further postoperative control was delegated to the outpatient departments. In line with the above mentioned, one more limitation is the small number of patients obtained who received local anesthesia.

To conclude, the XEN® gel stent appears to be effective for reducing IOP and the number of glaucoma medications in POAG despite prior MIGS. Even so, controlled follow-up and evaluation of the indication for subsequent interventions such as needling and open filtering bleb revision are advised after surgery [55]. It offers an effective and safe approach as a sole procedure in POAG in the context of a gradual therapeutically scheme of glaucoma surgery.

## Declarations

**Ethical Approval** The study complied with the ethical standards of the 1964 Helsinki declaration and its later amendments and followed the regulations of the Good Clinical Practice (GCP) guidelines. Furthermore, the ethics committee of the Charité—University Medicine Berlin



has given its approval (EA4/047/20). Informed consent was obtained from all individual participants included in the study.

**Conflict of interest** The authors declare no competing interests.

## References

1. Werkmeister RM, Cherecheanu AP, Garhofer G, Schmidl D, Schmetterer L (2013) Imaging of retinal ganglion cells in glaucoma: pitfalls and challenges. *Cell Tissue Res* 353:261–268. <https://doi.org/10.1007/s00441-013-1600-3>
2. Tham YC, Li X, Wong TY, Quigley HA, Aung T, Cheng CY (2014) Global prevalence of glaucoma and projections of glaucoma burden through 2040: a systematic review and meta-analysis. *Ophthalmology* 121:2081–2090. <https://doi.org/10.1016/j.ophtha.2014.05.013>
3. Kapetanakis VV, Chan MP, Foster PJ, Cook DG, Owen CG, Rudnicka AR (2016) Global variations and time trends in the prevalence of primary open angle glaucoma (POAG): a systematic review and meta-analysis. *Br J Ophthalmol* 100:86–93. <https://doi.org/10.1136/bjophthalmol-2015-307223>
4. Coleman AL, Kodjebacheva G (2009) Risk factors for glaucoma needing more attention. *Open Ophthalmol J* 3:38–42. <https://doi.org/10.2174/1874364100903020038>
5. Heijl A, Bengtsson B, Hyman L, Leske MC, Early Manifest Glaucoma Trial G (2009) Natural history of open-angle glaucoma. *Ophthalmology* 116:2271–2276. <https://doi.org/10.1016/j.ophtha.2009.06.042>
6. Quigley HA (2011) Glaucoma *Lancet* 377:1367–1377. [https://doi.org/10.1016/S0140-6736\(10\)61423-7](https://doi.org/10.1016/S0140-6736(10)61423-7)
7. Crawley L, Zamir SM, Cordeiro MF, Guo L (2012) Clinical options for the reduction of elevated intraocular pressure. *Ophthalmol Eye Dis* 4:43–64. <https://doi.org/10.4137/OED.S4909>
8. Lusthaus J, Goldberg I (2019) Current management of glaucoma. *Med J Aust* 210:180–187. <https://doi.org/10.5694/mja2.50020>
9. Arora KS, Robin AL, Corcoran KJ, Corcoran SL, Ramulu PY (2015) Use of various glaucoma surgeries and procedures in Medicare beneficiaries from 1994 to 2012. *Ophthalmology* 122:1615–1624. <https://doi.org/10.1016/j.ophtha.2015.04.015>
10. Cairns JE (1968) Trabeculectomy. Preliminary report of a new method. *Am J Ophthalmol* 66:673–679
11. Spaeth GL, Joseph NH, Fernandes E (1975) Trabeculectomy: a reevaluation after three years and a comparison with Scheie's procedure. *Trans Sect Ophthalmol Am Acad Ophthalmol Otolaryngol* 79:OP349-361
12. Watson PG (1981) Trabeculectomy. *Dev Ophthalmol* 1:61–70
13. Bevin TH, Molteno AC, Herbison P (2008) Otago Glaucoma Surgery Outcome Study: long-term results of 841 trabeculectomies. *Clin Exp Ophthalmol* 36:731–737. <https://doi.org/10.1111/j.1442-9071.2008.01896.x>
14. Diestelhorst M, Khalili MA, Krieglstein GK (1998) Trabeculectomy: a retrospective follow-up of 700 eyes. *Int Ophthalmol* 22:211–220. <https://doi.org/10.1023/a:1006238624072>
15. Ehrnrooth P, Lehto I, Puska P, Laatikainen L (2002) Long-term outcome of trabeculectomy in terms of intraocular pressure. *Acta Ophthalmol Scand* 80:267–271. <https://doi.org/10.1034/j.1600-0420.2002.800307.x>
16. Jampel HD, Solus JF, Tracey PA, Gilbert DL, Loyd TL, Jefferys JL, Quigley HA (2012) Outcomes and bleb-related complications of trabeculectomy. *Ophthalmology* 119:712–722. <https://doi.org/10.1016/j.ophtha.2011.09.049>
17. Landers J, Martin K, Sarkies N, Bourne R, Watson P (2012) A twenty-year follow-up study of trabeculectomy: risk factors and outcomes. *Ophthalmology* 119:694–702. <https://doi.org/10.1016/j.ophtha.2011.09.043>
18. Molteno AC, Bosma NJ, Kittelson JM (1999) Otago glaucoma surgery outcome study: long-term results of trabeculectomy—1976 to 1995. *Ophthalmology* 106:1742–1750. [https://doi.org/10.1016/S0161-6420\(99\)90351-2](https://doi.org/10.1016/S0161-6420(99)90351-2)
19. Robinson DI, Lertsmitkul S, Billson FA, Robinson LP (1993) Long-term intraocular pressure control by trabeculectomy: a ten-year life table. *Aust N Z J Ophthalmol* 21:79–85. <https://doi.org/10.1111/j.1442-9071.1993.tb00758.x>
20. Azuara-Blanco A, Katz LJ (1998) Dysfunctional filtering blebs. *Surv Ophthalmol* 43:93–126. [https://doi.org/10.1016/s0039-6257\(98\)00025-3](https://doi.org/10.1016/s0039-6257(98)00025-3)
21. Burney EN, Quigley HA, Robin AL (1987) Hypotony and choroidal detachment as late complications of trabeculectomy. *Am J Ophthalmol* 103:685–688. [https://doi.org/10.1016/s0002-9394\(14\)74330-2](https://doi.org/10.1016/s0002-9394(14)74330-2)
22. (1989) Fluorouracil Filtering Surgery Study one-year follow-up. The Fluorouracil Filtering Surgery Study Group. *Am J Ophthalmol* 108: 625–635 [https://doi.org/10.1016/0002-9394\(89\)90853-2](https://doi.org/10.1016/0002-9394(89)90853-2)
23. Belyea DA, Dan JA, Stamer RL, Lieberman MF, Spencer WH (1997) Late onset of sequential multifocal bleb leaks after glaucoma filtration surgery with 5-fluorouracil and mitomycin C. *Am J Ophthalmol* 124:40–45. [https://doi.org/10.1016/s0002-9394\(14\)71642-3](https://doi.org/10.1016/s0002-9394(14)71642-3)
24. Greenfield DS, Liebmann JM, Jee J, Ritch R (1998) Late-onset bleb leaks after glaucoma filtering surgery. *Arch Ophthalmol* 116:443–447. <https://doi.org/10.1001/archophth.116.4.443>
25. Singh J, O'Brien C, Chawla HB (1995) Success rate and complications of intraoperative 0.2 mg/ml mitomycin C in trabeculectomy surgery. *Eye (Lond)* 9(Pt 4):460–466. <https://doi.org/10.1038/eye.1995.107>
26. Feiner L, Piltz-Seymour JR, Collaborative Initial Glaucoma Treatment S (2003) Collaborative Initial Glaucoma Treatment Study: a summary of results to date. *Curr Opin Ophthalmol* 14:106–111. <https://doi.org/10.1097/00055735-200304000-00010>
27. Edmunds B, Thompson JR, Salmon JF, Wormald RP (2002) The National Survey of Trabeculectomy. III Early and late complications *Eye (Lond)* 16:297–303. <https://doi.org/10.1038/sj.eye.6700148>
28. Jampel HD, Pasquale LR, Dibernardo C (1992) Hypotony maculopathy following trabeculectomy with mitomycin C. *Arch Ophthalmol* 110:1049–1050. <https://doi.org/10.1001/archophth.1992.01080200029011>
29. Davids AM, Pahlitzsch M, Boeker A, Winterhalter S, Maier-Wenzel AK, Klamann M (2019) Ab interno canaloplasty (ABiC)-12-month results of a new minimally invasive glaucoma surgery (MIGS). *Graefes Arch Clin Exp Ophthalmol* 257:1947–1953. <https://doi.org/10.1007/s00417-019-04366-3>
30. Pahlitzsch M, Davids AM, Winterhalter S, Zorn M, Reitemeyer E, Klamann MKJ, Torun N, Bertelmann E, Maier AK (2021) Selective laser trabeculoplasty versus MIGS: forgotten art or first-step procedure in selected patients with open-angle glaucoma. *Ophthalmol Ther* 10:509–524. <https://doi.org/10.1007/s40123-021-00347-0>
31. Pahlitzsch M, Davids AM, Zorn M, Torun N, Winterhalter S, Maier AB, Klamann MK, Bertelmann E (2018) Three-year results of ab interno trabeculectomy (Trabectome): Berlin study group. *Graefes Arch Clin Exp Ophthalmol* 256:611–619. <https://doi.org/10.1007/s00417-017-3882-8>
32. Richter GM, Coleman AL (2016) Minimally invasive glaucoma surgery: current status and future prospects. *Clin Ophthalmol* 10:189–206. <https://doi.org/10.2147/OPTh.S80490>
33. Buffault J, Graber M, Bensmail D, Bluwol E, Jeanteur MN, Abitbol O, Benhatchi N, Sauvan L, Lachkar Y (2020) Efficacy and safety at 6 months of the XEN implant for the management of

- open angle glaucoma. *Sci Rep* 10:4527. <https://doi.org/10.1038/s41598-020-61319-1>
34. Samples JR, Ahmed IIK (2020) Current developments in glaucoma surgery and MIGS. Kugler Publications, Amsterdam
  35. Fea AM, Bron AM, Economou MA, Laffi G, Martini E, Figus M, Oddone F (2020) European study of the efficacy of a cross-linked gel stent for the treatment of glaucoma. *J Cataract Refract Surg* 46:441–450. <https://doi.org/10.1097/j.jcrs.0000000000000065>
  36. Hu JY, Ang BCH, Yip LW (2020) Efficacy of the XEN gel stent on intraocular pressure lowering in East Asian eyes. *Int Ophthalmol* 40:1191–1199. <https://doi.org/10.1007/s10792-020-01284-w>
  37. Widder RA, Dietlein TS, Dinslage S, Kuhnrich P, Rennings C, Rossler G (2018) The XEN45 Gel Stent as a minimally invasive procedure in glaucoma surgery: success rates, risk profile, and rates of re-surgery after 261 surgeries. *Graefes Arch Clin Exp Ophthalmol* 256:765–771. <https://doi.org/10.1007/s00417-018-3899-7>
  38. Linton E, Au L (2020) Technique of Xen implant revision surgery and the surgical outcomes: a retrospective interventional case series. *Ophthalmol Ther* 9:149–157. <https://doi.org/10.1007/s40123-020-00234-0>
  39. Shaarawy TGF, Sherwood M, World Glaucoma Association (2009) WGA guidelines on design and reporting of glaucoma surgical trials. Kugler Publications, The Hague
  40. Galal A, Bilgic A, Eltanamly R, Osman A (2017) XEN glaucoma implant with mitomycin C 1-year follow-up: result and complications. *J Ophthalmol* 2017:5457246. <https://doi.org/10.1155/2017/5457246>
  41. Heidinger A, Schwab C, Lindner E, Riedl R, Mossbock G (2019) A retrospective study of 199 Xen45 stent implantations from 2014 to 2016. *J Glaucoma* 28:75–79. <https://doi.org/10.1097/IJG.0000000000001122>
  42. Hengerer FH, Kohlen T, Mueller M, Conrad-Hengerer I (2017) Ab interno gel implant for the treatment of glaucoma patients with or without prior glaucoma surgery: 1-year results. *J Glaucoma* 26:1130–1136. <https://doi.org/10.1097/IJG.0000000000000803>
  43. Karimi A, Lindfield D, Turnbull A, Dimitriou C, Bhatia B, Radwan M, Gouws P, Hanifudin A, Amerasinghe N, Jacob A (2019) A multi-centre interventional case series of 259 ab-interno Xen gel implants for glaucoma, with and without combined cataract surgery. *Eye (Lond)* 33:469–477. <https://doi.org/10.1038/s41433-018-0243-8>
  44. Ozal SA, Kaplaner O, Basar BB, Guclu H, Ozal E (2017) An innovation in glaucoma surgery: XEN45 gel stent implantation. *Arq Bras Oftalmol* 80:382–385. <https://doi.org/10.5935/0004-2749.20170093>
  45. Tan NE, Tracer N, Terraciano A, Parikh HA, Panarelli JF, Radcliffe NM (2021) Comparison of safety and efficacy between ab interno and ab externo approaches to XEN gel stent placement. *Clin Ophthalmol* 15:299–305. <https://doi.org/10.2147/OPHTH.S292007>
  46. Grover DS, Flynn WJ, Bashford KP, Lewis RA, Duh YJ, Nangia RS, Niksch B (2017) Performance and safety of a new ab interno gelatin stent in refractory glaucoma at 12 months. *Am J Ophthalmol* 183:25–36. <https://doi.org/10.1016/j.ajo.2017.07.023>
  47. Kalina AG, Kalina PH, Brown MM (2019) XEN(R) Gel stent in medically refractory open-angle glaucoma: results and observations after one year of use in the United States. *Ophthalmol Ther* 8:435–446. <https://doi.org/10.1007/s40123-019-0192-8>
  48. Gabbay IE, Allen F, Morley C, Pearsall T, Bowes OM, Ruben S (2020) Efficacy and safety data for the XEN45 implant at 2 years: a retrospective analysis. *Br J Ophthalmol* 104:1125–1130. <https://doi.org/10.1136/bjophthalmol-2019-313870>
  49. Mansouri K, Guidotti J, Rao HL, Ouabas A, D'Alessandro E, Roy S, Mermoud A (2018) Prospective evaluation of standalone XEN gel implant and combined phacoemulsification-XEN gel implant surgery: 1-year results. *J Glaucoma* 27:140–147. <https://doi.org/10.1097/IJG.0000000000000858>
  50. Reitsamer H, Vera V, Ruben S, Au L, Vila-Arteaga J, Teus M, Lenzhofer M, Shirlaw A, Bai Z, Balaram M, Stalmans I (2021) Three-year effectiveness and safety of the XEN gel stent as a solo procedure or in combination with phacoemulsification in open-angle glaucoma: a multicentre study. *Acta Ophthalmol*. <https://doi.org/10.1111/aos.14886>
  51. Fernandez-Garcia A, Zhou Y, Garcia-Alonso M, Andrango HD, Poyales F, Garzon N (2020) Comparing medium-term clinical outcomes following XEN(R) 45 and XEN(R) 63 device implantation. *J Ophthalmol* 2020:4796548. <https://doi.org/10.1155/2020/4796548>
  52. Lenzhofer M, Kersten-Gomez I, Sheybani A, Gulamhusein H, Strohmaier C, Hohensinn M, Burkhard Dick H, Hitzl W, Eisenkopf L, Sedarous F, Ahmed II, Reitsamer HA (2019) Four-year results of a minimally invasive transscleral glaucoma gel stent implantation in a prospective multi-centre study. *Clin Exp Ophthalmol* 47:581–587. <https://doi.org/10.1111/ceo.13463>
  53. Lewczuk K, Konopinska J, Jablonska J, Rudowicz J, Laszewicz P, Dmuchowska DA, Mariak Z, Rekas M (2021) XEN glaucoma implant for the management of glaucoma in naive patients versus patients with previous glaucoma surgery. *J Clin Med* 10. <https://doi.org/10.3390/jcm10194417>
  54. Kiessler D, Rennings C, Hild M, Lappas A, Dietlein TS, Roessler GF, Widder RA (2021) Impact of failed ab-interno trabeculectomy (trabectome) on subsequent XEN45 gel stent implantation in pseudophakic eyes. *Int Ophthalmol* 41:4047–4053. <https://doi.org/10.1007/s10792-021-01977-w>
  55. Buffault J, Baudouin C, Labbe A (2019) XEN(R) Gel Stent for management of chronic open angle glaucoma: a review of the literature. *J Fr Ophthalmol* 42:e37–e46. <https://doi.org/10.1016/j.jfo.2018.12.002>
  56. Hohberger B, Welge-Lussen UC, Lammer R (2018) MIGS: therapeutic success of combined Xen gel stent implantation with cataract surgery. *Graefes Arch Clin Exp Ophthalmol* 256:621–625. <https://doi.org/10.1007/s00417-017-3895-3>
  57. Steiner S, Resch H, Kiss B, Buda D, Vass C (2021) Needling and open filtering bleb revision after XEN-45 implantation—a retrospective outcome comparison. *Graefes Arch Clin Exp Ophthalmol* 259:2761–2770. <https://doi.org/10.1007/s00417-021-05204-1>
  58. Gofman N, Cohen B, Matot I, Cattan A, Dotan G, Stolovitch C, Ela-Dalman N (2017) Do intraocular pressure measurements under anesthesia reflect the awake condition? *J Glaucoma* 26:299–302. <https://doi.org/10.1097/IJG.0000000000000355>
  59. O'Donoghue E, Batterbury M, Lavy T (1994) Effect on intraocular pressure of local anaesthesia in eyes undergoing intraocular surgery. *Br J Ophthalmol* 78:605–607. <https://doi.org/10.1136/bjo.78.8.605>
  60. Sauder G, Jonas JB (2002) Topical anesthesia for penetrating trabeculectomy. *Graefes Arch Clin Exp Ophthalmol* 240:739–742. <https://doi.org/10.1007/s00417-002-0464-0>
  61. Ahmed II, Zabriskie NA, Crandall AS, Burns TA, Alder SC, Patel BC (2002) Topical versus retrobulbar anesthesia for combined phacotrabeculectomy: prospective randomized study. *J Cataract Refract Surg* 28:631–638. [https://doi.org/10.1016/s0886-3350\(01\)01249-4](https://doi.org/10.1016/s0886-3350(01)01249-4)
  62. Özgün Melike Totuk Gedar DEA, Ümit Aykan (2016) Anesthetic management in glaucoma surgery. *ARC Journal of Anesthesiology* 1: 9-18

**Publisher's note** Springer Nature remains neutral with regard to jurisdictional claims in published maps and institutional affiliations.

Springer Nature or its licensor (e.g. a society or other partner) holds exclusive rights to this article under a publishing agreement with the author(s) or other rightsholder(s); author self-archiving of the accepted manuscript version of this article is solely governed by the terms of such publishing agreement and applicable law.