



# Surgical management of National Institutes of Health category II chronic bacterial prostatitis: a case series and scoping review of the literature

Peace U. Orji<sup>1^</sup>, Prajit Khooblal<sup>2</sup>, Jonathan Doolittle<sup>3</sup>, Scott D. Lundy<sup>2</sup>, Daniel Shoskes<sup>2</sup>

<sup>1</sup>Case Western Reserve University School of Medicine, Cleveland, OH, USA; <sup>2</sup>Cleveland Clinic Glickman Urological and Kidney Institute, Cleveland, OH, USA; <sup>3</sup>Oklahoma Department of Urology, University of Oklahoma, Oklahoma City, OK, USA

**Contributions:** (I) Conception and design: D Shoskes, SD Lundy; (II) Administrative support: PU Orji; (III) Provision of study materials or patients: D Shoskes, J Doolittle; (IV) Collection and assembly of data: D Shoskes, SD Lundy; (V) Data analysis and interpretation: PU Orji, P Khooblal, SD Lundy; (VI) Manuscript writing: All authors; (VII) Final approval of manuscript: All authors.

**Correspondence to:** Scott D. Lundy, MD, PhD. Cleveland Clinic Glickman Urological and Kidney Institute, 9500 Euclid Avenue, Cleveland, OH 44195, USA. Email: LUNDYS@ccf.org.

**Background:** National Institutes of Health (NIH) category II prostatitis refractory to antibiotic therapy can be challenging to treat. We present the outcomes from a case series of men who have undergone various surgical therapies to treat this condition. Additionally, we performed a scoping review of studies describing the characteristics and outcomes of patients surgically treated for chronic bacterial prostatitis (CBP).

**Methods:** This is a single-center retrospective case series of adult patients at Cleveland Clinic Glickman Urological and Kidney Institute with refractory NIH category II prostatitis managed with surgical intervention. PubMed was queried and all resulting articles were analyzed for relevance and parallel study designs.

**Results:** Twelve subjects underwent endoscopic procedures. Two of 12 (16.7%) subjects had CBP recurrence with *E. Coli* at 12 and 60 months; both patients initially had prostatic stones. One patient with CBP recurrence developed a urethral stricture. Seven subjects were treated with nerve-sparing robotic radical prostatectomy of whom two had concomitant prostate cancer. Three subjects had prostate stones, two of which extended beyond the surgical capsule. *E. coli* was the isolated pathogen for six patients with two of these being multi-drug resistant (MDR) *E. coli*. One patient in this group experienced recurrent urinary tract infections (UTIs) despite the surgery. Scoping review of available articles consistently failed to mention definitive diagnosis of CBP with prostatic secretion cultures or even urine cultures prior to surgical intervention and no studies were found on the curative outcomes of surgical intervention.

**Conclusions:** Our study provides one of the first single-center retrospective case series of patients with antibiotic refractory NIH category II CBP managed with surgical intervention. Overall, rate of cure between all surgical modalities was 84% (n=16). When disease is confined to the surgical capsule, endoscopic management is likely sufficient. Radical prostatectomy expectedly increased rates of postoperative erectile dysfunction and stress urinary incontinence compared to endoscopic intervention. However, in patients with disease beyond the capsule and/or concomitant prostate cancer, prior endoscopic treatment, or life-threatening UTI, radical prostatectomy may be justified.

**Keywords:** Chronic bacterial prostatitis (CBP); prostatitis; endoscopy; scoping review

Submitted Mar 09, 2023. Accepted for publication Sep 27, 2023. Published online Oct 24, 2023.

doi: 10.21037/tau-23-142

**View this article at:** <https://dx.doi.org/10.21037/tau-23-142>

<sup>^</sup> ORCID: 0000-0002-9931-117X.

## Introduction

### Background

Prostatitis is a generic term referring to several distinct syndromes with different etiologies. The National Institutes of Health (NIH) classification scheme describes four categories of prostatitis including: acute bacterial prostatitis (ABP) (category I), chronic bacterial prostatitis (CBP) (category II), chronic prostatitis/chronic pelvic pain syndrome (category III) and asymptomatic inflammatory prostatitis (AIP) (category IV) (1). Category II presents as recurrent urinary tract infections (UTIs), caused by the same bacterial strain which can be recovered from the prostate between symptomatic infections (2).

### Rationale and knowledge gap

Some patients can be managed medically with antibiotic therapy and/or alpha blockade. However, there is a subset of patients with disease refractory to conservative management and thus may be eligible for surgical intervention. These patients must be carefully selected as there is no evidence to justify surgery is appropriate for categories III or IV (3). If the infection is due to incomplete bladder emptying from benign prostatic hyperplasia (BPH), then relief of obstruction is the goal. If the infection is due to a nidus within the prostate, often within prostatic

calcifications, then the infected tissue must be completely removed. If all stones are within the surgical capsule, then a BPH procedure is acceptable but otherwise, the entire prostate would need removal. The literature has described transurethral resection of the prostate (TURP), laser therapy, holmium laser enucleation of the prostate, and robotic radical prostatectomy as viable treatment options (1-8). There has not been any case series describing the outcomes of men who have undergone surgical intervention for CBP.

### Objective

The purpose of this case series is to present outcomes of patients who have undergone various surgical therapies to treat CBP. Secondly, we provide a review of the current literature concerning surgical management of NIH category II prostatitis. We present this article in accordance with the PRISMA-ScR reporting checklist (available at <https://tau.amegroups.com/article/view/10.21037/tau-23-142/rc>).

## Methods

### Case series

This is a single-center retrospective case series of men seen at Cleveland Clinic Glickman Urological and Kidney Institute for the diagnosis of refractory NIH category II CBP and managed with surgical intervention. All surgeries were performed by a single surgeon. Diagnosis of CBP was established based on the presence of recurrent culture-proven UTI, prostatic secretion infections, and documentation of negative urine cultures in the asymptomatic period if possible. All patients came to our tertiary referral center with extensive histories of multiple antibiotic courses. Outside records were used to confirm this. Cure was defined as lack of recurrence of infection after surgical treatment. Only patients who underwent surgery were included; patients who received a diagnosis of chronic prostatitis incidentally after surgical treatment of BPH were excluded from this study. In the perioperative period, baseline cefazolin was used on induction. An additional antibiotic was included based on each patient's prior culture history; this was typically an aminoglycoside or a quinolone. Antibiotics were continued orally for at least 2 weeks beyond the perioperative period for patient who were already on long-term low dose therapy. Relevant patient history, perioperative details, and outcomes were

### Highlight box

#### Key findings

- Endoscopic management is likely appropriate for chronic bacterial prostatitis when the source of infection confined within the surgical capsule of the prostate.
- Radical prostatectomy may be appropriate in patients with chronic bacterial prostatitis (CBP) beyond the surgical capsule and/or prostate cancer, prior endoscopic treatment, or life-threatening urinary tract infections.

#### What is known and what is new?

- Surgery is a viable treatment option for National Institutes of Health (NIH) category II chronic bacterial prostatitis.
- Our study provides one of the first single-center retrospective case series of patients with antibiotic refractory NIH category II CBP managed with surgical intervention.

#### What is the implication, and what should change now?

- When recurrent infections persist and there is evidence for incomplete emptying or an infected nidus of stones within the prostate, surgical management can be curative.

obtained from the electronic medical record. The study was conducted in accordance with the Declaration of Helsinki (as revised in 2013). The study was approved by the institutional review board of the Cleveland Clinic (IRB No. 21-462). Informed consent was not required from patients included in this study as it was a retrospective study with participants from various states/countries. Prostatic stones were identified by transrectal ultrasound (TRUS) and/or computed tomography scan (CT scan). Although most patients arrived with outside CT scans, TRUS was always performed on-site to assess for presence of stones and whether stones were completely contained within the surgical capsule. Normally distributed values were reported as mean  $\pm$  standard deviation and nonparametric values were reported as median (interquartile range).

### Scoping review

PubMed was queried with the following searches: “chronic bacterial prostatitis” OR (“category ii”[All Fields] OR “category 2”[All Fields]) AND prostatitis) OR “bacterial chronic prostatitis” OR “ii prostatitis” OR (chronic[ti] (bacteri\*[ti] NOT non-bacteri\*[ti]) prostatitis[ti]) AND “Prostatectomy”[Mesh] OR prostatectom\* OR (“prostate gland” remov\*) AND holmium laser OR HoLEP OR (Laser Therapy[MeSH] AND Holium[MeSH]) AND (transurethral resection\*) OR TURP OR Transurethral Resection of Prostate[MeSH]. Additional articles were obtained by reviewing the references of relevant manuscripts. Date restrictions were not placed on the search. Exclusion criteria included: lack of relevancy to the present study, manuscripts in languages other than English, retracted and duplicate articles. The data were reviewed independently by two members of the research team, with a third member available for any discordant findings. The data were organized into a narrative summary for further discussion. Variables sought included: prostatitis classification, definitive diagnosis of CBP, outcomes, and complications, and time to follow-up.

## Results

### Endoscopic management

Twelve patients underwent endoscopic procedures intended to remove the source of infection. The mean age of patients in this subgroup was 71 years with a mean prostate volume of 50 cc. There were no acute infections

in the post-operative period. Six of the 12 patients in this subgroup had prostatic stones. 2 of the 12 (16.7%) patients had CBP recurrence following surgery with *E. Coli* at 12 and 60 months; both patients initially had prostatic stones. One of these patients with CBP recurrence developed a urethral stricture following laser therapy. Individual patient follow-up outcomes, endoscopic procedure, and clinical characteristics are listed in *Table 1*.

### Robotic total prostatectomy

Seven patients were treated with nerve-sparing robotic total prostatectomy for suspected source of infection outside of the surgical capsule. Median age of this subset was 67 years with a mean prostate volume of 31.2 cc. There were no acute infections in the post-operative period. Three of seven (43%) patients in this group had previously undergone TURP with life-threatening UTIs isolated to the prostate before robotic prostatectomy. Two patients in this subgroup had concomitant Gleason score six prostate cancer and one patient had Gleason score seven prostate cancer, diagnosed on prior prostate biopsy. Three patients had prostate stones, two of which had prostatic stones that extended beyond the surgical capsule. All subjects were diagnosed with CBP; two of the seven patients had a history of NIH category I prostatitis. *E. coli* was the isolated pathogen for six patients with two of these being MDR *E. coli*. *Serratia* and vancomycin resistant enterococcus (VRE) were each isolated in one subject, respectively.

Postoperatively, one patient (14.3%) experienced recurrent UTIs. While 6 of 7 patients in this subgroup were cured of CBP, one patient reported erectile dysfunction. One patient with Gleason six prostate cancer reported stress urinary incontinence at 72 months follow-up. Another patient with Gleason seven prostate cancer reported stress urinary incontinence at 84 weeks follow-up. Clinical characteristics of the patients, outcomes, and complications are detailed in *Table 1*.

### Scoping review

After conducting a comprehensive scoping review of available articles, it became evident that the majority of existing literature regarding CBP focuses on medical management of the condition. The literature screening strategy is depicted in *Figure 1*. Despite studies stating patients were diagnosed with CBP, the literature

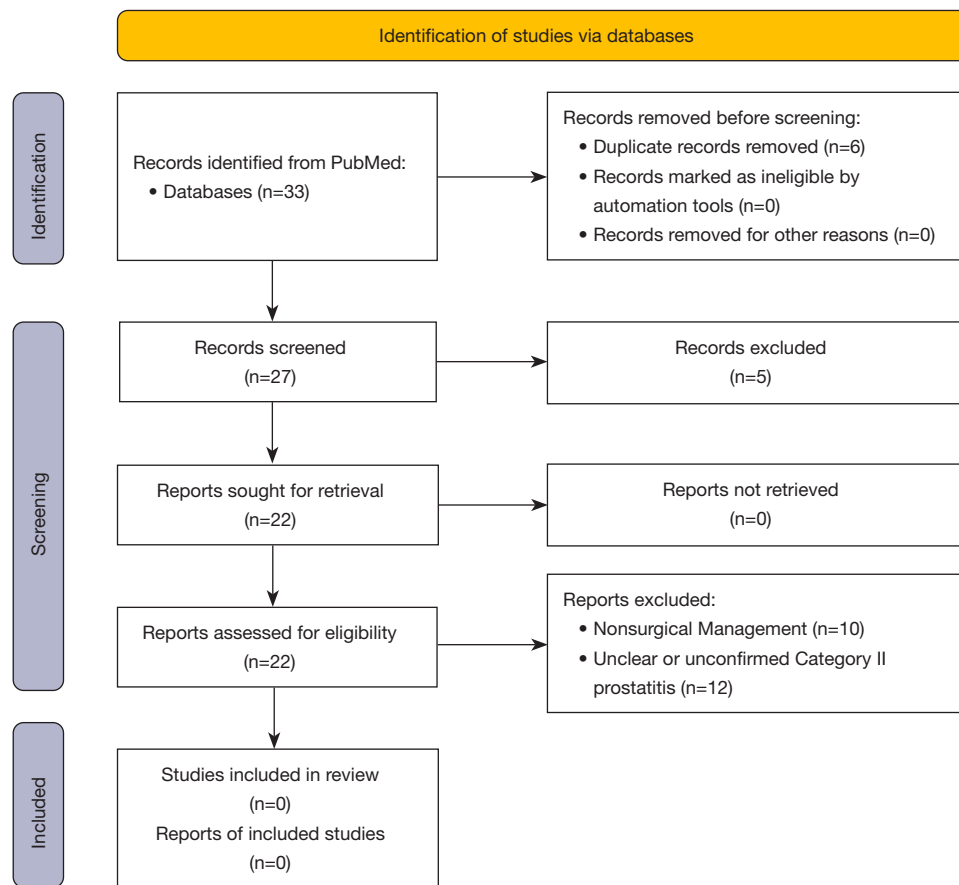
**Table 1** Patient characteristics and clinical characteristics

Case No.	Age (years)	Prostatitis	Pathogen	Recurrent?	TRUS	Stones?	Outcomes	Complications	Follow-up months
Electrosurgical management									
1	41	II	E coli	Yes	13	Yes	Cure	None	12
2	72	II*	E coli	Yes	50	No	Cure	None	60
3	69	II*	Klebsiella	Yes	80	No	Cure	None	12
4	70	II*	Klebsiella	Yes	65	No	Cure	None	10
5	65	I and II	E coli	Yes	24	Yes	Cure	None	132
6	71	II	E coli MDR	Yes	39	Yes	Recurrent	None	12
7	66	II	MRSA	Yes	22	Yes	Cure	None	15
Photo-vaporization of the prostate									
8	74	I	E coli	Yes	80	No	Cure	None	120
9	79	II*	E coli	Yes	80	Yes	Recurrent	Urethral stricture	60
10	73	II	E coli	Yes	24	Yes	Cure	None	36
11	71	II*	E coli	Yes	80	No	Cure	None	10
Holmium laser enucleation of the prostate									
12	72	II	E coli	Yes	77	No	Cure	None	9
Robotic radical prostatectomy									
13	76	II	E coli	Yes	43	No	Cure	SUI	84
14	68	I and II	E coli	Yes	24	Yes <sup>a</sup>	Cure	None	6
15	72	II	E coli	Yes	34	No	Cure	ED	6
16	66	I and II	E coli MDR	Yes	Not performed	N/A	Cure	SUI	72
17	51	II	VRE	Yes	35	Yes	Recurrent	None	24
18	49	II	E coli MDR	Yes	11	No	Cure	None	9
19	72	II	Serratia	Yes	40	Yes <sup>a</sup>	Cure	None	12

\*, chronic intermittent catheterization; <sup>a</sup>, not confined. TRUS, transrectal ultrasound; SUI, stress urinary incontinence; ED, erectile dysfunction; N/A, not applicable.

consistently fails to mention definitive diagnosis of CBP with prostatic secretion cultures or even urine cultures prior to surgical intervention. For the few articles that study the outcome of curing patients definitively diagnosed with CBP, the results often combined these patients with patients of category III prostatitis rather than maintaining stratified results of patients in their cohort or focused on the primary outcome of symptom relief rather than curing of recurrent infection. As a result, no studies were found on the curative outcomes of surgical intervention on patients

with CBP (3,9-28). One study by Cunha *et al.* did show TURP was unsuccessful in curing their patient with CBP due to remnant prostatic calcifications being left behind and serving as a nidus for continual infection. However, this study is primarily a testament to combination medication therapy as being more efficacious to treat CBP, and the focus was not on the efficacy of TURP on curing CBP (26). Thus, our study provides one of the first single-center retrospective case series of adult patients with refractory NIH category II CBP managed with surgical intervention.



**Figure 1** Identification of studies for review.

## Discussion

### Key finding

Between all modalities rate of cure was 84%. The available literature does not include patients with definitive diagnosis of CBP with prostatic secretion culture or urine cultures prior to surgical intervention. Furthermore, studies that assessed surgical outcomes did not properly stratify NIH categories of prostatitis or capture infection cure rates; thus, there were no studies of curative outcomes in patients with NIH category II CBP. When disease is confined to the surgical capsule, endoscopic management is likely sufficient. In patients with disease beyond the capsule and/or concomitant prostate cancer, prior endoscopic treatment, or life-threatening UTI, radical prostatectomy may be justified. Of note, only symptoms related to outflow obstruction were improved immediately by surgery. None

of the cases in this series resulted in acute infections in the post-operative period. Insurance coverage for endoscopic procedures and radical prostatectomy was easily obtained about surgeons in this study.

### Comparison with similar research

Fewer than 10% of outpatient prostatitis visits are for true CBP, however, it can be a challenging disease to treat. This condition is defined by recurrent UTIs of the same causal organism interspersed with asymptomatic periods. Despite urinary tests suggesting bacterial clearance, prostatic secretions during the asymptomatic period will show persistence of the same bacteria—confirming the source of infection to be the prostate. These diagnostic criteria help to distinguish category II prostatitis from the more common, NIH category III prostatitis (29). First-

line treatment for NIH category II prostatitis includes a 4-to-6-week course of antibiotics such as macrolides, sulfa drugs, tetracyclines and fosfomycin. Fosfomycin may be used to treat patients with multidrug resistant organisms or refractory disease. In addition to medication, prostatic massages with or without antibiotics may also alleviate symptoms (30,31). In cases of relapse, patients may be prescribed long-term low dose antibiotics, however, there are concerns for antibiotic resistance with this strategy (29). As a result, in selected patients, surgery is a viable treatment option for CBP and it provides an opportunity for patients to be cured. TURP and radical (total) prostatectomy are the primary surgical treatments for refractory CBP and are most beneficial in men with incomplete bladder emptying, significant prostatic stone burden and/or recurrent drug resistant infection (29).

Our case series is unique in that we demonstrate that endoscopic procedures typically used to treat BPH such as holmium laser enucleation of the prostate, photovaporization of the prostate, and TURP are effective therapies for patients with disease confined to the surgical capsule. However, these procedures are limited in their use if the nidus of infection is beyond the surgical capsule. As predicting or testing for the exact source of the infection is difficult given the current diagnostic tools, total prostatectomy offers a more robust treatment option. Total prostatectomy done in this setting without a concern for cancer should have a lower side effect profile than true radical prostatectomy given that nerves can be spared and no lymph node dissection is necessary however complications such as erectile dysfunction and urinary incontinence are still possible. In our study, patients who underwent nerve sparing total prostatectomy had prostate stones known to extend outside the surgical capsule, a history of prior TURP with life threatening UTIs isolated to the prostate, or concomitant prostate cancer. Even after this robotically invasive surgery, there is still the possibility that the recurrent UTI was not caused by the prostatic focus as evidenced by our one patient with recurrent UTI following removal of the prostate.

### **Strengths and limitations**

The strengths of our study include careful evaluation and diagnosis of infection localization and stone burden prior to surgery and a unified algorithmic approach within the same clinic. The study is limited by sample size and the inability to perform clean localization cultures on select patients due

to inability to discontinue antibiotics.

### **Implications and actions needed**

Studies with larger cohorts across a diversity of patient populations would support these findings from an academic tertiary care referral center.

### **Conclusions**

In well-selected patients, endoscopic management or radical prostatectomy may be curative in CBP that does not resolve with antibiotics. The literature surrounding this topic is limited in its utility due to absence of proper patient stratification and definitive culture proven disease.

### **Acknowledgments**

*Funding:* None.

### **Footnote**

*Reporting Checklist:* The authors have completed the PRISMA-ScR reporting checklist. Available at <https://tau.amegroups.com/article/view/10.21037/tau-23-142/rc>

*Conflicts of Interest:* All authors have completed the ICMJE uniform disclosure form (available at <https://tau.amegroups.com/article/view/10.21037/tau-23-142/coif>). DS serves as an unpaid editorial board member of *Translational Andrology and Urology* from August 2022 to July 2024. SDL reports that he received a grant from the American Urological Association. DS reports receiving payment for the American Urological Association Board Review course. He is paid for 5 lectures, all unrelated to the subject of this paper. He reports patents planned but unrelated to this work. He reports roles on several boards which are all medical non-profits and unpaid positions. Finally, he reports stock or stock options with Triural licenses nutraceuticals for category III prostatitis. He is also currently a full-time employee of Pacific Edge Diagnostics whose products in bladder cancer are completely unrelated to the subject of this paper. The other authors have no conflicts of interest to declare.

*Ethical Statement:* The authors are accountable for all aspects of the work in ensuring that questions related to the accuracy or integrity of any part of the work are

appropriately investigated and resolved. The study was conducted in accordance with the Declaration of Helsinki (as revised in 2013). The study was approved by the institutional review board of the Cleveland Clinic (IRB No. 21-462). Informed consent was not required from patients included in this study as it was a retrospective study with patients from various states/countries.

*Open Access Statement:* This is an Open Access article distributed in accordance with the Creative Commons Attribution-NonCommercial-NoDerivs 4.0 International License (CC BY-NC-ND 4.0), which permits the non-commercial replication and distribution of the article with the strict proviso that no changes or edits are made and the original work is properly cited (including links to both the formal publication through the relevant DOI and the license). See: <https://creativecommons.org/licenses/by-nc-nd/4.0/>.

## References

- Krieger JN, Nyberg L Jr, Nickel JC. NIH consensus definition and classification of prostatitis. *JAMA* 1999;282:236-7.
- Nickel JC. Prostatitis. *Can Urol Assoc J* 2011;5:306-15.
- Barnes RW, Hadley HL, O'Donoghue EP. Transurethral resection of the prostate for chronic bacterial prostatitis. *Prostate* 1982;3:215-9.
- Krongrad A, Lai S. Laparoscopic prostatectomy for severely symptomatic, treatment-refractory chronic prostatitis: Preliminary observations from an ongoing phase II clinical trial. *Urotoday Int J* 2011;4:art30.
- Alexander RB. Radical prostatectomy for chronic prostatitis. *BJU Int* 2003;92 Suppl 3:e17.
- Wagenlehner FM, Diemer T, Naber KG, et al. Chronic bacterial prostatitis (NIH type II): diagnosis, therapy and influence on the fertility status. *Andrologia* 2008;40:100-4.
- McLoughlin LC, McDermott TE, Thornhill JA. Radical prostatectomy in the presence of ongoing refractory ESBL *Escherichia coli* bacterial prostatitis. *BMJ Case Rep* 2014;2014:bcr2014206291.
- Schoeb DS, Schlager D, Boeker M, et al. Surgical therapy of prostatitis: a systematic review. *World J Urol* 2017;35:1659-68.
- Su ZT, Zenilman JM, Sfanos KS, et al. Management of Chronic Bacterial Prostatitis. *Curr Urol Rep* 2020;21:29.
- Feng Y, Ramnarine VR, Bell R, et al. Metagenomic and metatranscriptomic analysis of human prostate microbiota from patients with prostate cancer. *BMC Genomics* 2019;20:146.
- Smart CJ, Jenkins JD, Lloyd RS. The painful prostate. *Br J Urol* 1975;47:861-9.
- Krieger JN. Prostatitis syndromes: pathophysiology, differential diagnosis, and treatment. *Sex Transm Dis* 1984;11:100-12.
- Krieger JN, Riley DE, Vesella RL, et al. Bacterial dna sequences in prostate tissue from patients with prostate cancer and chronic prostatitis. *J Urol* 2000;164:1221-8.
- Baert L, Van Poppel H, Vandeursen H. Review of modern trends in the treatment of chronic bacterial prostatitis (C.B.P.). *Infection* 1991;19 Suppl 3:S157-9.
- Srigley JR. Key issues in handling and reporting radical prostatectomy specimens. *Arch Pathol Lab Med* 2006;130:303-17.
- Greer MD, Shih JH, Lay N, et al. Validation of the Dominant Sequence Paradigm and Role of Dynamic Contrast-enhanced Imaging in PI-RADS Version 2. *Radiology* 2017;285:859-69.
- Pfau A. The treatment of chronic bacterial prostatitis. *Infection* 1991;19 Suppl 3:S160-4.
- Mathisen W, Normann E, Taksdal S, et al. Doxycycline levels in prostatic tissue and blood. *Eur Urol* 1975;1:157-8.
- Pronk MJ, Pelger RC, Baranski AG, et al. Cure of chronic prostatitis presumably due to *Enterococcus* spp and gram-negative bacteria. *Eur J Clin Microbiol Infect Dis* 2006;25:270-1.
- Le B, Schaeffer AJ. Chronic prostatitis. *BMJ Clin Evid* 2011;2011:1802.
- Erickson BA, Schaeffer AJ, Van Le B. Chronic prostatitis. *BMJ Clin Evid* 2008;2008:1802.
- Bowen DK, Dielubanza E, Schaeffer AJ. Chronic bacterial prostatitis and chronic pelvic pain syndrome. *BMJ Clin Evid* 2015;2015:1802.
- Zasieda Y, Solomianyi R. Chronic prostatitis therapy combined with electromyostimulation-aspiration, transurethral electrophoresis of platelet-rich plasma and transrectal low-intensity pulsed ultrasound. *Georgian Med News* 2020;(299):29-33.
- Wagenlehner FM, Lunz JC, Kees F, et al. Serum and prostatic tissue concentrations of moxifloxacin in patients undergoing transurethral resection of the prostate. *J Chemother* 2006;18:485-9.
- Boerema JB, Bach D, Jol C, et al. Penetration of rifloxacin into human prostatic tissue and fluid. *J Antimicrob Chemother* 1991;28:547-54.
- Cunha BA, Gran A, Raza M. Persistent extended-spectrum  $\beta$ -lactamase-positive *Escherichia coli* chronic prostatitis

- successfully treated with a combination of fosfomycin and doxycycline. *Int J Antimicrob Agents* 2015;45:427-9.
27. Baummueller A, Hoyme U, Madsen PO. Rosamicin--a new drug for the treatment of bacterial prostatitis. *Antimicrob Agents Chemother* 1977;12:240-2.
  28. Netto NR Jr, Palma PC, Srulzon GB, et al. Concentrations of norfloxacin in prostatic tissues following oral administration in patients with benign prostatic hyperplasia. *Int Urol Nephrol* 1988;20:47-9.
  29. Lundy SD, Shoskes DA. (Mis)-Diagnosis and (Mis)-Management of Prostate Infections. *AUA Update series*. 2021; 40 (Lesson 28). Available online: <https://auau.auanet.org/content/update-series-2021-lesson-28-mis-diagnosis-and-mis-management-prostate-infections#group-tabs-node-course-default2>
  30. Anothaisintawee T, Attia J, Nickel JC, et al. Management of chronic prostatitis/chronic pelvic pain syndrome: a systematic review and network meta-analysis. *JAMA* 2011;305:78-86.
  31. Ateya A, Fayez A, Hani R, et al. Evaluation of prostatic massage in treatment of chronic prostatitis. *Urology* 2006;67:674-8.

**Cite this article as:** Orji PU, Khooblal P, Doolittle J, Lundy SD, Shoskes D. Surgical management of National Institutes of Health category II chronic bacterial prostatitis: a case series and scoping review of the literature. *Transl Androl Urol* 2023;12(10):1581-1588. doi: 10.21037/tau-23-142