

Received: 2018.05.27

Accepted: 2018.06.26

Published: 2018.10.02

Fence Angioplasty Prevents Narrowing of Venous Anastomosis in Solitary Pancreas Transplant

Authors' Contribution:

Study Design A
Data Collection B
Statistical Analysis C
Data Interpretation D
Manuscript Preparation E
Literature Search F
Funds Collection G

ABEF 1,2 **Je Ho Ryu**
BCD 1 **Tae Beom Lee**
BCEF 1 **Kwang Ho Yang**
ACDE 3 **Taeun Kim**
CDF 4 **Young Soo Chung**
ABCEFG 1,2 **Byung Hyun Choi**

1 Division of Hepato-Biliary-Pancreatic Surgery and Transplantation, Department of Surgery, Pusan National University Yangsan Hospital, Pusan National University School of Medicine, Yangsan, South Korea
2 Research Institute for Convergence of Biomedical Science and Technology, Pusan National University Yangsan Hospital, Yangsan, South Korea
3 Department of Radiology, Pusan National University Yangsan Hospital, Pusan National University School of Medicine, Yangsan, South Korea
4 Division of Transplant and Vascular Surgery, Department of Surgery, Pusan National University Hospital, Yangsan, South Korea

Corresponding Author: Byung Hyun Choi, e-mail: gmoolpop@gmail.com

Source of support: Departmental sources

Background: Graft thrombosis is the leading cause of early graft failure in pancreas transplants. Direct anastomosis grafting of the portal vein to the iliac vein or vena cava generally appears narrowed on postoperative computed tomography (CT) scans. However, modification of surgical techniques may prevent venous narrowing, which also prevents thrombosis-related graft failure.

Material/Methods: We performed 31 solitary pancreas transplants since 2015. Retrospective analysis of these patients was performed.

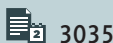
Results: Fence angioplasty was applied in the final 12 cases, and no technical failures or early graft losses occurred in these cases. Three graft losses, including 2 immunologic losses and 1 patient death with functioning graft, occurred after at least postoperative 4 months. The venous anastomoses were evaluated via intraoperative Doppler ultrasound and postoperative CT scans. Intraoperative Doppler ultrasound revealed improved spectral waves of venous anastomoses in the fence group (monophasic spectral wave, 42.9% vs. 0%, $p=0.017$). The fence-graft applied group had no cases of narrowing, whereas the non-fence group had high narrowing rates on CT scans (84.2% vs. 0%, $p<0.001$). Furthermore, with less use of postoperative heparin, postoperative bleeding rates were lower in the fence group (36% vs. 0%, $p=0.026$).

Conclusions: Fence angioplasty is a definitive method for avoiding venous anastomotic stenosis and preventing graft failure due to thrombosis.

MeSH Keywords: Anastomosis, Surgical • Pancreas Transplantation • Thrombosis

Abbreviations: ANOVA – analysis of variance; CT – computed tomography; DM – diabetes mellitus; GDA – gastroduodenal artery; HbA1c – hemoglobin A1c; HTK – Histidine-Tryptophan-Ketoglutarate; INR – international normalized ratio; IODU – intraoperative Doppler ultrasound; IVC – inferior vena cava; JAMA – Journal of the American Medical Association; LMWH – low molecular weight heparin; NM – Nafamostat mesylate; PAK – pancreas after kidney transplant; pDRI – pancreas donor risk index; PTA – pancreas transplant alone; SD – standard deviation; SMA – superior mesenteric artery

Full-text PDF: <https://www.annalsoftransplantation.com/abstract/index/idArt/911379>



3035



2



6



25



Background

Pancreas transplant is the only near-cure treatment for type I diabetes mellitus (DM) [1]. The results of pancreas transplant have improved over time. Nevertheless, the actual number of procedures has continuously decreased in the last 2 decades, especially for solitary pancreas transplants (pancreas after kidney transplant; PAK, pancreas transplant alone; PTA) in the United States. The decreases in solitary pancreas transplants were prominent after the publication of a study in JAMA in 2003 [2] in which the authors concluded that patients receiving solitary pancreas transplants had a greater mortality risk compared to those remaining on the waiting list [3]. A subsequent rebuttal letter for that study was also published, with contradictory conclusions [4]. However, the stigma of solitary pancreas transplant has not been overcome.

The other reason for reluctance to perform pancreas transplants is the relatively high rate of surgical complications. One of the major surgical complications after pancreas transplant is early graft failure due to thrombosis [5]. Unfortunately, the early graft loss rate has not improved over the last 30 years [6]. Even in recent reports, the technical failure rate due to thrombosis was 5–10% [7,8]. It is well known that platelet function is decreased in uremic patients, and thrombosis occurs more easily in solitary pancreas transplant than in simultaneous pancreas and kidney transplants [9]. Furthermore, postoperative heparin for the prevention of thrombosis has increased the risk of postoperative bleeding.

As the outcomes of pancreatic islet transplants are showing better outcomes than before, transplant surgeons face the need for technical perfection even with decreasing opportunities to perform solitary pancreas transplants [10]. If simple modifications of the surgical technique would decrease the risk of graft failure due to thrombosis, the barriers to entry with respect to performing pancreas transplant would be lower, thereby promoting increasing numbers of pancreas transplants. In this article, we suggest that our new surgical technique can minimize graft thrombosis.

Material and Methods

Patients

Thirty-one solitary pancreas transplants (PAK or PTA) were performed in Pusan National University Yangsan Hospital from August 2015 to January 2018. The mean follow-up period was 14.5 ± 8.0 months. The requirement for ethics approval was waived due to the retrospective nature of the study.

Surgical technique

Common technique

a. Pancreas retrieval

We procured the grafts using conventional methods [11]. A length of jejunum and the spleen were also procured with the duodenum graft and the pancreas. Surgical staplers were used for the duodenum graft and small bowel division. Histidine-tryptophan-ketoglutarate solution (HTK solution) was used for organ preservation and protection in all cases. HTK solution is the only usable solution for organ preservation in Korea.

b. Back-table procedure

The pancreas was prepared as follows:

- i. Mesentery clearing and dissection of the remnant jejunum from the graft pancreas was performed. The residual jejunum was not resected in order to avoid excessive expansion or edema after reperfusion.
- ii. The vascular structures of mesenteric root were reinforced with over and over sutures.
- iii. The spleen was carefully removed to avoid damage to the pancreatic graft tail, and the splenic artery and vein were preserved.
- iv. Lymph nodes around the superior mesenteric artery (SMA) were cleared.
- v. Y-graft reconstruction was performed using the donor's iliac artery. Generally, the internal iliac artery was anastomosed to the SMA and the external iliac artery was anastomosed to the splenic artery.

c. Recipient procedure

A mid-line incision was created. A right-sided colon and small bowel was detached from the retroperitoneum (i.e., the extended Kocher maneuver) to make space for the graft pancreas and dissection of the common iliac artery and inferior vena cava (IVC) for vessel anastomotic sites. It took approximately 20–30 min before vessel anastomosis. The conventional heparin (5000 IU) was injected before vessel anastomosis. Following venous anastomosis (see Clinical findings) with the graft head-up position, the Y-graft was anastomosed to the right common iliac artery. The graft duodenum was anastomosed to native duodenum in a side-to-side manner at a tension-free site. Finally, the remnant jejunum was resected. One patient had a duodeno-jejunosomy since the patient had no duodenum due to previous pancreatic surgery. Intraoperative Doppler ultrasound for the graft vessels was used by the surgeon. After drain tube insertion,

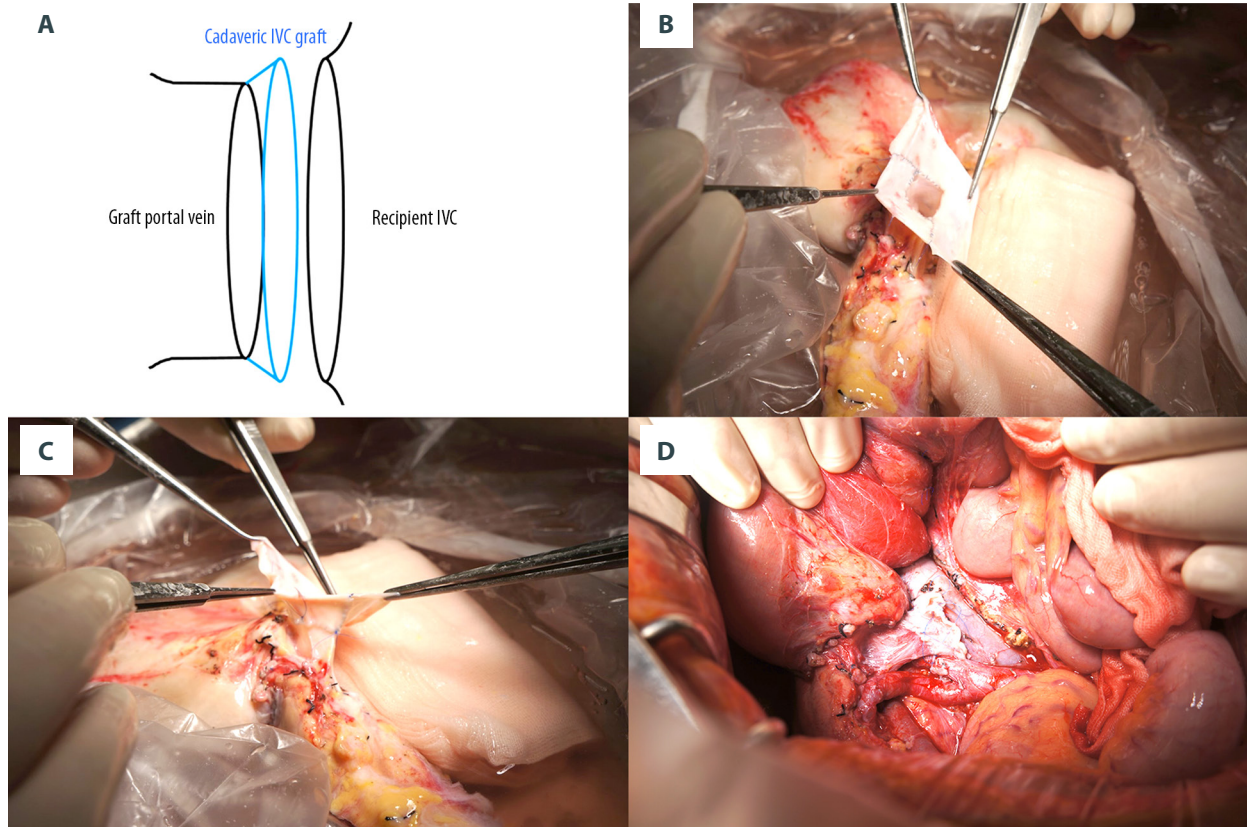


Figure 1. (A) The method of fence angioplasty. A cadaveric inferior vena cava (IVC) patch is procured from the same donor of pancreas. (B, C) The view after finishing the fence angioplasty in the bench procedure. The border of the fence is the site of anastomosis, which means that there are at least 2 openings. (D) The view after reperfusion of the graft pancreas; the fence is shown.

the wound was closed. This procedure was described in our previous report [12].

Venous anastomosis technique

a. Direct anastomosis (n=6)

The graft portal vein was anastomosed directly to the recipient's IVC.

b. Diamond-shaped patch anastomosis (n=13)

During the back-table procedure, a diamond-shaped patch (D-patch), procured from the same donor's IVC, was used for reconstruction of the graft portal vein. We aimed to prevent stenosis of the venous anastomosis due to sagging that occurred postoperatively. This procedure was described in our previous report [12].

c. Fence angioplasty (n=12) (Figure 1)

During the back-table preparation procedure, the IVC segment was procured from the donor's IVC. Next, we divided it in the coronal direction at the same width. Each patch was anastomosed to the graft portal vein anteriorly and posteriorly and then anastomosed to each other at the corner. A small split incision to the graft portal vein was needed because the IVC was usually wider than the graft portal vein. In the recipient procedure, the fence was anastomosed to the recipient's IVC.

Immunosuppression

Anti-thymocyte globulin (Thymoglobulin®, 5 mg/kg, divided 5 times; postoperative days 0, 1, 2, 4, and 6) induction was used. Tacrolimus (trough level, 9–11 ng/ml) and mycophenolate mofetil (1.5 grams/day) were prescribed. The dose of steroid was decreased to 10 mg after surgery during admission and stopped after 2 months, with routine monitoring of blood amylase and lipase. The dual immunosuppressant (tacrolimus and mycophenolate mofetil) regimen was used after cessation of the steroid.

Anticoagulation therapy

Intravenous conventional heparin (about 350 units/h) was prescribed to prevent thrombosis in the first 5 patients after computed tomography (CT) scan. Low molecular weight heparin (LMWH, 1 mg/kg/day) was used in 20 patients for 1 week. Nafamostat mesylate (NM) was used in the last 9 patients. In the last 9 patients, LMWH was used together with the NM in 4 cases. No heparin was used in the last 5 patients.

Radiologic findings

a. Intraoperative Doppler ultrasound (Figure 2)

Intraoperative Doppler ultrasound was performed in 26 patients. We observed the arterial flow, the size of the venous anastomoses, the state of the color Doppler in the venous anastomoses, and the spectral waves in the venous anastomoses. We only analyzed spectral waves since the size of the venous anastomoses and state of the color Doppler were somewhat subjective findings.

b. Postoperative CT (Figure 3)

CT scans were obtained at least twice on postoperative day 0 and before discharge in every patient. The state of the venous anastomosis was evaluated by a radiologist. We considered that the vessel was narrowed if only 1 narrowing was observed in both CT scans. Graft thrombosis also was detected by CT scans.

Statistical analysis

The patients who had fence angioplasty (fence group) and those who did not (non-fence group) were compared via statistical analysis.

Categorical variables are expressed in terms of absolute and relative frequencies. Quantitative variables are expressed as mean and standard deviation (SD). The *t* test was used to compare the results of quantitative assays, and Fisher's exact test was used to compare categorical variables. Repeated measures analysis of variance (ANOVA) was used to compare the changes in fasting glucose, C-peptide, and hemoglobin A1c (HbA1c) levels in both groups. The differences were considered to be significant at $p < 0.05$. Graft survival was analyzed using the Kaplan-Meier estimator. Statistical calculations were performed using PASW statistics for Windows (Version 21; SPSS, Inc., Chicago, IL).

Results

Demographics and baseline characteristics

Thirty-one isolated pancreas transplants were performed from 2015 to January 2018. Among them, the last 12 cases were in the fence angioplasty group. Table 1 shows the baseline characteristics of the patients in this study. There was no significant difference in recipients' ages, sex, PTA, and distribution of type of diabetes between the non-fence group and the fence group. Body mass index and preoperative HbA1c were also similar between the 2 groups. The majority of recipients had type I DM and could not control their blood glucose.

The pancreas donor risk index (pDRI) was analyzed as suggested by Axelrod et al. [13]. The pDRI was slightly higher in the fence group. However, according to the report, the 2 groups were in the same pDRI group, which meant they had similar risks of long-term graft failure.

Radiologic findings

Intraoperative Doppler ultrasound (IODU) was obtained for all recipients except in the first 5 cases. We observed the venous anastomosis sizes, the states of the color Doppler, and the spectral wave. The fence group showed wider anastomosis and no turbulent flow on the IODU. However, these are not objective findings; therefore, we only analyzed the spectral wave. The monophasic spectral wave, which suggested stenosis of the venous anastomoses, was only seen in the non-fence group (Table 2, Figure 2).

CT scans were performed for all recipients. There was no narrowing of the venous anastomoses in the fence group (Table 2, Figure 3). Most patients in the non-fence group had narrowing. Interestingly, all patients showed narrowing in the direct anastomosis.

Venous thrombosis rates were similar in both groups. However, most of them had partial thrombosis located in the end of the splenic vein or superior mesenteric vein. Only 1 patient in the non-fence group had an open thrombectomy, due to a near-total obstruction of the vein, while the others were treated with heparinization or just observation.

There were no episodes of arterial thrombosis.

Clinical findings

There were no technical failures, which was defined as early graft loss or re-use of insulin within the first 3 postoperative months. The amount of heparin used in the first week was much less in the fence group. Furthermore, no heparin was

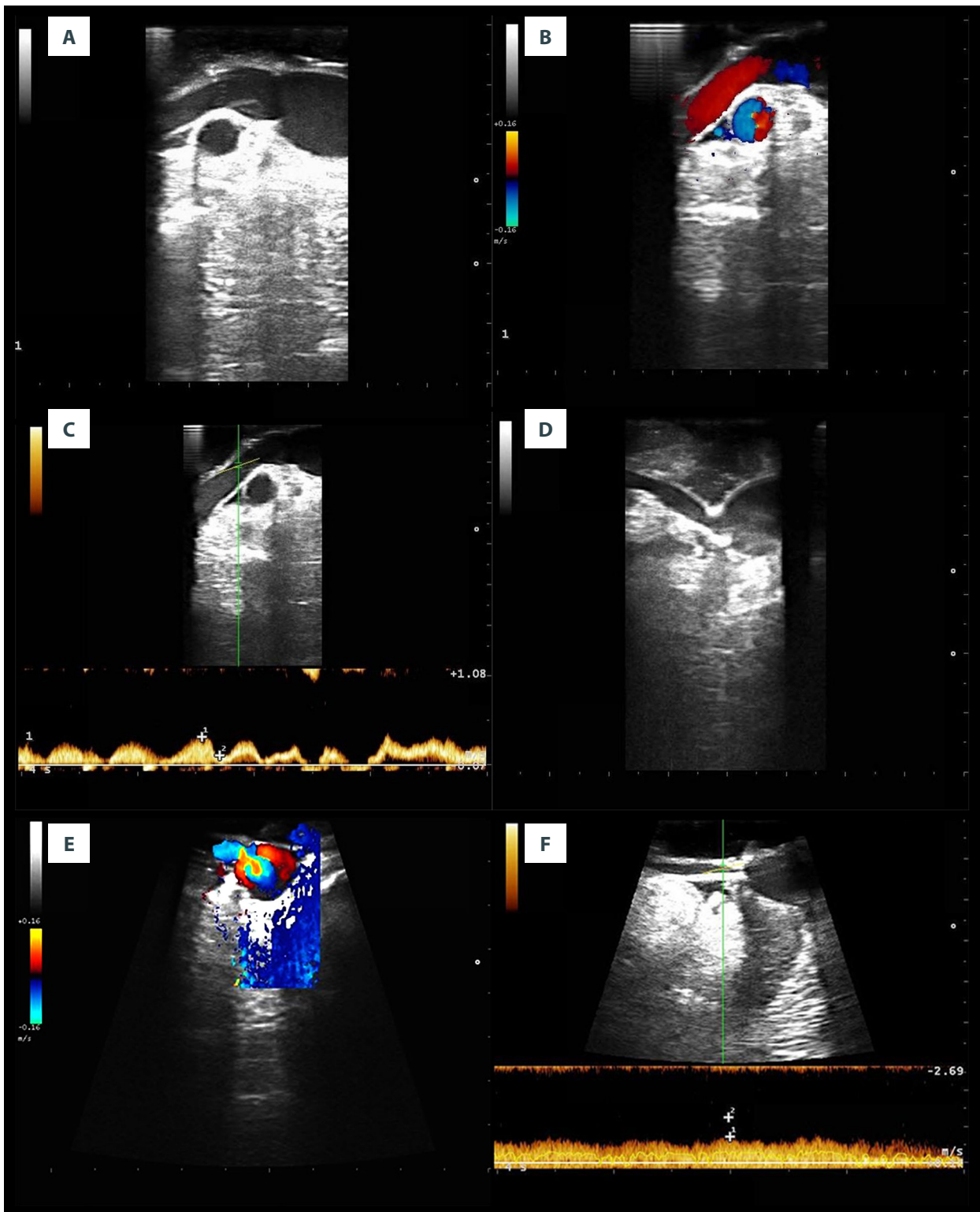


Figure 2. (A–C) Fence angioplasty procedure; (D–F) Direct anastomosis procedure. (A) The wide opening of the anastomotic site was observed using B-mode Doppler ultrasound. (B) No turbulent flow was observed on color Doppler ultrasound. (C) The biphasic spectral wave was observed using pulsed Doppler ultrasound. (D) Narrowing of the anastomosis was observed using B-mode Doppler ultrasound. (E) Turbulent blood flow was observed in the anastomotic site on color Doppler ultrasound. (F) Monophasic and only small variations according to respiration were observed on pulsed Doppler ultrasound.

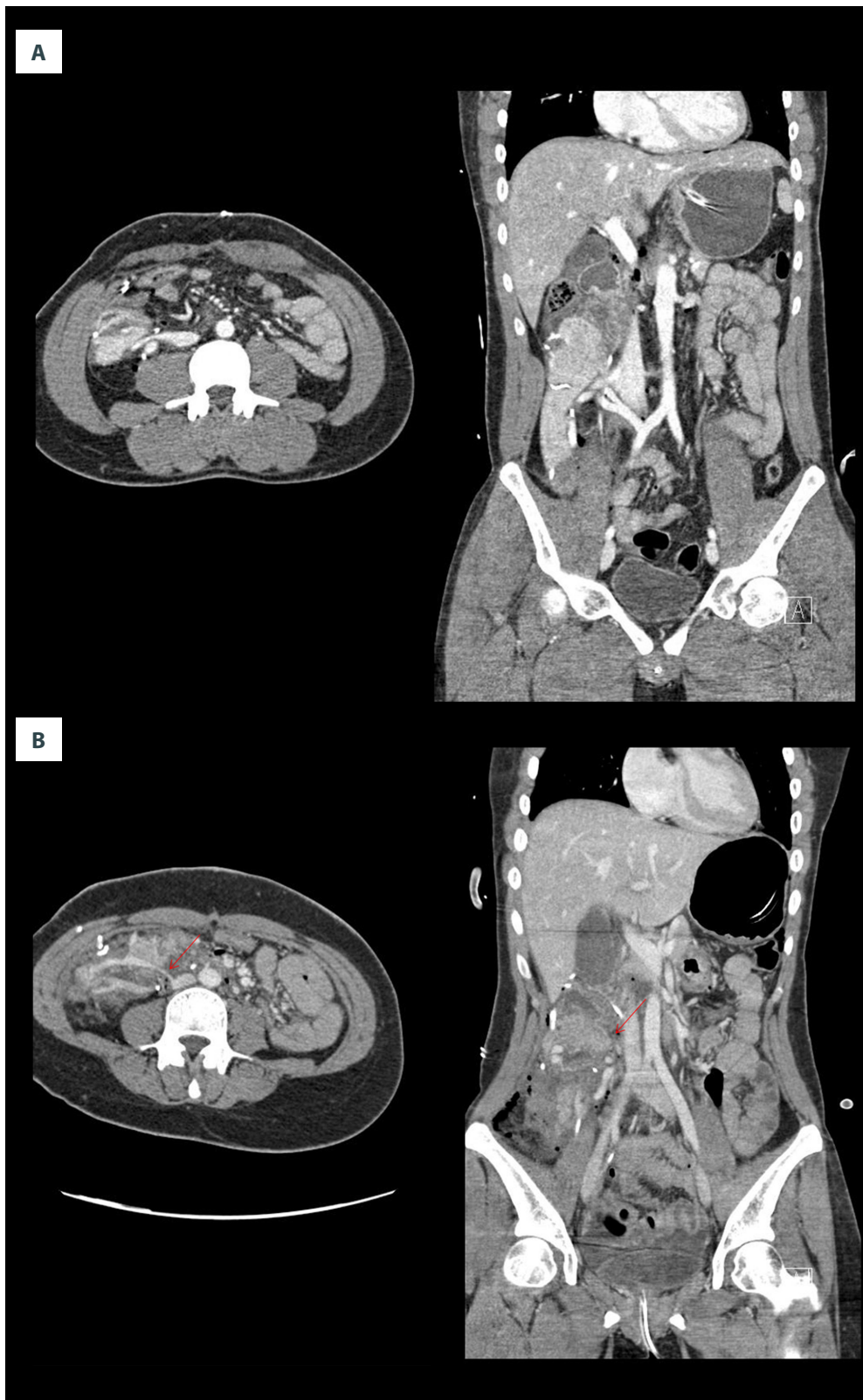


Figure 3. (A) The CT scan in fence angioplasty. Left; Axial view, Right; Coronal view. Wide opening was maintained, as seen in CT scan. (B) The CT scan in direct anastomosis. Left; Axial view, Right; Coronal view. The anastomotic narrowing (red arrow) was seen in CT scan.

Table 1. Baseline characteristics of recipients enrolled in the study.

Variables	Non-fence group (n=19)	Fence group (n=12)	p-Value
Mean age, y (SD)	35.6 (13.0)	38.8 (13.8)	0.513
Female gender, n (%)	9 (47.4)	6 (50)	1.000
PTA, n (%)	16 (84.2)	8 (66.7)	0.384
Type II DM, n (%)	4 (21.1)	3 (25)	1.000
Body mass index, kg/m ² (SD)	23.0 (2.6)	22.0 (2.9)	0.362
Preoperative HbA1c,% (SD)	9.7 (2.0)	8.6 (2.6)	0.209
pDRI*	0.97 (0.11)	1.12 (0.21)	0.011

* pDRI; pancreas donor risk index [13]. Equation: $pDRI = \exp(-0.13792 \times I[\text{Female Donor}]) - 0.034455 \times I[\text{Donor Age} < 20] \times [\text{Donor Age} - 20] + 0.026149 \times [\text{Donor Age} - 28] + 0.19490 \times I[\text{Donor Creatinine} > 2.5] + 0.23951 \times I[\text{Donor Black Race}] + 0.15711 \times I[\text{Donor Asian Race}] - 0.00986347 \times [\text{Donor BMI} - 24] + 0.033274 \times I[\text{Donor BMI} > 25] \times [\text{Donor BMI} - 25] - 0.006073879 \times (\text{Donor Height} - 173) + 0.21018 \times I[\text{Donor COD CVA}] - 0.28137 \times I[\text{Donor COD CVA for PAK txp}] + 0.014678 \times [\text{Preservation Time} - 12] + 0.33172 \times I[\text{DCD}]$.

Table 2. Radiologic and Clinical findings of recipients enrolled in the study.

Variables	Non-fence group (n=19)	Fence group (n=12)	p-Value
Monophasic spectral wave on IODU*, n (%)	6 (42.9, n =14)	0 (0)	0.017
Narrowing of venous anastomosis on CT scans, n (%)	16 (84.2) 6/6; direct anastomosis 10/13; D-patch using anastomosis	0 (0)	<0.001
Partial venous thrombosis on CT scan, n (%)	6 (31.6)	3 (25)	1.000
Technical failure, n (%)	0 (0)	0 (0)	1.000
Postoperative mean daily use of heparin in the first week, IU*/kg (SD)	119.1 (41.0)	30.6 (65.4)	<0.001
Postoperative bleeding (%)	7 (36.8)	0 (0)	0.026

IU – international unit.

prescribed to the last 5 patients. A decrease in the use of heparin resulted in less bleeding. There was no postoperative bleeding that required surgical re-exploration in the fence group.

Regarding graft function, postoperative C-peptide levels were increased in both groups. Fasting glucose and HbA1c were rapidly normalized after transplant. There were no differences in these changes in metabolic findings between the 2 groups (Figure 4).

Patient and graft survival

Three graft losses occurred. The first was due to an immunologic rejection, the second failure resulted from non-compliance with the immunosuppressant medication, and the last was a death with functioning graft that occurred due to cholangiocarcinoma. All of these patients were in the non-fence

group; however, there were no statistically significant differences due to different observational periods.

Figure 5 shows the survival curve for the grafts in all recipients. The 1-year and 2-year graft survival rates were 91.5% and 83.2%, respectively.

Discussion

Venous thrombosis and fence angioplasty

Graft thrombosis is the leading cause of technical failure in pancreas transplant [14]. The early graft failure rate is higher in isolated pancreas transplants than in simultaneous pancreas and kidney transplants, even in recent reports [15]. Then why does thrombosis occur easily in the pancreas graft? Why does

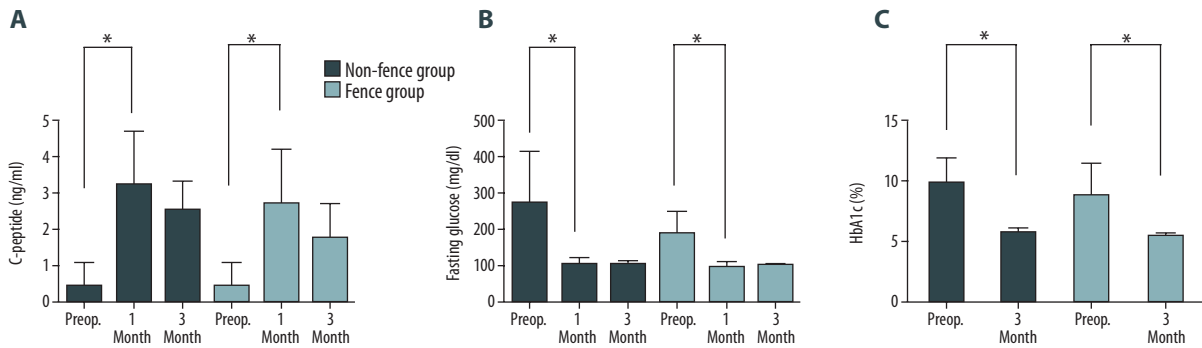


Figure 4. (A) C-peptide level changes from the preoperative period to postoperative 3 months. C-peptides were rapidly increased in the post-transplant period in both groups. However, there was no statistically significant difference between the 2 groups. * p<0.001. (B) The fasting glucose level changes from the preoperative period to postoperative 3 months. The fasting glucose levels were rapidly normalized in the post-transplant period in both groups. However, was no statistically significant difference between the 2 groups. * p<0.001. (C) Hemoglobin A1c (HbA1c) level changes from the preoperative period to postoperative 3 months. The HbA1c levels were rapidly normalized in the post-transplant period in both groups. However, there was no statistically significant difference between the 2 groups. * p<0.001

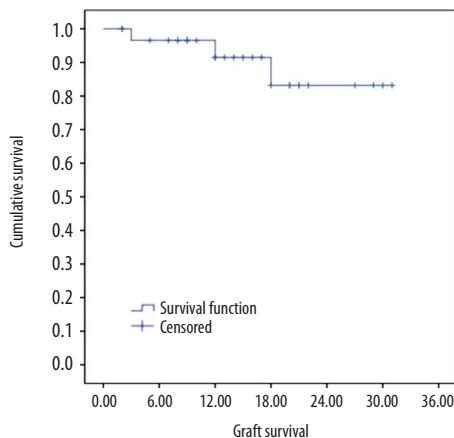


Figure 5. Overall graft survival curve of all recipients.

thrombosis not occur in kidney or liver allografts? We assume the reason is the difference in blood flow. In a previous report, we suggested that the most important cause of graft thrombosis is altered blood flow [16]. Venous thrombosis rather than arterial thrombosis is the main cause of early graft failure if there is no technical error. Arterial thrombosis occurs later, after venous congestion due to venous thrombosis, except in cases of technical errors (Figure 6). Hakeem et al. also reported that arterial thrombosis was detected later than venous thrombosis on CT scans [17].

The resistance to flow in small tubes was described by G. Hagen and J. Poiseuille [18]. They found that resistance to flow is a function of the inner radius of the tube (r), the length of the

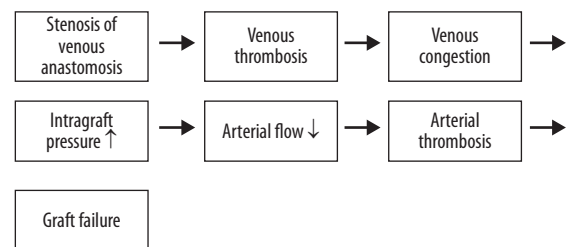


Figure 6. The natural history of graft loss from venous thrombosis. Anastomotic venous thrombosis may cause venous thrombosis at the anastomotic site, which provokes venous congestion. Then, intra-graft pressure can be increased and arterial flow diminished. Diminishing arterial flow can cause arterial thrombosis. Finally, the graft fails.

tube (L), and the viscosity of the fluid. Their observations are expressed in the following equation, known as the Hagen-Poiseuille equation:

$$Q = \Delta P \times \left(\frac{\pi r^4}{8 \mu L} \right)$$

$$R = 8 \mu L / \pi r^4$$

ΔP is the pressure gradient and Q is the steady flow of fluid in a hollow and rigid tube. R is the resistance to flow in small tubes. This equation indicates that a 2-fold increase in the radius of the tube will result in a 16-fold increase in flow. The length of the tube and the flow of fluid are inversely

proportional. This principle is also consistent with the results observed in clinical practice. Wider and shorter anastomoses are better for maintaining blood flow. The size of the opening is more important than the length, according to the equation above.

Fence angioplasty makes the opening more than twice as wide, which means resistance would be decreased to at least 1/16. Then, even though the length was elongated, blood flow could be maintained without disturbance.

We followed some different approaches to venous anastomosis. The diamond-shaped patch (D-patch) is the one of them [12]. Unfortunately, the D-patch technique could not guarantee the wide opening in the postoperative CT scan (Table 2). Furthermore, the technique took more effort and more time. However, fence angioplasty is easy and not time consuming in anastomosis. We prefer to use the IVC for the patch rather than any other veins due to its thickness and durability and the fact that it could always be obtained from the same cadaveric donor. The IVC is usually wider than the portal vein. We usually made slit incisions in the graft portal vein, which makes the anastomosis between the IVC and the portal vein wider. This is the second advantage of fence angioplasty.

Intraoperative Doppler ultrasound findings

IODU findings are well known in the field of living donor liver transplants [19]. Intraoperative B-mode ultrasound can show the strictures along the right hepatic vein in a liver transplant by direct visualization. Pulsed Doppler images show the monophasic spectral wave instead of the triphasic spectral wave in cases of right hepatic vein stenosis. Biphasic or triphasic spectral wave forms reflect not only the flow of venous drainage, but also the motion of the heart valves, which indicates that the resistance is low. This is a very sensitive finding in hepatic vein stenosis in living donor liver transplantation [20].

In this study, we evaluated portal vein flow by IODU. Monophasic spectral waves were only seen in the non-fence group. There was only a small variation of flow according to the respirations in the monophasic spectral wave. The fence angioplasty overcame this finding since wider anastomoses meant low resistance of the anastomoses. The biphasic spectral wave reflected the motion of the heart valves. The anastomotic site was larger in B-mode, and color Doppler findings showed no turbulent flow in the fence group. However, these were subjective findings; therefore, we did not include those findings in the results section.

CT scan findings

Stenosis is a pathologic narrowing, but all narrowings are not pathologic findings. Therefore, we elected to refer to narrowing

instead of stenosis in this article. We insist that the narrowing of venous anastomoses is the 'default' state, if modifications are not applied on the postoperative CT scan. This is caused by low flow of the graft pancreas. The direct anastomosis always showed narrowing in CT scans without exception. The fence angioplasty overcame this finding, since wider openings using vena cava patches made for more durability and wider anastomoses as seen on CT scan.

There was no difference in partial thrombosis on CT scans between the 2 groups. Most of the thromboses were non-occlusive partial thromboses of the splenic veins. The only case of near-occlusive thrombosis occurred in the non-fence group and required thrombectomy. Harbell et al. reported that arterial signal abnormalities with splenic thrombosis, such as absence or reversal of diastolic flow within the graft, require urgent operative intervention. Partial non-occlusive splenic vein thrombus does not increase the risk of graft loss [21]. There was no arterial signal abnormality in our study. Hakeem et al. described a CT grading system for pancreas allograft thrombosis [17]. They also reported that therapeutic anticoagulation is not necessary for non-occlusive peripheral venous thrombosis. The problem is in the extension of venous thrombi. Peripheral non-occlusive thrombi do not increase the risk of graft loss. However, a central occlusive venous thrombus in an anastomotic portal vein is associated with a very high risk of graft loss [17,21,22]. The narrowing itself is not a pathologic finding. This is the result of decreased flow through the portal vein. However, if the narrowing can be avoided, the risk of graft loss would be decreased. The fence angioplasty guarantees a wider opening of the anastomosis site, which minimizes the risk of central occlusive venous thrombosis. The fence angioplasty is the definite method for minimizing the narrowing of an anastomosis site on CT scan.

Clinical findings and graft survival

In this study, there were no technical failures in either group. There may be several reasons for this. First, the donors had low pDRI scores. The majority of donors were young, and the cold ischemic time was very short because Korea is not a big country. Second, the CT scan on the day of surgery or the first postoperative day detects early graft thrombosis. Subsequently, we used heparin aggressively, especially in the early period, in our center. Early CT scans and the aggressive use of heparin leads to low graft failure due to thrombosis [23]. Third, use of the vena cava for venous anastomosis has the advantage of low technical failure rate [12,24].

The postoperative use of heparin has been justified due to the risk of thrombosis [17,21,23,25]. However, heparinization increases the risk of postoperative bleeding. Seven cases of bleeding occurred in the non-fence group and most were

related to the use of heparin. We minimized use of heparin after fence angioplasty was applied. Even in the last 5 patients, we did not use heparin at all. Biphasic spectral wave in IODU and non-narrowing patent venous anastomosis on CT scan indicated that the use of heparin was not necessary. The lack of heparin led to no postoperative bleeding in the fence group.

References:

- Dholakia S, Mittal S, Quiroga I et al: Pancreas transplantation: Past, present, future. *Am J Med*, 2016; 129(7): 667–73
- Stratta RJ, Fridell JA, Gruessner AC et al: Pancreas transplantation: A decade of decline. *Curr Opin Organ Transplant*, 2016; 21(4): 386–92
- Venstrom JM, McBride MA, Rother KI et al: Survival after pancreas transplantation in patients with diabetes and preserved kidney function. *JAMA*, 2003; 290(21): 2817–23
- Gruessner RW, Sutherland DE, Gruessner AC: Mortality assessment for pancreas transplants. *Am J Transplant*, 2004; 4(12): 2018–26
- Troppmann C, Gruessner AC, Benedetti E, Papalois BE, Dunn DL, Najarian JS, et al: Vascular graft thrombosis after pancreatic transplantation: Univariate and multivariate operative and nonoperative risk factor analysis. *J Am Coll Surg*, 1996; 182(4): 285–316
- Gruessner AC: 2011 update on pancreas transplantation: comprehensive trend analysis of 25,000 cases followed up over the course of twenty-four years at the International Pancreas Transplant Registry (IPTR). *Rev Diabet Stud*, 2011; 8(1): 6–16
- Horneland R, Paulsen V, Lindahl JP et al: Pancreas transplantation with enteroanastomosis to native duodenum poses technical challenges – but offers improved endoscopic access for scheduled biopsies and therapeutic interventions. *Am J Transplant*, 2015; 15(1): 242–50
- Walter M, Jazra M, Kykalos S et al: 125 Cases of duodenoduodenostomy in pancreas transplantation: A single-centre experience of an alternative enteric drainage. *Transpl Int*, 2014; 27(8): 805–15
- Escolar G, Diaz-Ricart M, Cases A: Uremic platelet dysfunction: Past and present. *Curr Hematol Rep*, 2005; 4(5): 359–67
- Wisel SA, Braun HJ, Stock PG: Current outcomes in islet versus solid organ pancreas transplant for beta-cell replacement in type 1 diabetes. *Curr Opin Organ Transplant*, 2016; 21(4): 399–404
- Fridell JA, Powelson JA, Kubal CA et al: Retrieval of the pancreas allograft for whole-organ transplantation. *Clin Transplant*, 2014; 28(12): 1313–30
- Ryu JH, Lee TB, Park YM et al: Pancreas transplant with duodeno-duodenostomy and caval drainage using a diamond patch graft: A single-center experience. *Ann Transplant*, 2017; 22: 24–34
- Axelrod DA, Sung RS, Meyer KH et al: Systematic evaluation of pancreas allograft quality, outcomes and geographic variation in utilization. *Am J Transplant*, 2010; 10(4): 837–45
- Humar A, Ramcharan T, Kandaswamy R et al: Technical failures after pancreas transplants: why grafts fail and the risk factors – a multivariate analysis. *Transplantation*, 2004; 78(8): 1188–92
- Gruessner AC, Gruessner RW: Pancreas transplantation of US and non-US cases from 2005 to 2014 as reported to the United Network for Organ Sharing (UNOS) and the International Pancreas Transplant Registry (IPTR). *Rev Diabet Stud*, 2016; 13(1): 35–58
- Choi BH, Lee HY, Park YM et al: Formation of collateral veins in a graft pancreas after a simultaneous pancreas and kidney transplantation: A case report. *Transplant Proc*, 2015; 47(7): 2270–73
- Hakeem A, Chen J, Iype S et al: Pancreatic allograft thrombosis: Suggestion for a CT grading system and management algorithm. *Am J Transplant*, 2018; 18(1): 163–79
- Chien S, Usami S, Skalak R: Blood flow in small tubes. *Hand book of physiology, Section 2: The cardiovascular system*. 1984: 217–49
- Abdelaziz O, Attia H: Doppler ultrasonography in living donor liver transplantation recipients: Intra- and post-operative vascular complications. *World J Gastroenterol*, 2016; 22(27): 6145–72
- Ko EY, Kim TK, Kim PN: Hepatic vein stenosis after living donor liver transplantation: evaluation with Doppler US. *Radiology*, 2003; 229(3): 806–10
- Harbell JW, Morgan T, Feldstein VA et al: Splenic vein thrombosis following pancreas transplantation: Identification of factors that support conservative management. *Am J Transplant*, 2017; 17(11): 2955–62
- Han K, Ko HK, Tsauo J et al: Endovascular management for the treatment of pancreas transplant venous thrombosis: A single-center experience. *J Vasc Interv Radiol*, 2016; 27(6): 882–88
- Kim YH, Park JB, Lee SS et al: How to avoid graft thrombosis requiring graftectomy: Immediate posttransplant CT angiography in pancreas transplantation. *Transplantation*, 2012; 94(9): 925–30
- Laftavi MR, Gruessner A, Gruessner R: Surgery of pancreas transplantation. *Curr Opin Organ Transplant*, 2017; 22(4): 389–97
- Aboalsamh G, Anderson P, Al-Abbassi A et al: Heparin infusion in simultaneous pancreas and kidney transplantation reduces graft thrombosis and improves graft survival. *Clin Transplant*, 2016; 30(9): 1002–9

Conclusions

The fence angioplasty minimizes the narrowing of the venous anastomosis, which makes for low resistance of blood flow in the anastomotic site. This method also decreases the need to use heparin, which minimizes the risk of postoperative bleeding. Fence angioplasty is a simple but strong surgical technique that minimizes graft loss due to thrombosis.

Conflict of interest

None.