

Ultrasound-guided injection of the erector spinae enthesis for iliac crest pain syndrome

Sir,

A 40-year-old female patient applied to our clinic with chronic low back pain, especially on the left side of the lumbar spine, for the past 2 years. The pain was worse in a prolonged sitting position and during lateral bending of the trunk. Radiographs showed decreased lumbar lordosis with no facet pathologies. She denied any trauma and declared that oral anti-inflammatory drugs, massage, laser therapy, and low back school had been partially effective. Physical examination revealed intense pain on palpation of the paraspinal muscles and the posterior medial iliac crest on the left side. Active motions of the lumbar spine were painful especially during extension and right lateral bending. Straight leg raising and Wasserman tests were negative on both sides. Based on the clinical findings, the patient was diagnosed with chronic “nonspecific” low back pain with a remarkable myofascial pain component.

Due to the failure of previous conservative therapies, ultrasound (US) examination using a high-frequency linear probe (4–16 MHz) was performed to correctly identify the superficial painful structures (i.e., pain generators) before an eventual local injection therapy.^[1-3] With the probe positioned in a longitudinal oblique plane and using the posterior superior iliac spine as the bony landmark [Figure 1a], two muscular structures were identified under the thoracolumbar fascia: erector spinae muscle (ESM) and multifidus muscle [Figure 1b].^[4] Of note, at the sacral level, the ESM is mainly constituted of longissimus (thoracis) muscle with a small contribution from iliocostalis lumborum. Tilting the probe in the proximity of the painful site, the two components of erector spinae enthesis were visualized: the attachment sites of the erector spinae aponeurosis (ESA) and the deep tendon of the ESM [Figure 1b].

Based on the US findings, we planned the local injection in a craniocaudal direction [Figure 1b], using a 22-gauge needle (0.70 mm × 30 mm) and advancing it until the tendon-bone junction. The perientheseal injections were performed once a week for 2 weeks with a total volume of 4 mL for each procedure (2 mL of lidocaine hydrochloride 10 mg/mL and 2 mL of betamethasone disodium phosphate 4 mg/2 mL).

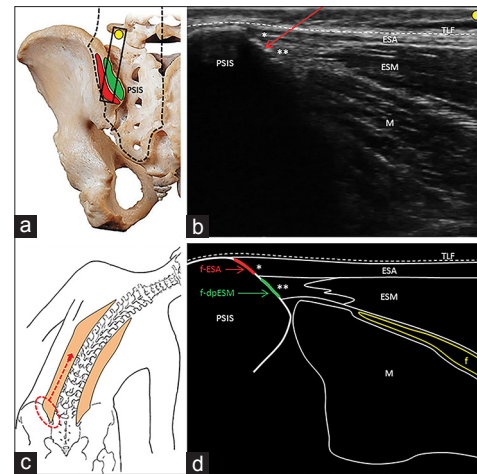


Figure 1: Black rectangle illustrates the probe positioning in the longitudinal oblique plane over the left posterior superior iliac spine. Black dotted line indicates the anatomical site of the erector spinae muscle. Red area shows the attachment site of the erector spinae aponeurosis and the green area shows the attachment site of the deep tendon of the erector spinae muscle. (a) Corresponding ultrasound image shows the thoracolumbar fascia (white dotted line), the erector spinae aponeurosis and its enthesis (single asterisk), the erector spinae muscle and its deep enthesis (double asterisks), the multifidus muscle (M) and the needle's direction in a craniocaudal direction (red arrow) (b). Schematic drawings show the lateral bending test eliciting pain over the opposite posterior medial iliac crest and the irradiation along the cranial portion of the erector spinae muscle (c); the footprint of the erector spinae aponeurosis (red line) and the footprint of the deep tendon of the erector spinae muscle (green line) over the posterior superior iliac spine (d). f = Fat tissue; f-ESA = Footprint of the erector spinae aponeurosis; f-dpESM = Footprint of the deep tendon of the erector spinae muscle

Betamethasone disodium phosphate has been used because it is a freely water soluble preparation (i.e., nonparticulate with no microcrystalline suspension)^[5] that has a high diffusion capacity and low risk of deposition inside soft tissues (which might otherwise cause iatrogenic damage to the enthesis). In addition, we also prescribed a personalized rehabilitation program with manual therapy and stretching focusing on the thoracolumbar fascia and the ESA. 4 weeks later, the patient reported a significant reduction of myofascial lumbar pain and improvement of active motion ranges of the lumbar spine [Figure 1c].

The iliac crest pain syndrome has been identified very frequently in patients with chronic “nonspecific” low back pain, and different authors showed that the principle pain generator coincides with the attachment site of the ESM to the posterior medial iliac crest [Figure 1d];^[6] alone or in combination with other painful anatomical structures such as the sacroiliac joint, (short and long) posterior sacroiliac ligaments, lumbar facet joints, superior cluneal nerves, and the trigger points of gluteal muscles.^[4] The latter is often associated with erector spinae enthesopathy; yet there is anatomical contiguity between the thoracolumbar fascia and the superficial fascia of gluteus maximus muscle.^[4]

In clinical practice, injections of the erector spinae entheses are not commonly performed due to the difficulty in identifying the aponeurotic and tendinous structures of the pelvic girdle by manual palpation. In this sense, we imply that “sonopalpation” can readily provide prompt visualization of the (painful) attachment sites of the ESM for safer interventions. This way, any vascular (e.g., bleeding), neural (e.g., superior cluneal nerve injury), or tendinous (e.g., intratendinous steroid injection) complications can easily be avoided as well. Last but not least, US examination can also allow the physician to readily evaluate the eventual fibro-adipose changes within the paraspinal muscles (e.g., reduced thickness and increased echogenicity)^[7] which would also/possibly contribute to the “nonspecific” low back pain of the patient.

Declaration of patient consent

The authors certify that they have obtained all appropriate patient consent forms. In the form the patient(s) has/have given his/her/their consent for his/her/their images and other clinical information to be reported in the journal. The patients understand that their names and initials will not be published and due efforts will be made to conceal their identity, but anonymity cannot be guaranteed.

Financial support and sponsorship

Nil.

Conflicts of interest

There are no conflicts of interest.

Vincenzo Ricci¹, Levent Özçakar²

¹Department of Biomedical and Neuromotor Science, Physical and Rehabilitation Medicine Unit, IRCCS Rizzoli Orthopaedic Institute, Bologna, Italy, ²Department of Physical and Rehabilitation Medicine, Hacettepe University Medical School, Ankara, Turkey

Address for correspondence: Dr. Vincenzo Ricci, Department of Biomedical and Neuromotor Science, Physical and Rehabilitation Medicine Unit, IRCCS Rizzoli Orthopaedic Institute, Bologna, Italy.
E-mail: vincenzo.ricci58@gmail.com

REFERENCES

1. Chang KV, Lin CP, Lin CS, Wu WT, Karmakar MK, Özçakar L, *et al.* Sonographic tracking of trunk nerves: Essential for ultrasound-guided pain management and research. *J Pain Res* 2017;10:79-88.
2. Gürçay E, Kara M, Kaymak B, Soyulu AR, Özçakar L. Prompt sonographic scanning and quantification of lumbar muscles: Seeing the butterfly. *Scand J Med Sci Sports* 2018;28:1314.
3. Can B, Kara M, Kara Ö, Ülger Z, Frontera WR, Özçakar L, *et al.* The value of musculoskeletal ultrasound in geriatric care and rehabilitation. *Int J Rehabil Res* 2017;40:285-96.
4. Willard FH, Vleeming A, Schuenke MD, Danneels L, Schleip R. The thoracolumbar fascia: Anatomy, function and clinical considerations. *J Anat* 2012;221:507-36.
5. MacMahon PJ, Eustace SJ, Kavanagh EC. Injectable corticosteroid and local anesthetic preparations: A review for radiologists. *Radiology* 2009;252:647-61.
6. Todorov P, Nestorova R, Batalov A. The sonoanatomy of lumbar erector spinae and its iliac attachment – The potential substrate of the iliac crest pain syndrome, an ultrasound study in healthy subjects. *J Ultrason* 2018;18:16-21.
7. Chang KV, Wu WT, Huang KC, Jan WH, Han DS. Limb muscle quality and quantity in elderly adults with dynapenia but not sarcopenia: An ultrasound imaging study. *Exp Gerontol* 2018;108:54-61.

This is an open access journal, and articles are distributed under the terms of the Creative Commons Attribution-NonCommercial-ShareAlike 4.0 License, which allows others to remix, tweak, and build upon the work non-commercially, as long as appropriate credit is given and the new creations are licensed under the identical terms.

Access this article online

Quick Response Code:



Website:

www.jmsjournal.net

DOI:

10.4103/jrms.JRMS_1034_18

How to cite this article: Ricci V, Özçakar L. Ultrasound-guided injection of the erector spinae entheses for iliac crest pain syndrome. *J Res Med Sci* 2019;24:69.

© 2019 Journal of Research in Medical Sciences | Published by Wolters Kluwer -Medknow