

# Sternoclavicular Joint Reconstruction in the Setting of Medial Comminuted Clavicle Fracture



George Sanchez, B.S., Nicholas I. Kennedy, M.D., Márcio B. Ferrari, M.D.,  
Angela Chang, B.S., and Matthew T. Provencher, M.D., M.C., U.S.N.R.

---

**Abstract:** A dislocation of the sternoclavicular joint is a particularly threatening injury given the close proximity of neighboring vital structures. Moreover, a traumatic injury resulting in a comminuted fracture of the medial clavicle in addition to joint instability results in even greater complexity. In the setting of sternoclavicular joint instability, definitive treatment that will lead to complete resolution of symptoms is necessary. Various treatment methods, both conservative and operative, with positive treatment outcomes have been described. The aim of this Technical Note is to describe our preferred surgical technique to treat a medial comminuted clavicle fracture with anterior sternoclavicular joint instability.

---

The sternoclavicular (SC) joint is a synovial joint that connects the upper extremity with the axial skeleton and contributes to range of motion during humeral elevation as well as glenohumeral and scapulothoracic motion.<sup>1,2</sup> Several ligaments stabilize the joint and restrain against anterior-posterior translation, superior-inferior rotation, and medial-lateral displacement.<sup>3,4</sup> A sectioning study on the ligamentous structures and capsular restraints suggest that the posterior capsule is the primary stabilizer of the joint; in fact, disruption of this capsule results in significant increases in anterior and posterior translation of the joint, including increases of 41% and 106%, respectively.<sup>3</sup>

Given the close proximity of the mediastinum to the joint, a strong understanding of sternoclavicular joint anatomy and mediastinal structures is essential. The nearby mediastinal structures are also susceptible to injuries if the SC joint experiences an instability event, particularly during a posterior dislocation. Fortunately, anterior dislocations of the SC joint are more common and less life-threatening given that an anteriorly displaced clavicle would not come into close contact with vital mediastinal structures.<sup>5</sup> Various treatment options ranging from conservative treatment with closed reduction as the first line of management to surgical treatment have been described. In cases of severe and/or recurrent SC joint instability cases, surgical treatment may be warranted.<sup>5-7</sup> The aim of this Technical Note is to describe our preferred surgical technique to treat a medial comminuted clavicle fracture with anterior SC joint instability.

---

*From the Steadman Philippon Research Institute (G.S., N.I.K., M.B.F., A.C., M.T.P.) and The Steadman Clinic (M.T.P.), Vail, Colorado, U.S.A.*

*The investigation was performed at the Steadman Philippon Research Institute, Vail, Colorado, U.S.A.*

*The authors report the following potential conflicts of interest or sources of funding: M.T.P. is a consultant for Arthrex and JRF Ortho; has the following patents issued: 9226743, 20150164498, 20150150594, and 20110040339; receives publishing royalties from Arthrex and SLACK. Full ICMJE author disclosure forms are available for this article online, as [supplementary material](#).*

*Received March 16, 2017; accepted May 21, 2017.*

*Address correspondence to Matthew T. Provencher, M.D., M.C., U.S.N.R., Steadman Philippon Research Institute, The Steadman Clinic, 181 West Meadow Drive, Suite 400, Vail, CO 81657, U.S.A. E-mail: [mprovencher@thesteadmanclinic.com](mailto:mprovencher@thesteadmanclinic.com)*

© 2017 by the Arthroscopy Association of North America  
2212-6287/17346/\$36.00

<http://dx.doi.org/10.1016/j.eats.2017.05.026>

## Surgical Technique

First, antibiotics are administered in the holding room prior to surgery ([Video 1](#)). The patient is brought to the operating room and then placed under light anesthesia. After this, the patient is placed in the beach chair position with a towel roll placed under the spine centrally. All bony prominences are well padded. The operative arm is then prepped and draped in standard fashion with the head at a slight 5° tilt. Once prepped and draped, the SC joint can be identified all the way down to the sternum and prepped in 3M Ioban Antimicrobial Incise Drapes. A surgical timeout is then taken before beginning the procedure.

**Table 1.** Pearls and Pitfalls

Pearls	Pitfalls
As the distal 2 cm of the clavicle is skeletonized using an elevator bluntly, a Darrach retractor should be used to protect the posterior structures	The lack of a Darrach retractor may result in a potential injury of a posterior neurovascular structure
A 2.5- to 3-mm high-speed burr should be used to make two 4-mm drill tunnels through the clavicle and sternum	Inappropriate drilling of the tunnels for reconstruction of the joint heightens the risk of fracture and, ultimately, surgical failure
Two unicortical PEEK (polyether ether ketone) screws are needed to provide optimal fixation of the graft through the sternum	Lack of screws (i.e., accessory fixation) may lead to recurrence in instability and postoperative failure requiring revision surgery
A vascular surgeon needs to be on standby during the procedure in case of a medical emergency	

### Initial Approach

Because of the nearby neurovascular structures, a vascular surgeon should be on standby during the case given the high potential for complications (Table 1). Using relevant bony landmarks, the right sternoclavicular and manubriosternal joints are identified. All borders are marked using a surgical pen. A line is drawn starting at the medial aspect of the right clavicle and extending distally to the manubriosternal joint (Fig 1).

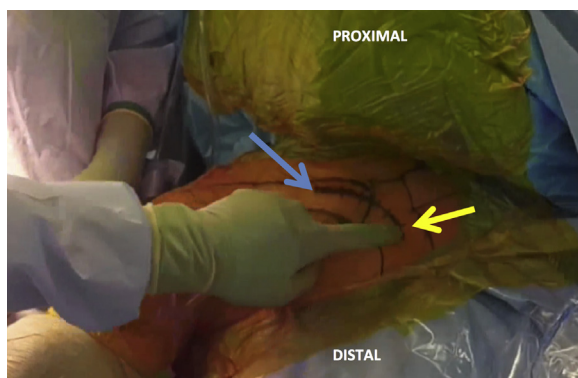
To fully expose the joint, a hockey stick–type incision is made directly over the end of the clavicle extending 5 cm medially and approximately 4 cm inferiorly down to the sternum. After the initial incision, Metzenbaum scissors and a needle-tip Bovie are used to make a flap of periosteum.

At this point, with direct visualization of the anterior aspect of the SC joint, the overall state of the joint can be assessed. If the capsule is intact, a vertical incision can then be made over the anterior aspect. After this, the state of the intra-articular disc may be evaluated and, if significantly worn, thin, or damaged, it cannot be used for capsular closure. If, however, it is mostly intact with an appropriate amount of thickness, then it can be used for capsular closure. Afterward, attention can be turned to the medial clavicular fracture. If

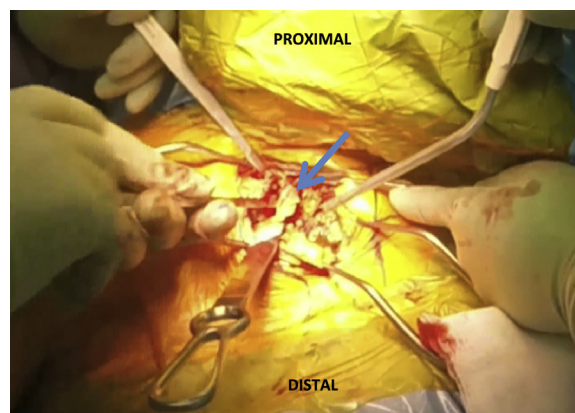
possible, the fracture should be fixated; however, if the fragment is severely comminuted as in this case, and fixation is not possible, then the goal should be complete resection (Fig 2). To remove all comminuted portions, the medial 2 cm of the clavicle is then skeletonized (Table 1) and excised while using an elevator bluntly while taking care to protect the posterior structures with a Darrach retractor. The angle of the distal clavicle medial to lateral should be preserved while also taking care to not damage any structures posterior to the joint. After this, a combination of a rongeur and rasp is used to smooth the edges of the clavicle. Once this portion of the technique is completed, joint stabilization can be assessed. Once fully evaluated, the operative plan is confirmed.

### Allograft and Sternoclavicular Joint Preparation

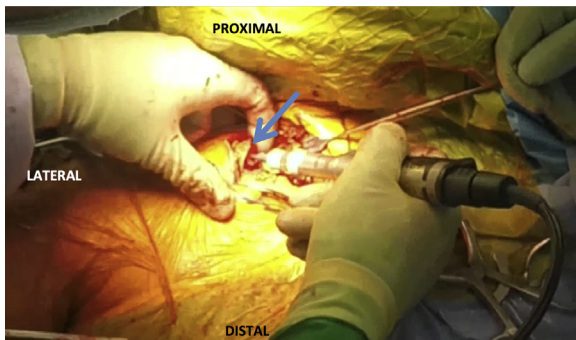
A 5-mm tibialis anterior allograft is then prepared with high-strength no. 2 suture (Arthrex, Naples, FL) on the back table while the attending surgeon completes full exposure of the joint. Once the allograft is prepared and the joint is thoroughly exposed, a 2.5- to 3-mm high-speed burr (Arthrex) is used to create a drill tunnel approximately 4 mm in length into the clavicle about 18 mm from the distal end of the clavicle



**Fig 1.** Using relevant bony landmarks, the right sternoclavicular and manubriosternal joints are identified. All borders are marked using a surgical pen. A line is drawn starting at the medial aspect of the right clavicle (blue arrow) and extending distally to the manubriosternal joint (yellow arrow).



**Fig 2.** Once the right sternoclavicular joint is fully exposed, attention is turned to the medial clavicular fragment (blue arrow). If possible, the fragment should be fixated. However, in the setting of a comminuted fracture near the sternoclavicular joint, a resection may be necessary.

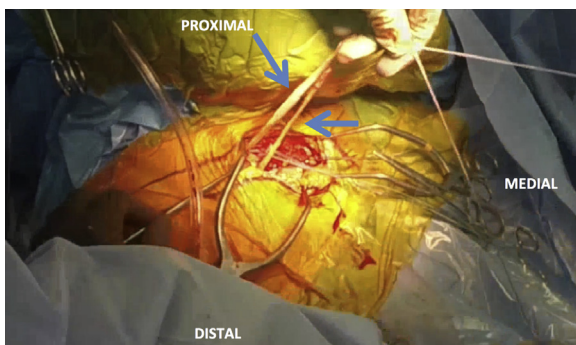


**Fig 3.** After resection of the medial fragment, the medial border of the right clavicle (blue arrow) is exposed. A tunnel is then formed extending through the intramedullary canal in a medial to anterior direction.

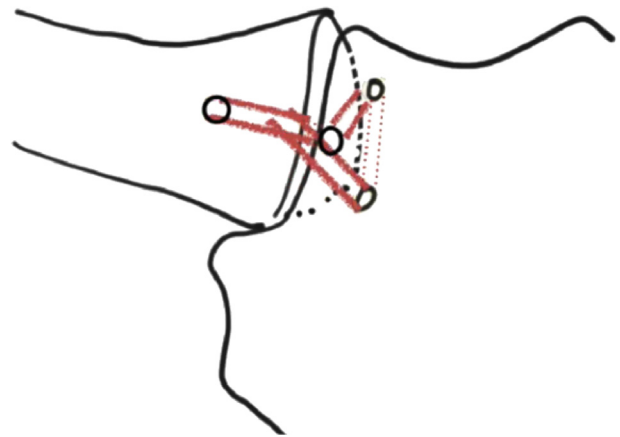
(Table 1). Then, the same burr is used to open the intramedullary canal from the distal clavicular end (Fig 3). Once the clavicle drill tunnel has been fully formed, another 4-mm drill tunnel is drilled with a burr into the sternum from medial to lateral and exiting anteriorly. In preparation for passage of the tibialis anterior allograft, stay sutures are passed through each previously formed drill tunnel.

#### Graft Passage Through Drill Tunnels

The graft is first passed around the clavicle and a half-hitch knot is formed. Afterward, the graft is docked into the drill tunnel and passed through the intramedullary canal until it exits out the medial end of the clavicle (Fig 4). Once the graft is passed through the clavicle, it is then passed through the drill tunnel made from medial to lateral in the sternum. The graft is passed until it exits the sternum anteriorly. Once the graft has been passed through the clavicle and sternum, the joint is fully reduced by pulling both ends of the graft. The graft is then fixed into the sternum with 2 unicortical PEEK



**Fig 4.** Two tunnels, approximately 4 mm in length, are then formed in both the sternum and clavicle on the right side. The allograft (blue arrow) that was previously prepared on the back table is then passed through the tunnels, beginning first in the clavicle. After this, the graft is passed through the sternum.



**Fig 5.** The final position of the graft in this right sternoclavicular joint is demonstrated. The solid and dotted red lines represent the position of the graft throughout the tunnels of the clavicle and sternum.

(polyether ether ketone) tenodesis screw  $5.5 \times 8.0$  mm (Arthrex) into each exit of the drill tunnel (Table 1). Screw size should be picked to ensure there is no posterior penetration and damage of any nearby structures.

Once the graft is fixed into position with the unicortical PEEK tenodesis screws, high-strength FiberTape (Arthrex) is then used to stitch the graft over itself in a figure-of-eight fashion. Once the graft is fixed into center (Fig 5), all knots are carefully buried. The stability of the joint is then verified through palpitation at the medial clavicle and sternum. Once the stability is fully assessed, closure can be performed.

#### Closure in Layered Fashion

The site should then be copiously irrigated. The fascia and remainder of the capsule can then be closed with high-strength no. 2 Suture (Arthrex), then closed in a standard, layered fashion with no. 2-0 Monocryl (Ethicon, Somerville, NJ), no. 3-0 Monocryl (Ethicon), Dermabond (Ethicon), and Steri-Strips (3M).

**Table 2.** Advantages and Disadvantages

Advantages	Disadvantages
Provides an anatomic reconstruction of the joint unlike other treatment options	Final fixation with 2 PEEK (polyether ether ketone) tenodesis screws may not offer the greatest amount of strength
Fully resolves instability with reinforcement of the relationship between the clavicle and sternum unlike conservative management	Although minimal, risk of damage to a posterior neurovascular structure is possible
Minimal potential damage to proximal neurovascular structures especially with use of appropriate retractors to keep structures safe	

Advantages and disadvantages of our preferred technique are listed in Table 2.

### Postoperative Plan

Patient should be admitted to hospital for overnight observance. The patient should be in a sling for 6 weeks, and allowed to do passive range of motion in the scapular plane, under supervision. The patient is then placed in a progressive rehabilitation program for approximately 3 to 4 months. Follow-up should be scheduled for 1 to 2 weeks after the postoperative date.

### Discussion

A dislocation of the SC joint is an uncommon injury that accounts for only 3% of all dislocations around the shoulder, with anterior dislocations 9 times more common than posterior dislocations.<sup>8</sup> However, as a result of the rarity of the injury, debate remains regarding the exact treatment that should be undertaken after an SC joint dislocation. Therefore, it is first important to evaluate the patient for symptoms of tracheal, esophageal, vascular, and neurologic damage of the mediastinal structures as well as a potential brachial plexus injury during physical examination on presentation. Although these complications are rare, they occur in approximately 30% of posterior SC joint dislocations, with a mortality rate between 3% and 4%.<sup>9</sup>

In the acute setting, most anterior dislocations are managed conservatively with closed reduction followed by immobilization.<sup>10,11</sup> The reduction can be performed with the affected arm in 90° of abduction while applying a direct force on the medial aspect of the clavicle.<sup>12</sup> A systematic review of 251 dislocations in 24 case series reported that closed reduction for both anterior and posterior dislocation may result in a successful postoperative outcome.<sup>13</sup> Despite good outcomes reported after conservative management for anterior dislocation of the SC joint, these injuries are inherently unstable and may require surgical treatment for fixation. Instability, in the absence of pain or discomfort, can continue to be managed conservatively. However, pain with activities of daily living and recurrent instability of the joint are indications for surgical treatment.

The optimal surgical technique for fixation is still debatable because of lack of long-term follow-up studies. Fixation involving screws and Kirschner wires have both been found adverse, with screws demonstrating biomechanically unfavorable results<sup>14</sup> and Kirschner wires possibly leading to a fatal migration.<sup>15</sup> However, aside from fixation with screws and Kirschner wires, suture anchor fixation, plating, reconstruction through autologous tendon repair using a figure-of-eight technique, sternocleidomastoid fascia grafting, and joint capsule and disc fixation have all

been previously described.<sup>6,16-19</sup> Of all techniques, Spencer et al.<sup>3</sup> found that the use of an autograft to complete a figure-of-eight fixation technique is the strongest of 3 reconstruction techniques biomechanically evaluated.

Although long-term follow-up studies are needed to determine the optimal surgical treatment, we believe our technique provides adequate stabilization of the SC joint in the setting of a medial comminuted clavicle fracture with anterior joint instability.

### References

1. Negri JH, Malavolta EA, Assuncao JH, et al. Assessment of the function and resistance of sternoclavicular ligaments: A biomechanical study in cadavers. *Orthop Traumatol Surg Res* 2014;100:727-731.
2. Renfree KJ, Wright TW. Anatomy and biomechanics of the acromioclavicular and sternoclavicular joints. *Clin Sports Med* 2003;22:219-237.
3. Spencer EE, Kuhn JE, Huston LJ, Carpenter JE, Hughes RE. Ligamentous restraints to anterior and posterior translation of the sternoclavicular joint. *J Shoulder Elbow Surg* 2002;11:43-47.
4. Bearn JG. Direct observations on the function of the capsule of the sternoclavicular joint in clavicular support. *J Anat* 1967;101:159-170.
5. Groh GI, Wirth MA. Management of traumatic sternoclavicular joint injuries. *J Am Acad Orthop Surg* 2011;19:1-7.
6. Bae DS, Kocher MS, Waters PM, Micheli LM, Griffey M, Dichtel L. Chronic recurrent anterior sternoclavicular joint instability: Results of surgical management. *J Pediatr Orthop* 2006;26:71-74.
7. Guan JJ, Wolf BR. Reconstruction for anterior sternoclavicular joint dislocation and instability. *J Shoulder Elbow Surg* 2013;22:775-781.
8. Rowe CR, Marble HC. Shoulder girdle injuries. In: Cave E, ed. *Fractures and other injuries*. Chicago: Year Book Publishers, 1958;250-259.
9. Nettles JL, Linscheid RL. Sternoclavicular dislocations. *J Trauma* 1968;8:158-164.
10. de Jong KP, Sukul DM. Anterior sternoclavicular dislocation: A long-term follow-up study. *J Orthop Trauma* 1990;4:420-423.
11. Wettstein M, Borens O, Garofalo R, Kombot C, Chevalley F, Mouhsine E. Anterior subluxation after reduction of a posterior traumatic sterno-clavicular dislocation: A case report and a review of the literature. *Knee Surg Sports Traumatol Arthrosc* 2004;12:453-456.
12. Morell DJ, Thyagarajan DS. Sternoclavicular joint dislocation and its management: A review of the literature. *World J Orthop* 2016;7:244-250.
13. Glass ER, Thompson JD, Cole PA, Gause TM 2nd, Altman GT. Treatment of sternoclavicular joint dislocations: A systematic review of 251 dislocations in 24 case series. *J Trauma* 2011;70:1294-1298.
14. Dutta AK, Wirth MA, Rockwood CA Jr. Sternoclavicular Joint Injuries. In: Rockwood CA, Bucholz RW, Court-Brown CM, Heckman JD, Tornetta P, eds. *Rockwood*

- and Green's fractures in adults*. Vol 7. Philadelphia: Lippincott Williams & Wilkins, 2010.
15. Kumar P, Godbole R, Rees GM, Sarkar P. Intrathoracic migration of a Kirschner wire. *J R Soc Med* 2002;95:198-199.
  16. Friedrich L, Affi FK, Skarvan J, Friederich NF, Hirschmann MT. Combined gracilis tendon autograft reconstruction and discus repair of a chronic anterior-superior sternoclavicular joint dislocation. *Knee Surg Sports Traumatol Arthrosc* 2012;20:1978-1982.
  17. Armstrong AL, Dias JJ. Reconstruction for instability of the sternoclavicular joint using the tendon of the sternocleidomastoid muscle. *J Bone Joint Surg Br* 2008;90:610-613.
  18. Abiddin Z, Sinopidis C, Grocock CJ, Yin Q, Frostick SP. Suture anchors for treatment of sternoclavicular joint instability. *J Shoulder Elbow Surg* 2006;15:315-318.
  19. Burrows HJ. Tenodesis of subclavius in the treatment of recurrent dislocation of the sterno-clavicular joint. *J Bone Joint Surg Br* 1951;33:240-243.