

[CASE REPORT]

Successful Re-administration of Atezolizumab for a Non-small-cell Lung Cancer Patient after Cardiac Tamponade Development as a Manifestation of Pseudo-progression Induced by Combination Treatment with Atezolizumab and Cytotoxic Chemotherapy

Koki Nakashima^{1,2}, Yoshiki Demura³, Masayuki Sato^{1,2}, Yuya Fujii¹,
Kazunari Igarashi¹ and Tamotsu Ishizuka²

Abstract:

Pseudo-progression is a phenomenon induced by treatment with immune checkpoint inhibitors and is characterized by an increase in tumor size or the appearance of new lesions, followed by tumor regression. However, life-threatening conditions, such as cardiac tamponade, can develop in such patients. We herein report on a 69-year-old man with lung adenocarcinoma who developed cardiac tamponade as a manifestation of pseudo-progression induced by treatment with atezolizumab combined with cytotoxic chemotherapy. After managing the cardiac tamponade, atezolizumab was successfully re-administered along with cytotoxic chemotherapy without disease progression.

Key words: immune checkpoint inhibitor, lung cancer, atezolizumab, cardiac tamponade, malignant pericardial effusion, pericardiocentesis

(Intern Med 60: 3009-3013, 2021)

(DOI: 10.2169/internalmedicine.6509-20)

Introduction

Immune checkpoint inhibitors (ICIs), such as anti-programmed cell death-1 (PD-1), anti-programmed cell death ligand-1 (PD-L1) and anti-cytotoxic T-lymphocyte antigen-4 (CTLA-4) antibodies, are effective treatment options for several types of cancers, including non-small cell lung cancer (NSCLC). However, ICIs can also cause atypical patterns of response, such as pseudo-progression. Although the tumor size on imaging typically increases during pseudo-progression, a reduction in true tumor size has recently been reported in those with this condition (1, 2). Hence, pseudo-progression is generally considered a positive predictor of NSCLC.

However, life-threatening responses, such as cardiac tamponade, can sometimes develop in patients with pseudo-

progression. While several studies (3-7) have reported cardiac tamponade as a manifestation of pseudo-progression induced by ICI monotherapy. However, no study has reported a case of pseudo-progression-induced cardiac tamponade induced by ICI treatment combined with cytotoxic chemotherapy. Hence, the appropriate treatments for such a condition remain unknown.

To our knowledge, this is the first report of pseudo-progression-induced cardiac tamponade caused by treatment with atezolizumab combined with cytotoxic chemotherapy, and the successful re-administration of atezolizumab after managing cardiac tamponade with pericardiocentesis.

Case Report

A 69-year-old man with a 40-year smoking history was referred to our hospital for the evaluation of abnormal chest

¹Department of Respiratory Medicine, Municipal Tsuruga Hospital, Japan, ²Third Department of Internal Medicine, Faculty of Medical Sciences, University of Fukui, Japan and ³Department of Respiratory Medicine, Japanese Red Cross Fukui Hospital, Japan

Received: October 14, 2020; Accepted: February 15, 2021; Advance Publication by J-STAGE: April 5, 2021

Correspondence to Dr. Koki Nakashima, kouk0527@yahoo.co.jp

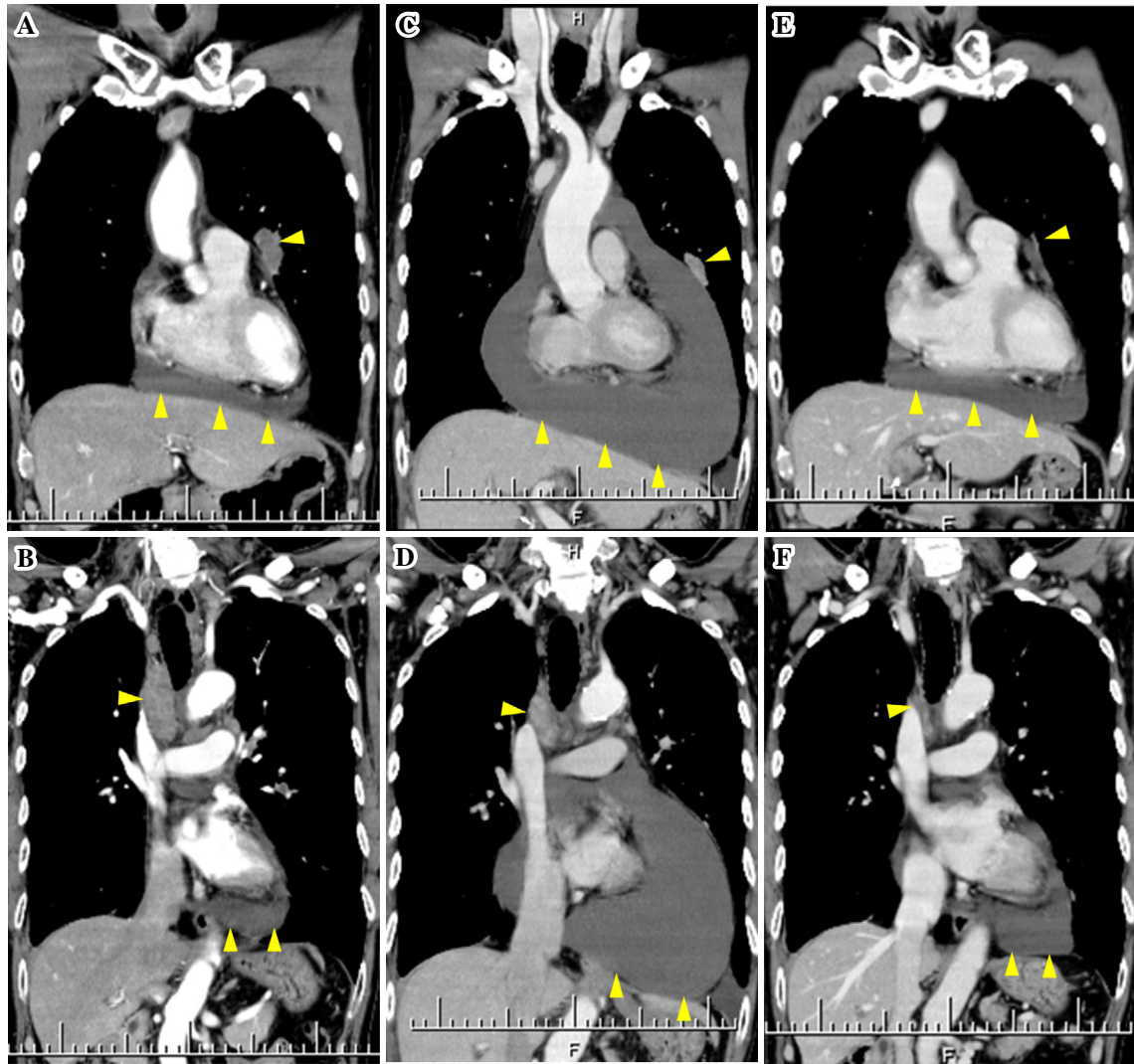


Figure 1. A, B: Chest contrast-enhanced computed tomography (CT) before the initiation of treatment showed the primary tumor in the left upper lung and mild pericardial effusion (A: arrows). It also showed swelling of the mediastinal lymph node (B: arrowhead). C, D: Chest contrast-enhanced CT at 20 days following the initiation of the first course of atezolizumab combined with cytotoxic chemotherapy showed an increasing pericardial effusion, while the size of the primary tumor was reduced (C: arrowheads). It also showed that the size of the mediastinal lymph node had decreased (D: arrowhead). E, F: Chest contrast-enhanced CT after the second course of treatment with carboplatin and nanoparticle albumin-bound paclitaxel (nab-PTX) showed that the size of the primary tumor in the left upper lung was dramatically reduced, and mild pericardial effusion was noted (E: arrowheads). In addition, the size of the mediastinal lymph node was reduced dramatically (F: arrowhead).

radiograph findings. The patient had no remarkable medical history, including autoimmune disorders. Chest computed tomography (CT) revealed a tumor measuring 45 mm in diameter in the left upper lung, swelling of the bilateral mediastinal lymph nodes and cervical lymph nodes, and a small amount of pericardial effusion (Fig. 1A, B). Positron emission tomography with 18-fluorodeoxyglucose (FDG-PET) also revealed an FDG uptake in the primary tumor and in multiple lymph nodes (Fig. 2). A transbronchial biopsy of the primary tumor showed a poorly differentiated adenocarcinoma. Endobronchial ultrasound-guided transbronchial needle aspiration (EBUS-TBNA) sampling of lymph node stations #4R and #7 also showed poorly differentiated ade-

nocarcinoma. Driver oncogenes, including the epidermal growth factor receptor (*EGFR*), anaplastic lymphoma kinase (*ALK*) fusion gene, and c-ros oncogene 1 (*ROS-1*) fusion gene, were negative. The PD-L1 tumor proportion score (TPS) was >75%. Based on these findings, the patient was diagnosed with advanced poorly differentiated adenocarcinoma of the lung (cT2aN3M1c: stage IVB), and treatment with carboplatin, nanoparticle albumin-bound paclitaxel (nab-PTX), and atezolizumab was initiated.

Twenty days after the initiation of the first course of treatment, hypotension and tachycardia occurred. Chest CT showed an increase in the amount of pericardial effusion, leading to the diagnosis of cardiac tamponade, although the

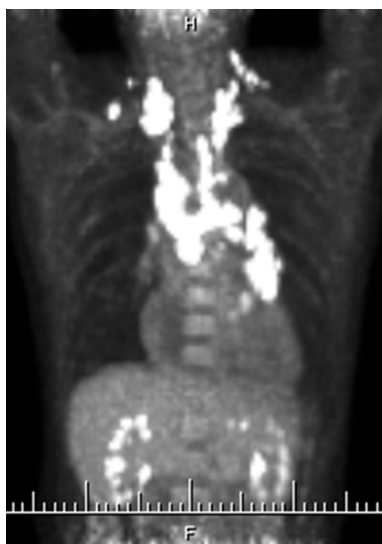

Figure 2. Positron emission tomography with 18-fluorodeoxyglucose (FDG-PET) revealed the uptake of FDG in the primary tumor and multiple lymph nodes, including cervical lymph nodes.

tumor size of other lesions was decreased (Fig. 1C, D). Emergency pericardial drainage was performed, and 1,660 mL of bloody pericardial fluid was extracted. Hypotension and tachycardia eventually improved. A cytological examination of the pericardial fluid confirmed the presence of adenocarcinoma. An analysis of the pericardial fluid revealed the following: pH 7.2, total cell count 3,153/ μ L (lymphocytes 36%, neutrophils 22%, histiocytes 10%, others 32%), protein 7.4 g/dL, glucose 13 mg/dL, and lactate dehydrogenase 11,401 IU/L. After removing the drainage tube, the second course of chemotherapy, carboplatin and nab-PTX without atezolizumab, was initiated. During the second course of treatment, the amount of pericardial effusion did not increase and the tumor size of other lesions decreased further (Fig. 1E, F). Hence, atezolizumab combined with carboplatin and nab-PTX was re-administered as the third course of treatment. Seven months have passed since the cardiac tamponade developed, and the patient is continuously receiving maintenance therapy with atezolizumab with no signs of disease progression, including pericardial effusion.

Discussion

The causes of cardiac tamponade after administration of ICI can be divided into three types: pseudo-progression, immune-related adverse events (irAEs) such as pericarditis, and disease progression, including hyperprogressive disease (3-10). Cardiac tamponade was considered as a manifestation of pseudo-progression in the present case for several reasons. First, the reaction occurred at the tumor lesion that had existed before treatment initiation. Pseudo-progression develops in preexisting lesions of the tumor; in some cases, pseudo-progression will appear in a new le-

sion (1, 2). Previous studies on cardiac tamponade induced by pseudo-progression also showed preexisting pericardial effusion (Table). Second, the tumor size of the other lesions was dramatically reduced. Although the exact reason for the different reactions between the pericardial effusion and other lesions is unclear, intratumoral heterogeneity of PD-L1 expression and differences in drug transferability to tissues are expected (11). In fact, several reports (shown in Table) (5-7) have described different reactions between the pericardial effusion and other lesions. Furthermore, some reports (12, 13) have also indicated that strong immune-related reactions tend to develop in patients with serositis, such as pleural or pericardial effusion. Hence, atezolizumab was re-administered after managing the cardiac tamponade. The successful re-administration of atezolizumab also suggests that cardiac tamponade was caused by pseudo-progression.

The clinical course of our patient suggests two important clinical issues. First, pseudo-progression can develop owing to ICI administration in combination with cytotoxic chemotherapy as well as in cases receiving an ICI alone. To our knowledge, this is the first case report of pseudo-progression caused by treatment with ICI combined with cytotoxic chemotherapy. In several clinical trials of ICIs for NSCLC patients, patients treated with an ICI alone had worse outcomes than those treated with cytotoxic chemotherapy within three to six months after the initiation of treatment (14, 15). In contrast, patients treated with an ICI combined with cytotoxic chemotherapy did not have worse outcomes than those treated with cytotoxic chemotherapy within a few months after the initiation of treatments (16-19). These results indicated that early immune-related reaction, such as pseudo-progression or hyperprogressive disease, might lead to poor outcomes in the early stage. Furthermore, these results also suggested that combination treatments with ICI and cytotoxic chemotherapy might be effective for reducing early death caused by these phenomena. In fact, all patients were treated with ICI alone in previous studies on cardiac tamponade induced by pseudo-progression (3-7). However, the present case indicated that pseudo-progression can develop due to combination treatment with cytotoxic chemotherapy and ICIs. Clinicians should monitor not only patients treated with an ICI but also those treated with ICIs combined with cytotoxic chemotherapy for signs of pseudo-progression-induced cardiac tamponade, especially in cases with pre-existing pericardial effusion.

Second, it is possible to re-administer an ICI after the management of pseudo-progression-induced cardiac tamponade without the intrapericardial administration of bleomycin or oral administration of prednisolone. Although intrapericardial sclerotherapy is recommended as a treatment for malignant pericardial effusion (20, 21), the appropriate management of cardiac tamponade as a manifestation of pseudo-progression remains unknown. Intrapericardial sclerotherapy is used to combine the visceral pericardium with the parietal pericardium by inflammation which is induced by some

Table. Details of Cases of Pseudo-progression Induced Cardiac Tamponade.

No.	Age	Sex	Histologic subtype	PD-L1 (%)	Drugs	Pre-existing pericardial effusion	Cycles at presentation (times)	Lymphocyte proportion in the pericardial fluid (%)	Interventions	Re-administration of ICI	Ref
1	62	M	adenocarcinoma	90	Nivolumab	Yes	1	unknown	Pericardiocentesis, Intrapericardial bleomycin	Yes	3
2	54	F	adenocarcinoma	unknown	Nivolumab	Yes	3	30	Pericardiocentesis, Prednisolone	No	4
3	46	M	SCLC	unknown	Nivolumab	Yes	4	5	Pericardiocentesis	Yes	4
4	65	M	adenocarcinoma	unknown	Nivolumab	Yes	4	84	Pericardiocentesis	Yes	5
5	71	M	adenocarcinoma	unknown	Nivolumab	Yes	2	2	Pericardiocentesis	No	5
6	63	F	adenocarcinoma	90<	Pembrolizumab	Yes	4	very few	Pericardiocentesis	Yes	6
7	70	M	adenocarcinoma	90<	Pembrolizumab	No	6	26	Pericardiocentesis	Yes	7
Present Case	69	M	adenocarcinoma	75<	Atezolizumab (with cytotoxic chemotherapy)	Yes	1	36	Pericardiocentesis	Yes	

agents such as bleomycin. However, a previous report indicated that the use of such a treatment may trigger the development of severe irAEs (22). The other patient with pseudo-progression-induced cardiac tamponade was treated with administration of prednisolone as an irAE was also suspected, in a case reported by Bhasker et al. (4). However, corticosteroids may decrease the efficacy of ICIs (23). Therefore, treatments, such as intrapericardial sclerotherapy and the administration of prednisolone, should be avoided in patients who are suspected of having pseudo-progression-induced cardiac tamponade. Several studies (4-7), including the present case, have encouraged clinicians to re-administer ICIs after achieving management with only pericardiocentesis without intrapericardial sclerotherapy or prednisolone administration in patients with pseudo-progression-induced cardiac tamponade caused by initial treatment with ICI.

It is difficult to distinguish pseudo-progression, irAEs, and disease progression correctly. However, if cardiac tamponade is considered an irAE or a sign of disease progression, ICI therapy should be discontinued. In contrast, if pseudo-progression is misdiagnosed as an irAE or disease progression, patients may miss opportunities to achieve a long-term survival with ICI therapy. In fact, several studies have indicated that patients with pseudo-progression showed significantly better outcomes than those without pseudo-progression (24, 25). Furthermore, the high PD-L1 TPS (>75%) was also the reason for our decision to re-administer ICI in the present case. Several studies (26, 27) have reported that a high PD-L1 TPS (>50%) was associated with an overall survival benefit. Therefore, clinicians should carefully determine whether or not ICI treatment should be continued, while considering the clinical course and patient background characteristics, including the PD-L1 TPS.

While the association between the development of pseudo-progression and a high PD-L1 TPS is unclear, sev-

eral cases shown in Table, including the present case, have involved a high PD-L1 TPS. Pseudo-progression-induced cardiac tamponade tends to develop in patients with a high PD-L1 TPS. Furthermore, the lymphocyte proportion in pericardial effusion, which was 36% in the present case, may be useful for diagnosing pseudo-progression because the mechanisms of pseudo-progression include infiltration and recruitment of immune cells, including lymphocytes, into the tumor (1, 28). However, the lymphocyte proportion in previous reports (Table) was inconsistent, i.e., 2-86%. The further accumulation of the number of cases of pseudo-progression induced cardiac tamponade due to ICIs is necessary to confirm these findings.

In conclusion, we encountered a case of the successful re-administration of atezolizumab in a patient with NSCLC after the development of cardiac tamponade as a manifestation of pseudo-progression induced by the initial administration of atezolizumab combined with cytotoxic chemotherapy. We recommend that re-administration of the ICI be considered in patients who are suspected of having pseudo-progression-induced cardiac tamponade to achieve a long-term survival if regional management with pericardiocentesis is possible.

The authors state that they have no Conflict of Interest (COI).

Acknowledgement

We are also grateful to Dr. Yoshitaka Okabe for providing consultation and performing the pericardial drainage.

References

- Di Giacomo AM, Danielli R, Guidoboni M, et al. Therapeutic efficacy of ipilimumab, an anti-CTLA-4 monoclonal antibody, in patients with metastatic melanoma unresponsive to prior systemic treatments: clinical and immunological evidence from three patient cases. *Cancer Immunol Immunother* 58: 1297-1306, 2009.

2. Wolchok JD, Hoos A, O'Day S, et al. Guidelines for the evaluation of immune therapy activity in solid tumors: immune-related response criteria. *Clin Cancer Res* **15**: 7412-7420, 2009.
3. Asai M, Kato Y, Kawai S, et al. Management of cardiac tamponade during nivolumab of lung cancer with intrapericardial bleomycin: case report. *Immunotherapy* **11**: 467-472, 2019.
4. Kolla BC, Patel MR. Recurrent pleural effusions and cardiac tamponade as possible manifestations of pseudoprogression associated with nivolumab therapy- a report of two cases. *J Immunother Cancer* **4**: 80, 2016.
5. Yamasaki M, Daido W, Saito N, et al. Pericardial effusion with tamponade in lung cancer patients during treatment with nivolumab: a report of two cases. *Front Oncol* **9**: 4, 2019.
6. Harada K, Ogasawara M, Shido A, et al. Pericardial tamponade during pembrolizumab treatment in a patient with advanced lung adenocarcinoma: a case report and review of the literature. *Thoracic Cancer* **11**: 1350-1353, 2020.
7. Tachihara M, Yamamoto M, Yumura M, Yoshizaki A, Kobayashi K, Nishimura Y. Non-parallel anti-tumour effects of pembrolizumab: a case of cardiac tamponade. *Respirol Case Rep* **7**: e00404, 2019.
8. Kushnir I, Wolf I. Nivolumab-induced pericardial tamponade: a case report and discussion. *Cardiology* **136**: 49-51, 2017.
9. de Almeida DVP, Gomes JR, Haddad FJ, Buzaid AC. Immune-mediated pericarditis with pericardial tamponade during nivolumab therapy. *J Immunother* **41**: 329-331, 2018.
10. Kim SH, Choi CM, Lee DH, et al. Clinical outcomes of nivolumab in patients with advanced non-small cell lung cancer in real-world practice, with an emphasis on hyper-progressive disease. *J Cancer Res Clin Oncol* **146**: 3025-3036, 2020.
11. Haragan A, Field JK, Davies MPA, Escriu C, Gruver A, Gosney JR. Heterogeneity of PD-L1 expression in non-small cell lung cancer: Implications for specimen sampling in predicting treatment response. *Lung Cancer* **134**: 79-84, 2019.
12. Kang DH, Chung C, Kim JO, et al. Pleural or pericardial metastasis: A significant factor affecting efficacy and adverse events in lung cancer patients treated with PD-1/PD-L1 inhibitors. *Thorac Cancer* **9**: 1500-1508, 2018.
13. Kanazu M, Edahiro R, Krebe H, et al. Hyperprogressive disease in patients with non-small cell lung cancer treated with nivolumab: a case series. *Thorac Cancer* **9**: 1782-1787, 2018.
14. Mok TSK, Wu YL, Kudaba I, et al. Pembrolizumab versus chemotherapy for previously untreated, PD-L1-expressing, locally advanced or metastatic non-small-cell lung cancer (KEYNOTE-042): a randomised, open-label, controlled, phase 3 trial. *Lancet* **393**: 1819-1830, 2019.
15. Herbst RS, Giaccone G, de Marinis F, et al. Atezolizumab for first-line treatment of PD-L1-selected patients with NSCLC. *N Engl J Med* **383**: 1328-1339, 2020.
16. Paz-Ares L, Luft A, Vicente D, et al. Pembrolizumab plus chemotherapy for squamous non-small-cell lung cancer. *N Engl J Med* **379**: 2040-2051, 2018.
17. Gandhi L, Rodríguez-Abreu D, Gadgeel S, et al. Pembrolizumab plus chemotherapy in metastatic non-small-cell lung cancer. *N Engl J Med* **378**: 2078-2092, 2018.
18. West H, McCleod M, Hussein M, et al. Atezolizumab in combination with carboplatin plus nab-paclitaxel chemotherapy compared with chemotherapy alone as first-line treatment for metastatic non-squamous non-small-cell lung cancer (IMpower130): a multicentre, randomised, open-label, phase 3 trial. *Lancet Oncol* **20**: 924-937, 2019.
19. Socinski MA, Jotte RM, Cappuzzo F, et al. Atezolizumab for first-line treatment of metastatic nonsquamous NSCLC. *N Engl J Med* **378**: 2288-2301, 2018.
20. Kunitoh H, Tamura T, Shibata T, et al. A randomised trial of intrapericardial bleomycin for malignant pericardial effusion with lung cancer (JCOG9811). *Br J Cancer* **100**: 464-469, 2009.
21. Maruyama R, Yokoyama H, Seto T, et al. Catheter drainage followed by the instillation of bleomycin to manage malignant pericardial effusion in non-small cell lung cancer: a multi-institutional phase II trial. *J Thorac Oncol* **2**: 65-68, 2007.
22. Sakata S, Matsuoka Y, Kawahara K, et al. Severe interstitial pneumonia associated with anti-PD-1 immune checkpoint antibody after talc slurry pleurodesis. *Respir Investig* **56**: 195-198, 2018.
23. Arbour KC, Mezquita L, Long N, et al. Impact of baseline steroids on efficacy of programmed cell death-1 and programmed death-ligand 1 blockade in patients with non-small-cell lung cancer. *J Clin Oncol* **36**: 2872-2878, 2018.
24. Won SE, Park HJ, Byun S, et al. Impact of pseudoprogression and treatment beyond progression on outcome in patients with non-small cell lung cancer treated with immune checkpoint inhibitors. *Oncoimmunology* **9**: 1776058, 2020.
25. Fujimoto D, Yoshioka H, Kataoka Y, et al. Pseudoprogression in previously treated patients with non-small cell lung cancer who received nivolumab monotherapy. *J Thorac Oncol* **14**: 468-474, 2019.
26. Reck M, Rodríguez-Abreu D, Robinson AG, et al. Updated analysis of KEYNOTE-024: pembrolizumab versus platinum-based chemotherapy for advanced non-small-cell lung cancer with PD-L1 tumor proportion score of 50% or greater. *J Clin Oncol* **37**: 537-546, 2019.
27. Fehrenbacher L, von Pawel J, Park K, et al. Updated efficacy analysis including secondary population results for OAK: a randomized phase III study of atezolizumab versus docetaxel in patients with previously treated advanced non-small cell lung cancer. *J Thorac Oncol* **13**: 1156-1170, 2018.
28. Forde PM, Chaft JE, Smith KN, et al. Neoadjuvant PD-1 blockade in resectable lung cancer. *N Engl J Med* **378**: 1976-1986, 2018.

The Internal Medicine is an Open Access journal distributed under the Creative Commons Attribution-NonCommercial-NoDerivatives 4.0 International License. To view the details of this license, please visit (<https://creativecommons.org/licenses/by-nc-nd/4.0/>).