



# Lessons Learnt from an 11-year Experience with Lymphatic Surgery and a Systematic Review of Reported Complications: Technical Considerations to Reduce Morbidity

Pedro Ciudad, MD, PhD<sup>1,2,3</sup> Joseph M. Escandón, MD<sup>4</sup> Oscar J. Manrique, MD, FACS<sup>4</sup>  
Valeria P. Bustos, MD<sup>5</sup>

<sup>1</sup> Department of Plastic, Reconstructive and Burn Surgery, Arzobispo Loayza National Hospital, Lima, Peru

<sup>2</sup> Department of Plastic and Reconstructive Surgery, China Medical University Hospital, Taichung, Taiwan

<sup>3</sup> Academic Department of Surgery, School of Medicine Hipolito Unanue, Federico Villarreal National University, Lima, Perú

<sup>4</sup> Division of Plastic and Reconstructive Surgery, Strong Memorial Hospital, University of Rochester Medical Center, Rochester, New York

<sup>5</sup> Division of Plastic and Reconstructive Surgery, Department of Surgery, Beth Israel Deaconess Medical Center, Harvard Medical University, Boston, Massachusetts

Address for correspondence Pedro Ciudad, MD, PhD, Department of Plastic, Reconstructive and Burn Surgery, Arzobispo Loayza National Hospital, Lima 1508, Peru (e-mail: pciudad@hotmail.com).

Arch Plast Surg 2022;49:227–239.

## Abstract

Complications experienced during lymphatic surgery have not been ubiquitously reported, and little has been described regarding how to prevent them. We present a review of complications reported during the surgical management of lymphedema and our experience with technical considerations to reduce morbidity from lymphatic surgery. A comprehensive search across different databases was conducted through November 2020. Based on the complications identified, we discussed the best approach for reducing the incidence of complications during lymphatic surgery based on our experience. The most common complications reported following lymphovenous anastomosis were re-exploration of the anastomosis, venous reflux, and surgical site infection. The most common complications using groin vascularized lymph node transfer (VLNT), submental VLNT, lateral thoracic VLNT, and supraclavicular VLNT included delayed wound healing, seroma and hematoma formation, lymphatic fluid leakage, iatrogenic lymphedema, soft-tissue infection, venous congestion, marginal nerve pseudoparalysis, and partial flap loss. Regarding intra-abdominal lymph node flaps, incisional hernia, hematoma, lymphatic fluid leakage, and postoperative ileus were commonly reported. Following suction-assisted lipectomy, significant blood loss and transient paresthesia were frequently reported. The reported complications of excisional procedures included soft-tissue infections, seroma and hematoma

## Keywords

- ▶ lymphedema
- ▶ intraoperative complications
- ▶ postoperative complications
- ▶ surgical procedures
- ▶ lymphatic vessels
- ▶ lymph nodes

DOI <https://doi.org/10.1055/s-0042-1744412>.  
ISSN 2234-6163.

© 2022. The Korean Society of Plastic and Reconstructive Surgeons. All rights reserved.

This is an open access article published by Thieme under the terms of the Creative Commons Attribution-NonDerivative-NonCommercial-License, permitting copying and reproduction so long as the original work is given appropriate credit. Contents may not be used for commercial purposes, or adapted, remixed, transformed or built upon. (<https://creativecommons.org/licenses/by-nc-nd/4.0/>)

Thieme Medical Publishers, Inc., 333 Seventh Avenue, 18th Floor, New York, NY 10001, USA

formation, skin-graft loss, significant blood loss, and minor skin flap necrosis. Evidently, lymphedema continues to represent a challenging condition; however, thorough patient selection, compliance with physiotherapy, and an experienced surgeon with adequate understanding of the lymphatic system can help maximize the safety of lymphatic surgery.

Recent developments in microsurgery and an improved understanding of the lymphatic system and the pathogenesis of lymphedema have prompted the introduction of novel surgical methods that offer physiologic surgical alternatives for the management of lymphedema.<sup>1,2</sup> For instance, lymphovenous anastomosis (LVA) has benefits including minimal invasiveness, optimal aesthetic outcomes, and lower costs in comparison to physical therapy; however, limited evidence reporting the clinical safety of LVA is currently available.<sup>3</sup> Although vascularized lymph node transfer (VLNT) has shown better long-term outcomes in terms of a greater likelihood of discontinuing compressive therapies,<sup>1</sup> when harvested from either the groin or supraclavicular region, iatrogenic lymphedema of the donor site can follow.<sup>4,5</sup> Although the omentum has provided an alternative for lymphatic tissue transfer, major concerns regarding donor site morbidity pose some obstacles to its ubiquitous use.<sup>6-8</sup>

Excisional surgical techniques are also available. The most common techniques include suction-assisted lipectomy (SAL), radical reduction with perforator preservation (RRPP), the Homan procedure, and the Charles procedure.<sup>9</sup> These techniques are usually indicated for patients with moderate to advanced lymphedema, yielding a high success rate. Nevertheless, pain, infection, lymphatic fistulas, severe wound breakdown, ulceration, and aggravation of lymphedema have been reported.<sup>9,10</sup> Herein, we present a systematic review of complications reported during the surgical management of lymphedema and our experience with technical considerations to prevent potential complications of lymphatic surgery.

## Methods

### Literature Search Strategy

This review was conducted in accordance with the Preferred Reporting Items for Systematic Reviews and Meta-Analyses (PRISMA) guidelines.<sup>11</sup> A comprehensive search of the medical indices PubMed, Ovid MEDLINE and In-Process & Other Non-Indexed Citations, Cochrane CENTRAL, and SCOPUS was performed from database inception through November 2020. The search strategy was designed and conducted by J.M.E. using the following terms: “complications,” “lymphedema,” “lymphoedema,” “lymph node,” “transfer,” “vascularized,” “transplant,” “lymphaticovenular,” “lymphovenous,” “anastomosis,” “liposuction,” and “subcutaneous excision” (see ► **Supplemental Digital Content 1** [available in the online version], which displays the search strategy used in different databases).

### Study Selection

Studies were included if they reported complications of lymphatic surgery using a specific technique and were written in English. Studies were excluded if they did not report postoperative outcomes and complications, or if the postoperative evolution was explicitly reported to be uneventful. Studies reporting cases of genital lymphedema or lymphatic malformations were also excluded.

### Data Pooling and Data Analysis

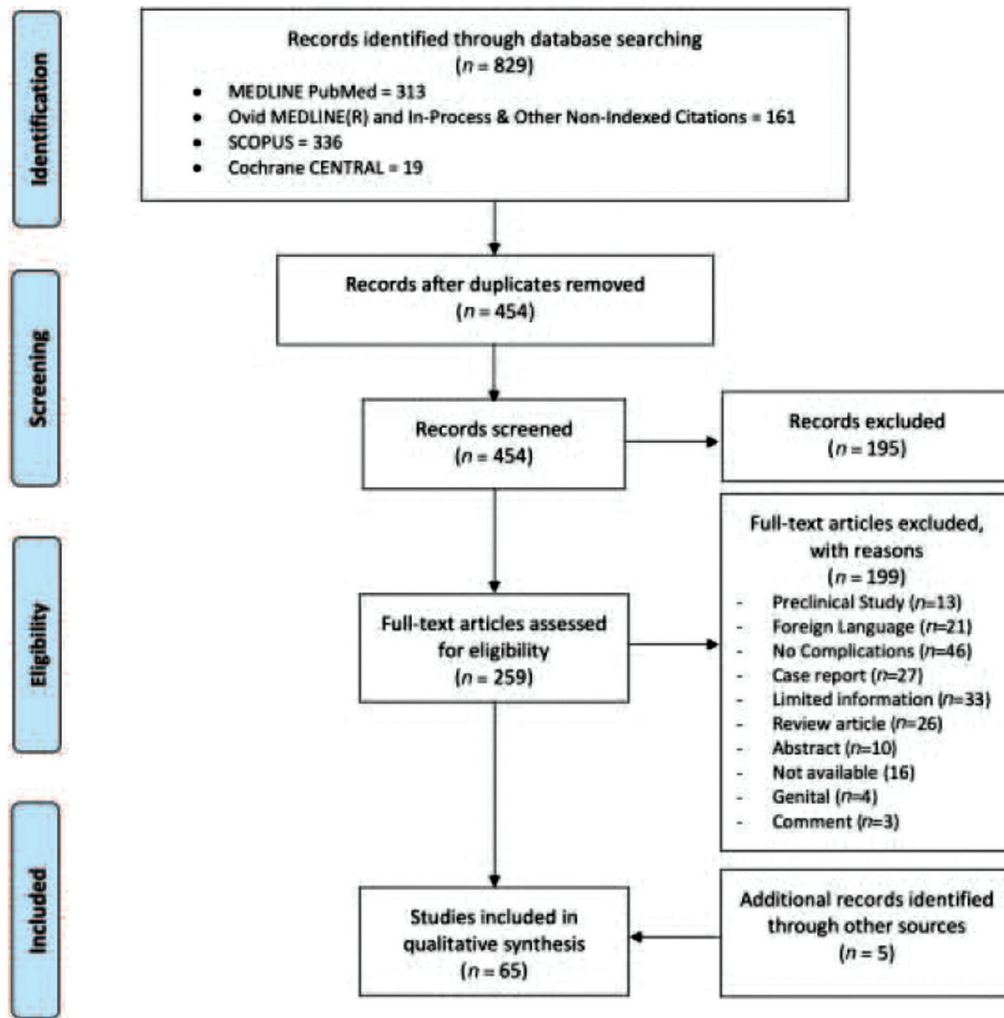
After duplicates were removed, two authors (J.M.E. and V.P.B.) independently screened the articles based on title and abstracts. Afterward, relevant studies underwent full-text assessment using the exclusion and inclusion criteria. Data extraction was performed independently by the same two authors. The variables selected to describe the studies included the following: author and year, type of study, cause of lymphedema, number of patients, age, lymphedema stage, duration of lymphedema, surgical technique, associated procedures, complications, and follow-up. Percentages in this review represented the proportion of the overall reported complications for each technique. Subsequently, several technical considerations on how to prevent complications of lymphatic surgery and the experience of the senior author (P.C.) were discussed based on the findings of this review.

## Results

After implementing the aforementioned search strategy, 829 references were identified. After duplicates were removed, 454 studies were evaluated based on title and abstract, and 195 were deemed irrelevant. Following full-text assessment of the remaining 259 studies, 60 articles were incorporated for qualitative data analysis. Five additional references were added during data extraction (► **Fig. 1**).

Thirteen articles reporting surgical complications of LVA were identified (see ► **Supplementary Table S1** [available in the online version], which displays an overview of the included studies).<sup>12-23</sup> A summary of the reported complications is exhibited in ► **Table 1**. The most common complications reported were re-exploration of the anastomosis ( $n = 22$ , 36.6%), venous reflux ( $n = 15$ , 24.6%), cellulitis or abscess ( $n = 9$ , 14.75%), seroma formation ( $n = 4$ , 6.55%), and lymphatic fluid leakage ( $n = 2$ , 3.27%).

Thirty-nine studies reporting surgical complications of VLNT were identified (see ► **Supplementary Table S2** [available in the online version], which displays an overview of the included studies).<sup>13,22,24-55</sup> The most common



**Fig. 1** Preferred reporting items for systematic reviews and meta-analyses flow diagram.

**Table 1** Reported complications of lymphovenous anastomosis

Complications	Number	Percentage
Revision of the anastomosis	22	36.0
Venous reflux	15	24.6
Cellulitis or abscess	9	14.75
Seroma	4	6.55
Ecchymoses	3	4.9
Recurrence	2	3.27
Lymphatic fluid leakage	2	3.27
Pneumonia	1	1.63
Partial skin necrosis	1	1.63
Pulmonary embolus	1	1.63
Neurapraxia	1	1.63

complications detailed after groin VLNT were donor site pain or numbness (*n* = 32, 26.8%), delayed wound healing (*n* = 16, 13.44%), seroma formation (*n* = 14, 11.76%), lymphatic fluid

leakage (*n* = 12, 10.08%), venous congestion (*n* = 9, 7.56%), and iatrogenic lymphedema (*n* = 5, 4.2%). When using lateral thoracic VLNT, iatrogenic lymphedema (*n* = 4, 30.76%), cellulitis (*n* = 2, 15.38%), and seroma and hematoma formation (*n* = 2, 15.38%) were also commonly reported. In patients treated with submental VLNT, the most common complications were venous congestion (*n* = 16, 42.1%), marginal nerve pseudoparalysis (*n* = 8, 21.05%), and partial flap loss (*n* = 7, 18.42%). In patients treated with supraclavicular VLNT, the presence of a congestive skin paddle (*n* = 4, 16%), donor site infection (*n* = 4, 16%), partial necrosis of the skin paddle (*n* = 3, 12%), and chyle leak (*n* = 3, 12%) were predominantly described (► **Table 2**).

Regarding intra-abdominal lymph node flaps, the incidence of incisional hernia (*n* = 9, 30%), hematoma formation (*n* = 5, 16.66%), and postoperative ileus (*n* = 3, 10%) were commonly reported after vascularized omental lymph node flap transfer. In patients treated with gastroepiploic VLNT, the presence of numbness or paresthesia (*n* = 8, 27.7%), delayed wound healing (*n* = 2, 16.6%), and recipient site lymphatic fluid leakage (*n* = 2, 11.1%) were commonly reported. The incidence of ventral hernia (*n* = 4, 30.76%), postoperative ileus (*n* = 4, 30.76%), and

**Table 2** Surgical complications of groin VLNT, supraclavicular VLNT, lateral thoracic VLNT, and submental VLNT

G-VLNT			LT-VLNT			SM-VLNT			SC-VLNT			Not specific (G-VLNT, LT-VLNT, and SM-VLNT)	
Complications	No.	Percentage	Complications	No.	Percentage	Complications	No.	Percentage	Complications	No.	Percentage	Complications	No.
Donor site pain or numbness	32	26.80	latrogenic lymphedema	4	30.76	Revision surgery due to venous complication	16	42.10	Congestion of the skin paddle	4	16	Donor site seroma	6
Delayed wound healing	16	13.44	Cellulitis	2	15.38	Marginal nerve pseudoparalysis	8	21.05	Donor site infection	4	16	Donor site infection	6
Seroma	14	11.76	Seroma or hematoma	2	15.38	Partial flap loss	7	18.42	Partial necrosis of the skin paddle and debridement	3	12	Donor wound dehiscence	3
Lymphatic fluid leakage	12	10.08	Wound dehiscence	1	7.69	Dehiscence of recipient site	3	7.89	Re-exploration	3	12	Recipient site infection	3
Revision surgery due to venous complication	9	7.56	Revision of the anastomosis	1	7.69	Arterial insufficiency	2	5.26	Chyle leakage	3	12	Recipient site bleeding (on coumadin)	1
Subclinical slower lymphatic flow in donor site limb	6	5.04	Temporary weakness of upper extremity	1	7.69	Intraoperative salvage procedure	1	2.63	Hematoma	2	8	Recipient site nonhealing wound	1
latrogenic lymphedema	5	4.20	Donor site pain	1	7.69	Hematoma	1	2.63	lymphatic fluid leakage	2	8	Recipient site hematoma	1
Wound infection	5	5.04	Lymphocele	1	7.69				Salvage procedure	1	4	Recipient site wound dehiscence	1
Partial necrosis of the skin paddle	4	3.36							Delayed wound healing	1	4	Local skin flap necrosis	1
Abdominal hernia	3	2.52							Partial loss of STSG	1	4		
Lymphocele	3	2.52							Lymphocele	1	4		
Local skin flap necrosis	2	1.68											
Arterial insufficiency	2	1.68											
Testicular hydrocele	1	0.84											
Pulmonary embolus	1	0.84											
Flap failure	1	0.84											
Hematoma	1	0.84											
Wound dehiscence	1	0.84											

Abbreviations: G-VLNT, groin VLNT; LT-VLNT, lateral thoracic VLNT; SC-VLNT, supraclavicular VLNT; SM-VLNT, submental VLNT; STSG, split-thickness skin graft; VLNT, vascularized lymph node transfer.

**Table 3** Surgical complications of gastroepiploic VLNT, jejunal VLNT, and the vascularized omental lymph node flap

Complications	VOLF		GE-VLNT		J-VLNT	
	Number	Percentage	Number	Percentage	Number	Percentage
Incisional hernia	9	30.00	–	–	4	30.76
Hematoma	5	16.66	–	–	1	7.69
Ileus and NG replacement	3	10.00	–	–	4	30.76
Cellulitis	3	10.00	–	–	1	7.69
Aborted procedure due to quality of flap	2	6.66	–	–	–	–
Pancreatitis	2	6.66	–	–	–	–
Flap loss	2	6.66	1	5.55	2	15.38
Seroma	2	6.66	1	5.55	–	–
Donor site infection	1	3.33	–	–	–	–
Revision surgery due to venous complication	–	–	1	5.55	–	–
Perioperative blood transfusion	–	–	1	5.55	–	–
Recipient-site hyperesthesia	–	–	1	5.55	–	–
Recipient-site lymphatic fluid leakage	–	–	2	11.11	–	–
Delayed wound healing	–	–	2	11.11	–	–
Recipient-site Paresthesia	–	–	3	16.66	–	–
Anastomotic revision	–	–	–	–	1	7.69

Abbreviations: GE-VLNT, gastroepiploic VLNT; J-VLNT, jejunal VLNT; NG, nasogastric; VLNT, vascularized lymph node transfer; VOLF, vascularized omental lymph node flap.

flap loss ( $n=2$ , 15.38%) was frequently reported following jejunal VLNT (►Table 3).

Seven studies reporting surgical complications of SAL were documented (see ►Supplementary Table S3 [available in the online version], which displays an overview of the included studies).<sup>6,56–59</sup> A summary of the reported complications is exhibited in ►Table 4. The most common complications reported were significant blood loss ( $n=30$ , 30.30%), transient paresthesia of the limb ( $n=32$ , 32.32%), contour irregularities ( $n=13$ , 13.13%), skin necrosis ( $n=6$ , 6.6%), and hematoma or seroma formation ( $n=8$ , 8.8%).

Eleven articles reporting complications after excisional procedures were identified (see ►Supplementary Table S4 [available in the online version], which displays an overview of the included studies).<sup>10,60–67</sup> An overview of the reported complications is presented in ►Table 5. The most common complications reported after RRPP were soft-tissue infection ( $n=6$ , 33.3%), numbness of the extremity ( $n=6$ , 33.3%), and seroma and hematoma ( $n=2$ , 11%). The most common complications described after the Charles procedure were recurrent episodes of soft-tissue infection ( $n=19$ , 22.6%), scarring and eczematoid dermatitis ( $n=13$ , 15.47%), graft loss requiring regrafting ( $n=10$ , 11.9%), ulceration ( $n=11$ , 13.09%), and significant perioperative blood loss ( $n=8$ , 9.5%). The reported complications after the Homan procedure were delayed wound healing ( $n=3$ , 50%) and skin flap necrosis ( $n=3$ , 50%).

## Discussion

Multiple techniques are available for the surgical management of lymphedema, and several modifications have been

**Table 4** Reported complications of suction-assisted lipectomy

Complications	Number	Percentage
Transient paresthesia or numbness	32	32.32
Blood transfusion	30	30.30
Contour irregularities	13	13.13
Hematoma/seroma	8	8.8
Skin necrosis	6	6.6
Superficial abrasions due to compression garments	2	2.2
Soft tissue infection	2	2.2
Neurapraxia	2	2.2
Pneumonia	1	1.1
Wound dehiscence	1	1.1
Fat necrosis	1	1.1
Epidermolysis	1	1.1

implemented to the point that a combination of different techniques has been suggested to offer more comprehensive and better results.<sup>6,37,38,68</sup> Physiologic techniques improve lymphatic drainage by means of lymphaticovenous connections and subsequent lymphatic fluid shunting into the venous system, or by promoting lymphangiogenesis.<sup>69</sup> Among those procedures, LVA and VLNT are the most widely accepted.<sup>38,69</sup> However, excisional procedures address the

**Table 5** Studies reporting surgical complications of excisional procedures

Complications	Number	Percentage	Number	Percentage	Number	Percentage
	Charles procedure		Homan procedure		RRPP	
Soft-tissue infection	19	22.61	NR	NR	6	33.3
Ulceration	11	13.09	NR	NR	NR	NR
Wrinkled areas	10	11.9	NR	NR	NR	NR
Skin graft loss	10	11.9	NR	NR	NR	NR
Significant blood loss	8	9.52	NR	NR	NR	NR
Eczematoid dermatitis	2	2.38	NR	NR	NR	NR
Numbness	NR	NR	NR	NR	6	33.3
Hypertrophic scarring	11	13.09	NR	NR	NR	NR
Wound dehiscence	6	7.14	NR	NR	NR	NR
Flap necrosis	1	1.2	3	50	NR	NR
Scar contracture	2	2.38	NR	NR	NR	NR
Delayed wound healing	4	4.76	3	50	4	22.2
Seroma	NR	NR	NR	NR	1	5.5
Hematoma	NR	NR	NR	NR	1	5.5

Abbreviation: RRPP, radical reduction with perforator preservation.

solid component of lymphedema and are advantageous in more advanced stages.<sup>37</sup>

### Lymphovenous Anastomosis

LVA is recommended when volume reduction using physical therapy has been unsatisfactory, or when there is worsening limb function, persistent limb pain, and recurrent episodes of cellulitis.<sup>69</sup> Although some authors have established an exponential relationship between the number of LVAs per limb and the reduction of the limb's cross-sectional area,<sup>70</sup> other authors have not detected a significant association during long-term follow-up.<sup>71,72</sup> In this sense, it is collectively agreed that LVA has produced promising results for early-stage disease in carefully selected lymphedema patients.<sup>73</sup> However, long-term results are less encouraging in advanced lymphedema stages, probably due to permanent damage from an increased interstitial pressure, recurrent infections, and lack of the functional smooth muscle required to successfully impel the lymphatic fluid into recipient veins.<sup>69,73</sup> Therefore, late-stage lymphedema, when lymphatic vessels are sclerotic, is a relative contraindication for LVA.

When lymphosclerosis is moderate or initial LVAs have been temporarily effective, additional LVAs are recommended. Since the first LVAs are normally performed on the medial surface of lymphedematous limbs along the saphenous or cephalic/basilic veins, it is recommended to perform further LVAs on the lateral aspect of limbs or on the medial aspect where the first LVAs were not performed. Ultimately, VLNT should be considered in stages where LVA is unlikely to be successful.<sup>68</sup>

### Vascularized Lymph Node Transfer

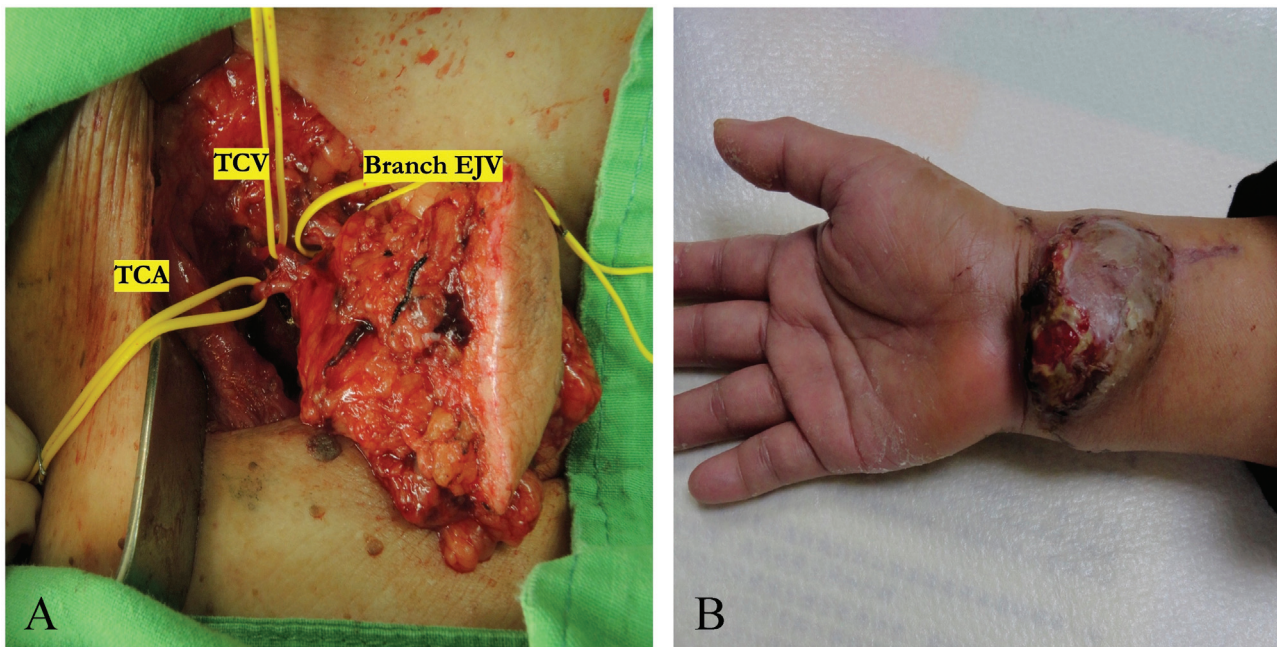
VLNT should be implemented in patients with minimal or no response to conservative treatment, when dermal fibrosis

and sclerotic lymph vessels prevent from performing LVA, and when postoperative outcomes following LVA are unsatisfactory. In fact, VLNT seems to be most effective even before fibrotic changes are evident.<sup>30,33,38,68</sup> Various donor sites have been described for lymph node flap harvest such as the groin, submental, lateral thoracic, supraclavicular, gastroepiploic, jejunal, and ileocecal areas.<sup>38,74</sup> Nonetheless, despite the satisfactory results of all vascularized lymph node flaps (VLNFs), there are some apprehensions concerning recipient and donor site morbidity.<sup>30,33,38</sup>

### Groin Vascularized Lymph Node Transfer

The groin VLNF is commonly based on the superficial circumflex iliac artery (SCIA). However, the superficial inferior epigastric artery or a minor, unnamed medial branch of the femoral artery can be an alternative pedicle if the SCIA is unsuitable.<sup>50,75,76</sup> In this direction, the critical area medial to the femoral artery and inferior to the inguinal crease must be avoided during flap harvest to preserve the sentinel lymph nodes of the leg and avoid donor site lymphedema,<sup>76</sup> a common complication reported in several series.<sup>22,43,52,54</sup> Nevertheless, some anatomical landmarks may not necessarily correspond to the dynamics of the lymphatic system.<sup>77</sup> Therefore, the incorporation of reverse lymphatic mapping to guide lymph node flap procurement can maximize safety and reduce the risk of iatrogenic lymphedema.<sup>77</sup>

If the SCIA is selected for arterial inflow and has an undersized pedicle and small caliber, to solve the anastomotic size discrepancy, the senior author (P.C.) recommends including a small "cuff" of 1 to 1.2 mm from the femoral artery at the origin of the SCIA. In this way, the risk of thrombosis secondary to the abrupt change in caliber at the anastomosis site is avoided and the surgeon can perform a less challenging microvascular anastomosis.<sup>76</sup>



**Fig. 2** Case of a supraclavicular vascularized lymph node transfer (VLNT). A patient with upper limb lymphedema who was managed using supraclavicular VLNT based on the transverse cervical vessels and a branch of the external jugular vein. (A) Intraoperative photograph. (B) A photograph at follow-up on postoperative day 10 exhibiting skin paddle congestion and partial skin necrosis of the transferred flap. EJV, external jugular vein; TCA, transverse cervical artery; TCV, transverse cervical vein.

Furthermore, in the cases in which the vascular stump is too short or if the SCIA caliber progressively decreases toward its origin, the lateral part of the SCIA can be used to vascularize the flap in a retrograde manner.<sup>76</sup>

Venous discrepancy is not uncommon; in these cases, dissection can be prolonged to include a branch of the greater saphenous vein or an alternative cutaneous vein with a larger caliber for venous anastomosis.<sup>76</sup> Finally, in the cases where a secondary debulking procedure is required or planned, it is recommended to use the deep venous system as recipient vessels, so that the anastomosis is not disturbed during further interventions.<sup>76</sup>

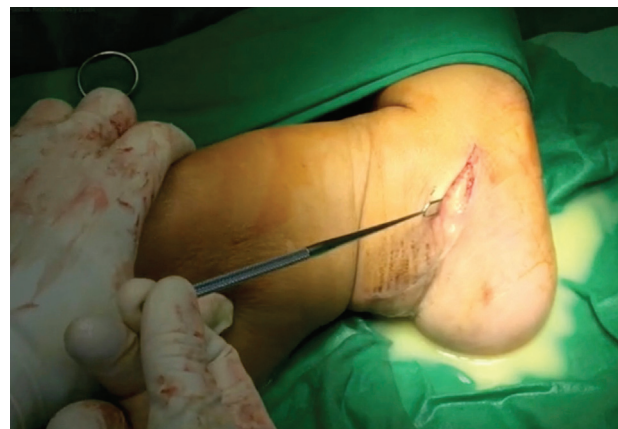#### Supraclavicular Vascularized Lymph Node Transfer

Solely in the case of right arm lymphedema, the left supraclavicular area is chosen; otherwise, it is advisable to harvest lymph nodes from the right neck to avoid the risk of severing the thoracic duct.<sup>78</sup> A skin paddle can be incorporated with the supraclavicular VLNT for soft-tissue coverage.<sup>78</sup> Nevertheless, it is recommended to avoid the integration of a cutaneous component, as perfusion is usually unpredictable (► **Fig. 2**).<sup>6,26</sup> In fact, the overlying skin was removed intraoperatively in 20% of a series of 23 supraclavicular VLNTs due to congestion in our previous study.<sup>25</sup>

Significant variations in the vascular anatomy of the transverse cervical artery (TCA) are also common.<sup>78,79</sup> For instance, the TCA may be very small and further dissection toward its origin may be necessary.<sup>78,79</sup> An associated transverse cervical vein is also usually present, but it can vary in size. In this scenario, a branch of the external jugular vein can be integrated into the flap as a second vein to intensify venous outflow and prevent venous congestion,<sup>78</sup> a com-

monly reported complication.<sup>26,78</sup> Complete knowledge of the anatomy is also imperative when a supraclavicular VLNT is lifted off from the anterior scalene muscle to preserve the phrenic nerve; otherwise, ventilation can be compromised if the nerve is severed.<sup>78</sup>

It is important to note that when a large lymphatic vessel is visualized along the surgical field and it cannot be preserved, careful ligation and anastomosis to a recipient vein must be accomplished, as in LVA.<sup>78</sup> Furthermore, to avoid lymphatic leakage from the donor site during flap harvest or the recipient site during inset,<sup>25,30</sup> punctilious use of microhemoclips to control small lymphatic vessels is mandatory (► **Fig. 3**).<sup>25,78</sup>



**Fig. 3** Case of persistent lymphatic fluid. After an initial incision, a lymphatic vessel was transected, and persistent lymphatic fluid was evident in a patient with primary lower extremity lymphedema.

### Lateral Thoracic Vascularized Lymph Node Transfer

The free axillary lymph node flap has been shown to significantly decrease the size of edematous limbs.<sup>80</sup> Interestingly, the lateral thoracic artery is absent in around 12.5% of sides, in which case, the thoracodorsal artery provides the vascular supply to those lymph nodes.<sup>74,81</sup> Harvest of the lateral thoracic nodes typically is not an option in patients with upper limb lymphedema, as doing so can further compromise the drainage of the ipsilateral affected arm, or if they have been removed during axillary dissection.<sup>81</sup> As with the other donor sites, reverse lymphatic mapping should be performed to minimize the risk of donor site lymphedema when harvesting the lateral thoracic nodes.<sup>81,82</sup>

### Submental Vascularized Lymph Node Transfer

The main concern with submental VLNT, apart from the conspicuous scar over the donor site, is the risk of marginal mandibular nerve injury.<sup>32</sup> To avoid peripheral nerve damage, a nerve stimulator should be used during meticulous microscopic dissection.<sup>32</sup> A platysma-sparing harvest technique is also useful during dissection to avoid asymmetry of the lower lip secondary to injury to the marginal mandibular nerve.<sup>32</sup> Moreover, outstanding knowledge of the anatomy is mandatory due to the anatomical variability in this region, as more challenging dissections may be required due to the divergent configuration of the artery and vein observed throughout the submandibular gland.<sup>83</sup>

### Intra-abdominal Vascularized Lymph Node Flaps

The omentum has been successfully reported as an alternative option to avoid iatrogenic lymphedema.<sup>84-87</sup> However, with this technique, significant recipient site complications were noted due to the extensive dissection required for flap inset.<sup>84</sup>

In previous studies, the distribution of lymph nodes within the omentum has been principally identified around the right gastroepiploic vessels, rather than within the whole omentum.<sup>88,89</sup> Consequently, a 3-cm-wide omentum segment from the greater curvature comprising the right gastroepiploic vessels has been determined to have an adequate quantity of lymph nodes.<sup>88,90</sup> Since it excludes the rest of the omental tissue, the resulting flap is a relatively small flap; therefore, it can be placed in the distal extremity, significantly improving the cosmesis of the recipient site. Furthermore, when compared with other intra-abdominal pedicles, the right gastroepiploic artery (RGA) is chosen because of the straightforwardness of its exposure and access compared with its contralateral counterpart. Additionally, it has been well established that flap procurement using the RGA does not increase the risk of gastric ischemia or other intra-abdominal complications.<sup>91,92</sup>

A laparoscopic approach allows faster harvest, reduced postoperative pain, shorter scars, faster return of bowel function, reduced adhesions, and decreased abdominal wall morbidity in comparison to the traditional open approach.<sup>86,93-95</sup> Nevertheless, complications such as injuries of the pedicle, partial graft necrosis, incisional hernia, peritonitis, injury to intra-abdominal organs, postoperative ileus

or bowel obstruction, hemorrhage, pancreatitis, and wound infection have been reported in large series of laparoscopic omental flap harvest.<sup>94,95</sup> Previously, we reported a series of 32 patients undergoing gastroepiploic VLNT who did not encounter any donor site complication; however, in other series, the authors reported only the incidence of postoperative ileus in one patient and a case of pancreatitis in a patient with a history of pancreas divisum.<sup>24</sup> In this regard, the dissection of the RGA in the vicinity of the pancreas must be limited to avoid pancreatitis, but it seems that the overall morbidity is low.

Another advantage is that the omental fat apron hanging from the transverse colon is left undisturbed with the gastroepiploic VLNT. In this way, the omental coverage of the intestine is maintained, the risk of adhesions is decreased, and the risk of transverse colon injury is diminished. Thus, as seen in this review, the reported donor site morbidity of the laparoscopic-assisted total omentum harvest is not comparable to that of the gastroepiploic VLNF. Finally, the abundance of lymph nodes of the gastroepiploic VLNF affords the distinctive opportunity to split the flap into two or even three units for a separate inset into two different limbs or different levels in the same extremity.<sup>86</sup> This avoids the potential complications of a second donor site and also reduces the flap harvest time.<sup>86</sup>

The jejunal mesentery is ideal as a donor site, as no risk of subsequent lymphedema is present and the vascular anatomy is reliable. Peripherally located lymph nodes are usually preferred due to their favorable hemodynamics, as they appear to have better balance of arterial inflow and venous outflow when compared with flaps raised closer to the root of the mesentery.<sup>5</sup>

An important detriment of the jejunal VLNT is its segmental blood supply. Therefore, any poorly vascularized bowel segment would depend merely on the collateral circulation within the bowel wall, which may lead to partial bowel necrosis, resulting in bacterial translocation and subsequent infection.<sup>88,96</sup> Moreover, because of the more intense manipulation of the intestines during flap harvest, perioperative ileus and prolonged nasogastric tube decompression in the short term and a higher risk of small bowel obstruction in the long run would be expected.<sup>88</sup>

### Suction-Assisted Lipectomy

In comparison to lymphedematous limbs with a predominant fluid component, which may be treated with physiologic procedures such as LVA and VLNT; SAL is preferably used in the cases where the solid component is predominant, as it targets the trophic changes of the subcutaneous tissue. Additionally, SAL is usually used in patients with mild fibrosis or minor trophic skin changes, in whom the previous use of a physiologic procedure has not provided symptomatic relief and the disease seems to progress after a considerable follow-up period.<sup>68</sup> SAL seems to be a favorable treatment option in comparison to excisional surgery, as it avoids large incisions that have a higher risk of infection or scarring.<sup>97</sup> However, although SAL is able to provide effective symptomatic relief, patients must adhere to strict lifelong compression



therapy as liposuction does not address lymphostasis.<sup>98</sup> Therefore, the addition of a physiologic procedure may become necessary for a comprehensive surgical management. In a previous report, we used LVA in combination with SAL and accomplished an average mean circumference reduction rate of 90 and 85% for upper extremity and lower extremity lymphedema, respectively, indicating the positive effect of this dual integrated therapy.<sup>6</sup>

The use of the ultrasound lipoplasty device, VASER, improves the surgical effectiveness of SAL as it ruptures the fibrotic tissue and septa while also preserving vascularization and lymphatic vessels.<sup>6</sup> This device also includes multiple rings that disperse the energy, decreasing the thermal injury produced by the acoustic waves of the cannula.<sup>6</sup> Additionally, with a tumescent technique and an optimal tourniquet, the thermal injury is reduced even more while vasoconstriction avoids significant blood loss.<sup>6,58</sup> This technique also reduces the traumatic avulsion of the tissues, enhances postoperative recovery, decreases traumatic bruising, and augments skin sensitivity and draping.<sup>6</sup> Nonetheless, the risk of epidermolysis persists in patients with severe lymphedema and epidermal skin changes who are treated with aggressive liposuction (► **Figs. 4** and **5**). Therefore, a thorough patient selection is always mandatory.

#### Radical Reduction with Perforator Preservation

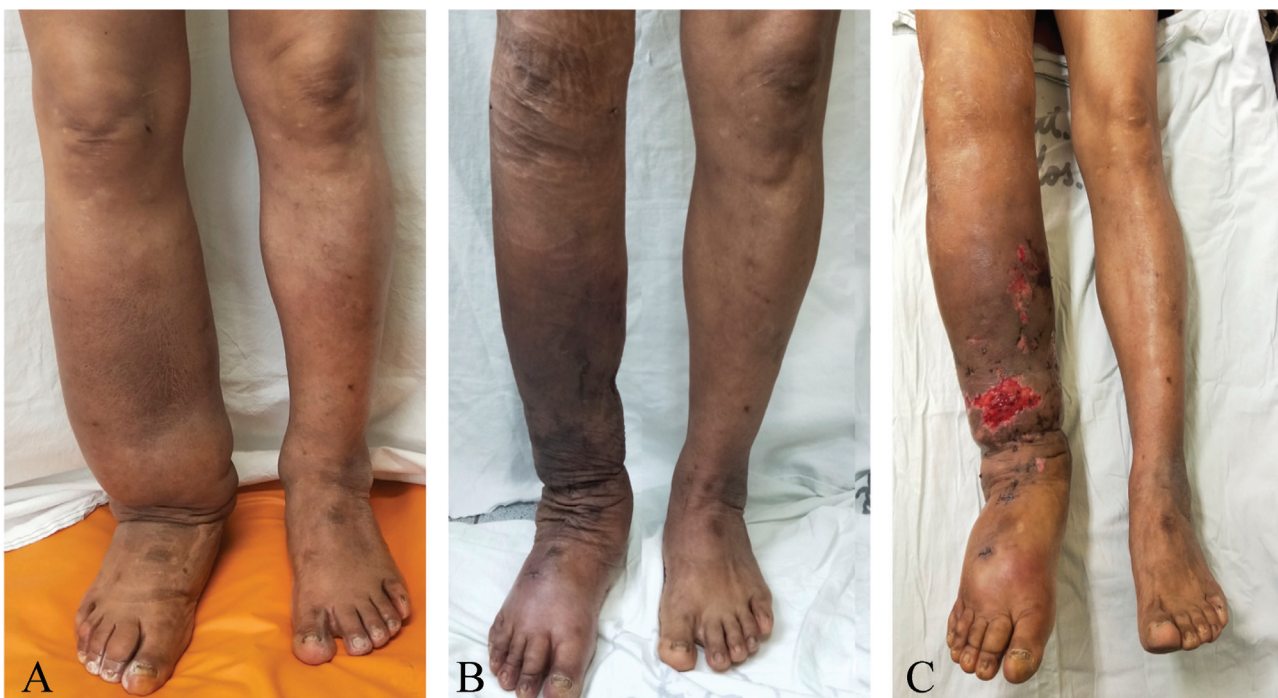
We have been including RRPP (an excisional procedure following microsurgical principles) in recent years in combination with VLNT when liposuction is not an option, obtaining promising results in patients with end-stage lymphedema but mild fibrosis and minimal trophic skin

changes.<sup>38</sup> The markings on the leg consist of two anterior and posterior ellipses positioned obliquely and parallel to each other, which provide good access to the subcutaneous layer around the circumference of the leg. It is also recommended to include a skin bridge with a minimum width of 4 cm that separates the ellipses, both anteriorly and posteriorly, as this prevents full skin necrosis at the middle of the leg.<sup>38,64</sup> During subcutaneous excision, fat is tangentially excised until a 0.5-cm-thick flap is attained. Using these parameters, flap necrosis is avoided and wound healing is optimized.<sup>38,64</sup> Finally, the senior author also recommends preserving a 1.5- to 2-cm “cuff” of fat around the two main skin flaps’ perforators (to the medial and lateral) to ensure adequate skin perfusion.

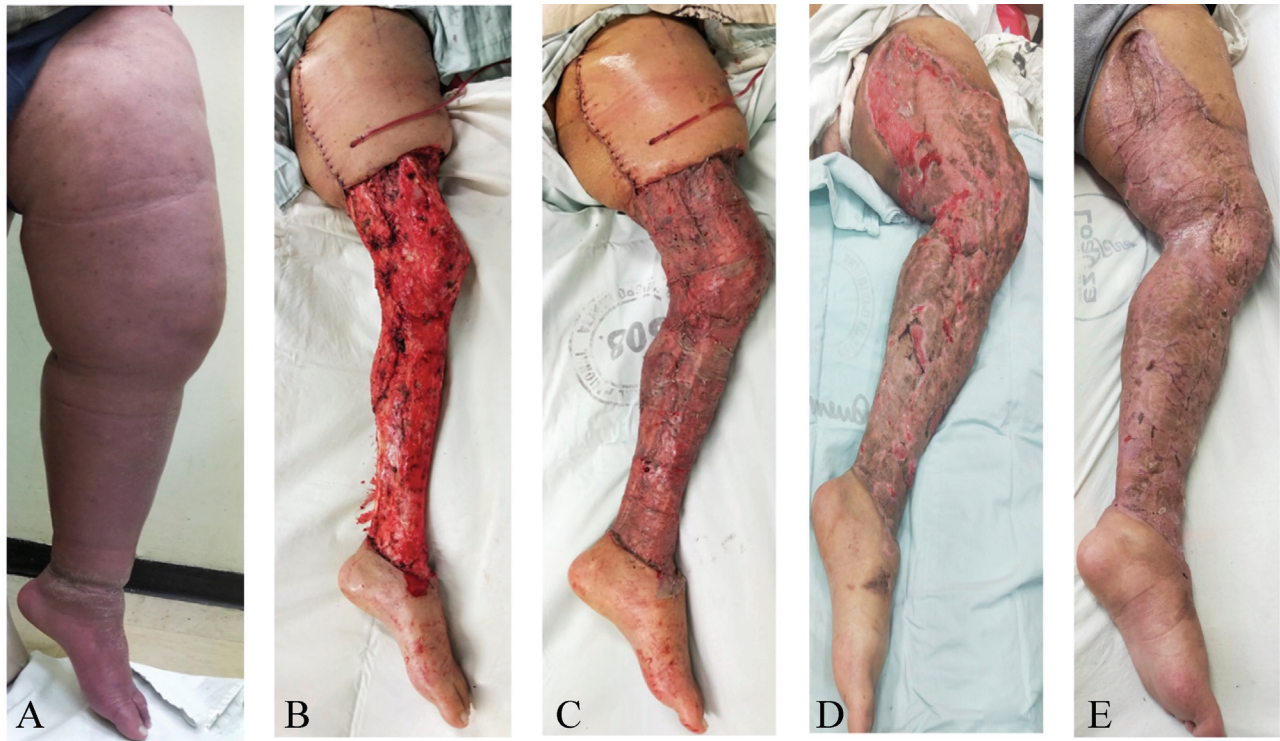For the upper extremity, as we reported in previous studies, the landmarks that represent the major fasciocutaneous branches of the radial and ulnar artery should be avoided during the initial dissection.<sup>38,65</sup> For the dorsal aspect of the forearm, a posterior ellipse is designed at the central area along its longitudinal axis.<sup>38,65</sup> Ultimately, loupe magnification is recommended to identify the vascular branches during elevation of the medial and lateral skin flaps; in this way, the bipedicle design of the medial and lateral skin flaps ensures blood supply from above the elbow and below the wrist.<sup>38,65</sup>

#### Homan Procedure

While aesthetically more favorable than the Charles procedure, the final outcomes of the Homan procedure is reliant on the amount of tissue removed and a sustained postoperative compression garment use.<sup>37</sup> Lee et al reported a series of 33 patients who underwent this treatment. The procedure was initially



**Fig. 4** Case of combined lymphovenous anastomosis (LVA) and suction-assisted lipectomy. (A) Preoperative photograph. (B) Postoperative photograph on the second day of follow-up. (C) Zone of epidermolysis on postoperative day 21.



**Fig. 5** Combined Charles, Homan, and VLNT procedure. (A) Preoperative photograph. (B) Intraoperative photograph before skin grafting. (C) Immediate postoperative photograph. (D) Postoperative photograph at 1 week of follow-up with a *Pseudomonas* infection and zones of skin graft loss. (E) Picture during follow-up in postoperative year 3 showing complete resolution of lymphedema.

successful in 28 patients, but only 6 were able to maintain an optimum limb circumference at a 2-year follow-up.<sup>99</sup>

In our experience, the Homan procedure is reserved for the upper thigh as it achieves a tension-free closure and provides a smooth-contoured transition from the skin-grafted area to the rest of the body when used in conjunction with the Charles procedure (in a combination referred to as CHAHOVA; ▶Fig. 5).<sup>37,66</sup> Consequently, this procedure is usually avoided in the leg as there is usually a higher tension during closure and a high risk of skin flap necrosis.

### Charles Procedure

The Charles procedure may be the only surgical option in patients with end-stage lower extremity lymphedema and frequent episodes of cellulitis.<sup>100</sup> However, despite its high success rate, latent complications have been reported such as poor cosmetic results, recurrence of lymphedema (especially at the foot and ankle), skin graft loss, infections, and toe amputation (▶Fig. 5).<sup>10,60–62,67</sup>

The modified Charles procedure consists of preserving the lesser saphenous vein along with its superficial branch on the dorsum of the foot. Therefore, the superficial venous system provides an additional recipient vein for VLNT and maximizes lymphatic drainage. In a previous clinical study of the CHAHOVA technique, 24 patients who presented with long-lasting unilateral late-stage lower extremity lymphedema underwent VLNT in conjunction with the Charles and Homan procedures achieving an average circumference reduction rate of 98.1%.<sup>37,67</sup>

When possible, intraoperative tourniquet control can help avoid complications related to intraoperative blood loss, therefore

decreasing the requirement for blood transfusion.<sup>100</sup> Van der Walt et al presented a modified Charles procedure, applying 5 to 7 days of negative-pressure dressings following the initial debulking surgery before delayed skin grafting.<sup>10</sup> In this series, three of nine patients required re-grafting and 88% required blood transfusions, especially when tourniquet use was not done appropriately. The results showed robust functional improvements in quality of life and a high overall satisfaction rate.<sup>10</sup>

Finally, several modest adjustments have been described that minimize the complication of the Charles procedure. For instance, long sheets of skin grafts circumferentially placed in an overlapping manner to decrease the number of ridges and avoid gaps are recommended.<sup>37,66</sup> Furthermore, immediate postoperative leg elevation and compliance with a rigorous physiotherapy regimen yield much more predictable outcomes of skin grafting.<sup>37</sup>

### Conclusion

Despite the numerous surgical alternatives available to reduce the limb volume and reinstate functionality, lymphedema continues to represent a challenging condition for surgeons. In this matter, a careful selection of patients and surgical approach, compliance with conservative therapy, and an experienced surgeon with an adequate understanding of the lymphatic system can help maximize safety during the surgical management of lymphedema. Nonetheless, complications are inherent to surgical interventions, and further studies reporting the complications of lymphatic surgery are required to improve outcomes.

### Author Contributions

Conceptualization: P.C. Data curation: all authors. Formal analysis: all authors. Funding acquisition: P.C. Investigation: all authors. Methodology: all authors. Project administration: all authors. Resources: all authors. Software: all authors. Supervision: P.C. and O.J.M. Validation: all authors. Visualization: all authors. Writing—original draft: all authors. Writing—review and editing: all authors.

### Patient consent

The patients provided written informed consent for the publication and the use of their images.

### Conflict of Interest

P.C. is an editorial board member of the journal but was not involved in the peer reviewer selection, evaluation, or decision process of this article. No other potential conflicts of interest relevant to this article were reported.

### References

- Pappalardo M, Patel K, Cheng MH. Vascularized lymph node transfer for treatment of extremity lymphedema: an overview of current controversies regarding donor sites, recipient sites and outcomes. *J Surg Oncol* 2018;117(07):1420–1431
- Forte AJ, Huayllani MT, Sisti A, et al. Assessment of lymphovenous anastomosis patency: technical highlights. *Plast Reconstr Surg Glob Open* 2020;8(03):e2718
- Rosian K, Stanak M. Efficacy and safety assessment of lymphovenous anastomosis in patients with primary and secondary lymphoedema: a systematic review of prospective evidence. *Microsurgery* 2019;39(08):763–772
- Raju A, Chang DW. Vascularized lymph node transfer for treatment of lymphedema: a comprehensive literature review. *Ann Surg* 2015;261(05):1013–1023
- Coriddi M, Skoracki R, Eiferman D. Vascularized jejunal mesenteric lymph node transfer for treatment of extremity lymphedema. *Microsurgery* 2017;37(02):177–178
- Ciudad P, Manrique OJ, Bustos SS, et al. Single-stage VASER-assisted liposuction and lymphatico-venous anastomoses for the treatment of extremity lymphedema: a case series and systematic review of the literature. *Gland Surg* 2020;9(02):545–557
- Goldsmith HS, De los Santos R. Omental transposition for the treatment of chronic lymphedema. *Rev Surg* 1966;23(04):303–304
- Nakajima E, Nakajima R, Tsukamoto S, Koide Y, Yarita T, Kato H. Omental transposition for lymphedema after a breast cancer resection: report of a case. *Surg Today* 2006;36(02):175–179
- Ramachandran S, Chew KY, Tan BK, Kuo YR. Current operative management and therapeutic algorithm of lymphedema in the lower extremities. *Asian J Surg* 2021;44(01):46–53
- van der Walt JC, Perks TJ, Zeeman BJV, Bruce-Chwatt AJ, Graewe FR. Modified Charles procedure using negative pressure dressings for primary lymphedema: a functional assessment. *Ann Plast Surg* 2009;62(06):669–675
- Shamseer L, Moher D, Clarke M, et al; PRISMA-P Group. Preferred reporting items for systematic review and meta-analysis protocols (PRISMA-P) 2015: elaboration and explanation. *BMJ* 2015;350:g7647
- Onoda S, Todokoro T, Hara H, Azuma S, Goto A. Minimally invasive multiple lymphaticovenular anastomosis at the ankle for the prevention of lower leg lymphedema. *Microsurgery* 2014;34(05):372–376
- Granzow JW, Soderberg JM, Kaji AH, Dauphine C. An effective system of surgical treatment of lymphedema. *Ann Surg Oncol* 2014;21(04):1189–1194
- Akita S, Yamaji Y, Tokumoto H, et al. Prevention of venous reflux with full utilization of venoplasty in lymphaticovenular anastomosis. *J Plast Reconstr Aesthet Surg* 2020;73(03):537–543
- Scaglioni MF, Meroni M, Fritsche E, Fuchs B. Combined pedicled superficial circumflex iliac artery perforator (SCIP) flap with lymphatic tissue preservation and lymphovenous anastomosis (LVA) for defect reconstruction and lymphedema-lymphocele prevention in thigh sarcoma surgery: preliminary results. *J Surg Oncol* 2021;123(01):96–103
- Poumellec MA, Foissac R, Cegarra-Escolano M, Barranger E, Ihrat T. Surgical treatment of secondary lymphedema of the upper limb by stepped microsurgical lymphaticovenous anastomoses. *Breast Cancer Res Treat* 2017;162(02):219–224
- Ayestary B, Bekara F, Andreoletti JB.  $\pi$ -shaped lymphaticovenular anastomosis for head and neck lymphoedema: a preliminary study. *J Plast Reconstr Aesthet Surg* 2013;66(02):201–206
- Giacalone G, Belva F, Opheide J, Haentjens P, Boccardo F, Campisi C. Outcome of lymphedema after microsurgical treatment. *Eur J Lymphology Relat Probl* 2011;22(62):21–25
- Schwarz GS, Grobmyer SR, Djohan RS, et al. Axillary reverse mapping and lymphaticovenous bypass: lymphedema prevention through enhanced lymphatic visualization and restoration of flow. *J Surg Oncol* 2019;120(02):160–167
- Cakmakoglu C, Kwiczen GJ, Schwarz GS, Gastman B. Lymphaticovenous bypass for immediate lymphatic reconstruction in locoregional advanced melanoma patients. *J Reconstr Microsurg* 2020;36(04):247–252
- Wolfs JAGN, de Joode LGEH, van der Hulst RRWJ, Qiu SS. Correlation between patency and clinical improvement after lymphaticovenous anastomosis (LVA) in breast cancer-related lymphedema: 12-month follow-up. *Breast Cancer Res Treat* 2020;179(01):131–138
- Engel H, Lin CY, Huang JJ, Cheng MH. Outcomes of lymphedema microsurgery for breast cancer-related lymphedema with or without microvascular breast reconstruction. *Ann Surg* 2018;268(06):1076–1083
- Nacchiero E, Maruccia M, Vestita M, Elia R, Marannino P, Giudice G. Multiple lymphatic-venous anastomoses in reducing the risk of lymphedema in melanoma patients undergoing complete lymph node dissection. A retrospective case-control study. *J Plast Reconstr Aesthet Surg* 2019;72(04):642–648
- Nguyen AT, Suami H, Hanasono MM, Womack VA, Wong FC, Chang EI. Long-term outcomes of the minimally invasive free vascularized omental lymphatic flap for the treatment of lymphedema. *J Surg Oncol* 2017;115(01):84–89
- Ciudad P, Manrique OJ, Date S, et al. A head-to-head comparison among donor site morbidity after vascularized lymph node transfer: pearls and pitfalls of a 6-year single center experience. *J Surg Oncol* 2017;115(01):37–42
- Maldonado AA, Chen R, Chang DW. The use of supraclavicular free flap with vascularized lymph node transfer for treatment of lymphedema: a prospective study of 100 consecutive cases. *J Surg Oncol* 2017;115(01):68–71
- Dionysiou D, Demiri E, Tsimponis A, et al. A randomized control study of treating secondary stage II breast cancer-related lymphoedema with free lymph node transfer. *Breast Cancer Res Treat* 2016;156(01):73–79
- Inbal A, Teven CM, Chang DW. Latissimus dorsi flap with vascularized lymph node transfer for lymphedema treatment: technique, outcomes, indications and review of literature. *J Surg Oncol* 2017;115(01):72–77
- Gratzon A, Schultz J, Secrest K, Lee K, Feiner J, Klein RD. Clinical and psychosocial outcomes of vascularized lymph node transfer for the treatment of upper extremity lymphedema after breast cancer therapy. *Ann Surg Oncol* 2017;24(06):1475–1481
- Ciudad P, Agko M, Perez Coca JJ, et al. Comparison of long-term clinical outcomes among different vascularized lymph node transfers: 6-year experience of a single center's approach to

- the treatment of lymphedema. *J Surg Oncol* 2017;116(06):671–682
- 31 Coriddi M, Wee C, Meyerson J, Eiferman D, Skoracki R. Vascularized jejunal mesenteric lymph node transfer: a novel surgical treatment for extremity lymphedema. *J Am Coll Surg* 2017;225(05):650–657
  - 32 Poccia I, Lin CY, Cheng MH. Platysma-sparing vascularized submental lymph node flap transfer for extremity lymphedema. *J Surg Oncol* 2017;115(01):48–53
  - 33 Agko M, Ciudad P, Chen HC. Staged surgical treatment of extremity lymphedema with dual gastroepiploic vascularized lymph node transfers followed by suction-assisted lipectomy: a prospective study. *J Surg Oncol* 2018;117(06):1148–1156
  - 34 Binoy C, Rao YG, Ananthakrishnan N, Kate V, Yuvaraj J, Pani SP. Omentoplasty in the management of filarial lymphoedema. *Trans R Soc Trop Med Hyg* 1998;92(03):317–319
  - 35 Kenworthy EO, Nelson JA, Verma R, Mbabuike J, Mehrara BJ, Dayan JH. Double vascularized omentum lymphatic transplant (VOLT) for the treatment of lymphedema. *J Surg Oncol* 2018;117(07):1413–1419
  - 36 Liu HL, Pang SY, Lee CC. Donor limb assessment after vascularized groin lymph node transfer for the treatment of breast cancer-related lymphedema: clinical and lymphoscintigraphy findings. *J Plast Reconstr Aesthet Surg* 2019;72(02):216–224
  - 37 Ciudad P, Agko M, Huang TCT, et al. Comprehensive multimodal surgical treatment of end-stage lower extremity lymphedema with toe management: the combined Charles', Homan's, and vascularized lymph node transfer (CHAHOVA) procedures. *J Surg Oncol* 2019;119(04):430–438
  - 38 Ciudad P, Manrique OJ, Adabi K, et al. Combined double vascularized lymph node transfers and modified radical reduction with preservation of perforators for advanced stages of lymphedema. *J Surg Oncol* 2019;119(04):439–448
  - 39 Mousavi SR, Akbari ME, Zarrintan S. Vascularized gastroepiploic lymph node transfer significantly improves breast cancer-related lymphedema. *J Surg Oncol* 2020;121(01):163–167
  - 40 Kraft CT, Eiferman D, Jordan S, Skoracki RJ. Complications after vascularized jejunal mesenteric lymph node transfer: a 3-year experience. *Microsurgery* 2019;39(06):497–501
  - 41 Chang EI, Ibrahim A, Liu J, et al. Optimizing quality of life for patients with breast cancer-related lymphedema: a prospective study combining DIEP flap breast reconstruction and lymphedema surgery. *Plast Reconstr Surg* 2020;145(04):676e–685e
  - 42 Leppäpuska IM, Suominen E, Viitanen T, et al. combined surgical treatment for chronic upper extremity lymphedema patients: simultaneous lymph node transfer and liposuction. *Ann Plast Surg* 2019;83(03):308–317
  - 43 Ho OA, Lin CY, Pappalardo M, Cheng MH. Comparisons of submental and groin vascularized lymph node flaps transfer for breast cancer-related lymphedema. *Plast Reconstr Surg Glob Open* 2018;6(12):e1923
  - 44 Visconti G, Tartaglione G, Bartoletti R, Salgarello M. Compartmental harvesting of dual lymph node flap from the right supraclavicular area for the treatment of lower extremity lymphedema: a case series. *J Plast Reconstr Aesthet Surg* 2019;72(02):211–215
  - 45 Becker C, Assouad J, Riquet M, Hidden G. Postmastectomy lymphedema: long-term results following microsurgical lymph node transplantation. *Ann Surg* 2006;243(03):313–315
  - 46 Koide S, Lin CY, Chen C, Cheng MH. Long-term outcome of lower extremity lymphedema treated with vascularized lymph node flap transfer with or without venous complications. *J Surg Oncol* 2020;121(01):129–137
  - 47 Koide S, Lin CY, Cheng MH. Delayed primary retention suture for inset of vascularized submental lymph node flap for lower extremity lymphedema. *J Surg Oncol* 2020;121(01):138–143
  - 48 Dionysiou D, Demiri E, Sarafis A, Goula CO, Tsimponis A, Arsos G. Functional lymphatic reconstruction with the “selected lymph node” technique guided by a SPECT-CT lymphoscintigraphy. *J Surg Oncol* 2019;120(06):911–918
  - 49 Ciudad P, Manrique OJ, Bustos SS, et al. Combined microvascular breast and lymphatic reconstruction with deep inferior epigastric perforator flap and gastroepiploic vascularized lymph node transfer for postmastectomy lymphedema patients. *Gland Surg* 2020;9(02):512–520
  - 50 Gharb BB, Rampazzo A, Spanio di Spilimbergo S, Xu ES, Chung KP, Chen HC. Vascularized lymph node transfer based on the hilar perforators improves the outcome in upper limb lymphedema. *Ann Plast Surg* 2011;67(06):589–593
  - 51 Viitanen TP, Mäki MT, Seppänen MP, Suominen EA, Saariisto AM. Donor-site lymphatic function after microvascular lymph node transfer. *Plast Reconstr Surg* 2012;130(06):1246–1253
  - 52 Vignes S, Blanchard M, Yannoutsos A, Arrault M. Complications of autologous lymph-node transplantation for limb lymphoedema. *Eur J Vasc Endovasc Surg* 2013;45(05):516–520
  - 53 Chen R, Mu L, Zhang H, et al. Simultaneous breast reconstruction and treatment of breast cancer-related upper arm lymphedema with lymphatic lower abdominal flap. *Ann Plast Surg* 2014;73(Suppl 1):S12–S17
  - 54 Pons G, Masia J, Loschi P, Nardulli ML, Duch J. A case of donor-site lymphoedema after lymph node-superficial circumflex iliac artery perforator flap transfer. *J Plast Reconstr Aesthet Surg* 2014;67(01):119–123
  - 55 Nguyen AT, Chang EI, Suami H, Chang DW. An algorithmic approach to simultaneous vascularized lymph node transfer with microvascular breast reconstruction. *Ann Surg Oncol* 2015;22(09):2919–2924
  - 56 Brorson H, Svensson H. Complete reduction of lymphoedema of the arm by liposuction after breast cancer. *Scand J Plast Reconstr Surg Hand Surg* 1997;31(02):137–143
  - 57 Stewart CJ, Munnoch DA. Liposuction as an effective treatment for lower extremity lymphoedema: a single surgeon's experience over nine years. *J Plast Reconstr Aesthet Surg* 2018;71(02):239–245
  - 58 Hoffner M, Ohlin K, Svensson B, et al. Liposuction gives complete reduction of arm lymphedema following breast cancer treatment: a 5-year prospective study in 105 patients without recurrence. *Plast Reconstr Surg Glob Open* 2018;6(08):e1912
  - 59 Chen WF, Zeng WF, Hawkes PJ, Man J, Bowen M. Lymphedema liposuction with immediate limb contouring. *Plast Reconstr Surg Glob Open* 2019;7(11):e2513
  - 60 Dellon AL, Hoopes JE. The Charles procedure for primary lymphedema. Long-term clinical results. *Plast Reconstr Surg* 1977;60(04):589–595
  - 61 Dandapat MC, Mohapatro SK, Mohanty SS. Filarial lymphoedema and elephantiasis of lower limb: a review of 44 cases. *Br J Surg* 1986;73(06):451–453
  - 62 Miller TA, Wyatt LE, Rudkin GH. Staged skin and subcutaneous excision for lymphedema: a favorable report of long-term results. *Plast Reconstr Surg* 1998;102(05):1486–1498
  - 63 Miller TA. Charles procedure for lymphedema: a warning. *Am J Surg* 1980;139(02):290–292
  - 64 Salgado CJ, Mardini S, Spanio di Spilimbergo S, Tang WR, Sassu P, Chen HC. Radical reduction of lymphedema with preservation of perforators. *Ann Plast Surg* 2007;59(02):173–179
  - 65 Salgado CJ, Sassu P, Gharb BB, Spanio di Spilimbergo S, Mardini S, Chen HC. Radical reduction of upper extremity lymphedema with preservation of perforators. *Ann Plast Surg* 2009;63(03):302–306
  - 66 Karri V, Yang MC, Lee IJ, et al. Optimizing outcome of Charles procedure for chronic lower extremity lymphoedema. *Ann Plast Surg* 2011;66(04):393–402
  - 67 Sapountzis S, Ciudad P, Lim SY, et al. Modified Charles procedure and lymph node flap transfer for advanced lower extremity lymphedema. *Microsurgery* 2014;34(06):439–447
  - 68 Ciudad P, Sabbagh MD, Agko M, et al. Surgical management of lower extremity lymphedema: a comprehensive review. *Indian J Plast Surg* 2019;52(01):81–92

- 69 Forte AJ, Khan N, Huayllani MT, et al. Lymphaticovenous anastomosis for lower extremity lymphedema: a systematic review. *Indian J Plast Surg* 2020;53(01):17–24
- 70 Narushima M, Mihara M, Yamamoto Y, Iida T, Koshima I, Munding GS. The intravascular stenting method for treatment of extremity lymphedema with multiconfiguration lymphaticovenous anastomoses. *Plast Reconstr Surg* 2010;125(03):935–943
- 71 Chang DW. Lymphaticovenular bypass for lymphedema management in breast cancer patients: a prospective study. *Plast Reconstr Surg* 2010;126(03):752–758
- 72 O'Brien BM, Sykes P, Threlfall GN, Browning FSC. Microlymphaticovenous anastomoses for obstructive lymphedema. *Plast Reconstr Surg* 1977;60(02):197–211
- 73 Nicoli F, Constantinides J, Ciudad P, et al. Free lymph node flap transfer and laser-assisted liposuction: a combined technique for the treatment of moderate upper limb lymphedema. *Lasers Med Sci* 2015;30(04):1377–1385
- 74 Barreiro GC, Baptista RR, Kasai KE, et al. Lymph fasciocutaneous lateral thoracic artery flap: anatomical study and clinical use. *J Reconstr Microsurg* 2014;30(06):389–396
- 75 Cheng MH, Chen SC, Henry SL, Tan BK, Chia-Yu Lin M, Huang JJ. Vascularized groin lymph node flap transfer for postmastectomy upper limb lymphedema: flap anatomy, recipient sites, and outcomes. *Plast Reconstr Surg* 2013;131(06):1286–1298
- 76 Ciudad P, Orfanotis G, Socas J, et al. Technical considerations to avoid microvascular complications during groin lymph node free flap transfer. *Arch Plast Surg* 2015;42(05):650–652
- 77 Dayan JH, Dayan E, Smith ML. Reverse lymphatic mapping: a new technique for maximizing safety in vascularized lymph node transfer. *Plast Reconstr Surg* 2015;135(01):277–285
- 78 Ooi ASH, Chang DW. 5-step harvest of supraclavicular lymph nodes as vascularized free tissue transfer for treatment of lymphedema. *J Surg Oncol* 2017;115(01):63–67
- 79 Weiglein AH, Moriggl B, Schalk C, Künzel KH, Müller U. Arteries in the posterior cervical triangle in man. *Clin Anat* 2005;18(08):553–557
- 80 Tinhofer IE, Meng S, Steinbacher J, et al. The surgical anatomy of the vascularized lateral thoracic artery lymph node flap-A cadaver study. *J Surg Oncol* 2017;116(08):1062–1068
- 81 Chang EI, Chu CK, Hanson SE, Selber JC, Hanasono MM, Schaverien MV. Comprehensive overview of available donor sites for vascularized lymph node transfer. *Plast Reconstr Surg Glob Open* 2020;8(03):e2675
- 82 Clough KB, Nasr R, Nos C, Vieira M, Inguenault C, Poulet B. New anatomical classification of the axilla with implications for sentinel node biopsy. *Br J Surg* 2010;97(11):1659–1665
- 83 Cheng MH, Lin CY, Patel KM. A prospective clinical assessment of anatomic variability of the submental vascularized lymph node flap. *J Surg Oncol* 2017;115(01):43–47
- 84 O'Brien BMC, Hickey MJ, Hurley JV, et al. Microsurgical transfer of the greater omentum in the treatment of canine obstructive lymphoedema. *Br J Plast Surg* 1990;43(04):440–446
- 85 Egorov YS, Abalmasov KG, Ivanov VV, et al. Autotransplantation of the greater omentum in the treatment of chronic lymphedema. *Lymphology* 1994;27(03):137–143
- 86 Ciudad P, Manrique OJ, Date S, et al. Double gastroepiploic vascularized lymph node transfers to middle and distal limb for the treatment of lymphedema. *Microsurgery* 2017;37(07):771–779
- 87 Ciudad P, Date S, Lee MH, et al. Robotic harvest of a right gastroepiploic lymph node flap. *Arch Plast Surg* 2016;43(02):210–212
- 88 Lin YS, Chen HC. Review of donor site complications among different intra-abdominal vascularized lymph node free flaps: future tendency of application based on anatomical considerations. *J Plast Reconstr Aesthet Surg* 2018;71(09):1362–1380
- 89 Borchard F, Betz P. Number and size of perigastric lymph nodes in human adults without gastric cancer. *Surg Radiol Anat* 1991;13(02):117–121
- 90 Agko M, Ciudad P, Chen HC. Histo-anatomical basis of the gastroepiploic vascularized lymph node flap: the overlooked "micro" lymph nodes. *J Plast Reconstr Aesthet Surg* 2018;71(01):118–120
- 91 Suma H, Tanabe H, Takahashi A, et al. Twenty years experience with the gastroepiploic artery graft for CABG. *Circulation* 2007;116(11, Suppl):I188–I191
- 92 Ciudad P, Maruccia M, Socas J, et al. The laparoscopic right gastroepiploic lymph node flap transfer for upper and lower limb lymphedema: technique and outcomes. *Microsurgery* 2017;37(03):197–205
- 93 Chu CK, Schaverien MV, Chang EI, Hanson SE, Hanasono MM, Selber JC. Intra-abdominal lymph nodes: a privileged donor site for vascularized lymph node transfer. *Plast Reconstr Surg Glob Open* 2020;8(03):e2673
- 94 Zaha H, Inamine S. Laparoscopically harvested omental flap: results for 96 patients. *Surg Endosc* 2010;24(01):103–107
- 95 Saltz R, Stowers R, Smith M, Gadacz TR. Laparoscopically harvested omental free flap to cover a large soft tissue defect. *Ann Surg* 1993;217(05):542–546
- 96 Olding M, Jeng JC. Ischemic tolerance of canine jejunal flaps. *Plast Reconstr Surg* 1994;94(01):167–173
- 97 Brorson H. From lymph to fat: liposuction as a treatment for complete reduction of lymphedema. *Int J Low Extrem Wounds* 2012;11(01):10–19
- 98 Damstra RJ, Voesten HGJM, Klinkert P, Brorson H. Circumferential suction-assisted lipectomy for lymphoedema after surgery for breast cancer. *Br J Surg* 2009;96(08):859–864
- 99 Lee BB, Kim YW, Kim DI, Hwang JH, Laredo J, Neville R. Supplemental surgical treatment to end stage (stage IV-V) of chronic lymphedema. *Int Angiol* 2008;27(05):389–395
- 100 Hassan K, Chang DW. The Charles procedure as part of the modern armamentarium against lymphedema. *Ann Plast Surg* 2020;85(06):e37–e43