



# Modified Semilateral Decubitus Position for Shoulder Arthroscopy and Its Application for Open Surgery of the Shoulder (One Setting for All Shoulder Procedures)

Ekavit Keyurapan, M.D., and Chaiwat Chuaychoosakoon, M.D.

**Abstract:** Two standard patient positions for shoulder arthroscopy are the beach-chair and lateral decubitus positions. Both positions have advantages and disadvantages in many aspects. Surgeons choose the position based on their preferences, mainly the orientation of the anatomy. If an operation needs to be converted to an open procedure, a patient who is placed in the lateral decubitus position might need to undergo repositioning and re-draping, which result in extending the operative time and increasing the risk of infection. For this circumstance, the modified semilateral decubitus position offers the same advantages as the lateral decubitus position and can be adjusted to achieve a more upright position similar to the beach-chair position.

The standard patient positions in shoulder arthroscopy are the beach-chair and lateral decubitus positions. The advantages and disadvantages of these 2 positions have been reported.<sup>1-3</sup> For the beach-chair position, the advantages are better anatomic orientation, easy positioning, and the ability to convert to an open surgical procedure without repositioning and re-draping. These advantages make the beach-chair position suitable for extra-articular work such as subacromial surgery (e.g., rotator cuff repair) and open surgery (e.g., fracture fixation and joint replacement). On the other hand, the disadvantages of the beach-chair position are the possibility of mechanical blockage of the head and endotracheal tube by the anterior portal and the difficulty in approaching the

posterior and inferior part of the capsulolabral tissue for instability surgery. The beach-chair position also requires an assistant or mechanical arm holder to maintain the shoulder in a particular position. Moreover, hypotensive anesthesia is crucial to minimize bleeding in the surgical field without compromising the blood supply to the brain.<sup>4,5</sup>

The advantages of the lateral decubitus position include horizontal orientation of the glenohumeral joint. This position allows the surgeon to better access the posterior and inferior part of the joint during capsulolabral work. Traction force that is applied to the arm also helps to open the glenohumeral joint space, as well as the subacromial space. Regarding hypotensive anesthesia in the lateral decubitus position, there is less difference in blood pressure between the ankle and arm, so the risk of stroke may be less for this position.<sup>4</sup>

With regard to the disadvantages of the lateral decubitus position, brachial plexus and peripheral nerve injuries from prolonged traction have been reported,<sup>1,6</sup> as have pressure sores on the underside of the thorax during surgery.<sup>7</sup> However, the main concern with shoulder surgery in the lateral decubitus position is the vertical orientation of the subacromial structures, which might cause difficulty for a surgeon who is not familiar with this position. If a procedure needs to be converted from arthroscopic to open, a patient in the lateral decubitus position might need to undergo repositioning and re-draping, which cost extra time and might increase the risk of infection.

*From the Department of Orthopaedic Surgery, Faculty of Medicine, Siriraj Hospital, Mahidol University (E.K.), Bangkok; and Department of Orthopaedic Surgery and Physical Medicine, Faculty of Medicine, Prince of Songkla University (C.C.), Songkhla, Thailand.*

*The authors report that they have no conflicts of interest in the authorship and publication of this article. Full ICMJE author disclosure forms are available for this article online, as [supplementary material](#).*

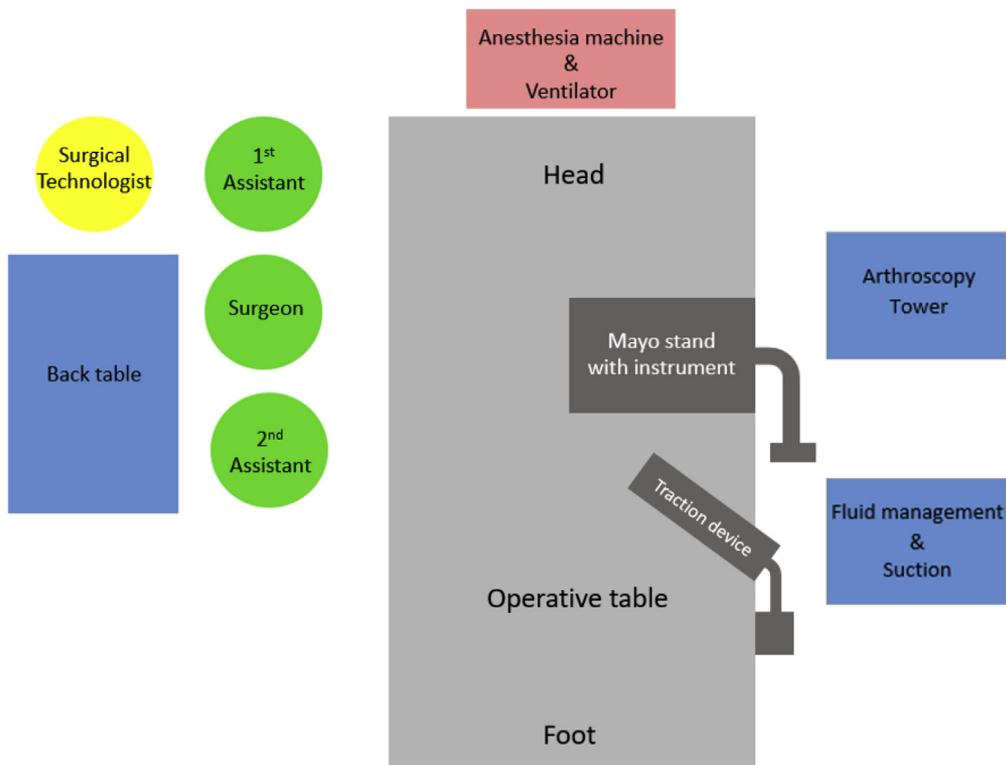
*Received July 21, 2017; accepted September 18, 2017.*

*Address correspondence to Ekavit Keyurapan, M.D., Department of Orthopaedic Surgery, Faculty of Medicine, Siriraj Hospital, Mahidol University, 2 Prannok Rd, Bangkoknoi, Bangkok 10700, Thailand. E-mail: [ekavit@gmail.com](mailto:ekavit@gmail.com)*

*© 2017 by the Arthroscopy Association of North America. Published by Elsevier. This is an open access article under the CC BY-NC-ND license (<http://creativecommons.org/licenses/by-nc-nd/4.0/>).*

*2212-6287/17884*

*<https://doi.org/10.1016/j.eats.2017.09.008>*



**Fig 1.** Layout of operating room setup for right shoulder surgery.

Thus, we propose the modified semilateral decubitus position that could be used to perform shoulder arthroscopy, similar to the lateral decubitus position. By flexing the operative table up, we can also perform open surgery without repositioning and re-draping.

## Surgical Technique

### Application of Anesthesia

In the operating room, the operative side is marked and confirmed by the surgeon. The patient receives an interscalene brachial plexus block combined with a laryngeal mask, endotracheal intubation, or sedation.

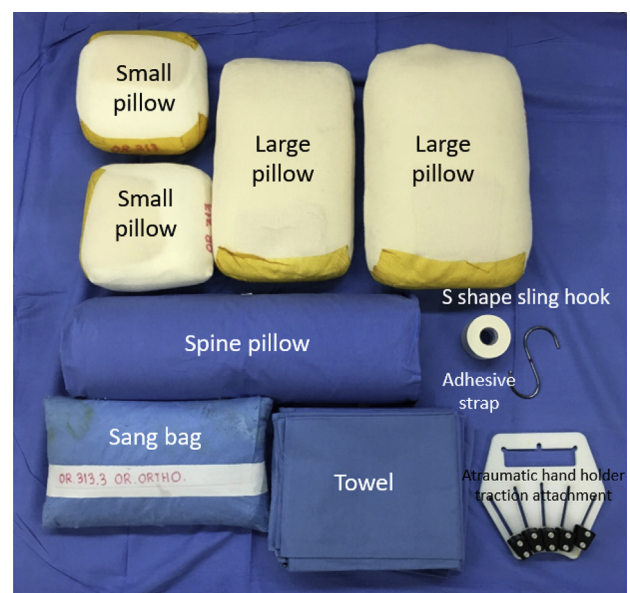
### Operating Room Setup and Patient Positioning Equipment

The operative setup is shown in [Figure 1](#). All equipment for patient positioning is shown in [Figure 2](#), comprising a padded spine pillow, 2 small pillows, 2 large pillows, towels, adhesive tape, a sandbag, an atraumatic hand-holder traction attachment (Arthrex, Naples, FL), and an S-shaped sling hook.

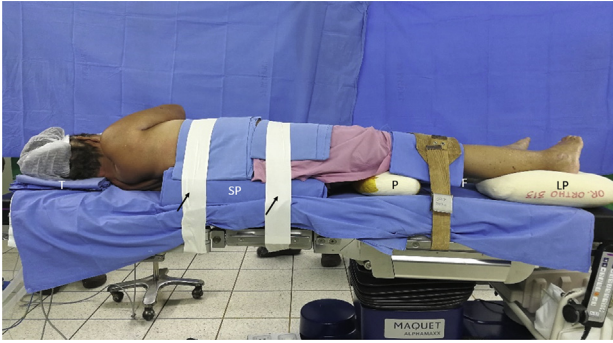
### Patient Positioning

The patient positioning technique is shown in [Video 1](#). After the patient is anesthetized, the sandbag is inserted underneath the buttock for the nonoperative side. Next, the surgical side of the body is turned up and supported by the spine pillow just inferior to the lower border of the

scapula. A pile of towels is placed under the head to prevent hyperextension of the neck. We do not use an axillary roll because the body weight is shared with the spine pillow from a leaning-back position. The nonoperative arm is secured on the arm board in 90° of abduction. Both legs are positioned and padded to protect the bony prominences and the common peroneal




**Fig 2.** Positioning equipment.



**Fig 3.** Patient in the semilateral decubitus position for surgery in right shoulder, viewing from posterior. The patient's head is supported by a pile of towels (T). The patient's body is supported by a spine pillow (SP) and secured by adhesive tape straps (arrows). The leg is supported by a small pillow (P) and a large pillow (LP) to free the fibular head area (F) and is secured by a restraint strap.

nerve (Fig 3). The body is strapped with 2-inch zinc oxide adhesive tape (Neotape; 3M, Bangkok, Thailand) over the towel at the level of the lower ribs and iliac crest. An additional strap is placed over both knees (conductive restraint strap; Steris, Montgomery, AL). The patient is then covered with warming blankets to prevent hypothermia (Bair Hugger lower-body blanket; 3M). The surgical-site skin is prepared and draped in sterile fashion



**Fig 4.** Patient in semilateral decubitus position prepared for right shoulder arthroscopy.

(Fig 4). The arm is covered with a sterile towel, covered by a STaR Sleeve (Arthrex), and connected to a 3-point shoulder distraction system (Arthrex). The shoulder is positioned in 30° of abduction and 45° of forward elevation with approximately 3 kg of weight. A sterile water-repellent drape (impervious split drape; Kimberly-Clark, Roswell GA) is applied around the shoulder for water drainage into a bucket.

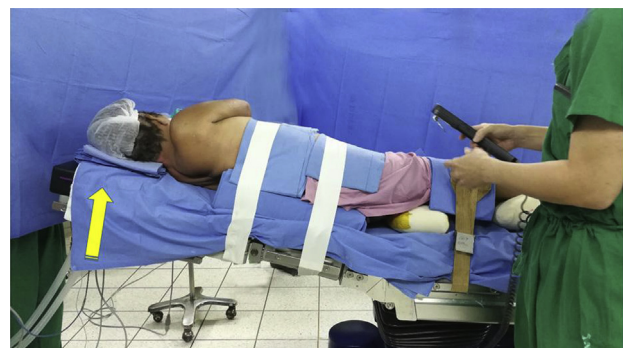### Open Surgery in Semilateral Decubitus Position

To adjust the semilateral decubitus position for open surgery, the middle part of the operative table is flexed to make the torso tilt 20° to 30° upright (Fig 5). Without traction, the scapula falls back because of gravity and scapulothoracic mobility. This position allows the surgeon to access the anterior part of the shoulder joint in an upright position, similar to the beach-chair position.

### Discussion

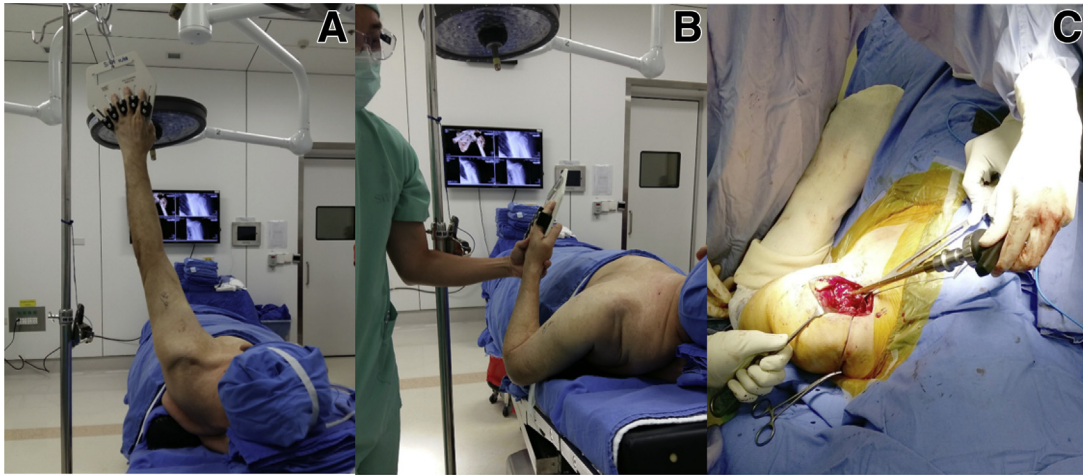
Two common patient positions for shoulder arthroscopy are the beach-chair and lateral decubitus positions. The beach-chair position has advantages over the lateral decubitus position in terms of upright anatomic orientation, easy conversion to an open procedure, better patient tolerance during regional anesthesia, and superior mobility of the arm during surgery. However, the disadvantages of the beach-chair position include the cost of setup, as well as mechanical blockage of the table and patient's head by the posterior portal and superior portal, respectively.<sup>1</sup> In contrast, the advantages of the lateral decubitus position are the traction force that opens the glenohumeral and subacromial space and the horizontal orientation of the glenoid that allows better access to the posterior labrum.

However, the main concerns with these 2 positions are neurovascular and cardiovascular risks. Traction in the lateral decubitus position may cause injuries to the



**Fig 5.** Modified semilateral decubitus position for open surgery in right shoulder. The upper part of the table is flexed and tilting upward (arrow) for a more upright shoulder position, similar to the beach-chair position.





**Fig 6.** Initial positioning for semilateral decubitus position. (A) The skin of the left shoulder is prepared with traction along the scapular plane using an atraumatic hand holder. (B) Full extension of the shoulder is achieved after traction is released, which allows preparation of the humeral stem without the obstruction of the patient's head. (C) Intraoperative photograph showing reaming of humeral canal for stem preparation.

brachial plexus and peripheral nerves.<sup>7</sup> To prevent traction injury to the brachial plexus, a traction weight of more than 7 kg should not be used.<sup>8,9</sup>

Compression of the fibular neck area to the operative table without appropriate padding can cause common peroneal nerve palsy,<sup>10</sup> whereas compression injuries to the superficial nerves and hypoglossal nerves from the beach-chair position have been reported.<sup>11</sup> Hypotension and bradycardia are other serious complications and can cause brain and spinal cord ischemia. Murphy et al.<sup>12</sup> studied cerebral desaturation events during shoulder arthroscopy using near-infrared spectroscopy and found significant reductions in cerebral oxygenation in patients in the beach-chair position compared with the lateral decubitus position. However, post-operative brain stroke has also been reported in a patient in the lateral decubitus position.<sup>13</sup>

To improve limitations in both surgical positions, Gross and Fitzgibbons<sup>14</sup> described a modification of lateral decubitus positioning by tilting the body back to 20° to 30° to position the glenoid parallel to the floor. Moreover, the direction of traction should be perpendicular to the humeral shaft, helping to open the joint space without subluxating the joint, as compared with traction along the arm.<sup>14</sup> Kim et al.<sup>15</sup> reported additional traction with the patient in the beach-chair position to improve the working space during surgery. Iamsumang and Chernchujit<sup>3</sup> described surgery with the patient in the supine position that could be used in instability procedures.

For our modified position, patient positioning is not straight lateral, but the patient's body is tilted back around 30° for the horizontal orientation of the glenoid according to Gross and Fitzgibbons.<sup>14</sup> However, we use less equipment for patient positioning; for example, no

beanbag is used to stabilize the torso, but a sandbag is used in the front and a spine pillow in the back. The patient's body is secured by adhesive tape straps and the conductive restraint strap. The advantage of this setting is the working space that does not have a beanbag in the way by positioning the spine pillow below the lower border of the scapula. We do not use an axillary roll because the patient's torso weight is shared by the spine pillow. For draping, only the wet area is covered by the water-repellent drape. Anatomic orientation is another issue of concern with the lateral decubitus position. For a more favorable anatomic orientation similar to the beach-chair position, we could adjust the position by flexing the surgical table and tilting the body piece up. The shoulder orientation will become more vertical, similar to the beach-chair position.

The described position can be applied to open surgery by flexing the upper part of the operating table up (Fig 6A), releasing traction, and allowing the scapula and arm to drop back. The patient's shoulder becomes more upright, close to the beach-chair position, with

**Table 1.** Pearls and Pitfalls of Shoulder Arthroscopic Surgery in Modified Semilateral Decubitus Position

Pearls

- The position of the patient should be stable after insertion of the spine pillow.
- The operative side of the shoulder should be free from the operative table.
- Traction weight should be <7 kg to prevent risk of neurapraxia.
- The traction position should be 45° in forward flexion and 30° in abduction.

Pitfall

- The surgeon requires some experience and practice to operate using the described viewing orientation.

**Table 2.** Comparison of Advantages of Shoulder Arthroscopic Surgery in Lateral Decubitus, Beach-Chair, and Modified Semilateral Decubitus Positions

Advantages	Lateral Decubitus	Beach Chair	Modified Semilateral Decubitus
Good access to subacromial space	●	●	●
Easy to perform instability repairs, SLAP repairs, and biceps work	●	●	●
Good exposure of glenoid	●	●	●
Excellent visualization of posterior and posteroinferior aspects of glenohumeral joint without need for trans-rotator cuff portals	●		●
Arthroscopic bubbles float to subdeltoid space out of field of view in subacromial space	●		●
Ease of anatomic reference in glenohumeral joint		●	
Ease of opening area between biceps anchor (SLAP region) and rotator cuff capsule	●		●
No obstruction of superior and posterior parts of shoulder by patient's head and operating table	●		●
Easy to convert to open procedure without repositioning or re-draping		●	●
Easy to perform fluoroscopic examination	●		●
Efficient setup	●		●

some degree of internal tilting of the body (Fig 6B). With this position, the surgeon can perform open surgery in the anterior part of the shoulder, similar to the beach-chair position, without much adjustment. This position also has enough room to allow working in the back and superior part of the shoulder. For shoulder arthroplasty, the critical step for patient positioning is the arm position, which needs to be fully extended and fully rotated for humeral component preparation (Fig 6C).

However, the modified semilateral decubitus position also has some difficulty in shoulder surgery, such as the biceps tenodesis technique that requires suturing of the

biceps stump. There is some difficulty in flexing the elbow that has been wrapped by the STaR Sleeve. If the surgeon needs to suture the biceps stump, the patient's arm has to be removed from traction and the elbow needs to be flexed, or a high anterior portal may be required for biceps tenodesis.<sup>16</sup> Therefore, we recommend using the suture anchor technique for biceps tenodesis.

In summary, the modified semilateral decubitus position is our universal position for performing shoulder surgical procedures, both arthroscopic and open. The advantages are ease of setup and flexibility allowing adjustment for open surgery if needed (Tables 1-3).

**Table 3.** Comparison of Disadvantages of Shoulder Arthroscopic Surgery in Lateral Decubitus, Beach-Chair, and Modified Semilateral Decubitus Positions

Disadvantages	Lateral Decubitus	Beach Chair	Modified Semilateral Decubitus
Orientation of anatomy	●		●
More difficult for training residents, especially with rotator cuff work	●		●
Usually requires general anesthetic	●		
Increased risk of cardiovascular and cerebral hypoperfusion		●	
Requires arm-holding sleeve and balanced suspension device	●		●
Less visualization in posterior and inferior aspects of joint		●	
Increased risk of neurapraxia to brachial plexus and peripheral nerve	●		●
More difficult to control arm rotation (external and/or internal), making access to some structures more difficult (e.g., subscapularis tears)	●		
Potential difficulty with conversion to open procedure	●		

## References

1. Peruto CM, Ciccotti MG, Cohen SB. Shoulder arthroscopy positioning: Lateral decubitus versus beach chair. *Arthroscopy* 2009;25:891-896.
2. Phillips BB. Arthroscopy of the upper extremity. In: Canale ST, Beaty JH, eds. *Campbell's operative orthopaedics*. Ed 12. Philadelphia: Mosby; 2012:2468-2469.
3. Iamsumang C, Chernchujit B. The supine position for shoulder arthroscopy. *Arthrosc Tech* 2016;5:e1117-e1120.
4. Papadonikolakis A, Wiesler ER, Olympio MA, Poehling GG. Avoiding catastrophic complications of stroke and death related to shoulder surgery in the sitting position. *Arthroscopy* 2008;24:481-482.
5. Laflam A, Joshi B, Brady K, et al. Shoulder surgery in the beach chair position is associated with diminished cerebral autoregulation but no differences in post-operative cognition or brain injury biomarker levels compared with supine positioning: The anesthesia patient safety foundation beach chair study. *Anesth Analg* 2015;120:176-185.
6. Gelber PE, Reina F, Caceres E, Monllau JC. A comparison of risk between the lateral decubitus and the beach-chair position when establishing an anteroinferior shoulder portal: A cadaveric study. *Arthroscopy* 2007;23:522-528.
7. Keyurapan E, Hu SJ, Redett R, McCarthy EF, McFarland EG. Pressure ulcers of the thorax after shoulder surgery. *Knee Surg Sports Traumatol Arthrosc* 2007;15:1489-1493.
8. Stanish WD, Peterson DC. Shoulder arthroscopy and nerve injury: Pitfalls and prevention. *Arthroscopy* 1995;11:458-466.
9. Weber SC, Abrams JS, Nottage WM. Complications associated with arthroscopic shoulder surgery. *Arthroscopy* 2002;18:88-95.
10. Knight DJ, Mahajan RP. Patient positioning in anaesthesia. *Contin Educ Anaesth Crit Care Pain* 2004;4:160-163.
11. Shah AC, Barnes C, Spiekerman CF, Bollag LA. Hypoglossal nerve palsy after airway management for general anesthesia: An analysis of 69 patients. *Anesth Analg* 2015;120:105-120.
12. Murphy GS, Szokol JW, Marymont JH, et al. Cerebral oxygen desaturation events assessed by near-infrared spectroscopy during shoulder arthroscopy in the beach chair and lateral decubitus positions. *Anesth Analg* 2010;111:496-505.
13. Zeidan A, Bluwi M, Elshamaa K. Postoperative brain stroke after shoulder arthroscopy in the lateral decubitus position. *J Stroke Cerebrovasc Dis* 2014;23:384-386.
14. Gross RM, Fitzgibbons TC. Shoulder arthroscopy: A modified approach. *Arthroscopy* 1985;1:156-159.
15. Kim K-C, Rhee K-J, Shin H-D. Beach-chair lateral traction position using a lateral decubitus distracter in shoulder arthroscopy. *Orthopedics* 2007;30:1001-1003.
16. Lo IKY, Burkhart SS. Arthroscopic biceps tenodesis using a bioabsorbable interference screw. *Arthroscopy* 2004;20:85-95.