



# Digital Necrosis in Granulomatosis with Polyangiitis

Philipp Jud<sup>1</sup>, Philipp Bosch<sup>1</sup>, Oleksiy Tsybrovskyy<sup>2</sup>

<sup>1</sup>Department of Internal Medicine, Medical University of Graz, Graz, Austria

<sup>2</sup>Department of Pathology, Medical University of Graz, Graz, Austria

A 73-year-old woman has necrotic lesions on her fingers that developed spontaneously within two weeks with no prior trauma (Figure 1). The physical examination and patient history were otherwise unremarkable. Initial laboratory testing revealed leucocytosis ( $12.31 \cdot 10^9/l$ ), neutrophilia ( $10.2 \cdot 10^9/l$ ), elevated CRP (101.2 mg/l), creatinine (2.12 mg/dl), and PR3 antineutrophil cytoplasmic antibodies ( $>200$  U/ml) with hematuria and proteinuria in urinalysis. Further diagnostic work-up revealed axonal sensorimotor polyneuropathy in electroneurography, occlusion of the radial and digital arteries in magnetic resonance imaging, and pauci-immune crescentic glomerulonephritis in renal biopsy (Figure 2) with unremarkable otorhinolaryngological examination and thoracic computer tomography. A diagnosis of granulomatosis with polyangiitis (GPA) was made, and treatment with corticosteroids, rituximab, and cyclophosphamide was started concurrently. Aspirin and prostaglandins were previously used to

treat digital necrosis. Renal parameters were stable six months after initial presentation (creatinine 2.26 mg/dl), thanks to maintenance therapy with rituximab and corticosteroids. The digital necrosis on the patient's second finger remained because she refused surgical removal due to her concern of being unable to pursue her hobby of playing the piano.

GPA typically manifests as renal and pulmonary involvement, with cutaneous manifestations occurring in up to 54% of cases.<sup>1</sup> However, the initial presentation of digital necrosis is a very unusual feature of GPA, with only a few cases reported.<sup>2</sup> Active vasculitis can cause destruction and thrombus formation within the affected vessels, resulting in digital ischemia and, in severe cases, digital necrosis.<sup>3</sup> Therefore, early detection and initiation of adequate treatment are critical.

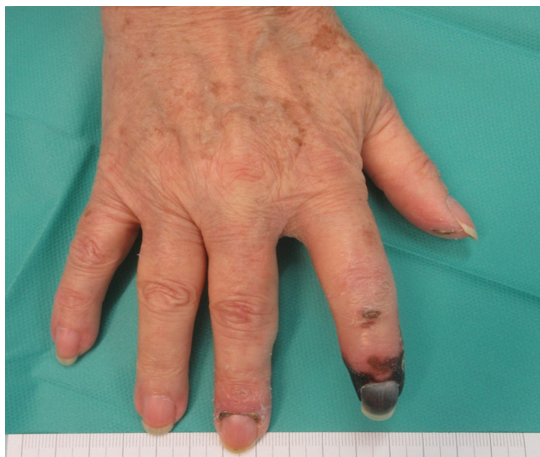

FIG. 1. Digital necrosis of the patient's right second finger, with necrotic lesions on the patient's right thumb and the middle finger's nail fold.

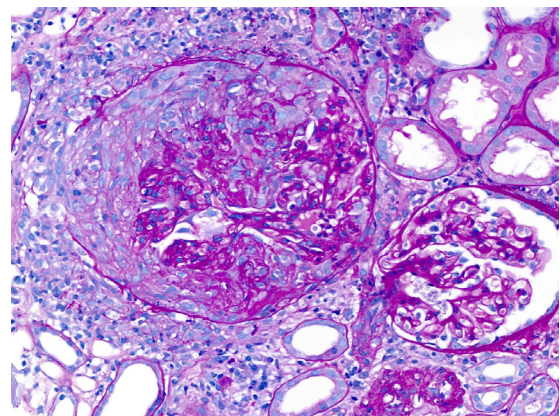


FIG. 2. Patient's kidney biopsy revealing proliferating glomerular epithelial cells (cellular crescents), a rupture of the Bowman's capsule, and a periglomerular inflammatory reaction corresponding to pauci-immune crescentic glomerulonephritis (periodic acid-Schiff stain, 40x original objective magnification).



Corresponding author: Philipp Jud, Department of Internal Medicine, Medical University of Graz, Graz, Austria  
e-mail: philipp.jud@medunigraz.at

Received: October 20, 2022 Accepted: December 30, 2022 Available Online Date: Jan 23, 2023 • DOI: 10.4274/balkanmedj.galenos.2022.2022-10-78

Available at [www.balkanmedicaljournal.org](http://www.balkanmedicaljournal.org)

ORCID iDs of the authors: P.J. 0000-0002-0832-1322; P.B. 0000-0002-6783-6422; O.T. 0000-0002-3998-1649.

Cite this article as:

Jud P, Bosch P, Tsybrovskyy O. Digital Necrosis in Granulomatosis with Polyangiitis. *Balkan Med J.*; 2023; 40(1):68-9.

Copyright@Author(s) - Available online at <http://balkanmedicaljournal.org/>

**Informed Consent:** The authors declare that written consent was obtained from the patient.

**Author Contributions:** Concept – P.J.; Data Collection or Processing- P.J., P.B., O.T.; Analysis or Interpretation- P.J., P.B., O.T.; Literature Review – P.J., P.B., O.T.; Writing – P.J.

**Conflict of Interest:** All author declare no conflicts of interest.

## REFERENCES

1. Montero-Vilchez T, Martinez-Lopez A, Salvador-Rodriguez L, et al. Cutaneous Manifestations of Granulomatosis with Polyangiitis: A Case Series Study. *Acta Derm Venereol.* 2020;100:adv00150. [\[CrossRef\]](#)
2. Lau RA, Bains R, Suraweera D, et al. A Rare Case of Digital Ischemia and Gangrene in ANCA-Associated Vasculitis with Review of the Literature. *Case Rep Rheumatol.* 2017;2017:2421760. [\[CrossRef\]](#)
3. Phillips RW, Twiest MW. Wegener's granulomatosis and gangrene in the feet. *Ann Intern Med.* 1983;99:571. [\[CrossRef\]](#)