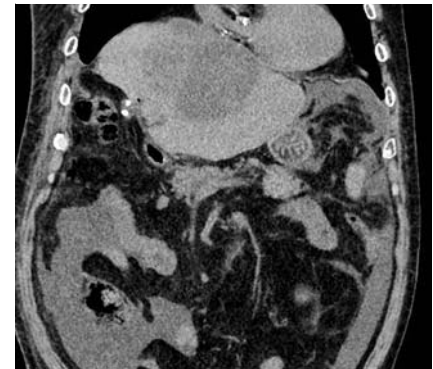


Endoscopic ultrasound-guided transgastric pyogenic liver abscess drainage using a drill dilator



► **Fig. 1** Photograph of the novel drill dilator (Tornus ES; Asahi Intecc).



► **Fig. 2** Computed tomography scan showing a pyogenic liver abscess at segment 4 and the caudate lobe.

Percutaneous transhepatic drainage (PTD) is the gold standard treatment for pyogenic liver abscess [1], but PTD can be challenging where a pyogenic liver abscess is located at a site that is difficult to access via the percutaneous approach and in patients with severe dementia, in whom self-removal of the tube is a risk. An endoscopic ultrasound (EUS)-guided procedure offers internal drainage via a transluminal approach and may be an alternative option in such cases. Several studies have reported the clinical benefits of EUS-guided access for pyogenic liver abscesses [2–4]; however, this technique requires tract dilation prior to metal stent deployment. In patients with a pyogenic liver abscess, severe inflammation can cause the cystic wall to become thickened and hardened and this can make tract dilation challenging.

A novel drill dilator has recently become available in Japan (Tornus ES; Asahi Intecc) (► **Fig. 1**) [5]. This allows a tract to be easily dilated using a clockwise rotation of the device handle, without force needing to be applied. We herein describe EUS-guided transgastric pyogenic liver abscess drainage using a drill dilator. An 89-year-old man was admitted to our hospital for treatment of a pyogenic liver abscess (► **Fig. 2**). The percutaneous approach was difficult because the abscess was located at segment 4 and the caudate lobe, with intervening vessels, and EUS-guided access was therefore selected. The abscess was punctured from the stomach using a 19G needle and contrast medium was injected. Balloon catheter insertion was attempted after deployment of a 0.025-inch guidewire (► **Fig. 3 a**); however, the procedure

failed because the wall of the abscess was extremely hard. We then attempted drill dilator insertion and easily achieved successful tract dilation (► **Fig. 3 b**). Finally, a partially covered self-expandable metal stent was deployed from the pyogenic liver abscess to the stomach, with no adverse events (► **Fig. 3 c**; ► **Video 1**).

In conclusion, a drill dilator appears to be useful for pyogenic liver abscess drainage, as well as for bile duct dilation.

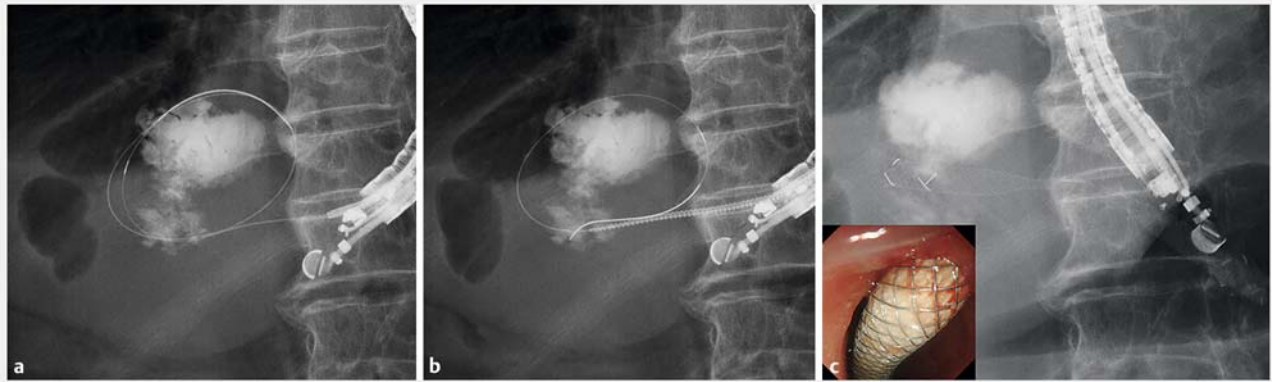
Endoscopy_UCTN_Code_TTT_1AS_2AD

Competing interests

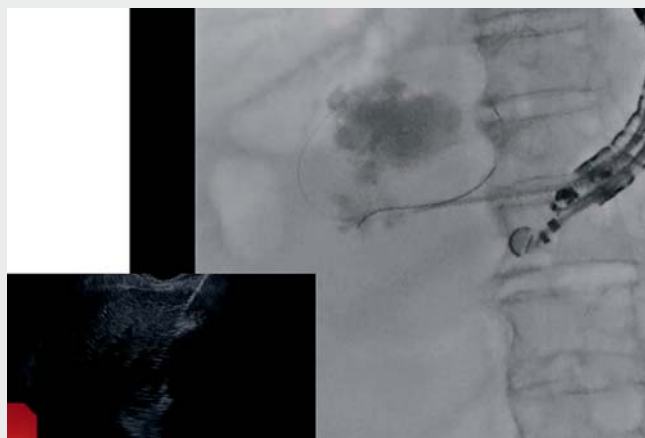
The authors declare that they have no conflict of interest.

The authors

Takeshi Ogura, Yuki Uba, Mitsuki Tomita, Masahiro Yamamura, Hiroki Nishikawa
2nd Department of Internal Medicine, Osaka Medical and Pharmaceutical University, Osaka, Japan



► **Fig. 3** Fluoroscopic images showing: **a** a 0.025-inch guidewire deployed after puncture of the pyogenic liver abscess with a 19G needle; **b** the drill dilator being easily inserted under endoscopic ultrasound guidance; **c** transgastric drainage of the abscess with a self-expandable metal stent (inset, endoscopic view).



► **Video 1** Endoscopic ultrasound-guided drainage of a pyogenic liver abscess using a novel drill dilator.

Bibliography

Endoscopy 2023; 55: E342–E343

DOI 10.1055/a-1990-0798

ISSN 0013-726X

© 2023. The Author(s).

This is an open access article published by Thieme under the terms of the Creative Commons Attribution-NonDerivative-NonCommercial License, permitting copying and reproduction so long as the original work is given appropriate credit. Contents may not be used for commercial purposes, or adapted, remixed, transformed or built upon. (<https://creativecommons.org/licenses/by-nc-nd/4.0/>)

Georg Thieme Verlag KG, Rüdigerstraße 14, 70469 Stuttgart, Germany



Corresponding author

Takeshi Ogura, MD

2nd Department of Internal Medicine,
Osaka Medical and Pharmaceutical
University, 2-7 Daigakuchou, Takatsukishi,
Osaka 569-8686, Japan
oguratakeshi0411@yahoo.co.jp

References

- [1] Singh S, Chaudhary P, Saxena N et al. Treatment of liver abscess: prospective randomized comparison of catheter drainage and needle aspiration. *Ann Gastroenterol* 2013; 26: 332–339
- [2] Ogura T, Masuda D, Saori O et al. Clinical outcome of endoscopic ultrasound-guided liver abscess drainage using self-expandable covered metallic stent (with video). *Dig Dis Sci* 2016; 61: 303–308
- [3] Tonzuka R, Itoi T, Tsuchiya T et al. EUS-guided drainage of hepatic abscess and infected biloma using short and long metal stents (with videos). *Gastrointest Endosc* 2015; 81: 1463–1469
- [4] Rana SS, Ahmed S, Sharma R et al. Safety and efficacy of EUS-guided drainage of liver abscess: A single-center experience. *Endosc Ultrasound* 2020; 9: 350–351
- [5] Yamada M, Hara K, Haba S et al. Endoscopic ultrasound-guided hepaticogastrostomy using a novel drill dilator. *Endoscopy* 2022. doi:10.1055/a-1838-3682

ENDOSCOPY E-VIDEOS

<https://eref.thieme.de/e-videos>



Endoscopy E-Videos is an open access online section, reporting on interesting cases and new techniques in gastroenterological endoscopy. All papers include a high quality video and all contributions are freely accessible online. Processing charges apply (currently EUR 375), discounts and waivers acc. to HINARI are available.

This section has its own submission website at <https://mc.manuscriptcentral.com/e-videos>