

# Left ventricular tamponade- pathophysiology determines the therapeutic approach: a case series

Barun Kumar<sup>1</sup>, Ashwin Kodliwadmth <sup>1\*</sup>, Anupam Singh <sup>2</sup>, Amar Upadhyay<sup>3</sup>, Anshuman Darbari <sup>4</sup>, and Bhanu Duggal<sup>1</sup>

<sup>1</sup>Department of Cardiology, All India Institute of Medical Sciences (AIIMS), Rishikesh, Uttarakhand, India; <sup>2</sup>Department of Ophthalmology, All India Institute of Medical Sciences (AIIMS), Rishikesh, Uttarakhand, India; <sup>3</sup>Department of Paediatrics, Doon Medical College, Dehradun, Uttarakhand, India; and <sup>4</sup>Department of CTVS, All India Institute of Medical Sciences (AIIMS), Rishikesh, Uttarakhand, India

Received 14 June 2020; first decision 10 August 2020; accepted 18 November 2020

## Background

Left ventricular (LV) tamponade is rare. LV tamponade can occur in cases of a loculated pericardial effusion overlying the LV and in cases of circumferential pericardial effusions in patients with severe pulmonary arterial hypertension (PAH). Both causes of LV tamponade share the common feature of not presenting with the classical features of cardiac tamponade. However, the therapeutic approach of the two is different.

## Case summary

Here, we report two cases of LV tamponade. The first patient was a case of post-mitral valve replacement who presented with loculated posterior pericardial effusion with LV tamponade. Due to the loculated and posterior nature of the effusion, his pericardial fluid was drained from the axilla by echocardiographic and fluoroscopic guidance. The second patient presented with features of severe PAH with a circumferential pericardial effusion and LV tamponade. Due to the circumferential nature of the effusion, the pericardiocentesis was performed from the subxiphoid route.

## Discussion

The pathophysiology of LV tamponade must be determined accurately before performing pericardiocentesis. Left ventricular tamponade in patients with severe PAH and non-loculated circumferential effusion can be drained from the subxiphoid route, while LV tamponade due to loculated effusion overlying LV must be drained by echocardiographic and fluoroscopic guidance from the axilla.

## Keywords

Pulmonary artery hypertension • Prosthetic heart valve • Pericardial effusion • Cardiac tamponade • Pericardiocentesis • Case report • Case series

## Learning points

- Left ventricular (LV) tamponade can occur in patients with circumferential pericardial effusion and severe pulmonary artery hypertension (PAH) or in patients with loculated effusion overlying LV.
- Both aetiologies of LV tamponade share the common feature of absence of classical features of cardiac tamponade.
- Left ventricular tamponade in patients with severe PAH can be drained from the subxiphoid route while LV tamponade due to loculated effusion overlying LV must be drained from the axilla.

\* Corresponding author. Tel: +918312470157, +919743458960. Email: [ashrocks33@gmail.com](mailto:ashrocks33@gmail.com)

Handling Editor: Amardeep Ghosh Dastidar

Peer-reviewers: Richard Alexander Brown and Ojas H Mehta

Compliance Editor: Hibba Kurdi

Supplementary Material Editor: Aiste Monika Jakstaite

© The Author(s) 2020. Published by Oxford University Press on behalf of the European Society of Cardiology.

This is an Open Access article distributed under the terms of the Creative Commons Attribution Non-Commercial License (<http://creativecommons.org/licenses/by-nc/4.0/>), which permits non-commercial re-use, distribution, and reproduction in any medium, provided the original work is properly cited. For commercial re-use, please contact [journals.permissions@oup.com](mailto:journals.permissions@oup.com)

## Introduction

Cardiac tamponade is characterized by classical Beck's triad and pulsus paradoxus. It results in diastolic collapse of the right ventricle (RV), diagnosed accurately by echocardiography.<sup>1</sup> Left ventricular (LV) tamponade is rare and can occur in special circumstances like regional pericardial effusion overlying LV,<sup>2</sup> or in circumferential pericardial effusion in patients with severe pulmonary arterial hypertension (PAH).<sup>3</sup> Left ventricular tamponade rarely presents with the classical clinical features of tamponade and hence diagnosis is often delayed.<sup>4,5</sup> Here, we report two cases of LV tamponade. One patient presented with loculated pericardial effusion overlying LV following mitral valve replacement while the 2nd patient presented with circumferential pericardial effusion on the background of severe PAH. The therapeutic approach to draining these effusions was determined based on the pathophysiology of the LV tamponade.

## Timeline

Time	Event
Case 1	
Day 1	A 50-year-old gentleman underwent mitral valve replacement.
Day 8	Discharged on tablet warfarin 5 mg after normal echocardiography.
Day 13	Presented to emergency department with vomiting, uneasiness, and breathlessness since 2 days. He was in shock with investigations showing deranged coagulation parameters, normal functioning prosthetic valve, and posterior loculated pericardial effusion with left ventricular (LV) collapse. Warfarin withheld and underwent pericardiocentesis from axillary route.
Day 16	International normalized ratio (INR) therapeutic and warfarin restarted.
Day 18	Pigtail catheter removed.
Day 21	Discharged with normal vitals and echocardiography on Optimal medical therapy (OMT).
Day 30	Followed up in Out-patient department (OPD) with normal echo and INR therapeutic
Day 60	Followed up in OPD with normal echo and INR therapeutic.
Case 2	
Day 1, 9:00 a.m.	28-year-old lady admitted with New York Heart Association Class III dyspnoea in shock. Initially stabilized in intensive care unit.
2:00 p.m.	Underwent transthoracic echocardiography showing severe pulmonary arterial hypertension with circumferential pericardial effusion

*Continued*

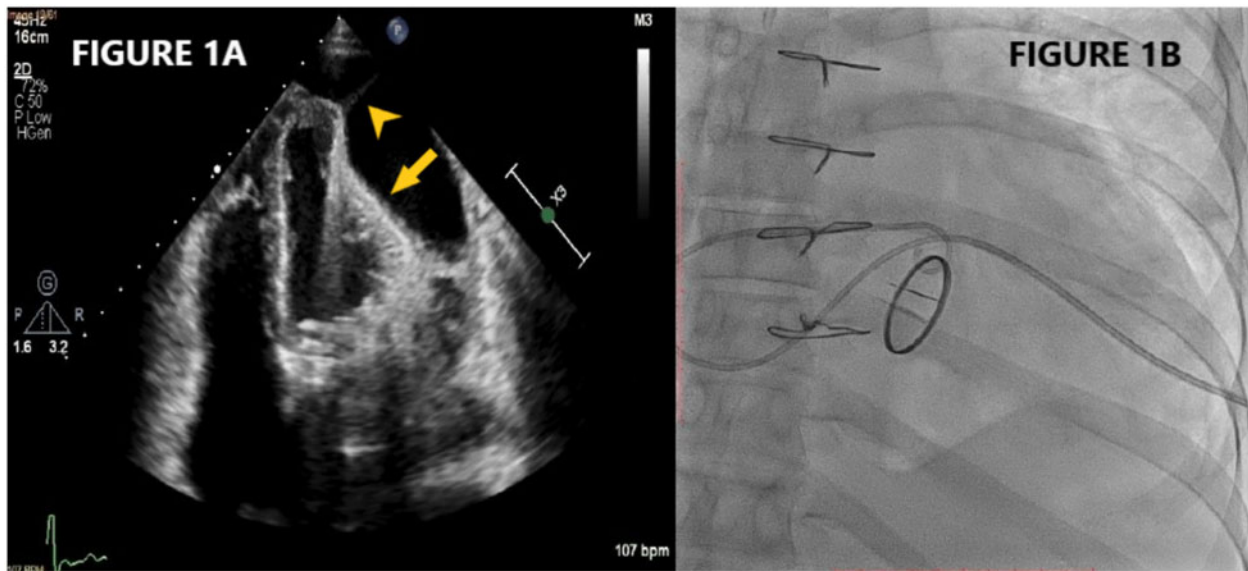
### Continued

Time	Event
	with LV tamponade. All routine investigations sought and medical management intensified.
4:00 p.m.	Underwent pericardiocentesis through subxiphoid route resulting in improvement in haemodynamics.
6:00 p.m.	Had cardiac arrest and cardio-pulmonary resuscitation started.
7:00 p.m.	Declared dead.

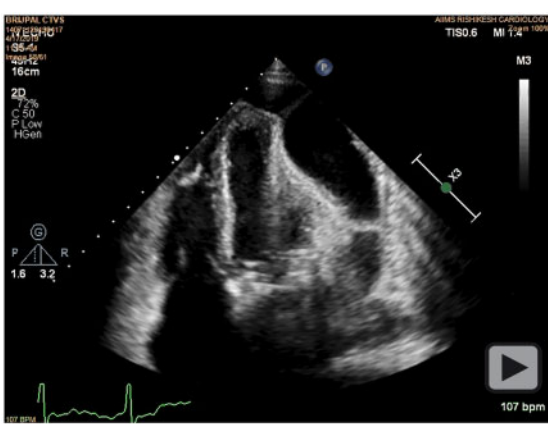
## Case presentation

### Case 1

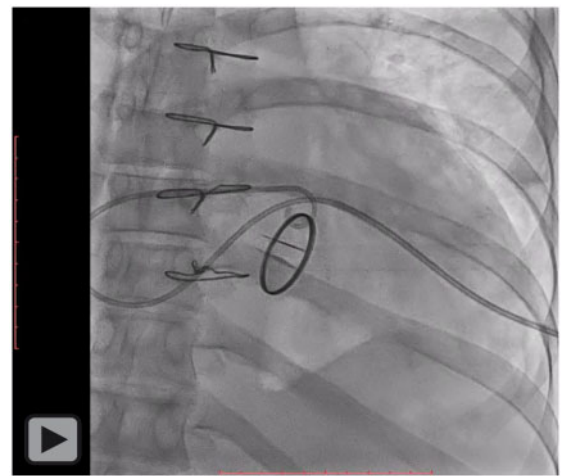
We report the case of a 50-year-old gentleman of North Indian ethnicity, a shopkeeper by occupation, who underwent mitral valve replacement with St. Jude's Medical (SJM) No. 31 prosthetic valve for rheumatic severe mitral stenosis and moderate mitral regurgitation. He was discharged with normal post-procedure examination and echocardiography on a post-operative Day 8 with tablet warfarin 5 mg o.d. along with other optimal medical therapy. He presented to the emergency department on the 13th post-operative day with the chief complaints of vomiting, uneasiness, and breathlessness for 2 days. Physical examination revealed a sick, restless man with a heart rate of 118 beats/min and respiratory rate of 30 breaths/min and blood pressure (BP) of 70/50 mmHg. There was no pulsus paradoxus or raised jugular venous pressure (JVP). Cardiovascular system examination revealed metallic opening and closing clicks and no murmur on auscultation. Investigations were significant for a 12 lead surface electrocardiogram (ECG) showing low voltage complexes, chest X-ray showing enlargement of the cardiac silhouette and a transthoracic echocardiographic study showing posterior loculated pericardial effusion and LV diastolic collapse (*Figure 1A, Video 1*). His prothrombin time/international normalized ratio (PT/INR) had increased from 2.52 to 6.25, haemoglobin had fallen from 132 to 90 g/L, and haematocrit had fallen from 45.53% to 28.8%. Transthoracic echocardiography and fluoroscopy confirmed normal functioning of the prosthetic valve (*Video 2*). After written informed consent, pericardiocentesis was done from left mid-axillary line in the 7th intercostal space with fluoroscopy and echocardiography guidance and 250 mL of bloody pericardial fluid was removed (*Figure 1B, Video 2*). Immediately after removal of pericardial fluid, the patient improved symptomatically with improvement in the BP. Post-pericardiocentesis echocardiography showed no pericardial effusion or evidence of LV diastolic collapse. Warfarin was withheld in view of increased INR and treated with 8 units of fresh frozen plasma and injection vitamin K for 3 days. Repeat PT/INR after 3 days showed INR of 2.4 and warfarin was restarted in a dose of 2 mg o.d. The pericardial fluid was drained 6th hourly daily for 4 days until there was no aspirate after which the pigtail catheter was removed on 5th post-procedure day. He was discharged after 3 days of pigtail removal with normal vitals. Follow-up after 9 days and after 40 days revealed excellent physician and patient assessed outcomes, with normal echocardiography and therapeutic INR.



**Figure 1** (A) Transthoracic echocardiography in apical four-chamber view showing prosthetic mitral valve, absence of right ventricular collapse, presence of posterior pericardial effusion with left ventricular diastolic collapse (arrow), and presence of loculations within the pericardium (arrow-head). (B) Fluoroscopy image showing presence of prosthetic mitral valve and pigtail catheter being inserted into the pericardium from the axilla.



**Video 1** Transthoracic echocardiography in apical four-chamber view showing opening and closing click of prosthetic mitral valve, absence of right ventricular collapse, presence of posterior pericardial effusion with left ventricular diastolic collapse, and presence of loculations within the pericardium.

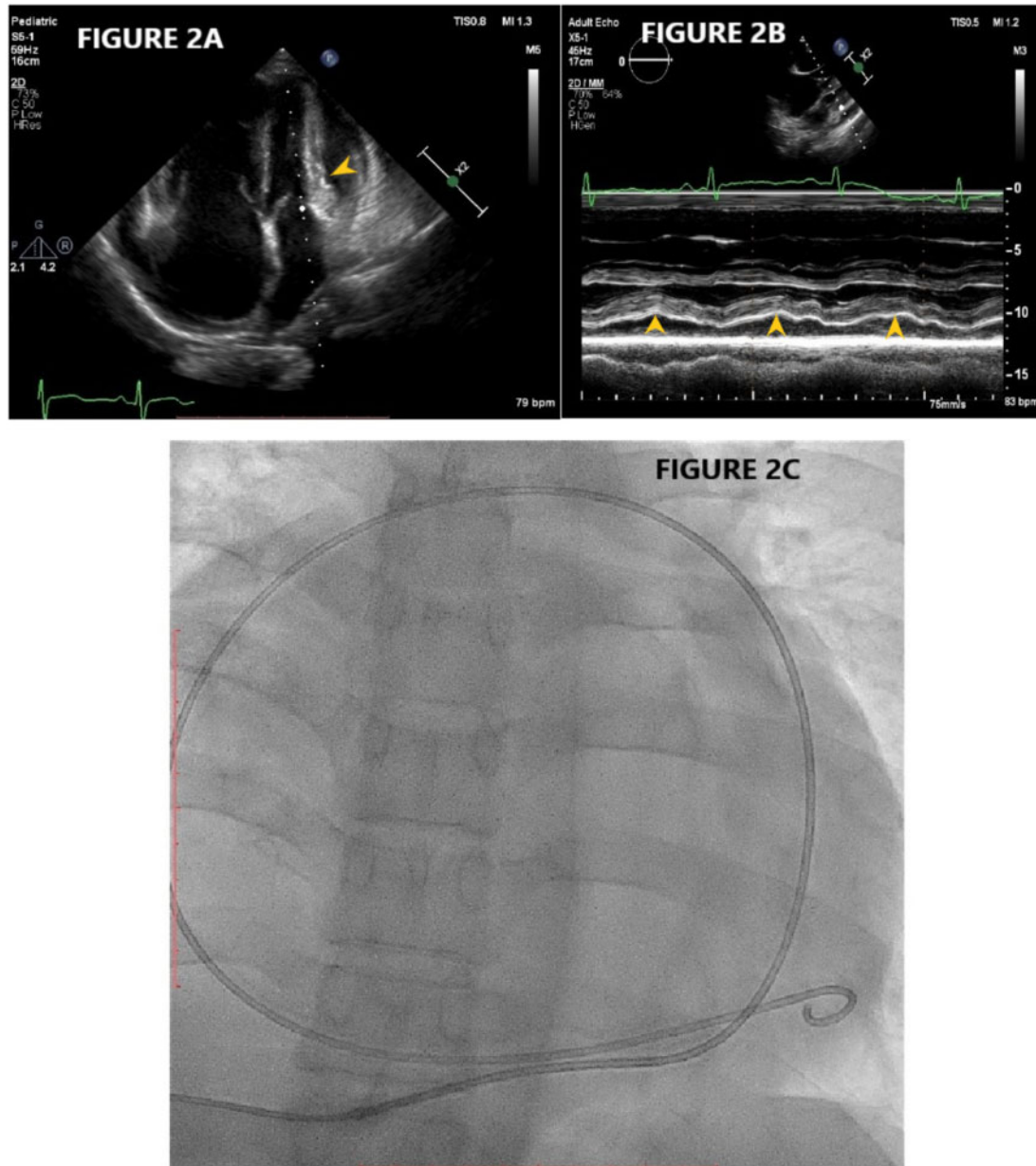


**Video 2** Fluoroscopy movie showing opening and closing click of prosthetic mitral valve and pigtail catheter being inserted into the pericardium from the axilla.

## Case 2

We report the case of a 28-year-old lady of North Indian ethnicity, homemaker by occupation, who presented to us with complaints of exertional dyspnoea since 1 year, increased since 1 month, presently in New York Heart Association Class III with history of two episodes of syncope since 1 month. On examination, she was found to have a pulse rate of 114 b.p.m., BP of 70/40 mmHg, right ventricular type apex, loud P2, Grade 3 parasternal heave, and muffled

heart sounds with raised JVP with prominent cv waves, tender hepatomegaly, and no paradoxical pulse. Twelve-lead surface ECG showed low voltage complexes. Transthoracic echocardiography showed dilated right-sided cardiac chambers, severe tricuspid regurgitation with right ventricular systolic pressure of 113 mmHg, circumferential pericardial effusion with LV diastolic collapse (*Figure 2A* and *B*, *Video 3*). After written informed consent, she was



**Figure 2** (A) Transthoracic echocardiography in apical four-chamber view showing dilated right atrium and ventricles, circumferential pericardial effusion with left ventricular diastolic collapse (arrowhead). (B) Transthoracic echocardiography M-mode through right and left ventricles showing presence of left ventricular diastolic collapse (arrowheads). (C) Fluoroscopy image showing pigtail catheter being inserted into the pericardium from the subxiphoid route.

immediately shifted to the catheterization laboratory for pericardiocentesis. Pericardiocentesis was done through subxiphoid route with echocardiography and fluoroscopy guidance and 300 mL of straw-coloured pericardial fluid was removed (Figure 2C). Post-procedure, the BP improved to 120/70 mmHg and the patient improved symptomatically with resolution of pericardial effusion and LV collapse on echocardiography. She was shifted to the cardiac care unit for further management. After about 2 h, she had a sudden cardiac arrest with rhythm showing asystole and cardio-pulmonary resuscitation (CPR) was started according to

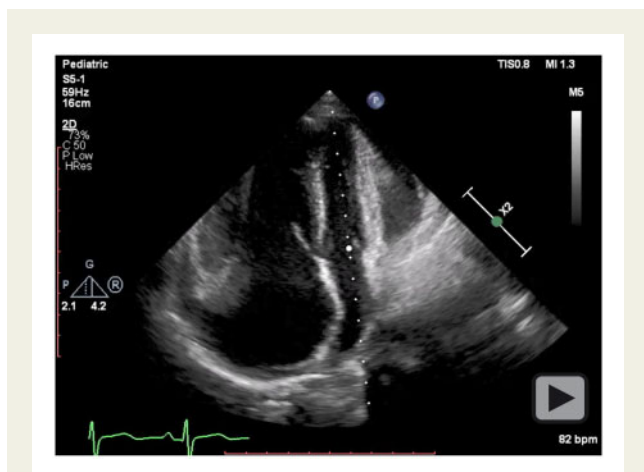
advanced cardiac life support protocol. Even after 60 min of high-quality CPR, she could not be revived and declared dead.

## Discussion

### Cardiac tamponade

Cardiac tamponade is clinically suspected in a patient with hypotension, raised JVP, and muffled heart sounds—which constitute the Beck's triad. The classical pulsus paradoxus, decrease in the systolic





**Video 3** Transthoracic echocardiography in apical four-chamber view showing dilated right atrium and ventricles, circumferential pericardial effusion with left ventricular diastolic collapse.

blood pressure by  $>10$  mmHg during inspiration can be the first clue to the diagnosis. Echocardiography is the investigation of choice for tamponade which shows early diastolic collapse of the right ventricle, the late diastolic collapse of the right atrium, exaggerated variation in RV and LV chamber size, and interventricular septal shifting during inspiration.<sup>1</sup> Due to low pressures in the right atrium (RA)/RV and thinner RV, the haemodynamic effects are evident on right side of the heart while the left side being spared due to high systemic pressures.<sup>6</sup>

### Left ventricular tamponade

Due to the high pressures in the left-sided chambers, tamponade of LV is rare and can occur in special circumstances. One mechanism is pericardial effusion in presence of high pressures in the right-sided cardiac chambers that exceed that in left, as in severe PAH. Another mechanism is loculated effusion posterior to LV, where the effusion will exert pressure over the underlying LV causing collapse. Loculated effusions most commonly occur post-operatively and commonly occur posteriorly and laterally.<sup>4</sup> The presence of adhesions in the pericardial space likely increases regional intrapericardial pressure beyond intracavitary diastolic pressure, thus causing invagination and collapse of the ventricular wall.<sup>7</sup> In regional left heart tamponade, the absence of pericardial fluid anteriorly allows free expansion of RV in inspiration without interfering with LV filling and thus not causing decrease BP and not resulting in pulsus paradoxus.<sup>2</sup>

Pericardial effusions in PAH indicate an advanced stage of severe PAH with right ventricular failure. Pericardial effusion worsens the paradoxical interventricular septal motion characterized by displacement of the interventricular septum into the left ventricle during inspiration which impairs the preload of the left ventricle and leads to further decreases in cardiac output. When the increased intrapericardial pressure exceeds the left ventricular diastolic pressure, there is left atrial and/or ventricular diastolic collapse. The right ventricular diastolic collapse is absent due to the elevated right-sided pressures that are higher than the pericardial pressure. Hypotension may be absent in some of these patients because of a compensatory increase in

systemic vascular resistance.<sup>5</sup> Pulsus paradoxus is absent because elevated right ventricular pressure and volume prevent the inspiratory drop in pleural pressure from further increasing right ventricular preload and stroke volume.<sup>3</sup> Left ventricular tamponade is related to the severity of PAH not the aetiology. It can occur with severe PAH of any aetiology. Thus, both aetiologies of LV tamponade result in absence or rarity of the classical features of cardiac tamponade—hypotension, RV collapse, and pulsus paradoxus.

### Pericardiocentesis

Pericardial fluid drainage can be accomplished either by percutaneous pericardiocentesis or subxiphoid pericardiotomy. The various approaches for percutaneous pericardiocentesis are subxiphoid, parasternal, and apical. Each of the three approaches has their advantages and disadvantages. Though the subxiphoid approach is most commonly used and has a lower risk of pneumothorax, it has the risk of hepatic or peritoneal injury and takes a longer path to reach the pericardial space. The parasternal approach also carries the risk of pneumothorax. Though the apical approach carries a higher risk of pneumothorax and ventricular puncture, it takes a shorter path to the pericardial cavity and the puncture, if occurs, self-heals due to thickness of the LV.<sup>8</sup> Echo-guided pericardiocentesis is the preferred technique as it is simple and safe. Fluoroscopy-guided pericardiocentesis is standardized and effective and can complement the echo-guided approach. The more invasive technique, subxiphoid surgical pericardiotomy should be selected in cases in which percutaneous pericardiocentesis is unsuccessful or when the echocardiographic examination discourages a percutaneous approach.<sup>9</sup> LV tamponade with loculated effusion mandates the axillary approach. The role of pericardiocentesis is controversial in patients with PAH.<sup>10</sup> Pericardiocentesis in patients with severe PAH is accompanied by further haemodynamic deterioration and death in patients with pre-existing right heart failure. It is believed that rapid fluid removal allows the already dilated right ventricle to further expand, thereby acutely decreasing left ventricular diastolic filling and cardiac output.<sup>3</sup> Though pericardiocentesis in PAH is controversial, tamponade is a clear indication for drainage.<sup>5</sup>

### Pathophysiology of left ventricular tamponade determines the therapeutic approach

Left ventricular tamponade caused by severe PAH can be approached from the standard subxiphoid route. As the effusion in such a circumstance is circumferential, the drainage of the fluid anterior to RV itself will decrease the fluid within the whole pericardium and result in resolution of LV collapse. It can also be approached from the axilla, but as the subxiphoid route is more convenient, common and has lesser complications, it is the preferred route.

But in patients with LV tamponade due to loculated effusion, the subxiphoid approach may not be useful as the pigtail catheter may not reach the effusion due to the loculations and rather be dangerous carrying the risk of RV perforation, thus mandating an axillary approach by echocardiography and fluoroscopy guidance. Thus, though LV tamponade is rare, demonstrating the pathophysiology of LV tamponade accurately by echocardiography is a must before planning pericardiocentesis.

## Conclusion

Left ventricular tamponade is rare. It can occur in patients with circumferential pericardial effusion and severe PAH or in patients with loculated effusion overlying LV. The clinical recognition of LV tamponade is difficult as the classical signs of tamponade are often absent. The pathophysiology of LV tamponade must be determined accurately before performing pericardiocentesis. Though pericardial fluid drainage in LV tamponade due to severe PAH is controversial, it is definitely indicated in haemodynamically unstable patients. Left ventricular tamponade in patients with severe PAH and non-loculated circumferential effusion can be drained from the subxiphoid route, while LV tamponade due to loculated effusion overlying LV must be drained by echocardiographic and fluoroscopic guidance from the axilla.

## Lead author biography



Dr Barun Kumar is an interventional cardiologist and Associate Professor of Cardiology at All India Institute of Medical Sciences, Rishikesh, India. He has special interest in the field of Interventional Cardiology.

## Supplementary material

Supplementary material is available at *European Heart Journal - Case Reports* online.

**Slide sets:** A fully edited slide set detailing this case and suitable for local presentation is available online as [Supplementary data](#).

**Consent:** The authors confirm that written consent for submission and publication of this case report including images and associated text has been obtained from the patient in line with COPE guidelines.

**Conflict of interest:** none declared.

**Funding:** none declared.

## References

- Lewinter MM, Hopkins WE. Pericardial diseases. In: DL Mann, DP Zipes, P Libby, R Bonow (eds) *Braunwald's Heart Disease: A Textbook of Cardiovascular Medicine*, 10th edn. Philadelphia: Elsevier; 2015. p1640–1644.
- Schwartz SL, Pandian NG, Cao QL, Hsu TL, Aronovitz M, Diehl J. Left ventricular diastolic collapse in regional left heart cardiac tamponade: an experimental echocardiographic and hemodynamic study. *J Am Coll Cardiol* 1993;**22**: 907–913.
- Adams JR, Tonelli AR, Rokadia HK, Duggal A. Cardiac tamponade in severe pulmonary hypertension. A therapeutic challenge revisited. *Annals ATS* 2015;**12**: 455–460.
- Chuttani K, Tischler MD, Pandian NG, Lee RT, Mohanty PK. Diagnosis of cardiac tamponade after cardiac surgery: relative value of clinical, echocardiographic, and hemodynamic signs. *Am Heart J* 1994;**127**:913–918.
- Sahay S, Tonelli AR. Pericardial effusion in pulmonary arterial hypertension. *Pulm Circ* 2013;**3**:467–467.
- Spodick DH. Pericardial diseases. In: E Braunwald, DP Zipes, P Libby (eds) *Braunwald's Heart Disease a Textbook of Cardiovascular Medicine*, 6th edn. Philadelphia: W B Saunders; 2001. p1841.
- Kuvin JT, Khabbaz K, Pandian NG. Left ventricular apical diastolic collapse: an unusual echocardiographic marker of postoperative cardiac tamponade. *J Am Soc Echocardiogr* 1999;**12**:218–220.
- Hinton J, Wilkinson JR. Percutaneous pericardiocentesis. *Medicine* 2018;**46**: 658–660.
- Susini G, Pepi M, Sisillo E, Bortone F, Salvi L, Barbier P et al. Percutaneous pericardiocentesis versus subxiphoid pericardiotomy in cardiac tamponade due to postoperative pericardial effusion. *J Cardiothorac Vasc Anesth* 1993;**7**: 178–183.
- Fenstad ER, Le RJ, Sinak LJ, Maradit-Kremers H, Ammash NM, Ayalew AM et al. Pericardial effusions in pulmonary arterial hypertension: characteristics, prognosis, and role of drainage. *Chest* 2013;**144**:1530–1538.